



RESEARCH ARTICLE

The potent effect of silymarin combination with Praziquantel or mirazid for *Schistosoma mansoni* treatment in infected male swiss albino mice

El-Nagar, D.M.^{1*}, Al Olayan, E.M.¹, Aloufi, A.S.¹, Khatab, A.R.¹

¹Department of Zoology, College of Science, King Saud University Riyadh, Saudi Arabia
*Corresponding author: elnagard1@yahoo.com

ARTICLE HISTORY

Received: 28 May 2020
Revised: 15 November 2020
Accepted: 22 November 2020
Published: 00 March 2021

ABSTRACT

This work was carried out to investigate the effect of silymarin combination in the therapeutic plane of schistosomiasis with praziquantel or mirazid to enhance the liver and reduce fibrosis. Mice were divided into 2 main groups, the 1st uninfected group served as control and the 2nd group infected subcutaneously with 60 cercaria of *S. mansoni* per each. The infected group was subdivided into 5 subgroups, the 1st kept untreated, the 2nd and 3rd treated at the 7th week of infection with (600 mg/kg) of PZQ orally for 3 consecutive days, while the 3rd treated also orally with (150 mg/kg) of silymarin daily for 11 weeks. The 4th and 5th groups treated orally at the 7th week of infection with 600 mg/kg of MZ for 3 consecutive days, while the 5th group treated orally also with 150 mg/kg of silymarin daily for 11 weeks. IgG determination showed high level in the untreated infected group. Furthermore, the infected groups treated with PZQ and PZQ with silymarin displayed the lower levels than treated with MZ. Additionally, the untreated infected group showed severe pathological changes as hyaline degeneration, inflammation, presence of worm burdens in dilated portal veins, granulomas as well as depositions of collagenous and reticular fibers indicated intense fibrosis. Treatment with PZQ alone resulted in reduction of pathological signs and decreasing of granulomas. Combination with silymarin to PZQ therapy revealed more improvement for liver besides to lowering of granulomas areas and volumes and decreasing of fibrosis. Whereas, treatment with MZ was less effective than PZQ to reduce granulomas areas, volumes and fibrosis. Although, combination of silymarin to MZ treatment resulted in more curative signs and reduction of granulomas areas, volumes and fibrosis. Furthermore, the present study concluded that PZQ still the more effective drug of schistosomiasis treatment than MZ. The silymarin is very useful in schistosomiasis treatment when combined with PZQ or MZ due to its anti-fibrotic effect.

Keywords: *Schistosoma mansoni*; praziquantel; mirazid; silymarin.

INTRODUCTION

Schistosomiasis is a tropically wide spread disease, it causes millions of infections in Africa, Asia and Latin America besides to animal husbandry economy threats (El-Khadragy *et al.*, 2019). Three main different species of *Schistosoma* can infect human *S. mansoni*, *S. hematobium* and *S. japonicum*. Cercariae are the infectious phase of *Schistosoma* that developed in fresh water snails which carrying the sporocysts (Zhao *et al.*, 2019). Cercariae penetrate the skin and reach the portal vein via the circulation accompanied by worm eggs arrival to the liver resulted in granulomatous reactions. It is followed by depositions of collagen I, II and III that termed fibrosis, due to activation of hepatic stellate cells. Fibrosis may be reversible whereas cirrhosis is an irreversible process, so it is very important to prevent the development of fibrosis to cirrhosis (El-Hawary *et al.*, 2018).

Praziquantel (PZQ) is a specific anti-schistosomal drug used for long time to eliminate the *schistosoma* worm burdens, but many studies reported its weak effect on immature stages of the parasite (El-Lakkany *et al.*, 2012; Dkhil *et al.*, 2014). On the other hand, PZQ exhibited a limited effect on liver fibrosis have developed due to ova depositions, granulomas formation and liver damage (Almeer *et al.*, 2018).

Mirazid is an anti-schistosomal drug which is newer than PZQ. It was introduced in the markets since 2001. It is extracted from myrrh which is an oleo-gum resin that collected from *Commiphora molomi* trees (El-Malky *et al.*, 2013). Mirazid has been reported as anti-protozoa drug (Baghdadi & Al-Mathal, 2010), furthermore it has a molluscicide and cercaricide action (Massoud & Habib, 2003), mosquito larvicide action (Massoud & Labib, 2000), anti-schistosomal effect (Badria *et al.*, 2008).

Silymarin is considered a hepatoprotective agent used for liver diseases treatment. It is an anti-oxidant due to its activity to scavenge reactive oxygen species and then inhibits lipid peroxidation (Mata-Santos et al., 2014). Antischistosomal drugs revealed unnoticeable reduction in hepatic fibrosis which increase the concern of using herbs to reduce fibrosis Silymarin possibly play a potent role to ameliorate and suppress fibrogenesis and granulomatous reactions due to schistosomiasis (Velebny et al., 2008; Kamel, 2016).

The present work aimed to investigate the impact of silymarin as antifibrotic agent combined with PZQ or with mirazid in mice infected by *Schistosoma mansoni*.

MATERIALS AND METHODS

Animals

60 male albino mice weighed 25±5 g, supplied from Theodor Bilharz Institute, Cairo – Egypt. Mice were kept inside plastic cages at 22°C and 12-h periods of light and dark. Mice were supplied with clean water and commercial food. The experiment was carried out under the general ethics of Saudi Arabia.

Experimental design

Mice were randomly divided into 2 main groups. Mice were infected with 60 cercariae per each by cutaneous infection

- A. uninfected mice were kept for the experimental period (negative control).
- B. infected mice with 60 cercariae per each by cutaneous infection. Then subdivided into 5 subgroups:
 - 1- Untreated infected were sacrificed after 18 weeks of infection.
 - 2- Infected mice were treated orally at the 7th week of infection with PZQ (600 mg/kg/b.w.) daily for 3 consecutive days (Velebny et al., 2008).
 - 3- Infected mice were treated orally at the 7th week of infection of with PZQ for 3 consecutive days and Silymarin (150 mg/kg/b.w.) daily for 11 weeks (Kamel, 2016).
 - 4- Infected mice were treated orally at the 7th week of infection with Mirazid (600 mg/kg/b.w.) for 3 consecutive days on empty stomach (Badria et al., 2008).
 - 5- Infected mice were treated orally at the 7th week of infection with Mirazid for 3 consecutive days and Silymarin (150 mg/kg/b.w.) daily for 11 weeks.

Oral doses were taken by stomach gavage. Mice were sacrificed after 18 weeks of infection. Collected blood samples were centrifuged at 3000 xg. to obtain sera. Livers were harvested and cut into small pieces then fixed in 10% neutral buffered formalin for the purpose of histological processes.

Serum evaluation for IgG

Serum IgG determination was carried out by Enzyme-linked immunosorbent Assay (ELISA). 1 mg/50 mL per well plate of the antigen preparations were used in the microtiter plates, diluted in bicarbonate buffer (0.05 M; pH 9). Phosphate saline buffer (0.15 M; pH 7.5-7.6) with 0.05% Tween 20 (PBS-Tween) was used for washing. 1% bovine serum albumin in PBS-Tween (BSA 1%) at 37°C was used for nonspecific sites blocking. Then serum samples were diluted 1:200 in BSA 1%, 50 ml of the diluted samples were incubated in the plates at 37°C for an hour. After washing plates were incubated at 37°C

with 50 mL of secondary antibody (anti-IgG mouse-peroxidase conjugated) diluted 1:500 in BSA 1%. The measurement was performed with hydrogen peroxide using ortho-phenyldiamine (0.04% phosphate citrate buffer 0.1 M, pH 5) as a chromogen. Absorbance values were obtained at 450 nm by microplate reader (Multiskan Labsystem).

Histopathological Analysis

Livers samples were cut into small pieces and fixed in 10% buffered neutral formalin. Pieces were dehydrated in ascending grades of ethanol alcohols followed by clearing in xylene and then embedded in paraffin wax. Sections were cut at 5µm thickness. Sections were rehydrated in descending grades of alcohols and cleared in xylene. Sections were stained by H&E as a routine stain, M. Tr. specific for collagenous fibers and Gomori Silver Technique specific for reticular fibers. Granulomatous lesions diameters and areas were measured by software of microscopy (Motic-2000), Volumes of granuloma were calculated according to formula Volume of sphere = 4.19 r³.

Statistical Analysis

The data were expressed as mean ± SEM (standard error of mean). Statistical significance of the control and experimental groups was evaluated by SPSS16.0. Comparison was made between control and experimental groups in IgG, granuloma area and granuloma volume. p<0.05 was considered to be significant.

RESULTS

Post-treatment with PZQ and silymarin to infection with *S. mansoni* lowered IgG levels than MZ and silymarin treatment

The untreated infected mice group with *S. mansoni* showed highly significant increasing of IgG levels. Whereas, the post-treated mice groups with PZQ alone and combined with silymarin revealed significantly decrease of IgG levels compared to untreated infected group. Moreover, the post-treated groups with MZ alone and combined with silymarin displayed less decrease of IgG levels than that of PZQ post-treatment alone and combined with silymarin groups (Table 1).

The silymarin combination with PZQ or MZ improved liver and minimized granulomatous lesion induced by *S. mansoni* infection

The mice liver of the control was investigated for the purpose of comparison, a brief description of normal liver was presented in a section examined under the microscope. The liver composed mainly of masses of parenchymal cells

Table 1. IgG responses in sera of untreated infected group and post-treated groups with PZQ, MZ alone or combined with Silymarin compared to control group

Groups	IgG microtitre
Control	90±0.2
Infected	200±0.3 ^{*a}
Infected + PZQ	130±0.2 ^{*a,b}
Infected + PZQ + Sily	100±0.3 ^{*b}
Infected + MZ	170±0.4 ^{*a}
Infected + MZ + Sily	150±0.3 ^{*a,b}

Data = Mean ± standard mean of error

P value significant when p<0.05

^{*a} significant compared to control group

^{*b} significant compared to infected group

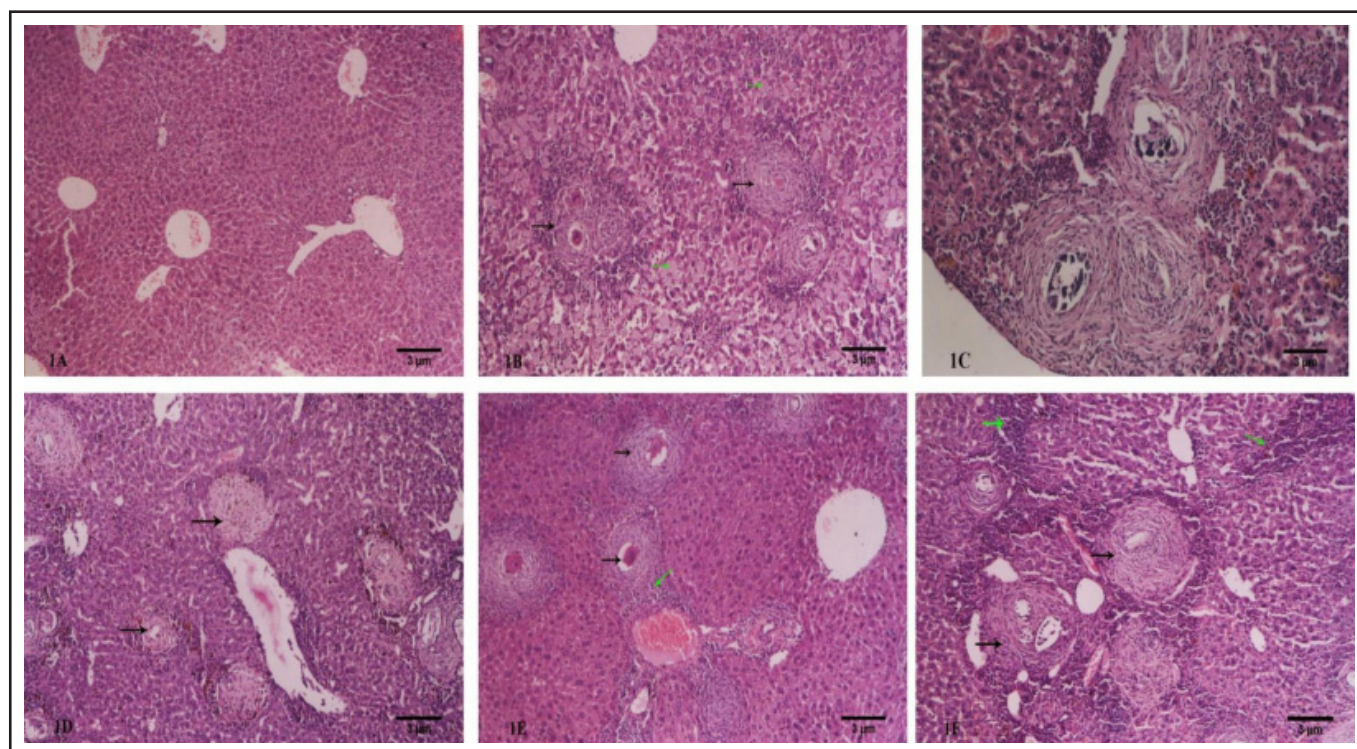


Figure 1. The silymarin combination with PZQ or MZ improved liver and minimized granulomatous lesion. Photomicrograph of liver control showing normal structure (1A), infected mice liver displaying hyaline degeneration (green arrows), large fibro-cellular granulomatous lesions with eggs and full completed miracidia (1B), infected mice treated with 600mg/kg PZQ showing fibro-cellular granuloma with partial and complete destroyed eggs (1C), infected mice treated with PZQ and 150 mg/kg silymarin revealing minimized granuloma with complete destruction of eggs (black arrows) (1D), infected mice treated with 600 mg/kg MZ displaying congested portal vein with hemorrhage and edema, granuloma with full formed miracidia (black arrows), inflammatory cells (green arrows) (1E), infected mice treated with MZ and 150 mg/kg silymarin showing minimized granuloma with partial destroyed miracidia (black arrows), inflammatory cells (green arrows) (1F). (H&E-100X).

arranged in lobules. Each lobule was centered with vein, at the periphery branches of the hepatic vein, hepatic artery and bile duct were present (Figure 1A). Whereas, after 18 weeks post to infection, the untreated infected mice liver displayed severe alterations represented by fibro-cellular granulomatous lesions with active ova, developed and completely formed miracidia. Lesions were surrounded by dense collagenous fibrous bundles and inflammatory cells mainly eosinophils and lymphocytes were arranged around fibers. Moreover, hyaline degeneration of hepatocytes were observed (Figure 1B). Granulomatous lesions reached great area and volume (Table 2). Furthermore, the infected group treated with PZQ at 7th week of infection for 3 consecutive days revealed marked improvement manifested by minimized fibro-cellular granulomatous lesions with partially and completely destroyed ova surrounded by lower content of fibers and inflammatory cells (Figure 1C). Previous studies indicated that post-treatment with PZQ to infection resulted in many remarkable signs for *S.mansoni* cure manifested by reduction of worm burdens and eggs, decreasing of granuloma size besides to improvement of liver functions and reduction of pathological signs. while, the effect of PZQ on fibrosis due to infection still limited. Minimized granuloma showed less area and volume than untreated infected mice group (Table 2). Infected mice treated with combined oral dose of PZQ for 3 consecutive days and daily treatment of silymarin continuously for 11 weeks at 7th week of infection gained more degree of improvement showed less minimized fibro-cellular granulomas with completely destroyed ova and surrounded by inflammatory cells. In addition to dilated portal vein surrounded by inflammatory

Table 2. Granulomas areas and volumes of untreated infected group and post-treated groups with PZQ, MZ alone or combined with Silymarin compared to control group

Groups	Granuloma area	Granuloma volume
Control	0±0	0±0
Infected	12.9±0.2 ^{*a}	28±0.2 ^{*a}
Infected + PZQ	4.5±0.1 ^{*a,b}	7.2±0.2 ^{*a,b}
Infected + PZQ + Sily	3.5±0.02 ^{*a,b}	5.6±0.07 ^{*a,b}
Infected + MZ	6.8±0.07 ^{*a,b}	11.5±0.08 ^{*a,b}
Infected + MZ + Sily	5.3±0.02 ^{*a,b}	7.3±0.03 ^{*a,b}

Data = Mean ± standard mean of error

P value significant when $p < 0.05$

*a significant compared to control group

*b significant compared to infected group

cells (Figure 1D). Granulomatous lesions reached the least area and volume (Table 2). While, the investigation of mice liver treated with oral treatment of MZ for 3 consecutive days at 7th week of infection showed histopathological changes. The sign of infection was demonstrated by the presence of fibro-cellular granulomas with mature ova and others appeared destroyed surrounded by fibers and inflammatory cells. Additionally, portal veins looked congested with erythrocytes and edema surrounded by inflammatory cells (Figure 1E). Granulomatous lesions gained larger areas and volumes that groups treated with PZQ (Table 2). Investigation of infected hepatic sections treated with orally combined

doses of MZ for 3 consecutive days and silymarin for 11 weeks continuously, at 7th week after infection displayed some less pathological changes demonstrated by granulomas with complete destructed ova. Some aggregations of inflammatory cells were abundant (Figure 1F). Granulomas reached less areas and volumes than that group treated with MZ only, but still larger than groups treated with PZQ only or combined with silymarin.

Silymarin combination with PZQ or MZ treatment minimized the collagenous and reticular fibers depositions due to *S. mansoni*

The control liver section showed no collagenous or reticular fibers depositions (Figure 2A & 3A). The untreated infected mice liver stained with M.tr revealed heavy incidence of collagenous and reticular fibers depositions in the granulomatous lesions besides to worm burden in the dilated portal vein (Figure 2B & 3B). Whereas, the infected mice treated with PZQ only showed less depositions of collagenous and reticular fibers compared the untreated infected group (Figure 2C & 3C). Additionally, silymarin combination with PZQ resulted in the least collagenous and reticular fibers depositions (Figure 2D & 3D). While, infected mice liver treated with MZ only showed intense depositions of collagenous and reticular fibers in the fibro-cellular granuloma as response to weak treatment of infection (Figure 2E & 3E). The collagenous and reticular depositions were minimized in the infected mice treated with combined

doses of MZ and silymarin, referring to the potent effect of silymarin to reduce fibrosis resulted from granuloma response of infection.

DISCUSSION

Liver fibrosis induced by schistosomiasis is responsible for a major public health problem in Asia, Africa and South America (Zhao *et al.*, 2019). Chemical drugs for schistosomiasis treatment could ameliorate mature worms and decrease eggs accumulation in an impressive way. While, these drugs had less impact to reverse the liver fibrosis especially in chronic stages (Andrade, 2008).

In the present study, the untreated infected mice group revealed high detection for IgG referred to active infection that matched with many previous studies (Abdul-Ghani & Hassan, 2010; Wang *et al.*, 2017). Whereas, the infected groups treated with PZQ alone or combined with silymarin displayed the lowest detection of IgG among groups referred to reduction of infection. While, the infected groups treated with MZ alone or combined with silymarin also showed decreasing of IgG detection compared to untreated infected group, but more than infected groups treated with PZQ. These findings were the opposite of Abdel-Aziz *et al.* results who stated that infected groups treated with PZQ or MZ decreased significantly the IgG levels in an almost equal way (Aziz *et al.*, 2006).

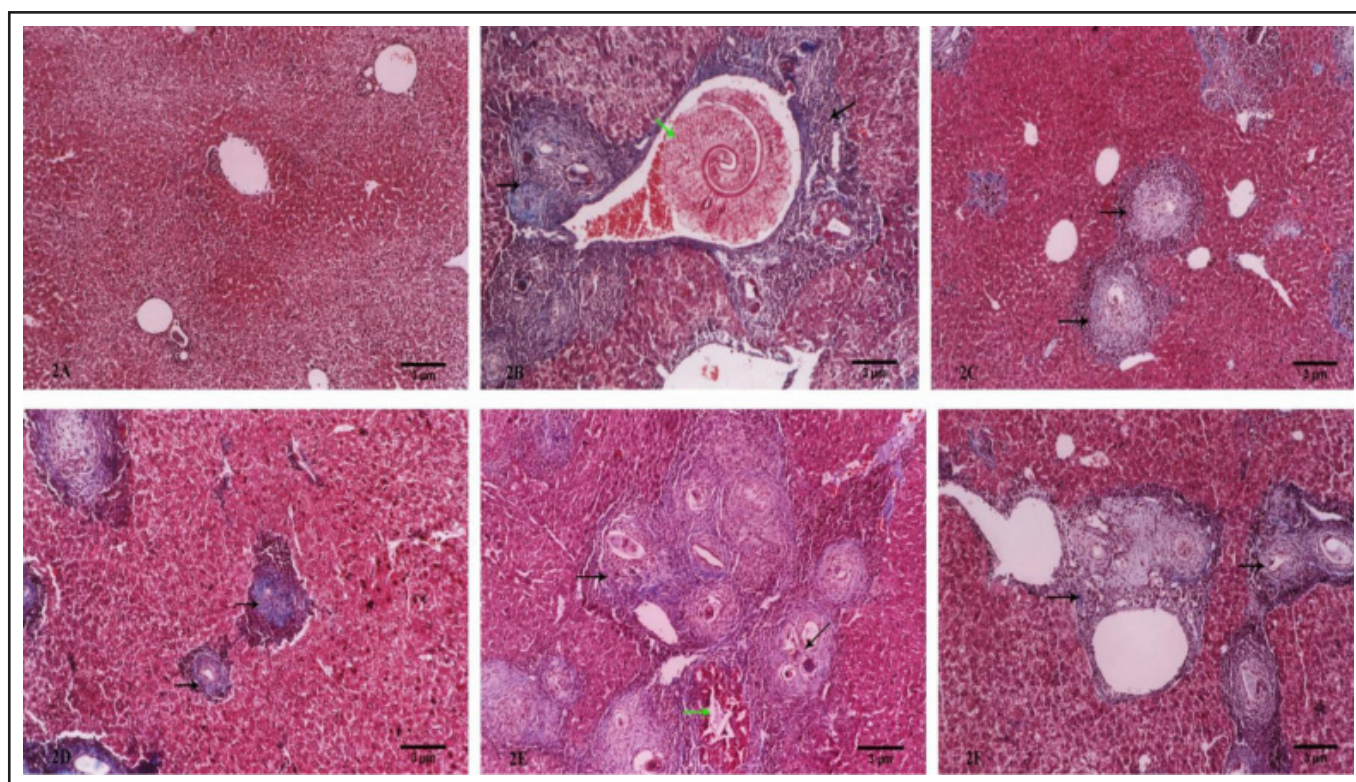


Figure 2. Silymarin combination with PZQ or MZ treatment minimized the collagenous fibers.

Photomicrograph of control liver showing normal structure without depositions of collagenous fibers (2A), untreated infected mice liver displaying worm burden in the dilated portal vein (green arrow) and intense depositions of collagenous fibers in the fibro-cellular granuloma with eggs and complete formed miracidia (2B), infected mice liver treated with 600 mg/kg PZQ showing complete and partial destruction of eggs with less depositions of collagenous fibers in the granuloma (2C), infected mice liver treated with combined doses of PZQ and 150 mg/kg silymarin revealing minimized granuloma with complete destruction of eggs and a very small amount of collagenous fibers (2D), infected mice liver treated with 600 mg/kg MZ displaying granulomatous lesions with eggs and full complete miracidia with high content of collagenous fibers (black arrows), T.S. of worm burden (green arrow) (2E), infected mice liver treated with combined doses of MZ and 150 mg/kg silymarin revealing minimized granulomatous lesions and less content of collagenous fibers in the fibro-cellular granuloma (2F). (M.Tr.-100X).

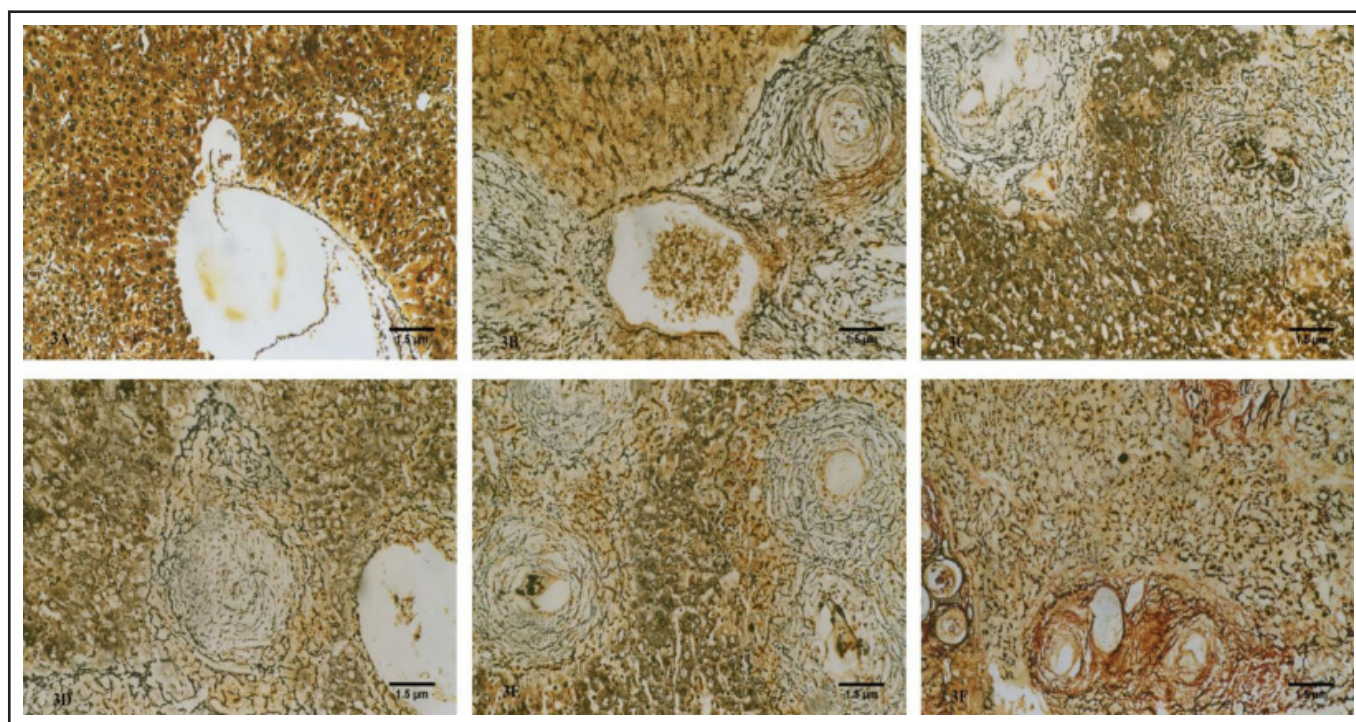


Figure 3. Silymarin combination with PZQ or MZ treatment minimized the reticular fibers. Photomicrograph of control liver showing no depositions of reticular fibers (3A), untreated infected mice liver displaying heavy depositions of reticular fibers around granuloma (3B), infected mice treated with 600mg/kg PZQ showing depositions of reticular fibers (3C), infected mice treated with combined doses of PZQ and 150 mg/kg of silymarin showed less depositions of reticular fibers (3D), infected mice treated with 600 mg/kg MZ revealing depositions of reticular fibers in granuloma with full formed miracidia (3E), infected mice treated with combined doses of MZ and 150 mg/kg silymarin showing less depositions of reticular fibers (3F). (Silver Gomori Tech. – 200X).

The present work represented that 18 weeks after infection induced marked pathological changes manifested by presence of worm burdens in dilated portal veins. Granulomatous lesions with enormous areas and volumes were observed due to isolation of the eggs from the liver cells. Eggs trapped in depositions of collagenous and reticular fibers which lead to liver fibrosis, these findings run in agreement with (Mata-Santos *et al.*, 2014; El-Khadragy *et al.*, 2019). Previous studies indicated that post-treatment with PZQ to infection resulted in many remarkable signs for *S. mansoni* cure manifested by reduction of worm burdens and eggs, decreasing of granuloma size besides to improvement of liver functions and reduction of pathological signs. While, the effect of PZQ on fibrosis due to infection still limited (Issa, 2007; Elgharabawy *et al.*, 2011). Accordingly, the present results are in agreement with the previous findings. Additionally, the present study revealing that combination of silymarin to the therapy plane with PZQ improved not only the liver function but also the hepatocytes degeneration and liver fibrosis due to reduction of collagenous and reticular depositions that coincided with many studies (H. Mata-Santos *et al.*, 2010; El-Lakkany *et al.*, 2012). Moreover, the present study elucidated that PZQ is more potent than MZ in *S. mansoni* treatment which manifested by less improved hepatic tissue with fibrosis and larger granuloma areas and volumes that close to Abdel-Rahman findings. Additionally, in the present study combination of silymarin to MZ treatment revealed more improvement to the liver tissue and less granuloma areas and volumes due to reduction of fibrosis.

In conclusion, it was concluded that praziquantel still the more effective anti-schistosomal drug compared with mirazid. Moreover, silymarin could reduce the pathological

alterations induced by *Schistosoma* infection when combined with anti-schistosomal drugs that it could reduce the fibrosis and then minimized the granulomatous reactions, so it is recommended in the therapeutic plans of *Schistosoma*.

ACKNOWLEDGEMENTS

The authors acknowledge financial support from the Researchers Supporting Project number (RSP-2020/111). King Saud University, Riyadh, Saudi Arabia.

Conflict of interest

The authors declare that they have no conflict of interest.

REFERENCES

- Abdul-Ghani, R.A. & Hassan, A.A. (2010). Murine schistosomiasis as a model for human schistosomiasis mansoni: similarities and discrepancies. *Parasitology Research* **107**: 1-8. <https://doi.org/10.1007/s00436-010-1855-5>
- Almeer, R.S., El-Khadragy, M.F., Abdelhabib, S. & Moneim, A.E.A. (2018). Ziziphus spina-christi leaf extract ameliorates schistosomiasis liver granuloma, fibrosis, and oxidative stress through downregulation of fibrinogenic signaling in mice. *PLoS ONE* **13**: 1-23. <https://doi.org/10.1371/journal.pone.0204923>
- Andrade, Z.A. (2008). Schistosomiasis and hepatic fibrosis regression. *Acta Tropica* **108**: 79-82. <https://doi.org/10.1016/j.actatropica.2008.04.003>
- Aziz, M.A., Abbas, A., Elbakry, K. & Toson, E.A. (2006). Immune response on mice infected with *Schistosoma mansoni* and treated with myrrh. *Journal of Medical Science* **6**: 858-

861. <https://doi.org/10.3923/jms.2006.858.861>
- Badria, F., Abou-Mohamed, G., El-Mowafy, A., Masoud, A. & Salama, O. (2008). Mirazid: A new schistosomicidal drug. *Pharmaceutical Biology* **39**: 127-131. <https://doi.org/10.1076/phbi.39.2.127.6253>
- Baghdadi, H.B. & Al-Mathal, E.M. (2010). Anti-coccidial effect of Commiphora molmol in the domestic rabbit (*Oryctolagus cuniculus domesticus* L.). *Journal of the Egyptian Society of Parasitology* **40**: 653-668.
- Dkhil, M., Abdel Moneim, A. & Al-Quraishy, S. (2014). Berberine protects against *Schistosoma mansoni*-Induced oxidative damage in renal and testicular tissues of mice. *Pakistan Journal of Zoology* **46**: 763-771.
- El-Hawary, S.S., Taha, K.F., Kirillos, F.N., Dahab, A.A., El-Mahis, A.A. & El-Sayed, S.H. (2018). Complementary effect of Capparis spinosa L. and silymarin with/without praziquantel on mice experimentally infected with *Schistosoma mansoni*. *Helminthologia (Poland)* **55**: 21-32. <https://doi.org/10.1515/helm-2017-0055>
- El-Khadragy, M.F., Al-Olayan, E.M., Elmallah, M.I.Y., Alharbi, A.M., Yehia, H.M. & Abdel Moneim, A.E. (2019). Probiotics and yogurt modulate oxidative stress and fibrosis in livers of *Schistosoma mansoni*-infected mice. *BMC Complementary and Alternative Medicine* **19**: 1-13. <https://doi.org/10.1186/s12906-018-2406-3>
- El-Lakkany, N.M., Hammam, O.A., El-Maadawy, W.H., Badawy, A.A., Ain-Shoka, A.A. & Ebeid, F.A. (2012). Anti-inflammatory/anti-fibrotic effects of the hepatoprotective silymarin and the schistosomicide praziquantel against *Schistosoma mansoni*-induced liver fibrosis. *Parasites and Vectors* **5**: 1-14. <https://doi.org/10.1186/1756-3305-5-9>
- El-Malky, M.A., Lu, S.H., El-Beshbishi, S.N., Saudy, N.S. & Ohta, N. (2013). Effect of Mirazid in *Schistosoma japonicum*-infected mice: parasitological and pathological assessment. *Parasitology Research* **112**: 373-377. <https://doi.org/10.1007/s00436-012-3145-x>
- Elgharabawy, R., El Sisi, A.E., Awara, W., Elmasry, T. & El-Kowrany, S. (2011). Effects and mechanism of action of immunomodulating agents against schistosomiasis-induced hepatic inflammation and fibrosis in mice. *Research in Pharmaceutical Biotechnology* **3**: 32-45.
- Issa, R. (2007). *Schistosoma mansoni*: The prophylactic and curative effects of propolis in experimentally infected mice. *Rawal Medical Journal* **32**: 94-98.
- Kamel, R.O.A. (2016). Interactions between mefloquine and the anti-fibrotic drug silymarin on *Schistosoma mansoni* infections in mice. *Journal of Helminthology* **90**: 760-765. <https://doi.org/10.1017/S0022149X16000018>
- Massoud, A.M.A. & Habib, F.S.M. (2003). The effects of myrrh (*Commiphora molmol*) on the infected snails of *Schistosoma* sp. and their egg masses: effect on shedding of cercariae and on snail fecundity. *Journal of the Egyptian Society of Parasitology* **33**: 585-596.
- Massoud, A.M. & Labib, I.M. (2000). Larvicidal activity of *Commiphora molmol* against *Culex pipiens* and *Aedes caspius* larvae. *Journal of the Egyptian Society of Parasitology* **30**: 101-115.
- Mata-Santos, H.A., Dutra, F.F., Rocha, C.C., Lino, F.G., Xavier, F.R., Chinalia, L.A., Hossy, B.H., Castelo-Branco, M.T.L., Teodoro, A.J., Paiva, C.N. & Pyrrho, A.S. (2014). Silymarin reduces profibrogenic cytokines and reverses hepatic fibrosis in chronic murine schistosomiasis. *Antimicrobial Agents and Chemotherapy* **58**: 2076-2083. <https://doi.org/10.1128/AAC.01936-13>
- Mata-Santos, H., Lino, F., Carneiro Rocha, C., Paiva, C., Castelo Branco, M. & Pyrrho, A. (2010). Silymarin treatment reduces granuloma and hepatic fibrosis in experimental schistosomiasis. *Parasitology Research* **107**: 1429-1434. <https://doi.org/10.1007/s00436-010-2014-8>
- Velebny, S., Hrcckova, G. & Kogan, G. (2008). Impact of treatment with praziquantel, silymarin and/or beta-glucan on pathophysiological markers of liver damage and fibrosis in mice infected with *Mesocestoides vogae* (Cestoda) tetrathyridia. *Journal of Helminthology* **82**: 211-219. <https://doi.org/10.1017/S0022149X08960776>
- Wang, Y., Lin, C., Cao, Y., Duan, Z., Guan, Z., Xu, J., Zhu, X.Q. & Xia, C. (2017). Up-regulation of Interleukin-21 Contributes to Liver Pathology of Schistosomiasis by Driving GC Immune Responses and Activating HSCs in Mice. *Scientific Reports* **7**: 1-11. <https://doi.org/10.1038/s41598-017-16783-7>
- Zhao, Y., Yang, S., Li, B., Li, W., Wang, J., Chen, Z., Yang, J., Tan, H. & Li, J. (2019). Alterations of the mice gut microbiome via *Schistosoma japonicum* ova-induced granuloma. *Frontiers in Microbiology* **10**: 1-16. <https://doi.org/10.3389/fmicb.2019.00352>