

Case Report

Interocclusal Registration for Diagnosis and Treatment Planning for Implant Restorations

S AlZain

Department of Prosthetic
Dental Sciences, College
of Dentistry, King Saud
University, Riyadh,
Saudi Arabia

ABSTRACT

This paper describes a new technique to record the interocclusal relationship of an implant case where multiple posterior teeth are missing and need to be replaced by implant restorations. In the case presented, an appliance was designed to be supported only by hard immovable tissues; teeth that provide a precise fit of records. The well-fitting appliance can be used to accurately mount implant cases with inadequate posterior support for diagnosis and treatment planning. This technique of interocclusal registration has the advantages of accurate mounting, preservation of materials and financial expenses, and reduction of chair-side time. This appliance may also be used in all cases of multiple missing posterior teeth requiring prosthodontic treatment.

KEYWORDS: *Interocclusal Records, Diagnosis and Treatment Plan, Implant Restorations*

Date of Acceptance:
28-Feb-2017

INTRODUCTION

Diagnostic casts enable clinicians to evaluate the case and discuss treatment plan with other professionals in the implant team. Accurately mounted diagnostic casts should provide information necessary to formulate an appropriate treatment plan for implant restorations such as implant site and angulation, edentulous ridge relationship to adjacent teeth and opposing arch, availability of inter-arch space, etc. A diagnostic wax-up may be needed. A radiographic template is also fabricated on mounted diagnostic casts. Therefore, accurately mounted diagnostic casts are important for a successful treatment plan of implant as well as other prosthodontic cases.

Accurate interocclusal records should provide support and stability of the casts. Different dental materials may be used such as plasters, zinc oxide-eugenol paste, or metallic wax mixtures such as aluminum wax (Aluwax).^[1-4] Polyvinyl siloxane and polyether can also be used.^[5,6] Although polyvinyl siloxane and polyether are routinely used for interocclusal registration due to their dimensional stability, the amount of force that is applied on casts during mounting may not be easy to control.^[1] Too much force results in an extensive compression of those materials, and too little force

results in an inaccurate seating of casts into the record.^[1] Both conditions result in an inaccurate mounting of casts.

In edentulous cases where there are multiple missing posterior teeth, a record base that is made of baseplate wax, autopolymerizing, light-activated resin, or hard waxes is often used. An occlusal wax rim is placed on occlusal surface of the record base and imprints of opposing teeth are recorded. This method is time-consuming in both laboratory and clinic.

This paper describes a simple time-saving technique of recording an interocclusal relationship of maxillary and mandibular teeth in a case where multiple posterior teeth were missing for the purpose of diagnosis and treatment planning for implant restorations.

CASE REPORT

A 65-year old female patient presented in the prosthodontic clinic for replacement of multiple missing maxillary and mandibular posterior teeth with implant restorations. Therefore, an accurate mounted diagnostic

Address for correspondence: Dr. S AlZain,
P.O. Box 102247, Riyadh 11675,
Kingdom of Saudi Arabia.
E-mail: saharalzain@gmail.com

Access this article online

Quick Response Code:



Website: www.njcponline.com

DOI: 10.4103/njcp.njcp_65_17

This is an open access article distributed under the terms of the Creative Commons Attribution-Non Commercial-Share Alike 3.0 License, which allows others to remix, tweak, and build upon the work non-commercially, as long as the author is credited and the new creations are licensed under the identical terms.

For reprints contact: reprints@medknow.com

How to cite this article: AlZain S. Interocclusal registration for diagnosis and treatment planning for implant restorations. Niger J Clin Pract 2017;20:1049-51.

casts were needed. The correct maximum intercuspal position was clinically checked to locate positions of introclusal contacts [Figure 1]. Areas of contacts were marked on the maxillary diagnostic cast, and a single layer of a baseplate wax (Sculpturing wax, YETI Dental, YETI Dentalprodukte GmbH, Industriestrasse 3, 78234 Engen, Germany) was adapted only to occlusal contact areas on maxillary cast [Figure 1B]. A petroleum jelly (Vaseline Petroleum Jelly, Unilever, Inc.) was used to lubricate maxillary cast. An autopolymerizing acrylic resin (Orthoresin, Densply, Weybridge, Surrey KT15, 25E, England) was used with a sprinkle-on technique. The acrylic resin covered incisal/occlusal surfaces of maxillary remaining teeth and extended up to one-third of their labial/buccal and palatal surfaces to get adequate stability and retention of the appliance. The acrylic resin was also extended to cover occlusal, buccal, and palatal surfaces of unopposed maxillary posterior teeth to provide extra rigidity and retention of the appliance. No attempt was made to contact soft tissues. Only the area of the acrylic resin covering the baseplate wax was removed with an acrylic bur. Wax was first exposed, and then removed to leave a window in the acrylic resin. The appliance was finished and polished. The acrylic resin appliance was intraorally tried-in to make sure there were no interferences in maximum intercuspal position [Figure 1C]. The finished appliance was intra-orally seated on maxillary teeth. A petroleum jelly lubricant was applied to all natural teeth. An acrylic resin material (Duralay, Inlay Pattern Resin, Reliance Dental Mfg. Co, 5805W. 117th Pl. Worth, Illinois 60482) was mixed according to manufacturer's instructions and was directly applied to the incisal/occlusal thirds of mandibular remaining teeth, and the patient was instructed to close in maximum intercuspal position [Figure 1D]. Excess material extending to the middle

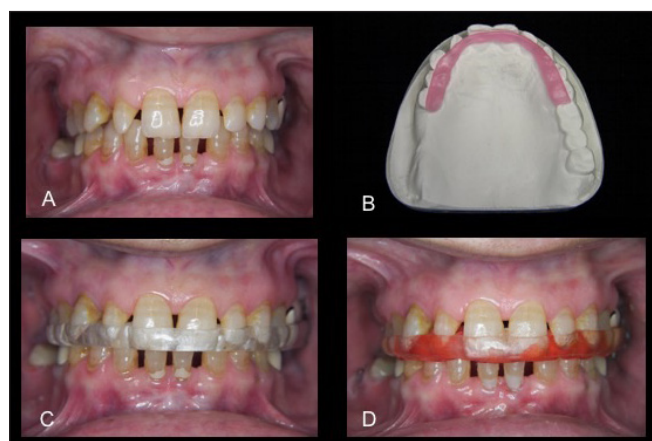


Figure 1: (A) Teeth contacts in maximum intercuspal position. (B) A baseplate wax covering contact areas of maxillary teeth with opposing ones. (C) A try-in of the teeth-fitted appliance. (D) Maximum intercuspal position was recorded using an acrylic resin.

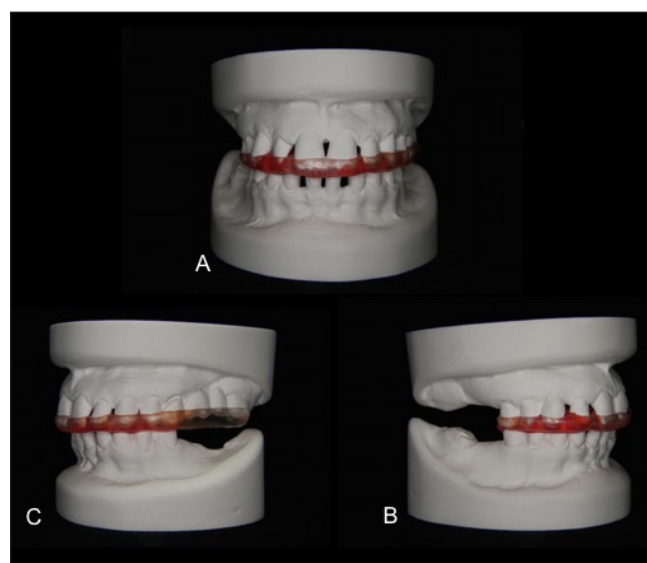


Figure 2: (A) Frontal view of the stable and retentive acrylic resin appliance verified on the casts. (B) Right-side lateral view of appliance verified on the casts. (C) Left-side lateral view of appliance verified on the casts.

third of the mandibular teeth was immediately removed to avoid engaging teeth undercuts at interproximal areas. After setting of the material, the appliance was removed from patient's mouth and finished using an acrylic bur. The appliance was seated on the maxillary diagnostic cast. The mandibular cast was seated into the imprints in the record. An accurate relationship of the maxillary and mandibular diagnostic casts using the acrylic resin appliance was verified before mounting them [Figure 2A,B,C]. Although there were multiple missing posterior teeth, maxillary and mandibular casts could be still held together with adequate stability and retention using only the retentive acrylic resin appliance. However, wooden sticks and sticky wax were applied onto sides of casts to provide extra stabilization.

DISCUSSION

Accurate mounting of diagnostic casts is considered mandatory for diagnosis and treatment planning of implant and other prosthodontic cases. Mounting of diagnostic casts of distally edentulous cases with multiple missing posterior teeth, that do not provide adequate posterior vertical stability and support, are considered the most commonly encountered clinical difficulty.

The conventionally used materials such as plasters, pastes, aluminum wax, polyvinyl siloxane, and polyether materials may not result in an accurate mounting. This could be either due to their dimensional instability or due to their direct contact with the movable soft tissues. In distally edentulous cases, a record base and an occlusal recording material are usually used for diagnostic mounting, which is time-consuming. In the present

case, a stable and retentive acrylic resin appliance was fabricated to facilitate interocclusal registration and accurate mounting of the diagnostic casts in distally edentulous cases with multiple missing posterior teeth that do not provide adequate posterior vertical stability and support. The appliance was designed to fit only onto hard immovable tissues; the teeth. No attempt was made to develop contact with the soft movable tissues. Therefore, the appliance can be used to mount different casts with a high degree of precision. This would also result in the elimination of errors that could be introduced by using different interocclusal records and recording materials. The preservation of materials and financial expenses and the reduction of laboratory and clinical chair-side times were considered additional advantages.

Financial support and sponsorship

Nil.

Conflicts of interest

There are no conflicts of interest.

REFERENCES

1. Squier RS. Jaw relation records for fixed prosthodontics. *Dent Clin N Am* 2004;48:471-86.
2. Keyf F, Altunsoy S. Compressive strength of interocclusal recording materials. *Braz Dent J* 2001;12:43-6.
3. Vergos VK, Tripodakis AD. Evaluation of vertical accuracy of interocclusal records. *Int J Prosthodont* 2003;16:363-8.
4. Pagnano VO, Bezzon OL, Mattos MC, Ribeiro RF, Turbino ML. Clinical evaluation of interocclusal recording materials in bilateral free end cases. *Braz Dent J* 2005;16:140-4.
5. Ghazal M, Ludwig K, Kern M. Evaluation of vertical accuracy of interocclusal recording materials. *Quintessence Int* 2008;39:727-32.
6. Ghazal M, Albashaireh Z, Kern M. The ability of different materials to reproduce accurate records of interocclusal relationships in the vertical dimension. *J Oral Rehab* 2008;35:816-20.

