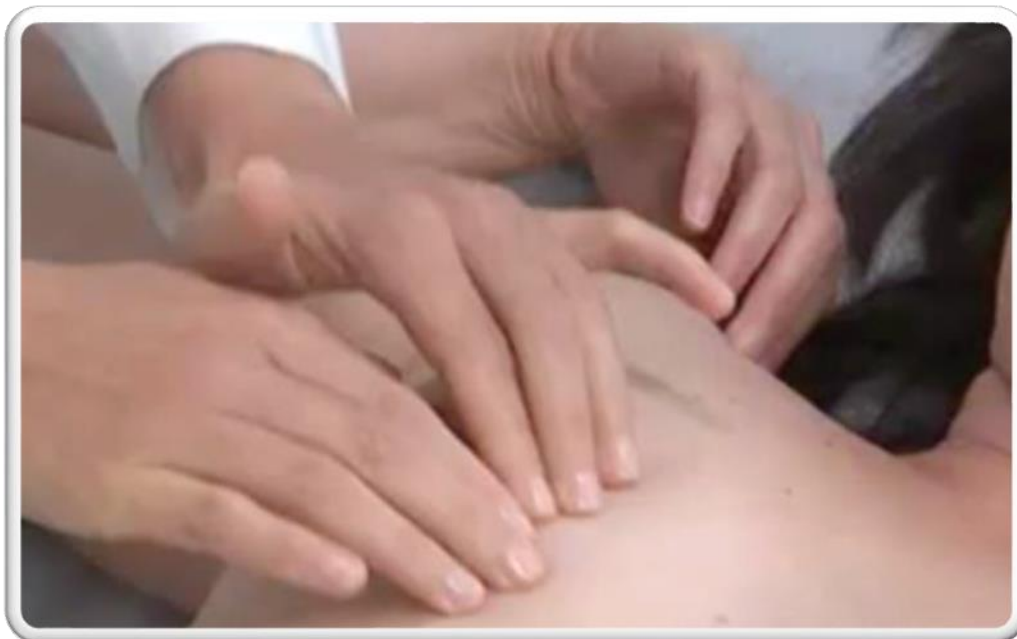

NUR 221 health assessment (practical) Procedure guide and performance checklist

Module six

Physical examination of Breast & Lymphatic System



- Physical assessment of the breasts and axillae follows an organized pattern. It begins with a patient survey followed by inspection of the breasts while the patient assumes a variety of positions. Palpation includes the entire surface of each breast. including the tail of Spence and the lymph nodes of the axillae.

A. Physical Examination of the breast and axilla:

1.

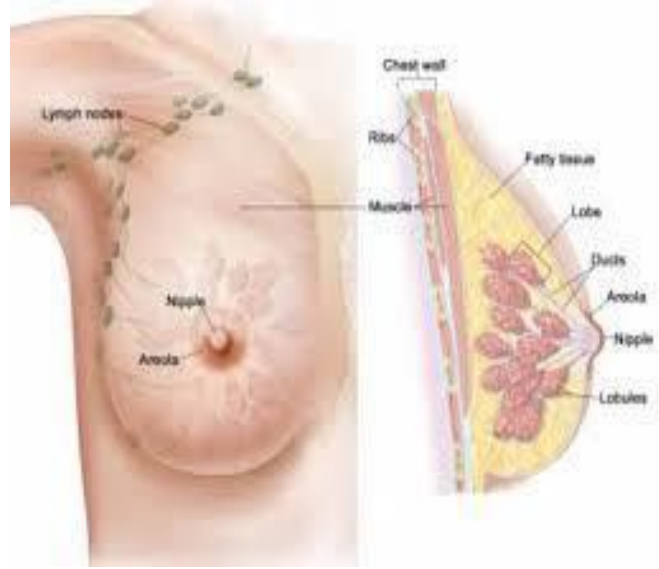
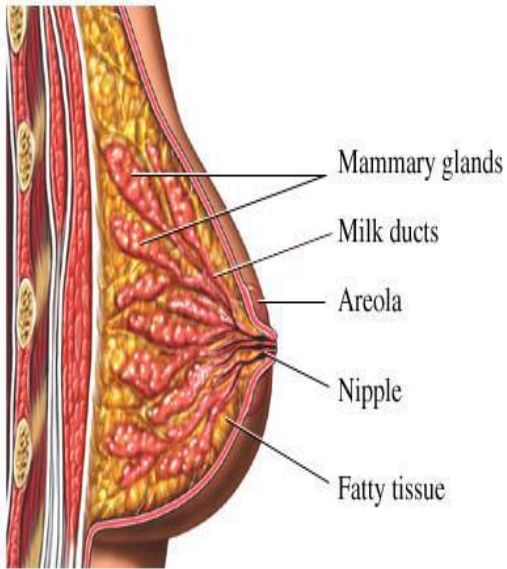
- ✓ **Presence of symptoms such as** changes in underarm area axilla, tenderness, lump, swelling, rash.
- ✓ **Family History:** breast cancer, breast disorder, other types of cancer.
- ✓ **Life style habits: high** fat diet, caffeine, smoking, alcohol.
- ✓ **Medications:** oral contraceptive pills.

2. Prepare equipment:

- ✓ Examination gown and drape.
- ✓ Clean, nonsterile examination gloves
- ✓ Small pillow or rolled towel
- ✓ Metric ruler


3. Patient preparation:


- ✓ Provide an environment that is warm, comfortable and private.
- ✓ Ask the patient if they prefer a nurse who is the same gender for cultural consideration.
- ✓ Explain the steps of the examination, and answer any questions the client may have. These actions will help to relive client anxiety.
- ✓ Explaining that they will need to expose the breasts and privacy will be provided.
- ✓ Use draping techniques to maintain the patient's dignity.
- ✓ Provide specific instructions to the patient state whether the patient must sit stand or lie down.
- ✓ Explain the reasons for the examination and provide education about BSE (breast self-examination).
- ✓ When patient have lesions or drainage in and around the breasts, nonsterile examination gloves are required to prevent infection.
- ✓ Use Standard Precautions.



Note: the upper outer quadrant of breast is the sites of most breast tumors.

Physical examination techniques and normal finding

Procedure	Normal Findings
INSPECTION	
<p>1- Instruct the patient.</p> <ul style="list-style-type: none"> ✓ Explain to the patient that you will be assessing her breasts in variety of ways. ✓ First you will have the patient sit and then assume several positions that move the breasts away from the chest wall so that differences in size shape, symmetry, contour, and color can be detected. ✓ Inform the patient that she will then lie down and you will assess each breast by palpating the breast tissue and nipple. ✓ Explain the purpose of each assessment in terms the patient will understand. 	
<p>2- Position the patient.</p> <ul style="list-style-type: none"> ✓ The patient should sit comfortably and erect, with the gown at the waist to both breasts are exposed . <div style="text-align: center;">  </div> <p>Fig 1. The patient is seated at the beginning of the breast examination</p>	
<p>3-Inspect and compare size and symmetry of the breasts.</p>	One breast may normally be slightly larger than the other.
<p>4-Inspect for skin color.</p>	Color should be consistent with

	the rest of the body.
5-Inspect for venous patterns.	Venous pattern are the same bilaterally.
6- Inspect for moles or other markings.	Moles that are unchanged, nontender and long –standing are of no concern.
7-Inspect the areolae.	The areolae are normally round or oval and almost equal in size ,areolae are pink in light skinned people and brown in dark skinned people .the areolae darken in pregnancy.
8- Inspect the nipples.	Nipple are normally the same color as the areolae and are equal in size and shape. Nipples are generally everted but may be flat or inverted. Nipples should be free of cracks, crust, erosions, ulcerations, pigment changes or discharge.
9-Inspect with the patient's arms over the head 	
Fig. 2 Inspection of the breasts with the patient's arms over the head.	

10-Inspect with the patient 's hands pressed against her waist

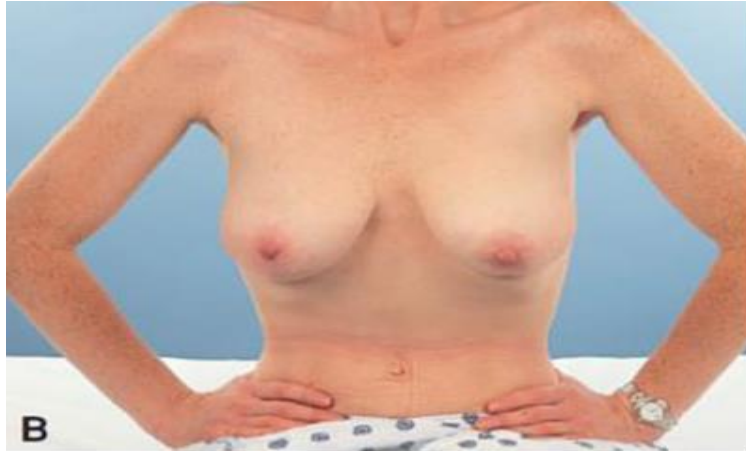

Fig. 3 Inspection of the breasts with the patient's hands pressed

11-Inspect with the patient's hands pressed together at the level of the waist.

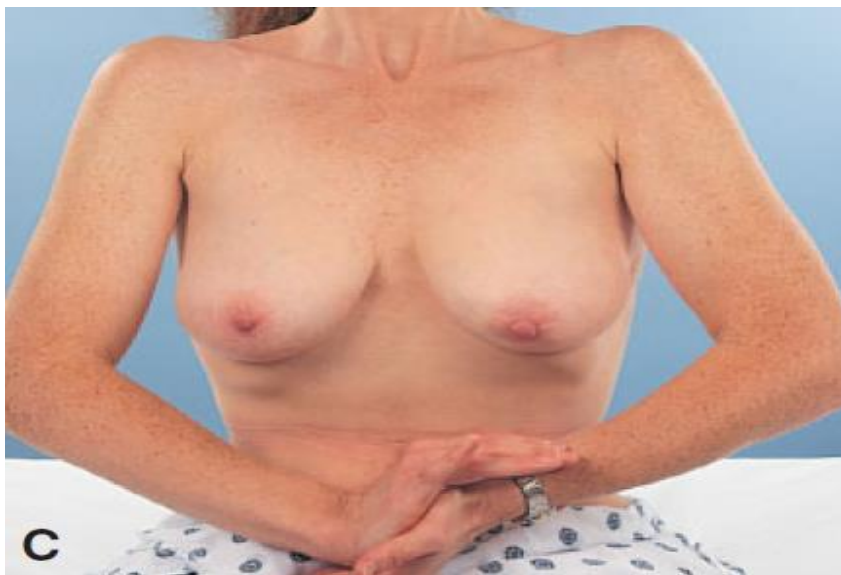

Fig. 4 Inspection of the breasts with the patient's hands pressed together at the level of her waist.

12-Inspect with the patient leaning forward from the waist

The breast normally fall freely and evenly from the chest.

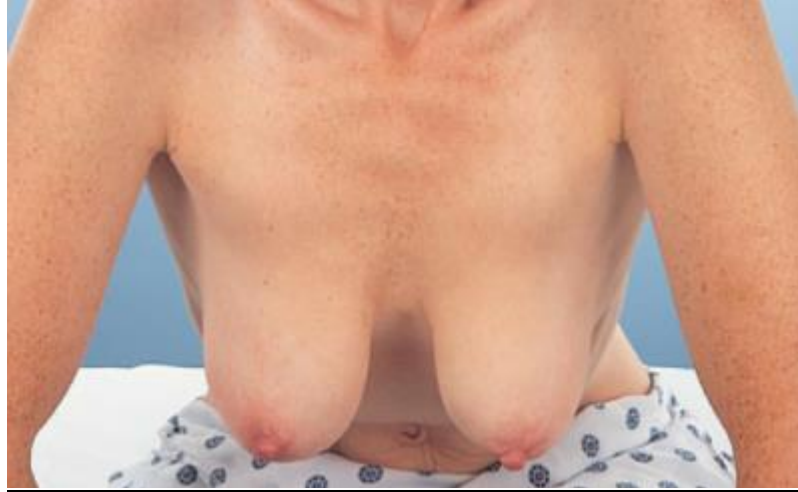

Fig. 5 Assisting the patient to lean forward for inspection

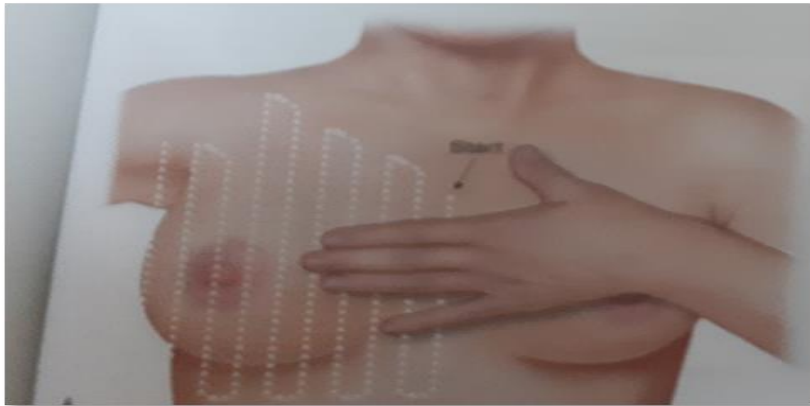
PALPATION OF THE BREAST

PROCEDURE	NORMAL FINDINGS
<p>1-Position the patient :</p> <ul style="list-style-type: none"> ✓ Ask the patient to lie down. Cover the breast that is not being examined. ✓ place a small pillow or rolled towel under the shoulder of the side to be palpated and position the patient's arm over her head. 	<p>This maneuver flattens the breast tissue over the chest wall.</p>
<p>2-Instruct the patient:</p> <ul style="list-style-type: none"> ✓ Explain that you will be touching the entire breast and nipple. ✓ Tell the patient to inform you of any discomfort or tenderness. 	
<p>3-Palpate skin texture.</p>	<p>Skin texture should be smooth with uninterrupted contour.</p>
<p>4-Palpate the breast.</p> <ul style="list-style-type: none"> ✓ Use the finger pads of the three finger in dime-sized circular motions to press the breast tissue against the chest wall. 	

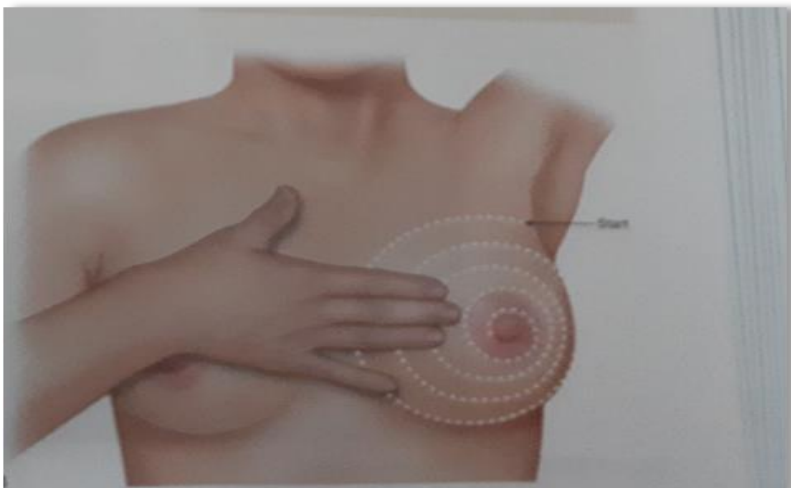

✓ Methods for Breast Palpation

- The vertical strip method for palpation of breast.
- The concentric circle pattern for palpation of the breast

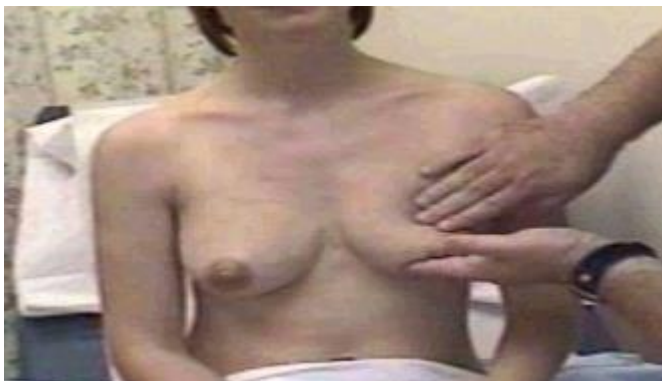

A. THE VERTICAL STRIP METHOD FOR PALPATION OF THE BREAST



B. THE CONCENTRIC CIRCLE PATTERN FOR PALPATION OF THE BREAST

- The following landmarks are used to be sure the entire breast is assessed:
 - ✓ down the midaxillary line, across the inframmary ridge at the fifth or sixth rib, up at the lateral edge of the sternum, across the clavicle, and back to the midaxillary.
- As each area is examined, three levels of pressure should be applied in sequence. These are:
 - ✓ light for subcutaneous tissue
 - ✓ medium at the midlevel tissues and
 - ✓ deep to the chest wall.
- Pressure is adapted according to the size, shape and consistency of the breast tissue. Additionally, pressure will vary in relation to breast size and the presence of breast implants. Implants are placed behind breast tissue; therefore, the steps for breast examination are the same as for palpation of breasts in women without implants.
- In female patients with pendulous breasts, palpate with one hand under the breast to support it and the other hand pushing against breast tissue in a downward motion.

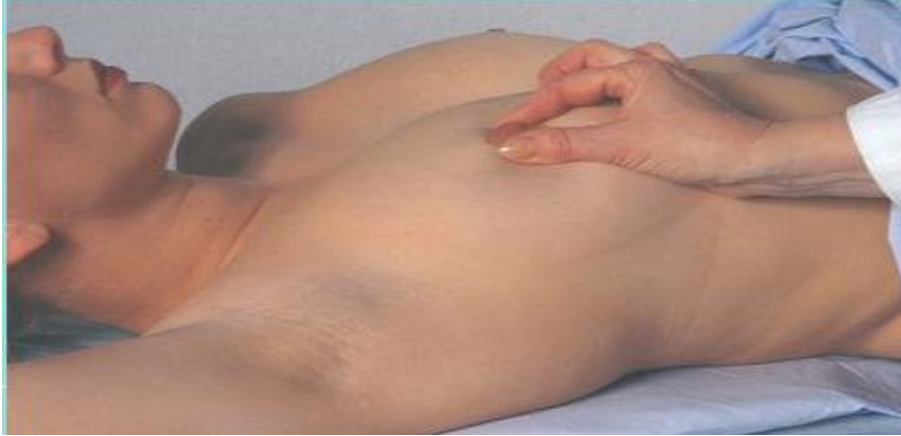

Palpating a pendulous breast

- In obese female with large breasts, palpation with two hands should be performed with the patient in the sitting and supine

positions.

5-Palpate the nipple and areola



Nipple is free of discharge, that it is nontender and that the areolae is free of masses.

- ✓ the area beneath and at the nipple should be palpated, not squeezed to observe for drainage .

Repeat steps 1 through 5 on the other breast.

B- Examination of the Axillae:

1. Instruct the patient.

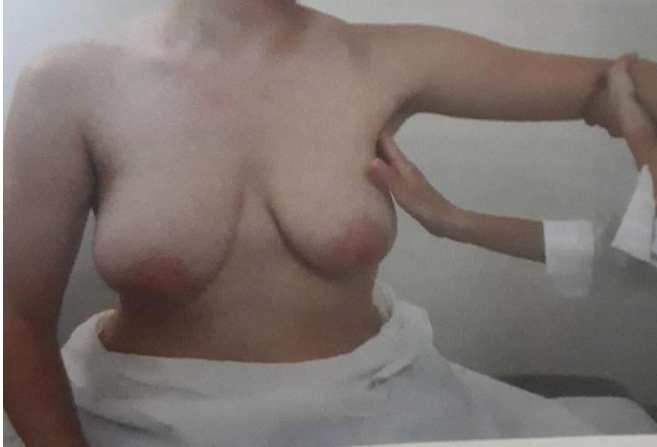- Explain to the patient that you will examine the axillae by looking and palpating.
- Explain that relaxation will make the examination more comfortable.
- Tell the patient to inform you of any discomfort.

2. Position the patient.

- Ask the patient or assist the patient to assume a sitting position.
- Flex the arm at the elbow and support it on your arm.
- Note presence of axillary hair.
- With the palmar surface of your fingers, reach deep into the axilla.
- Gently palpate the anterior border of the axilla (anterior or subpectoral nodes), the central aspect

Axilla is free of redness, rashes, lumps or lesions.

along the rib cage (central nodes), the posterior border (subscapular/posterior nodes), and along the inner aspect of the upper arm (lateral nodes).





King Saud University
College of Nursing
Medical Surgical Department

NURS 221 HEALTH ASSESSMENT (Practical)
Performance Checklist

Breast and axilla assessment

Name of student _____

Student Number _____

The student nurse should be able to:

Performance Criteria	Competency Level			Comments
	Done Correctly	Done with Assistance	Not Done	
Inspection				
• Begin the examination with the patient in sitting with the both breast exposed.				
• Inspect the patient's size and symmetry of the breast.				
• Inspect for skin color.				
• Inspect for venous pattern.				
• Inspect for moles or other markings				
• Inspect the areolae.				
• Inspect the nipples.				
• Inspect with the patient's arms over the head.				
• Inspect with the patient's hands pressed against her waist .				
• Inspect with the patient leaning forward from the waist.				
Palpation				

<ul style="list-style-type: none"> • Position the patient 				
<ul style="list-style-type: none"> • Palpate skin texture. 				
<ul style="list-style-type: none"> • Palpate the breast <ul style="list-style-type: none"> - Vertical strip - Concentric circle pattern. - Pendulous breasts. 				
<ul style="list-style-type: none"> • Palpate the nipple and areolae. 				
<p><u>Examination of the axilla</u></p> <p><u>Inspection and palpation</u></p>				
<ul style="list-style-type: none"> • Inspect axillary skin for rashes or infection (sitting position) 				
<ul style="list-style-type: none"> • Palpate axillary lymph nodes. 				

Evaluated by: _____

Date Evaluated: _____

References

D' Amico, D. Health & Physical Assessment in Nursing, 3rd Ed. (2016). Pearson, Cloth.
 ISBN-10: 0133876403 • ISBN-13: 9780133876406