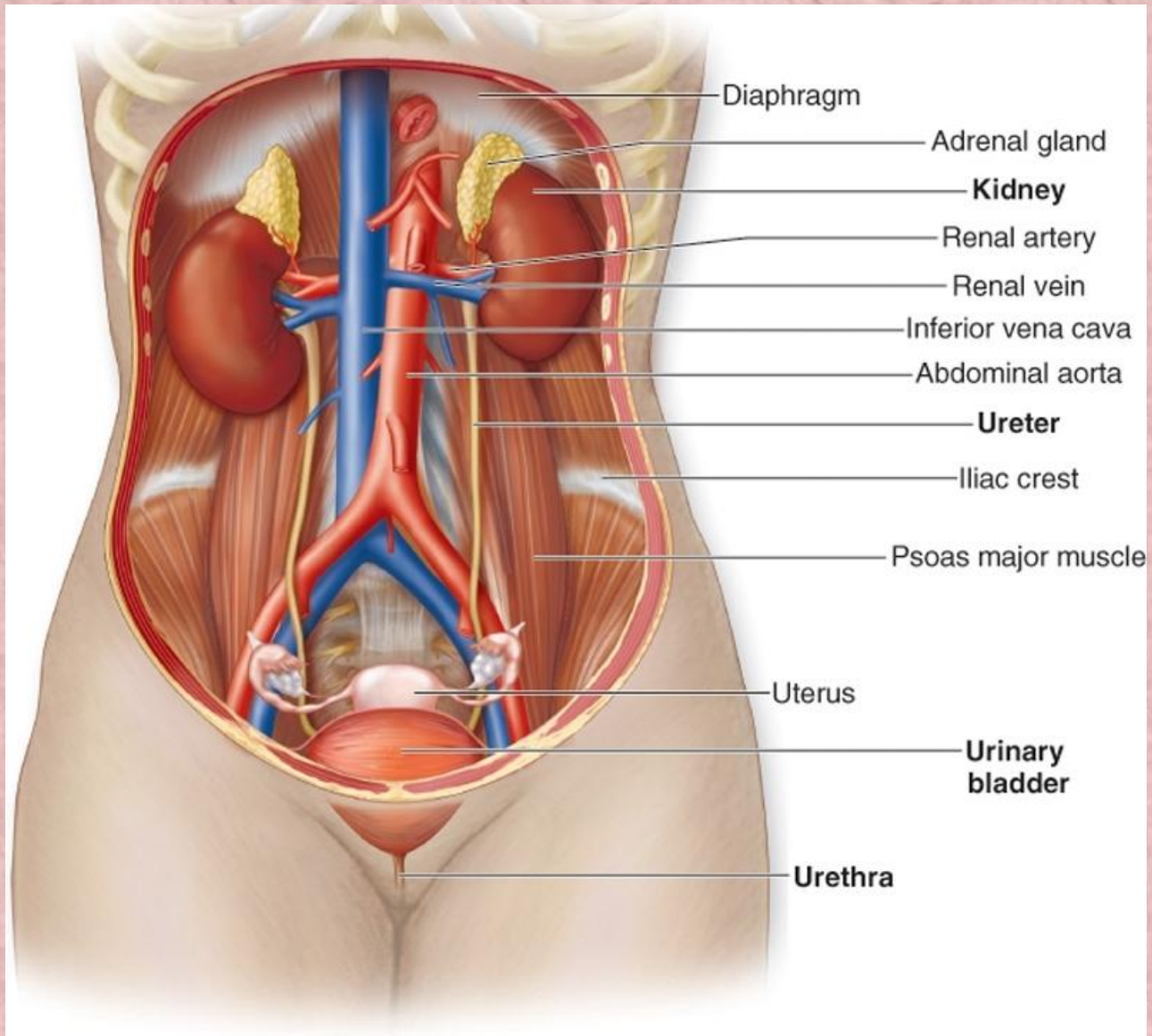
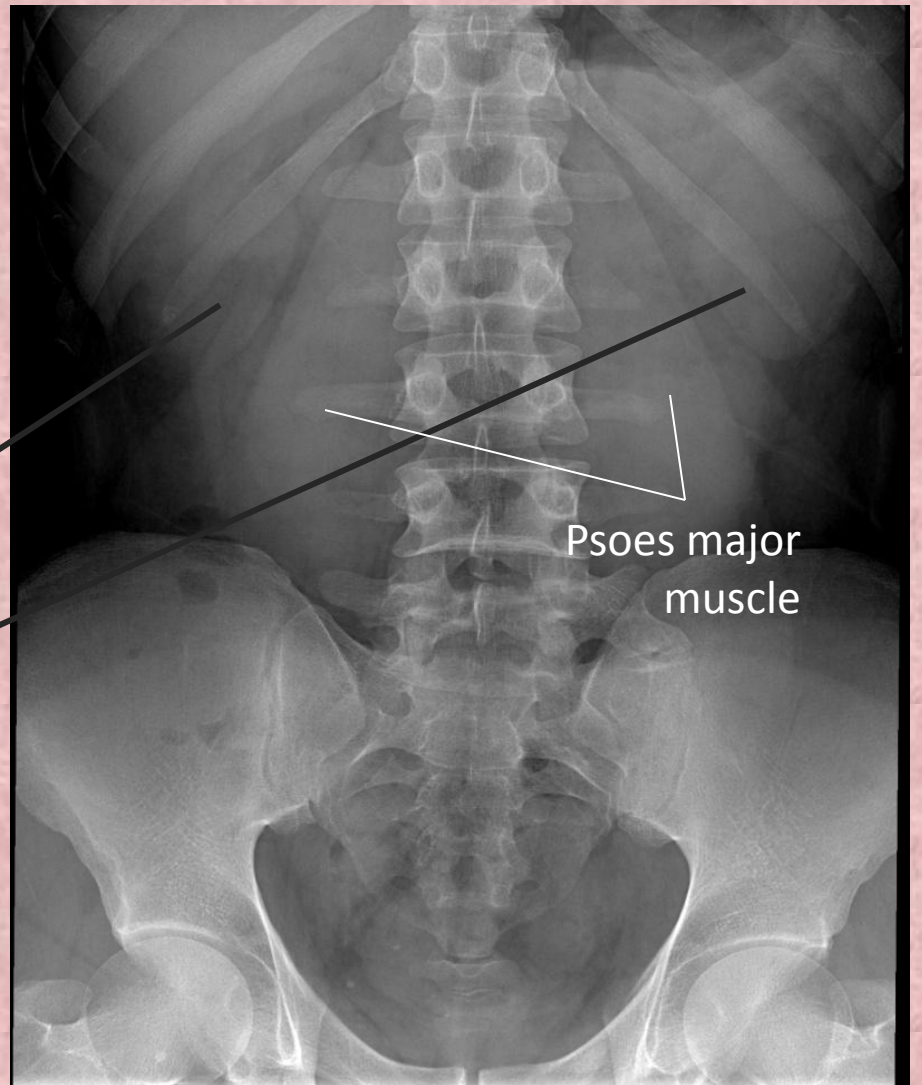
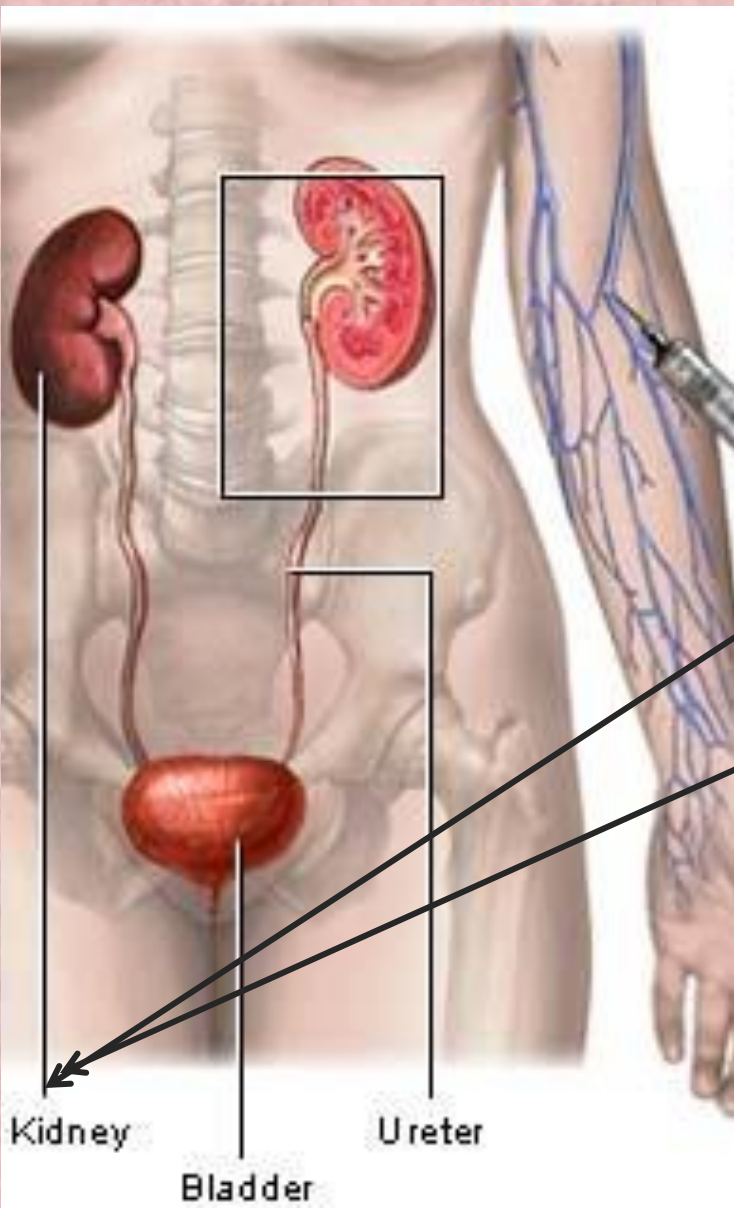
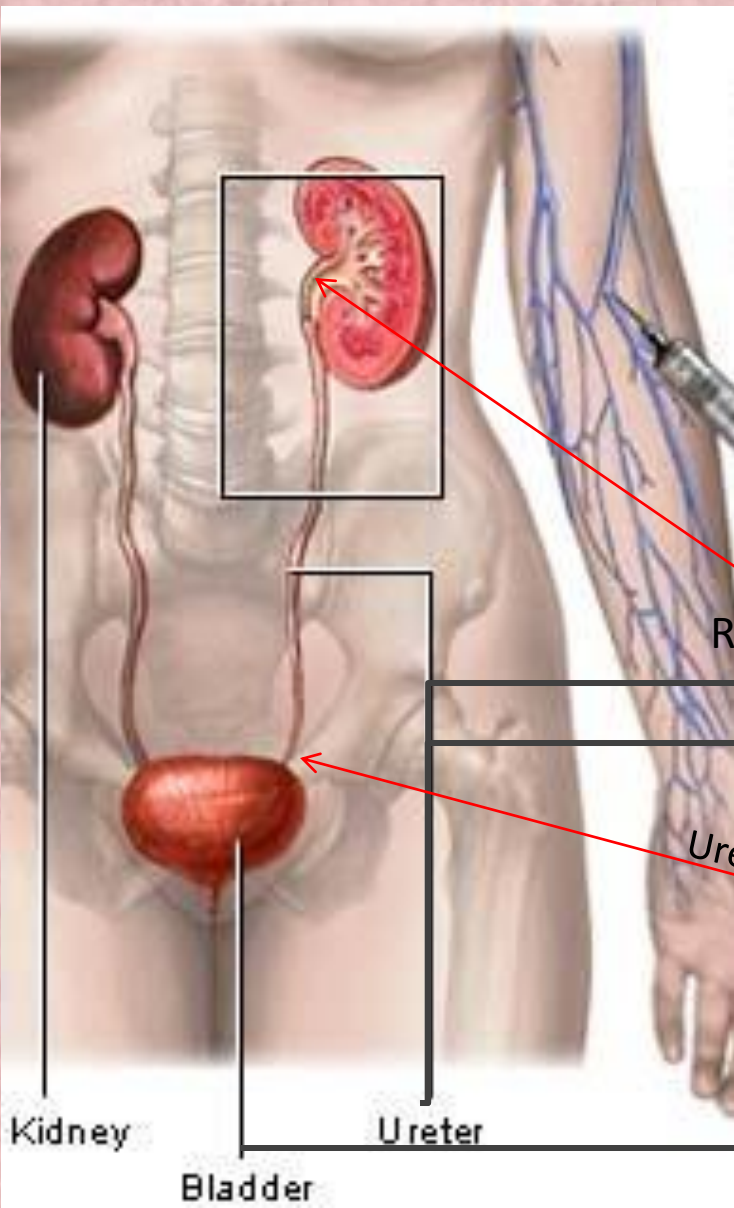


Urinary system anatomy

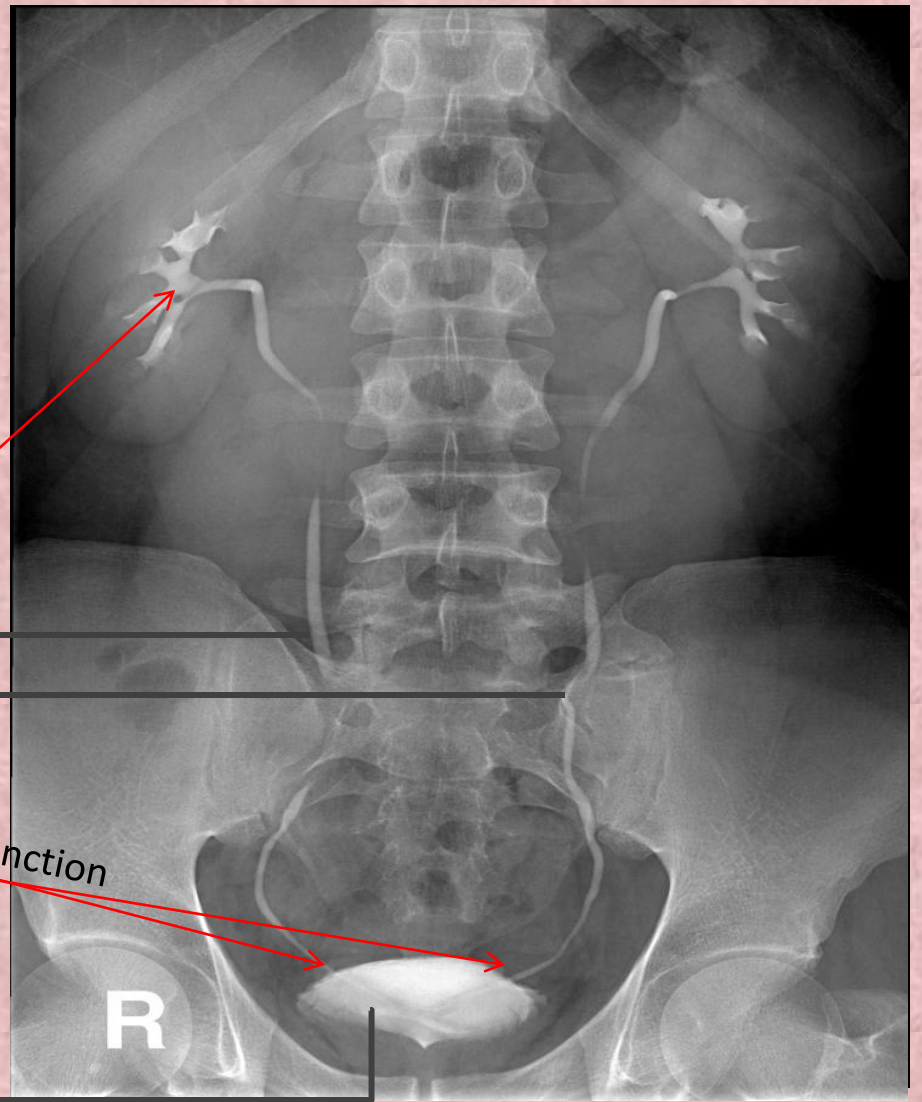


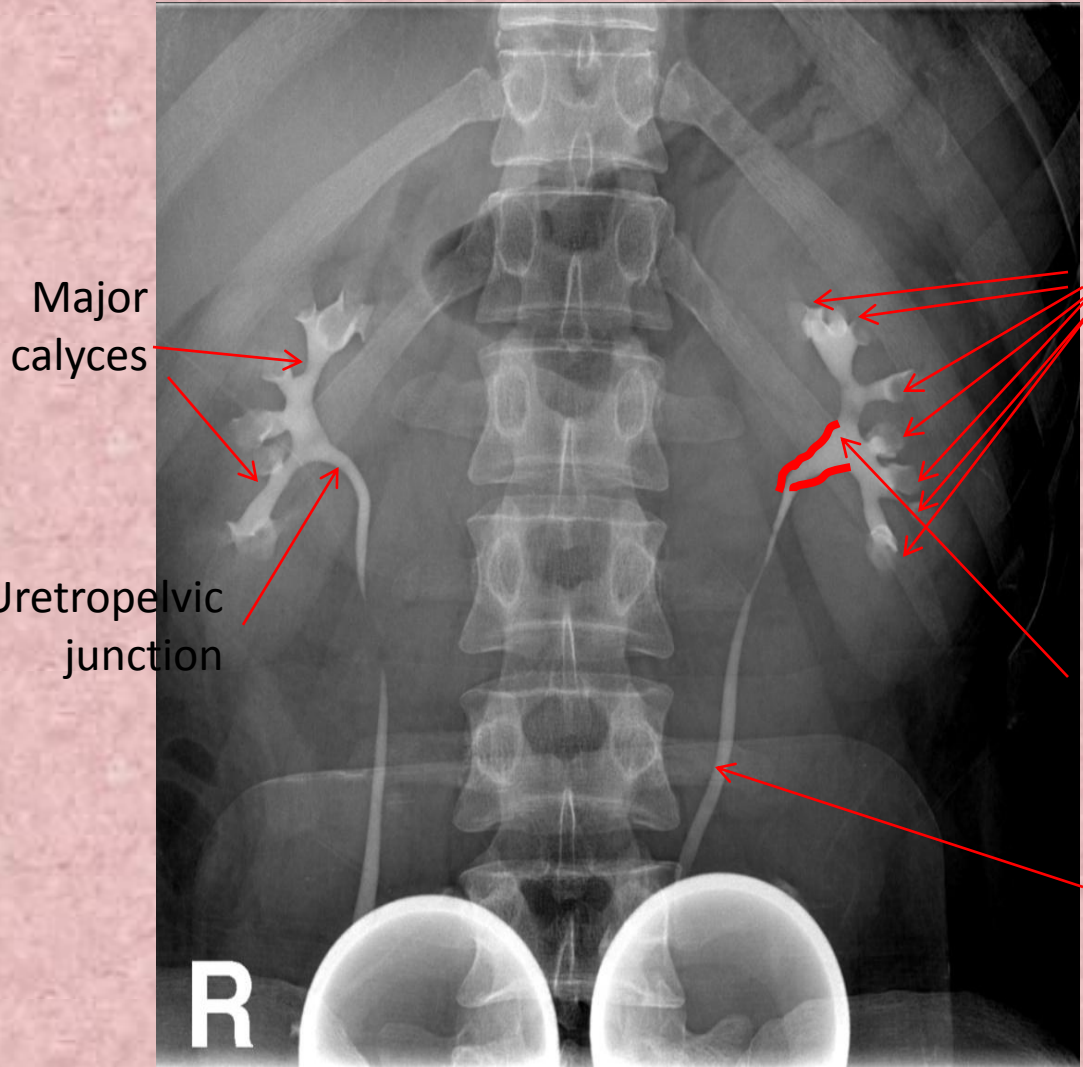




Renal pelvis

Uretrovesical junction

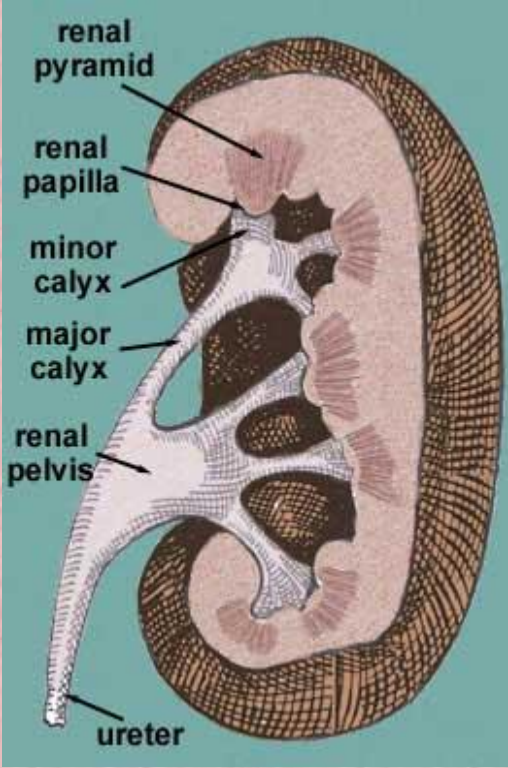


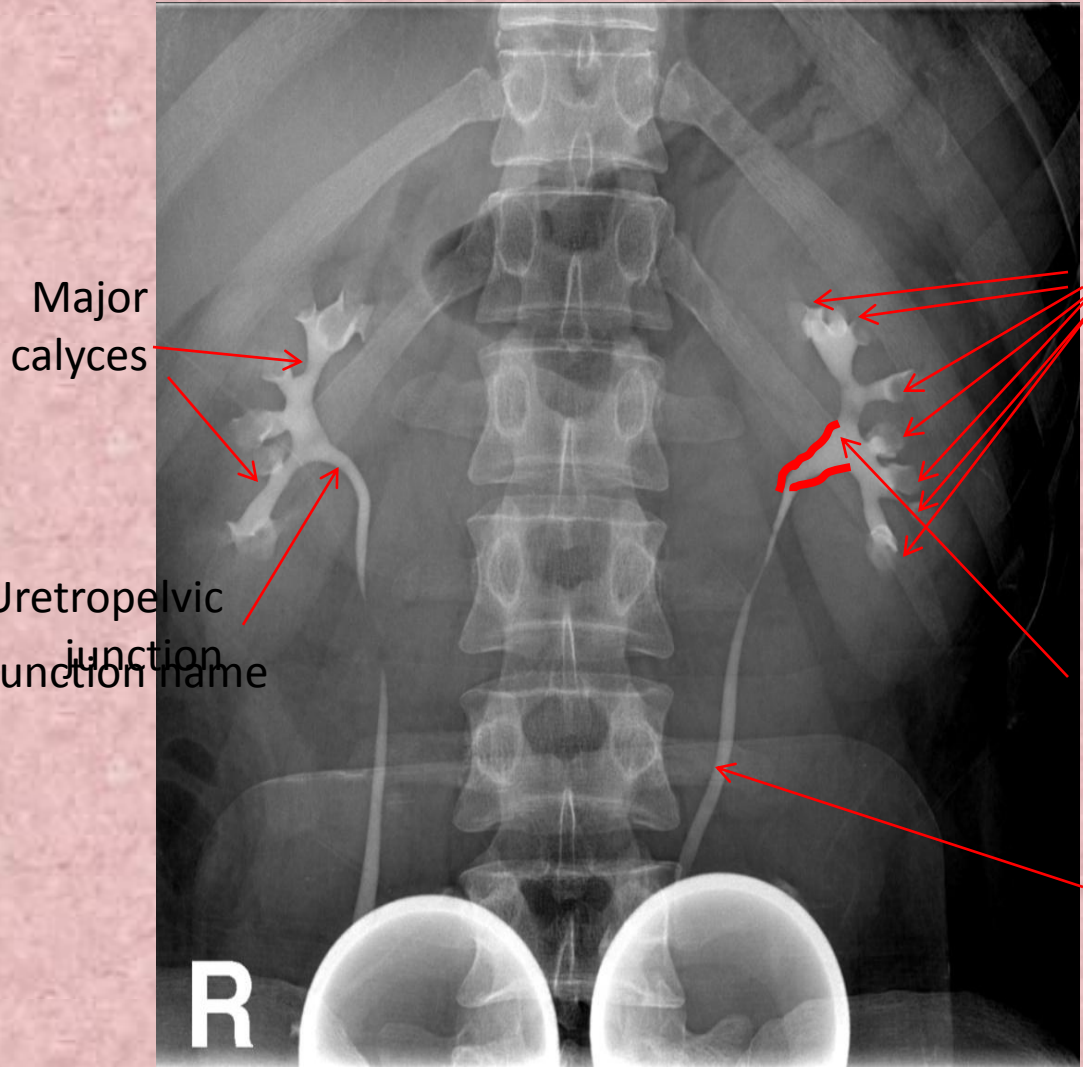


Minor calyces

Renal pelvis

urieter

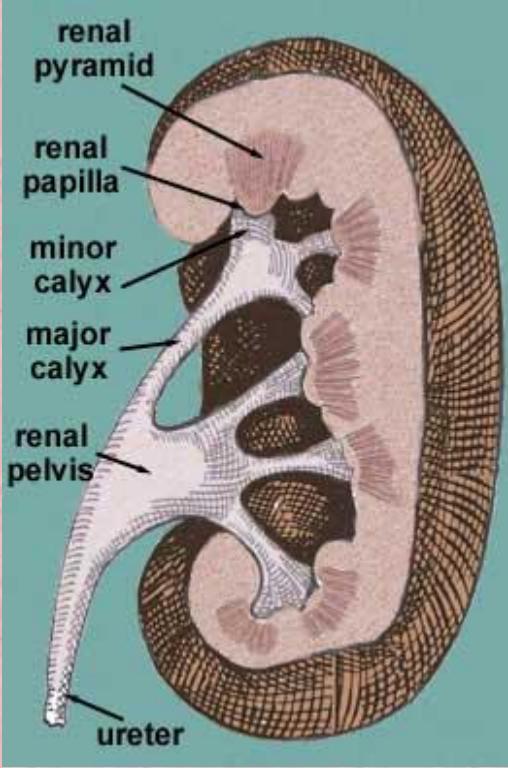




Minor calyces

Renal pelvis

urieter



Bladder

