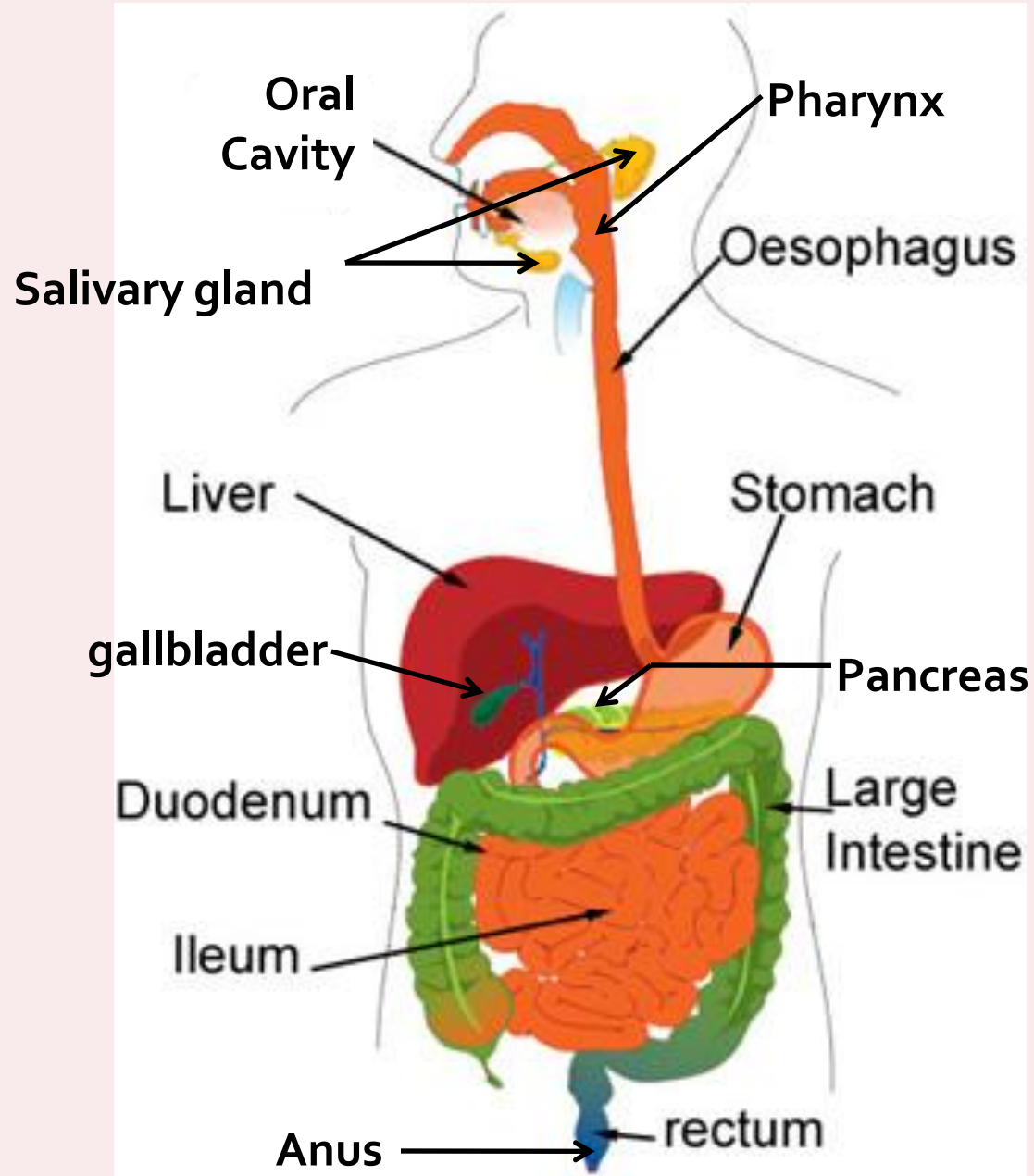




DIGESTIVE SYSTEM

Digestive System

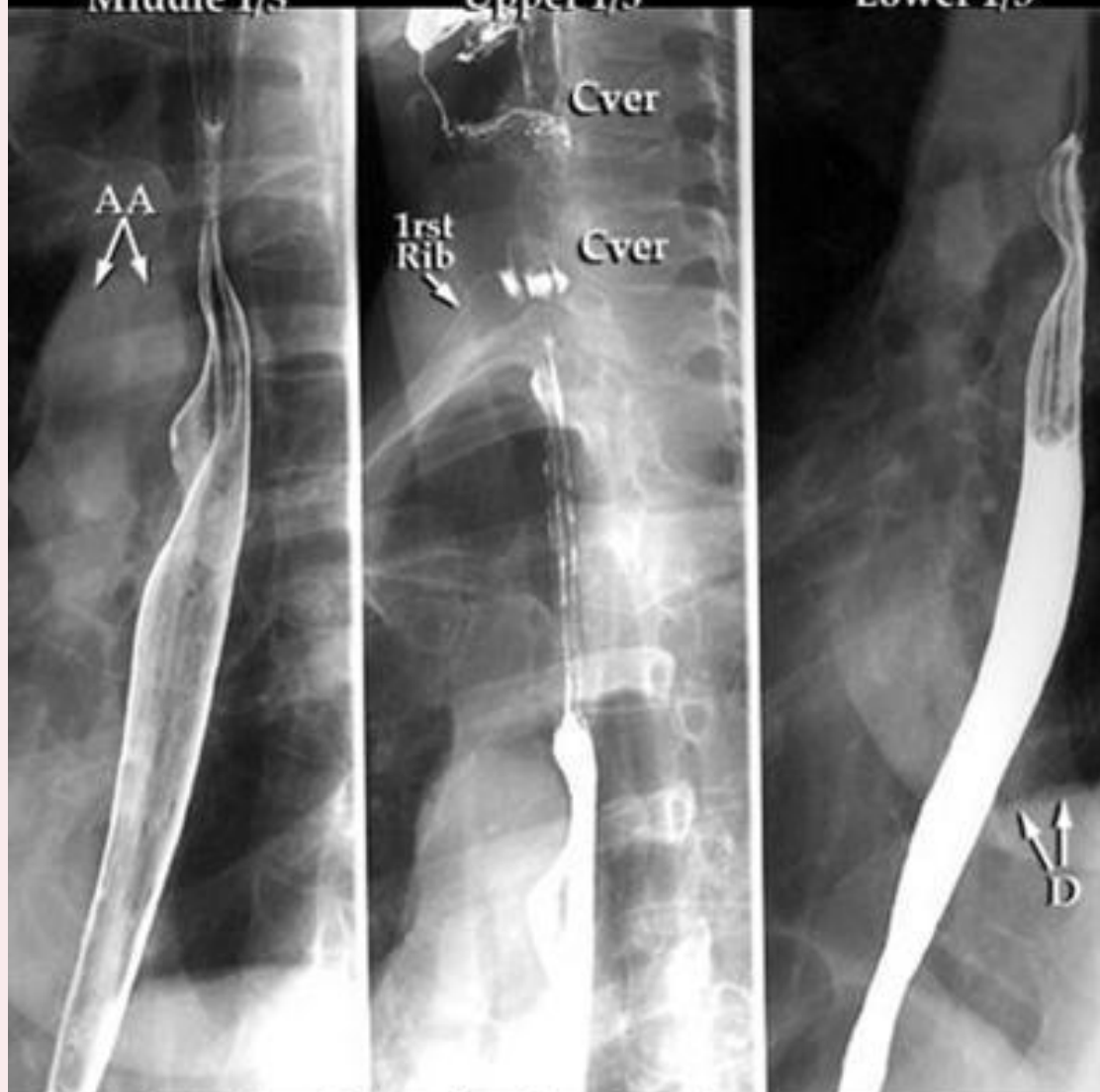

Esophogram

Middle 1/3

Upper 1/3

Lower 1/3

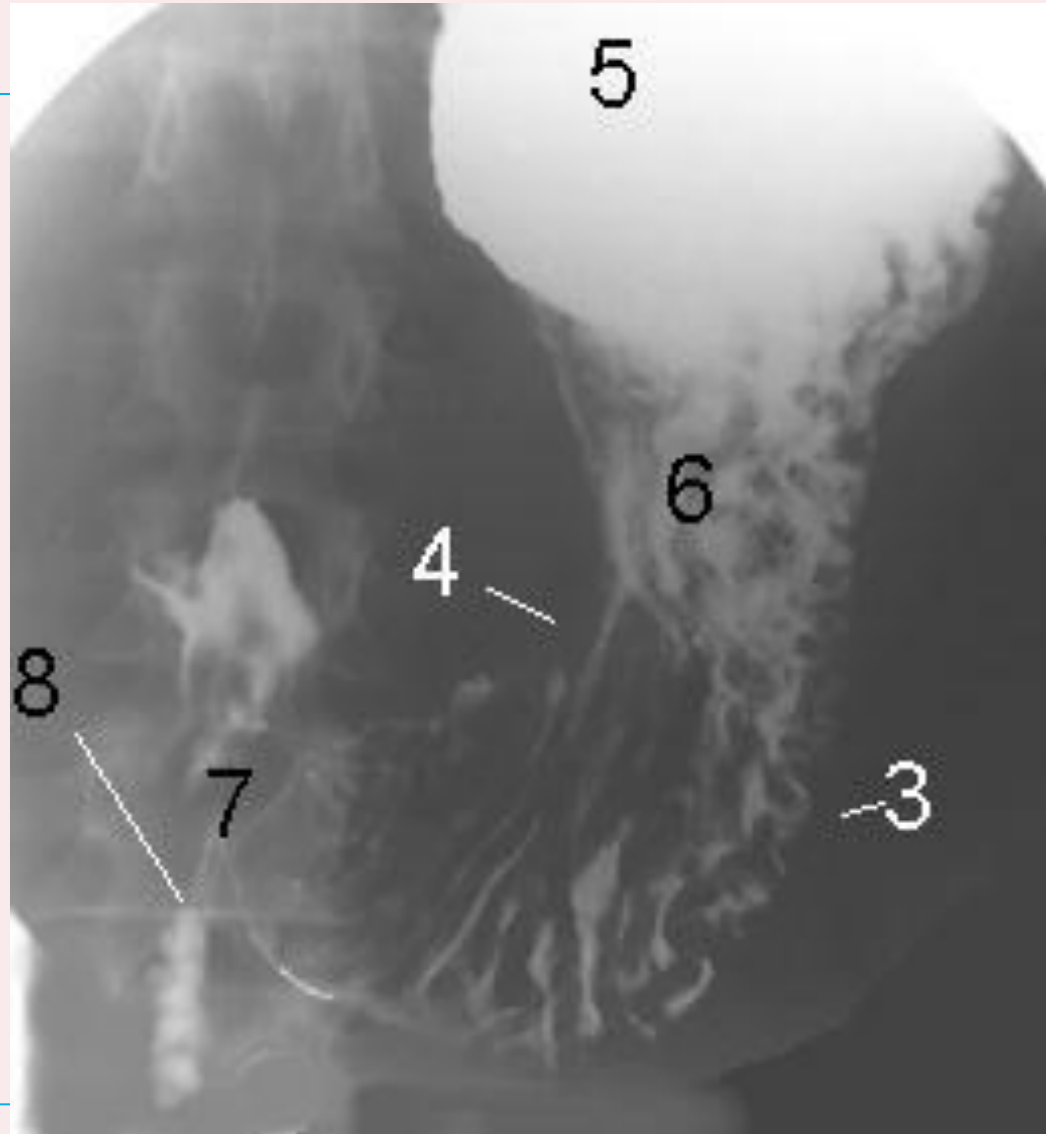


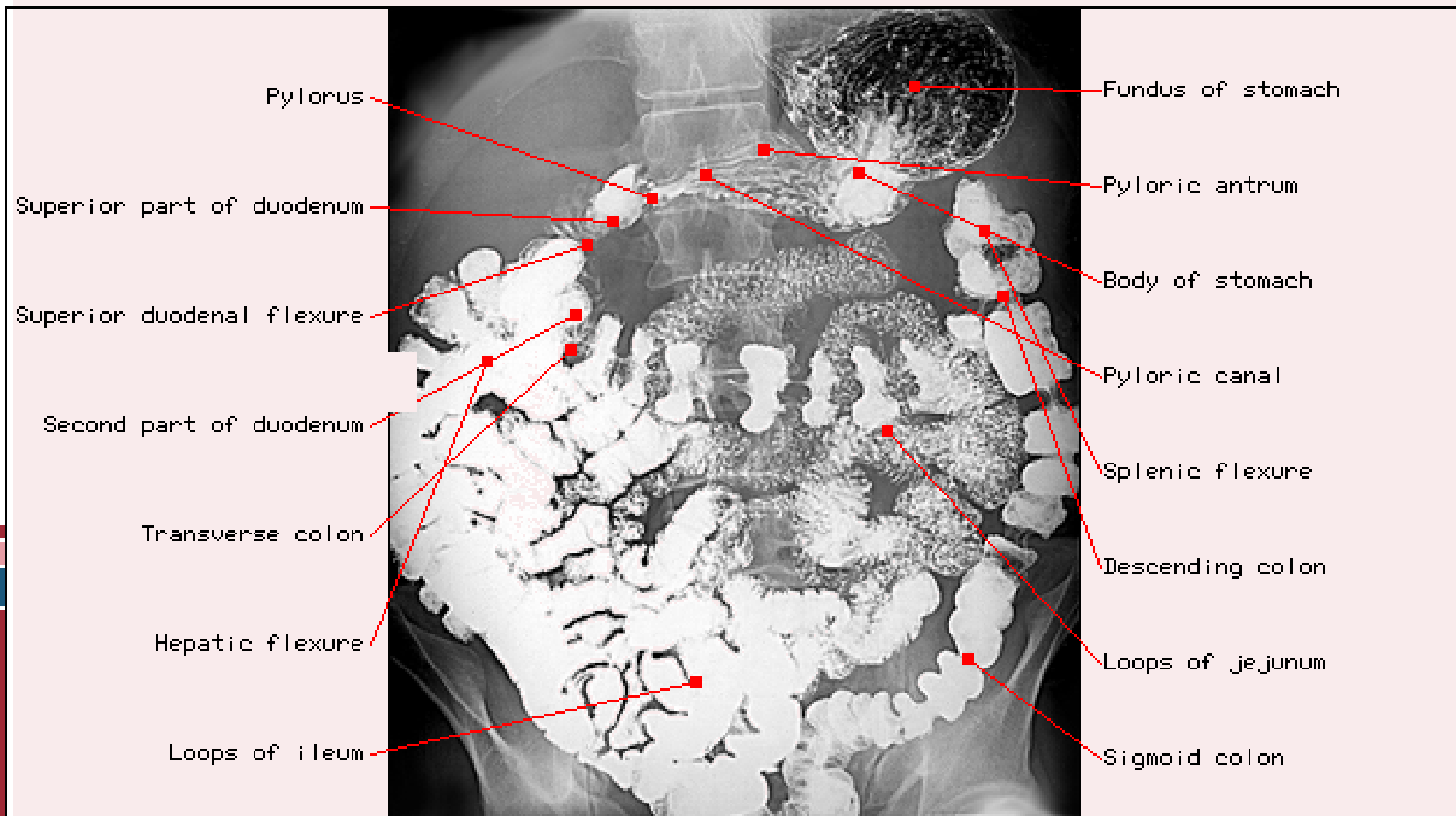
AA=Aortic Arch (note indentation of esophagus)

Cver=Cervical Vertebra

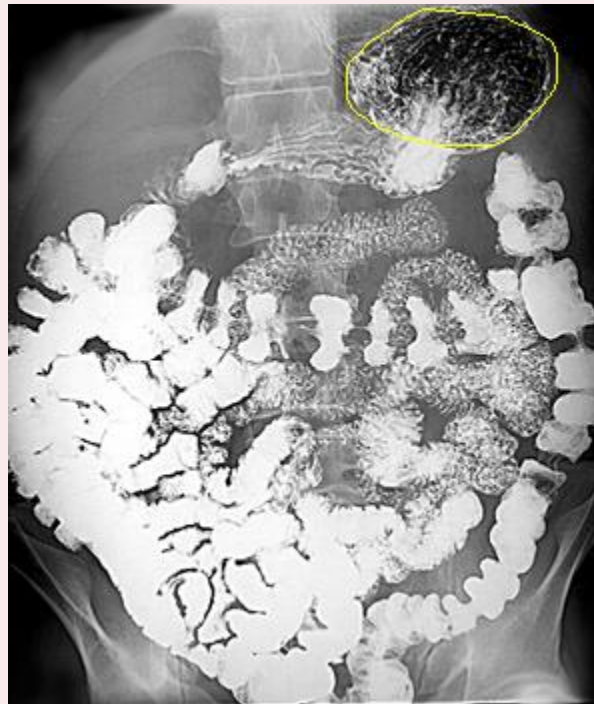
D=Diaphragm

- greater curvature (3)
- lesser curvature (4)
- fundus (5)
- the body (6) of the stomach
- pyloric region (7)
- (8) second part of the duodenum

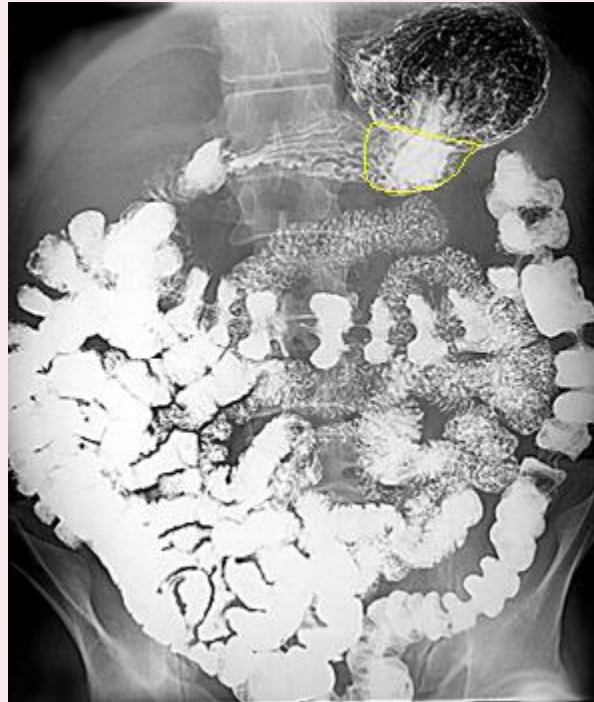



Fundus of stomach

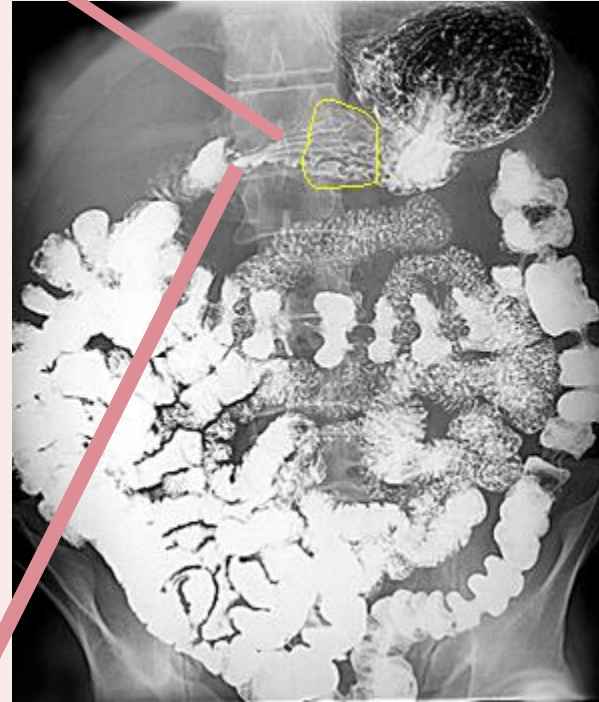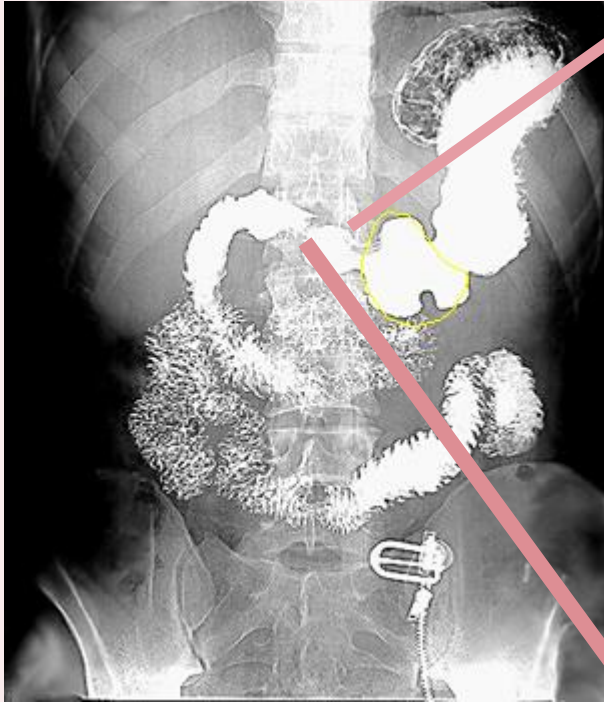


Body of stomach



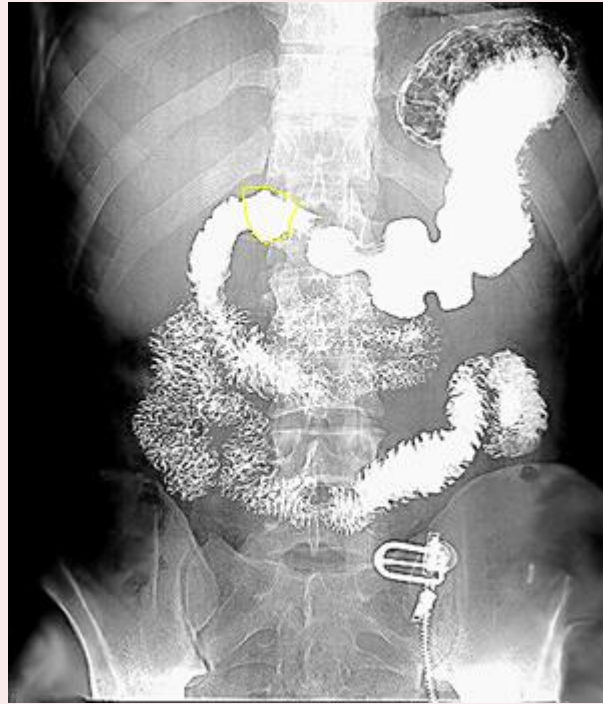
Pyloric antrum

Pyloric canal

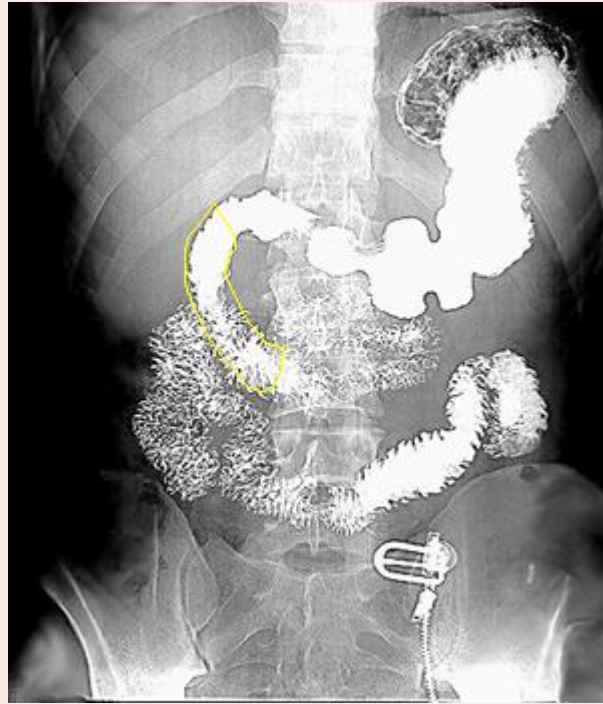


pylorus

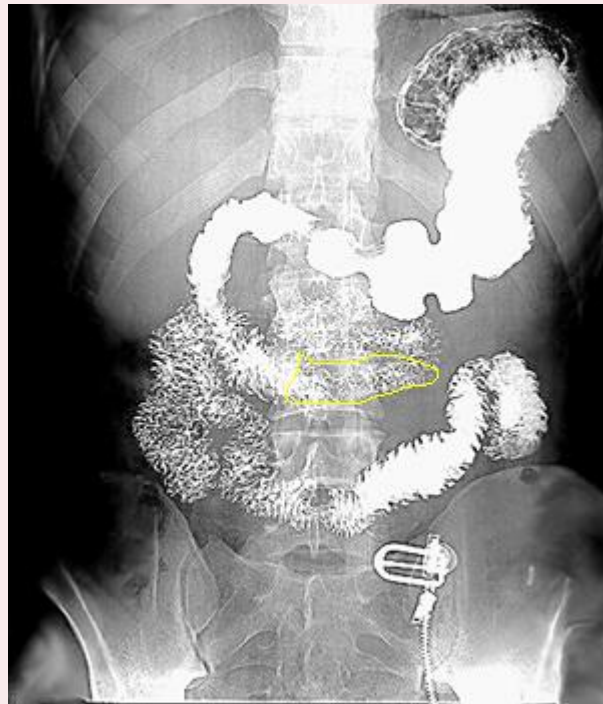
1st superior part of Duodenum)



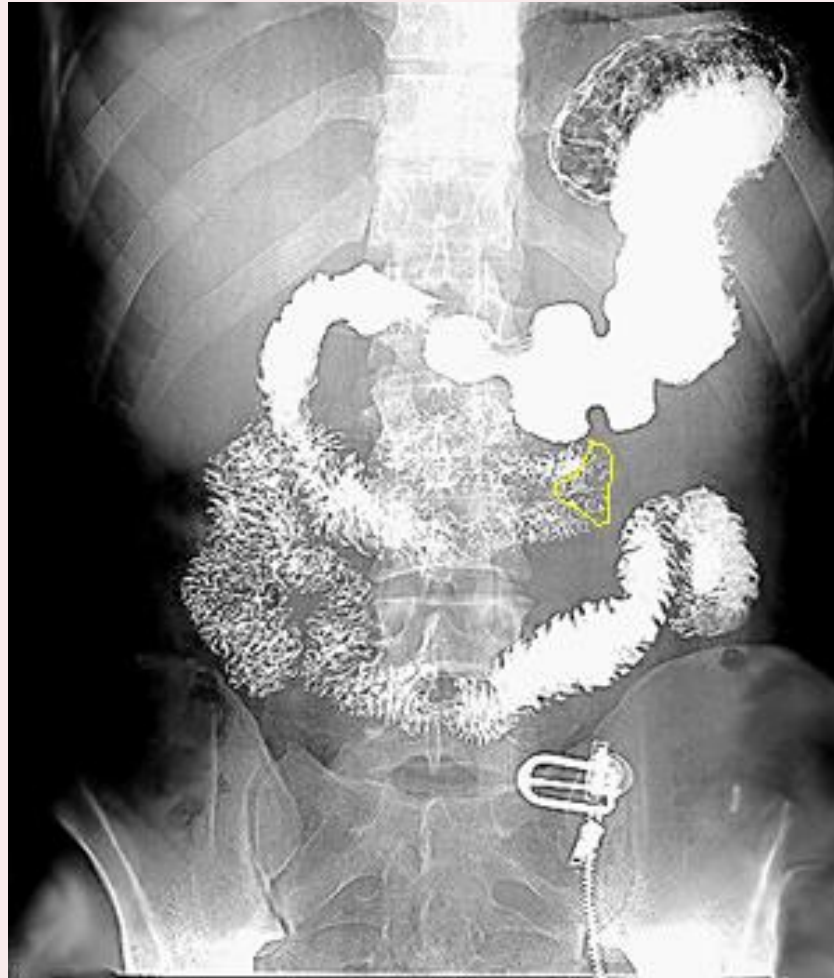
2nd (Descending part of duodenum)



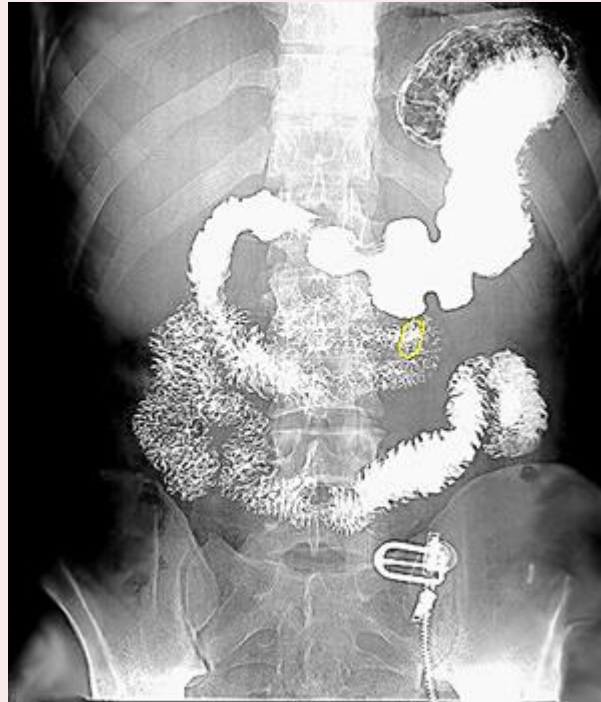
3rd (Horizontal part of duodenam)



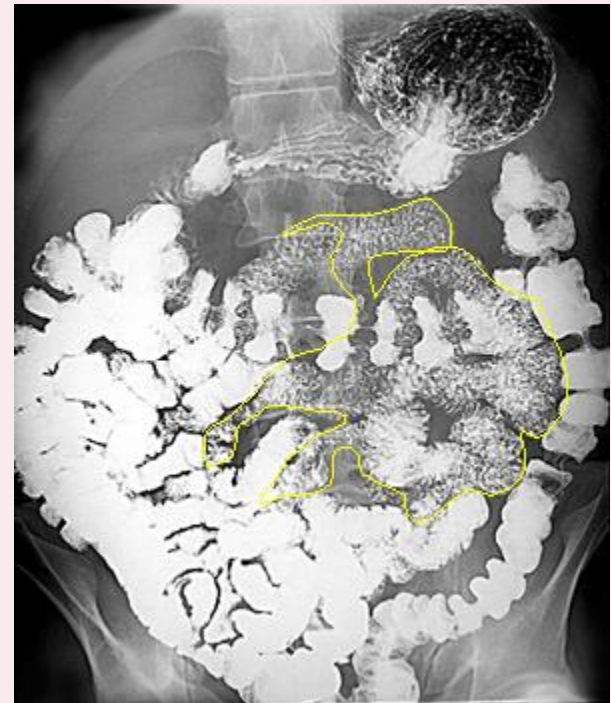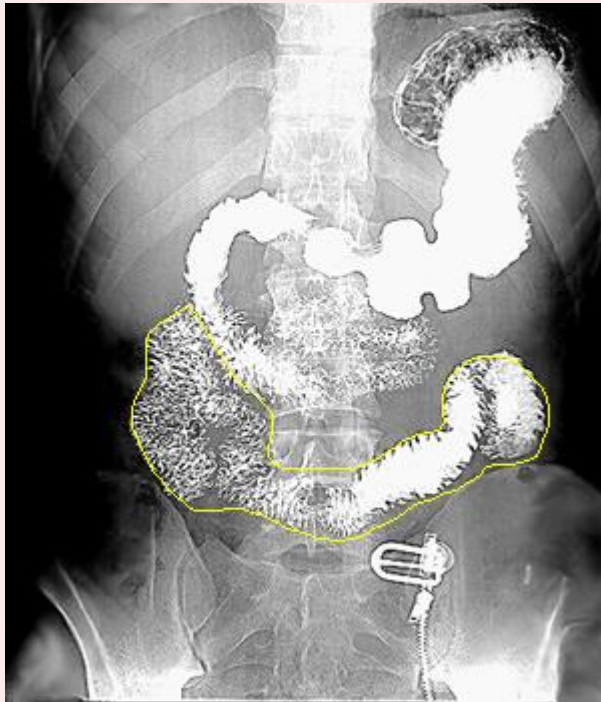
4th (Ascending part of duodenum)



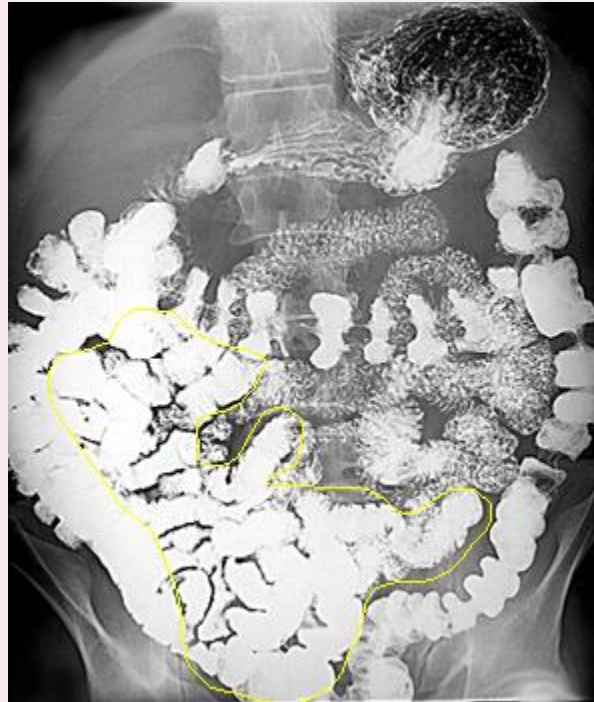Duodenojejunal junction



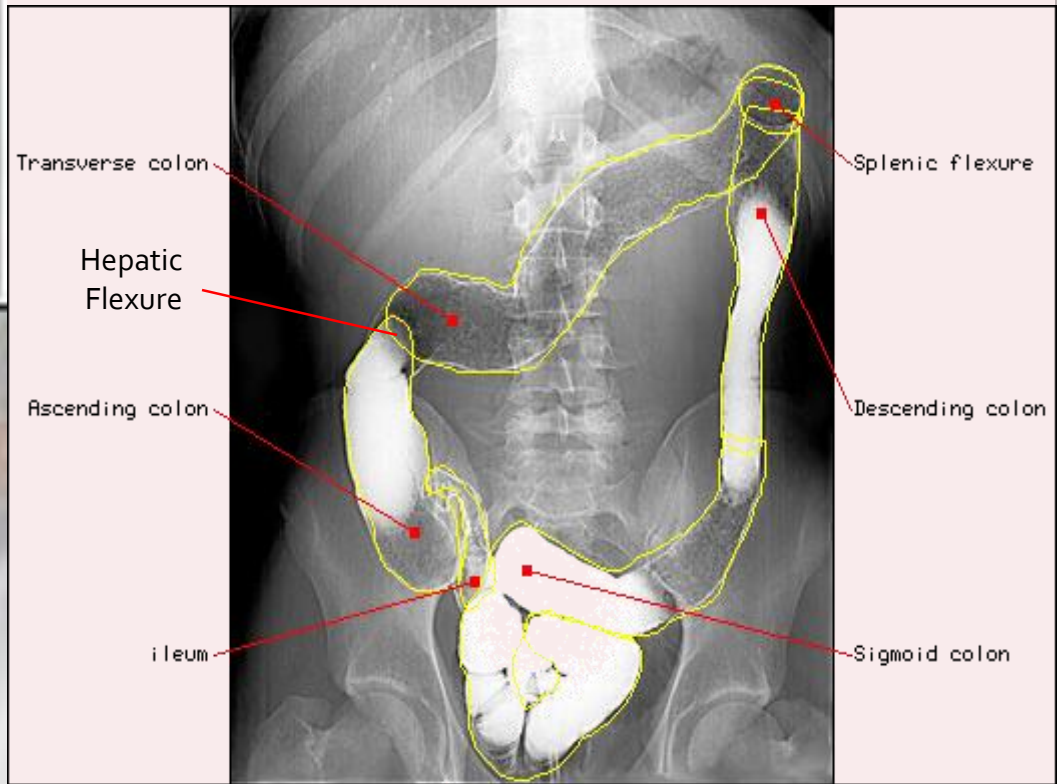
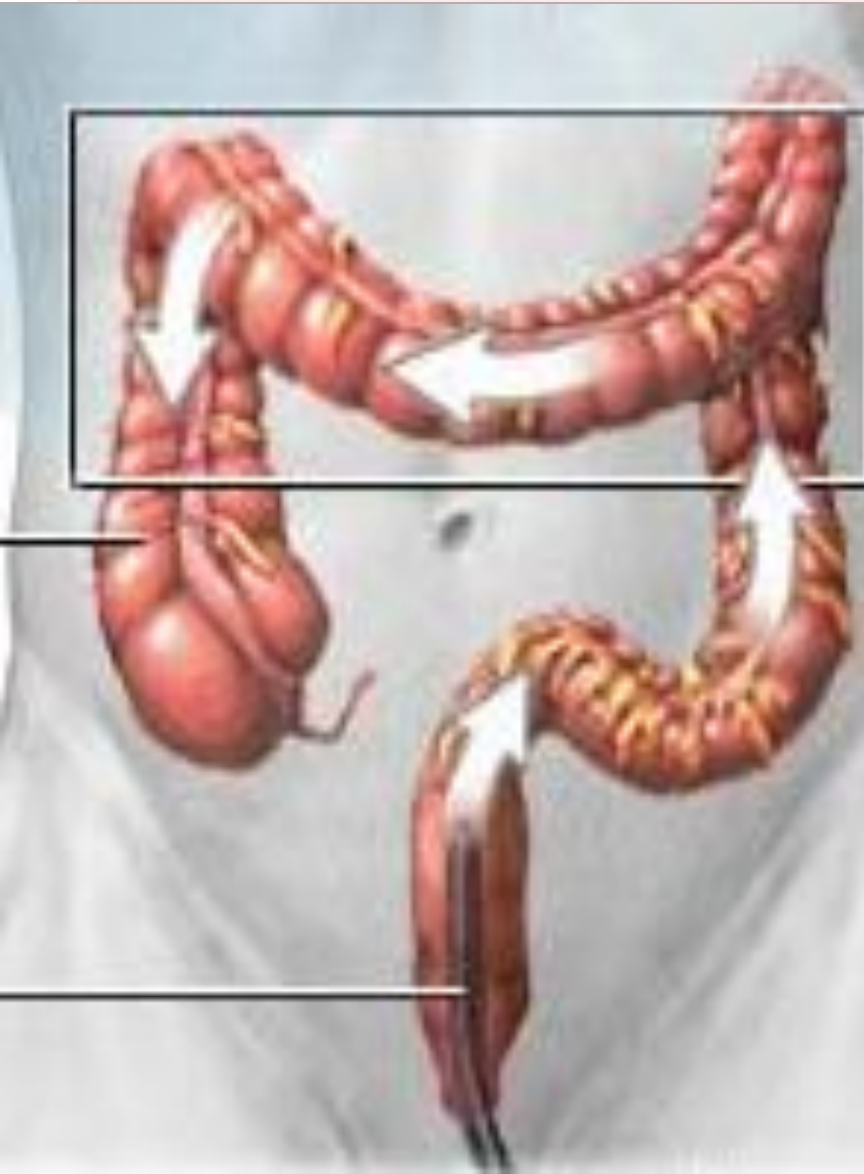Jejunum



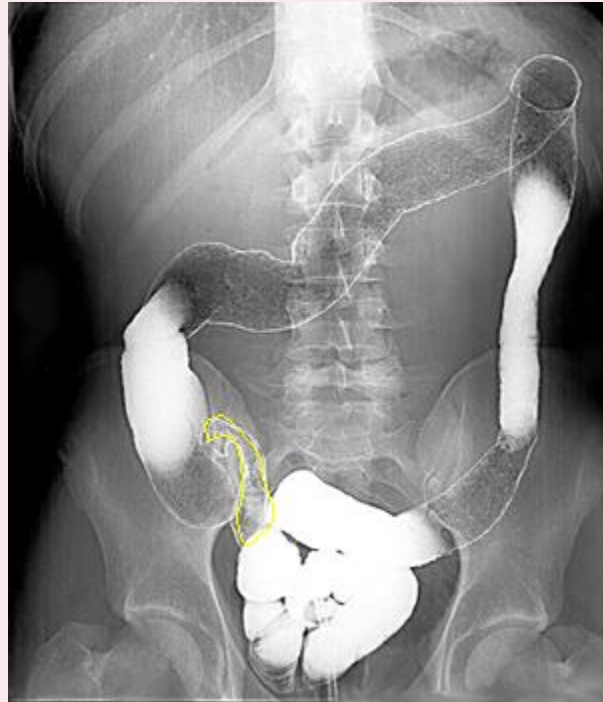
Ileum



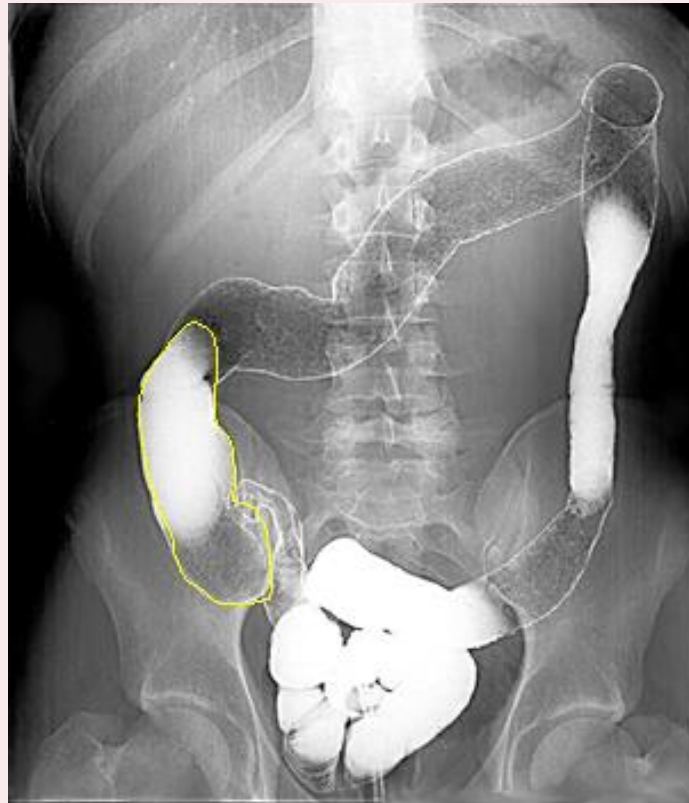
Barium Enema



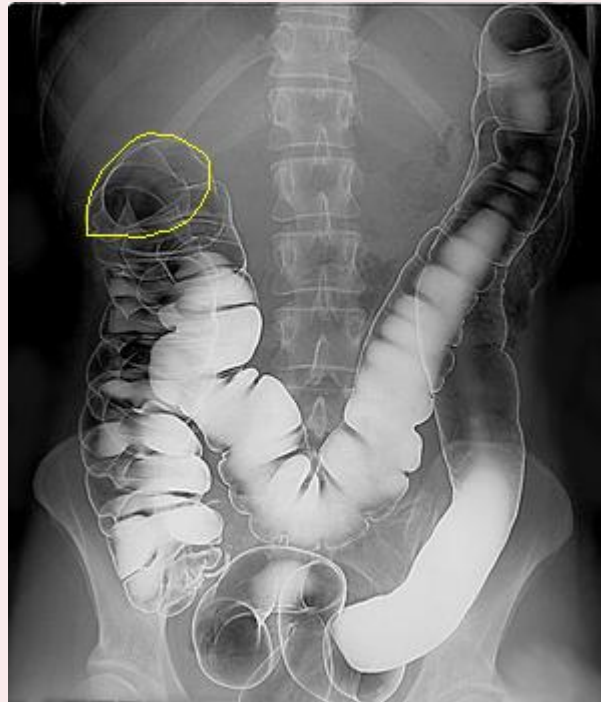
Ileum



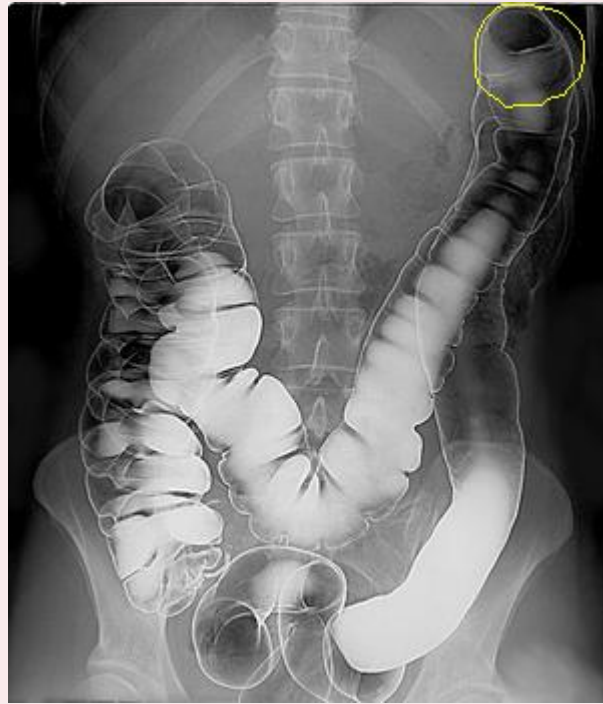
Ascending colon



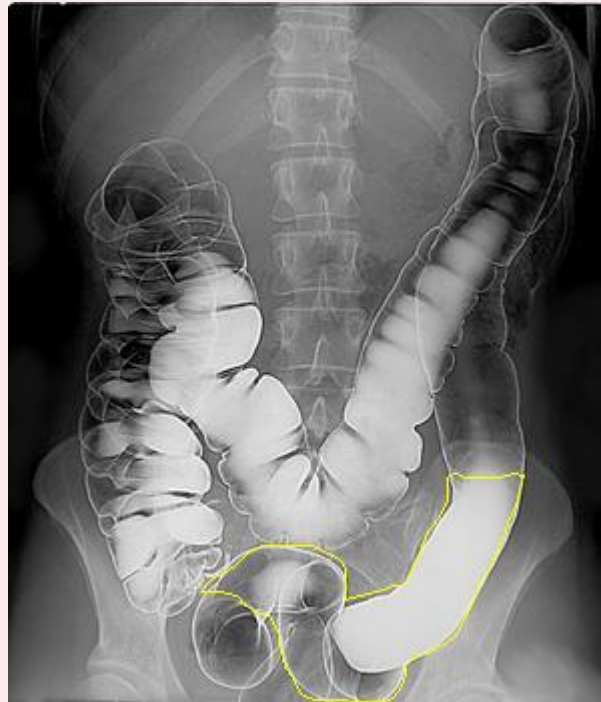Hepatic flexure

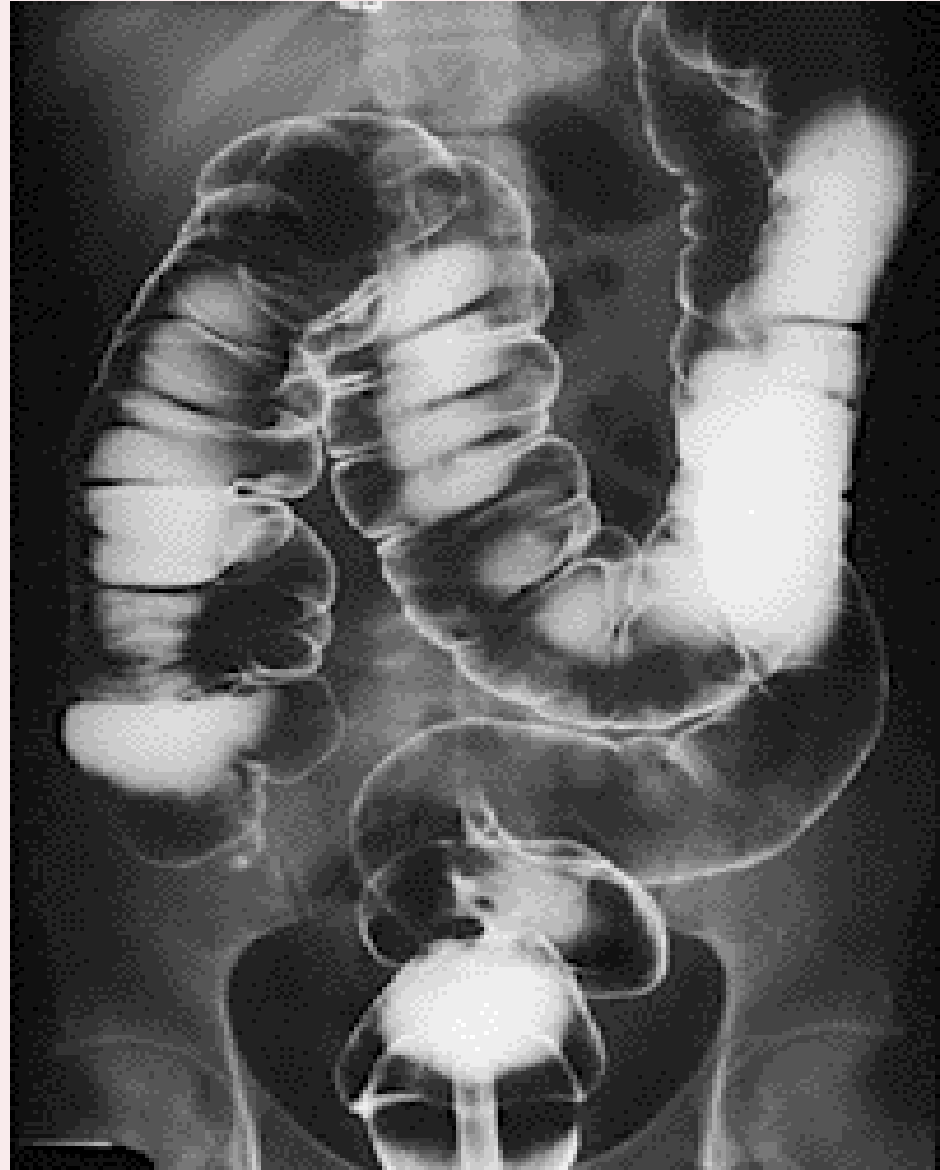
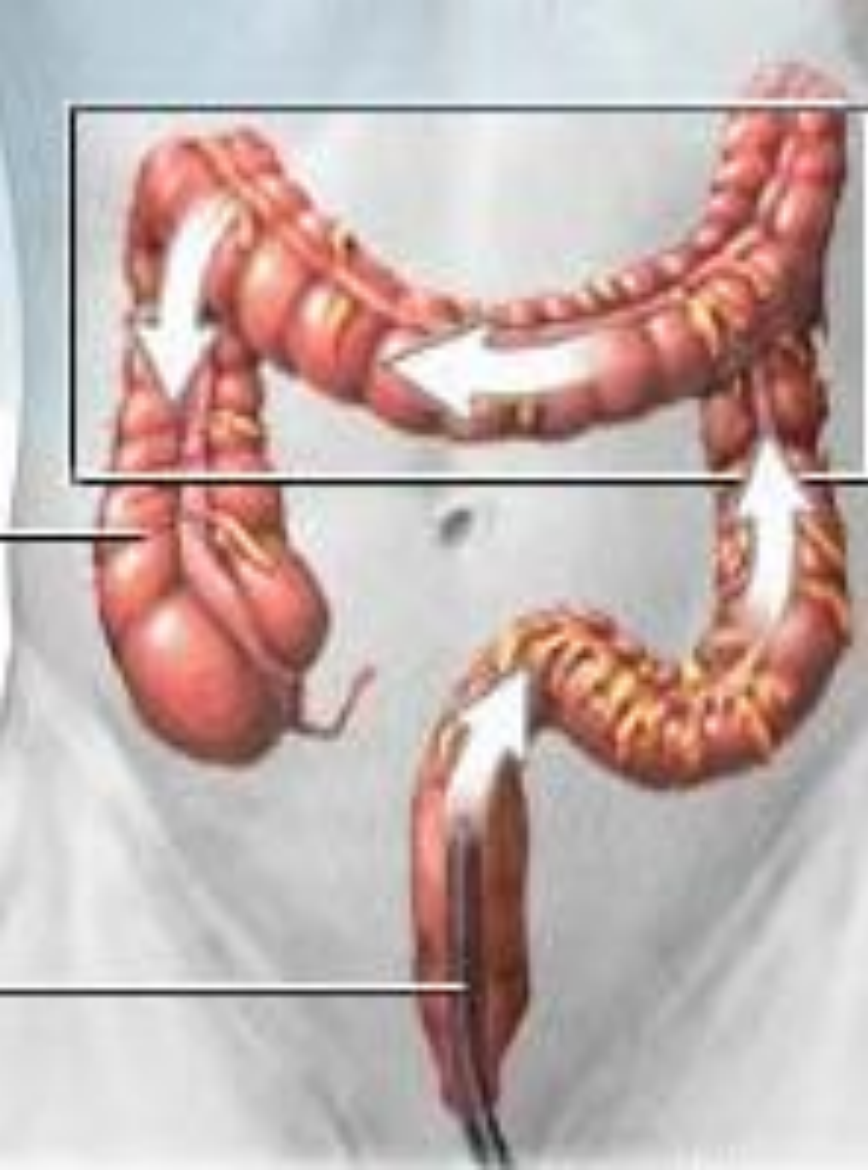

Splenic flexure



Sigmoid







THANK YOU

