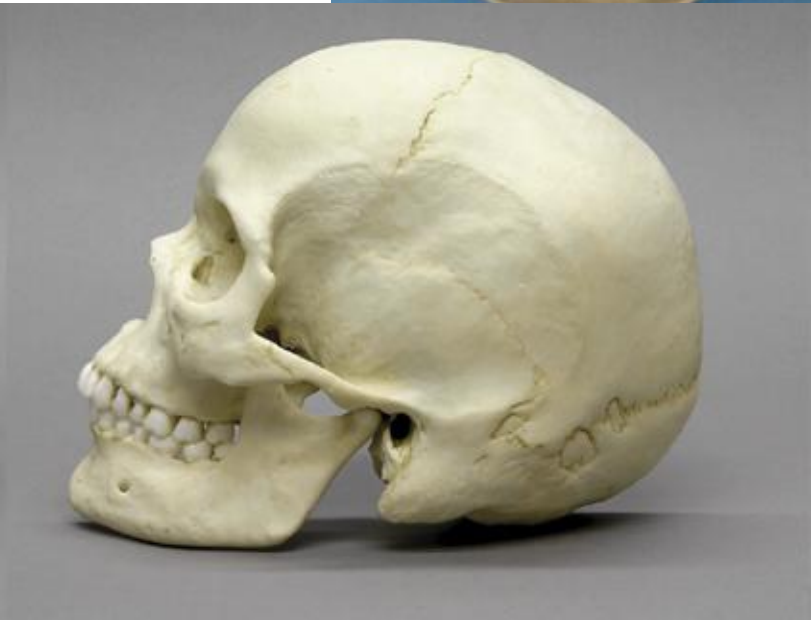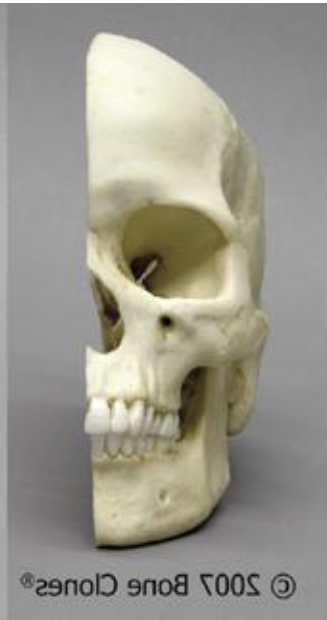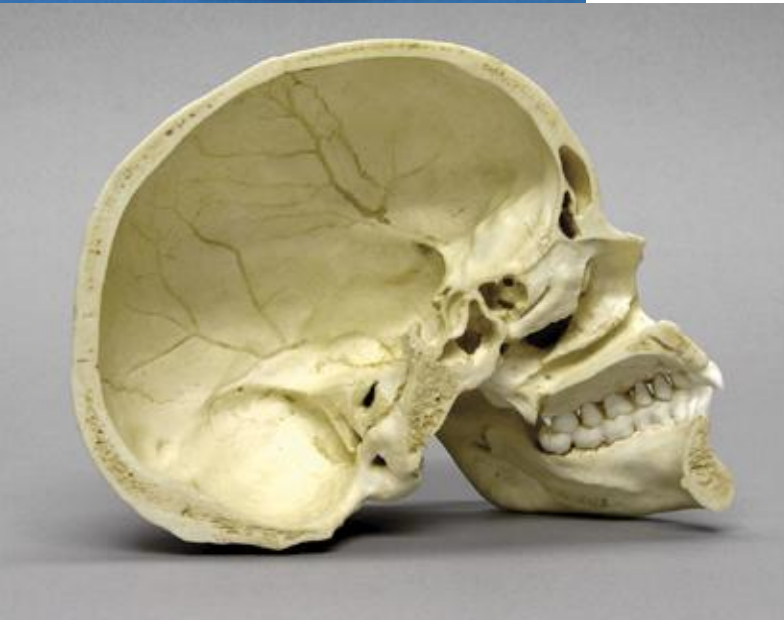
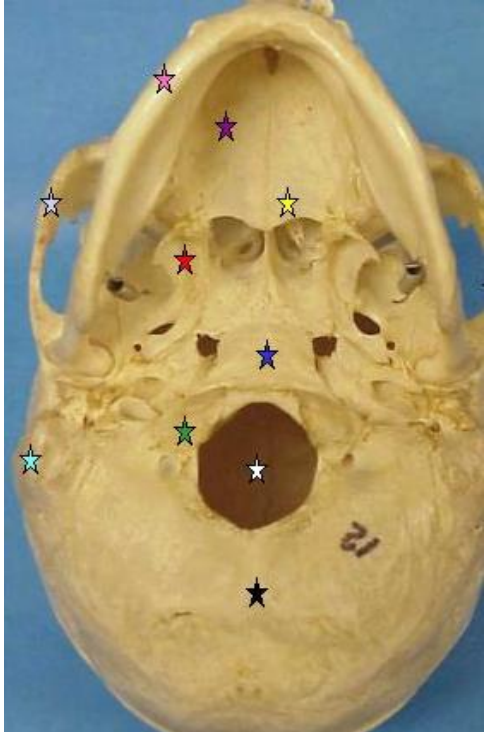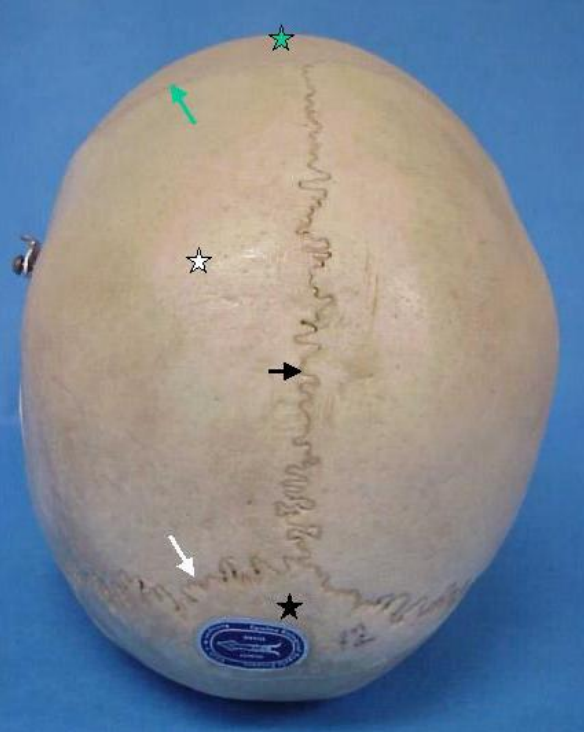


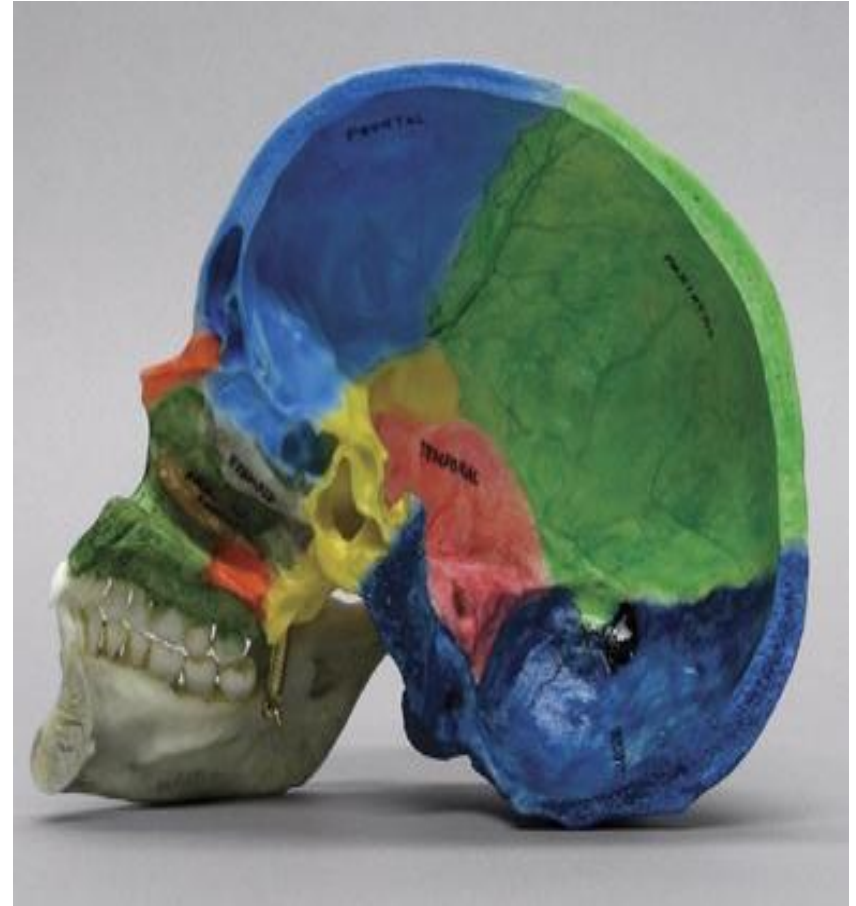
# skull



# skull

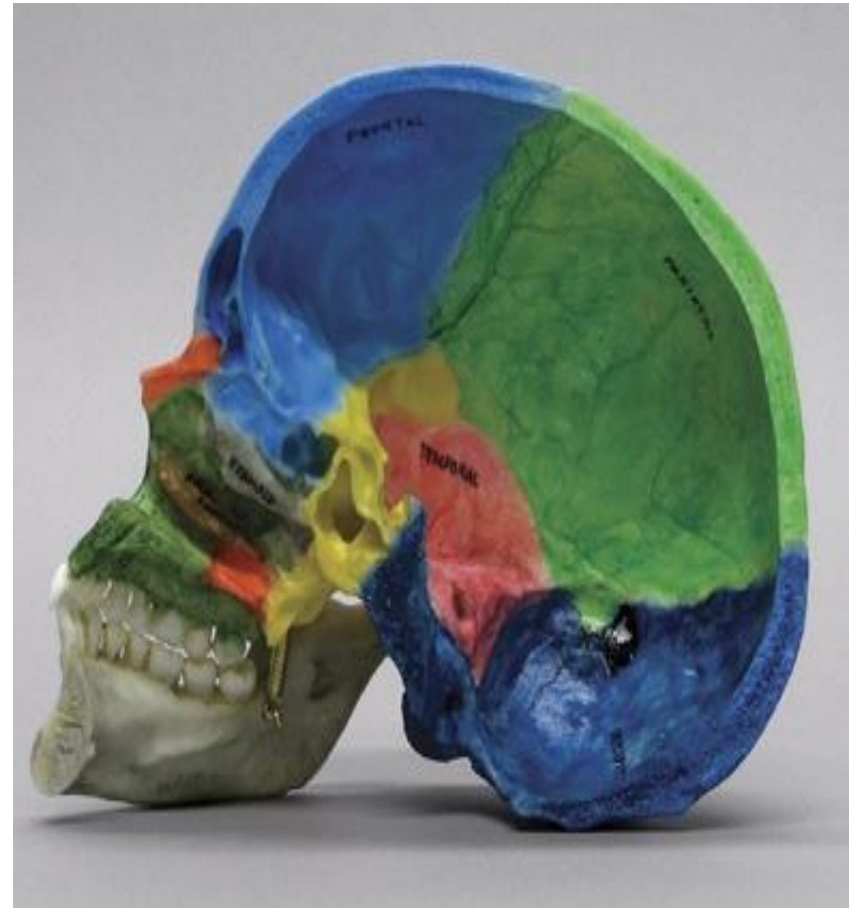
The skull is divided into :

- 8 Cranial Bones .
- 14 Facial Bones .



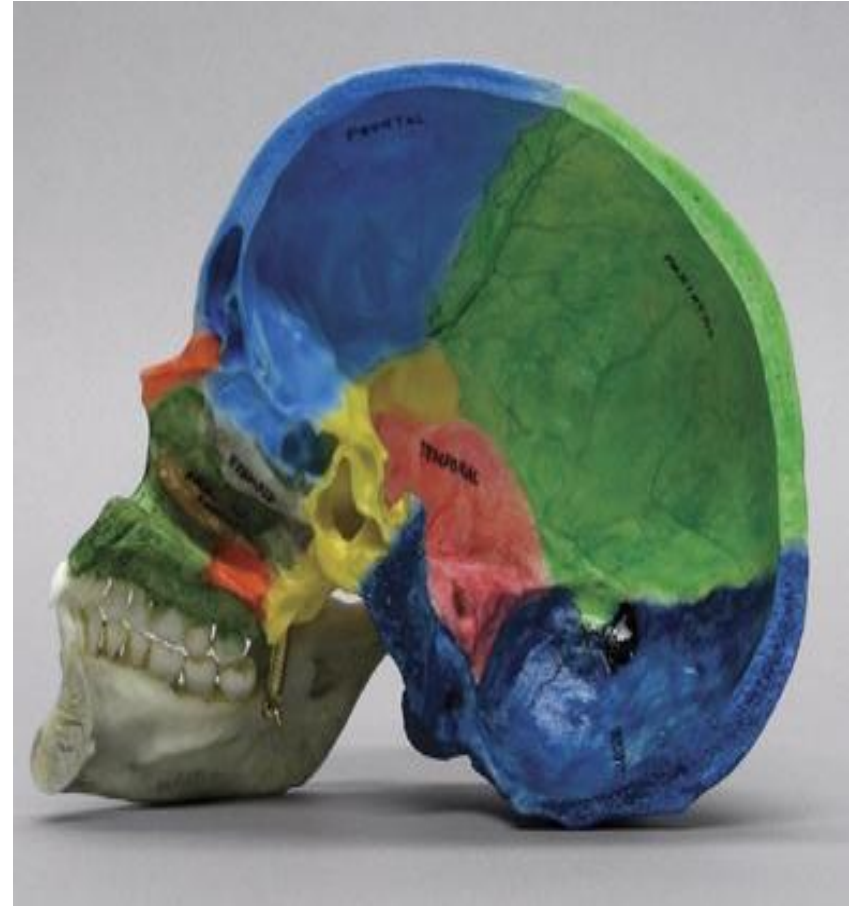
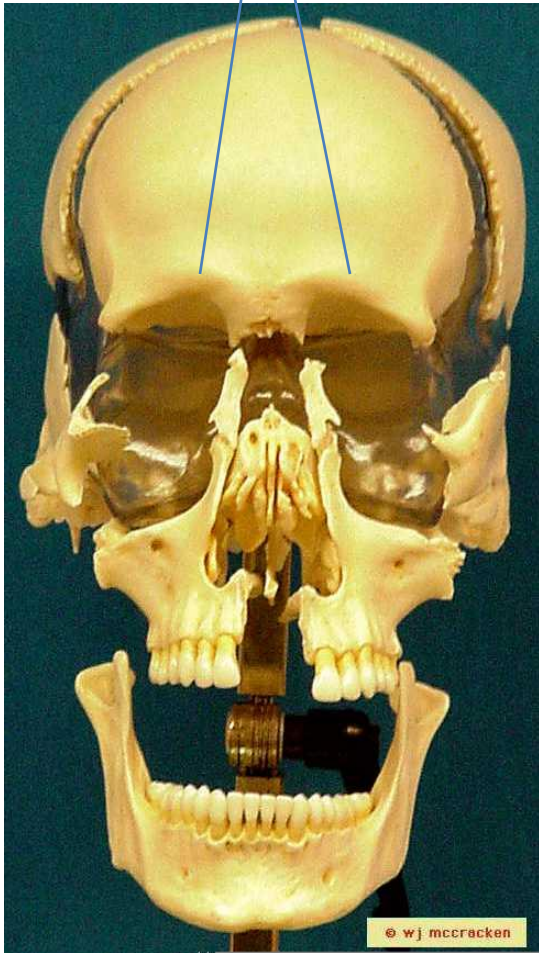
# Cranial Bones

- Frontal bone
- occipital
- Rt. Parietal Bone
- Lt. Parietal Bone
- Rt. Temporal Bone
- Lt. Temporal Bone
- Sphenoid
- Ethmoid



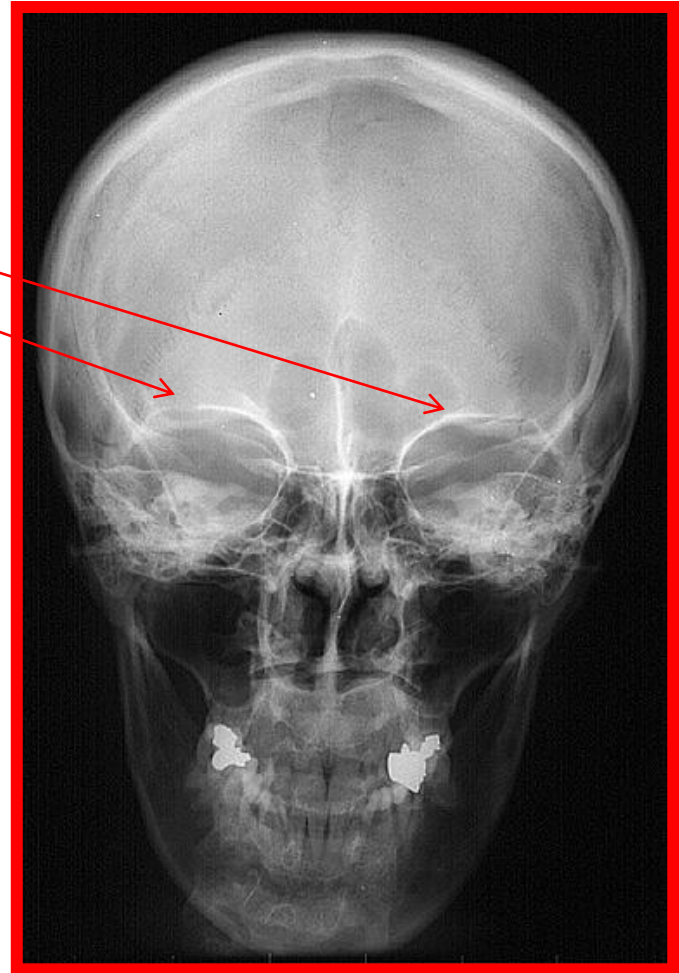
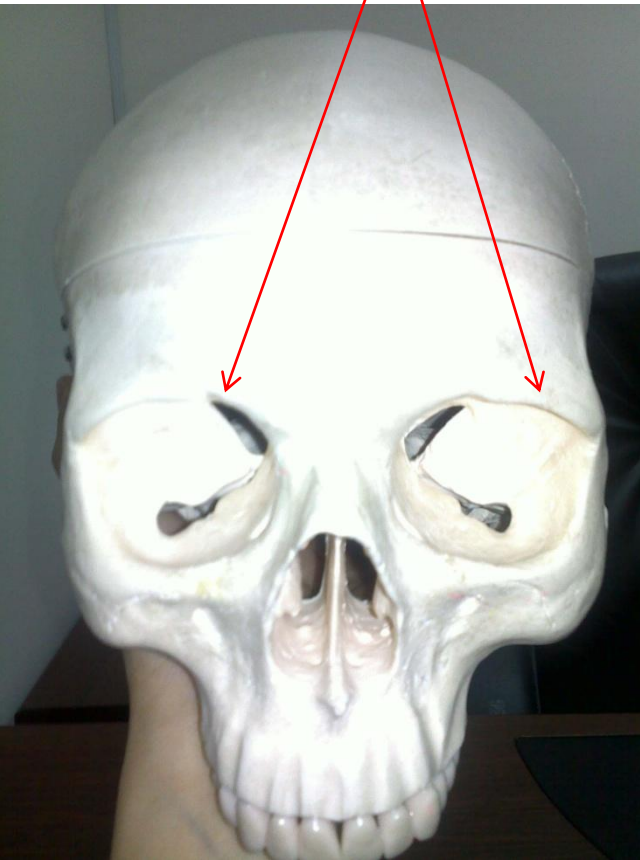
# Frontal bone

Supraorbital margin

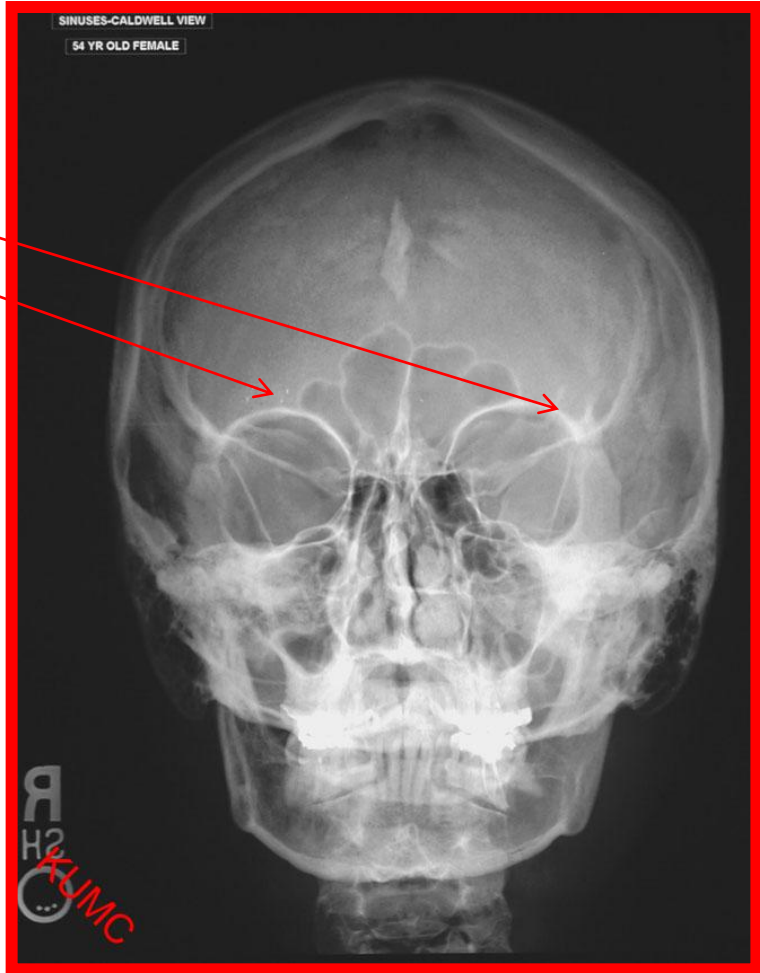
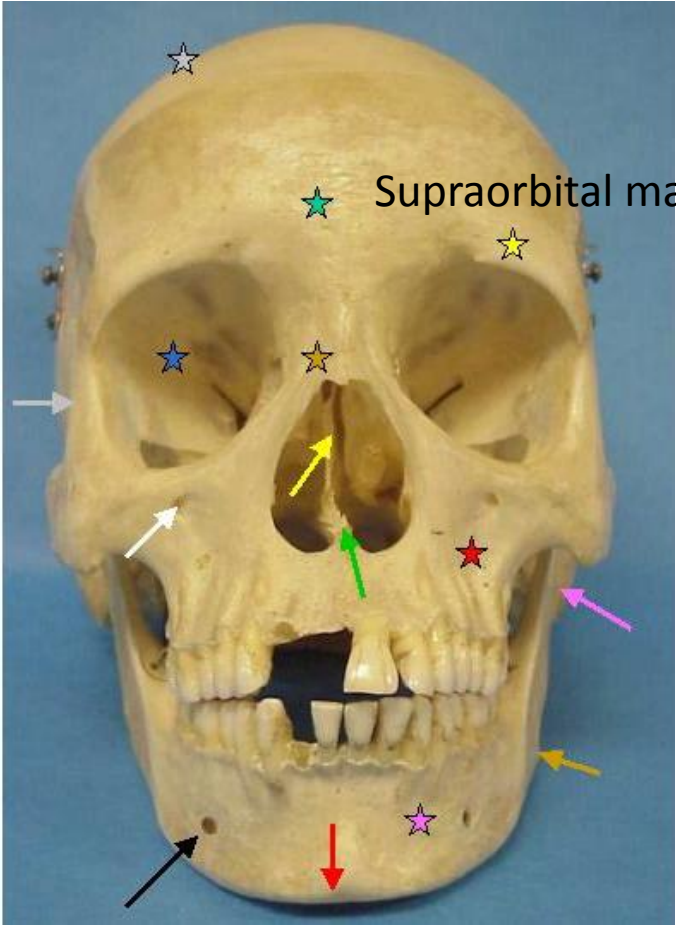


# PA

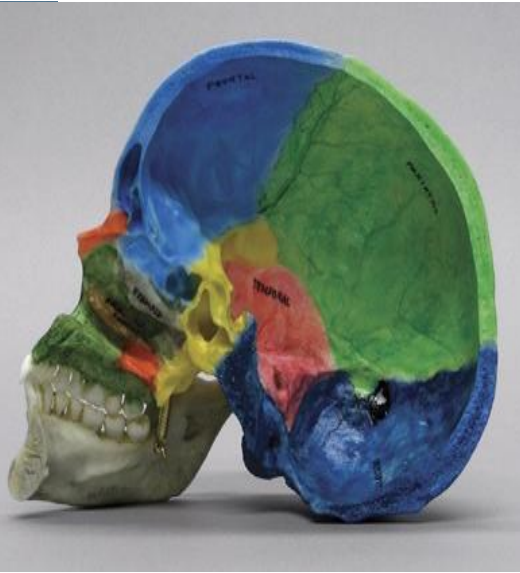
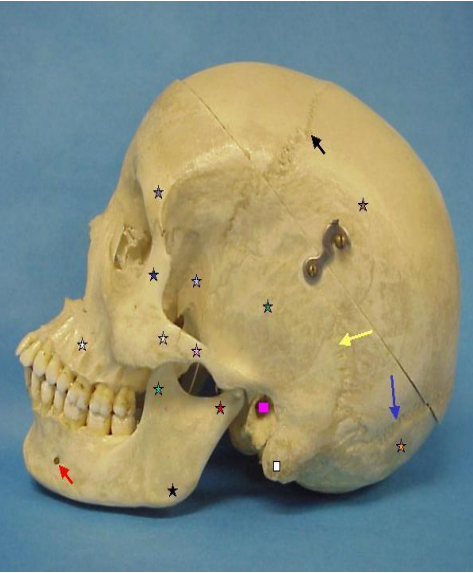
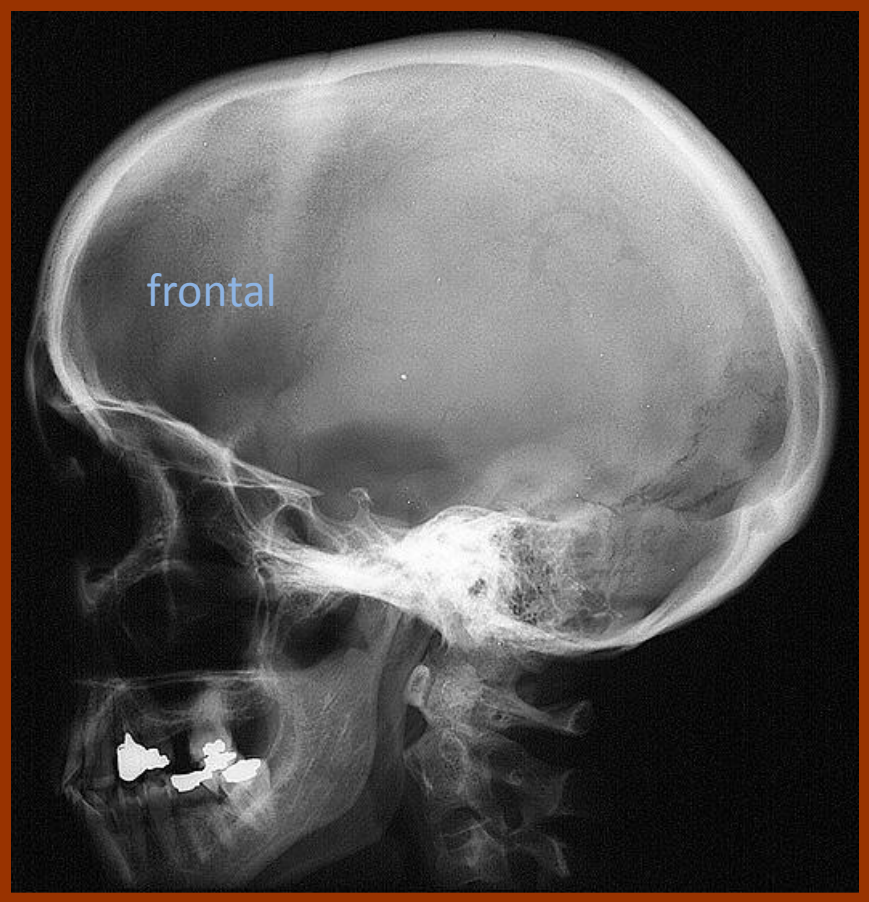
Supraorbital margin



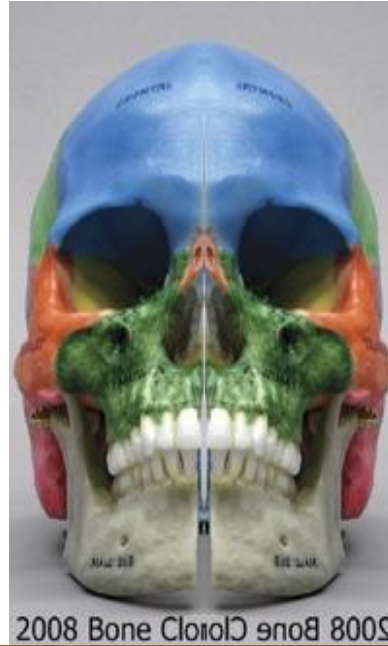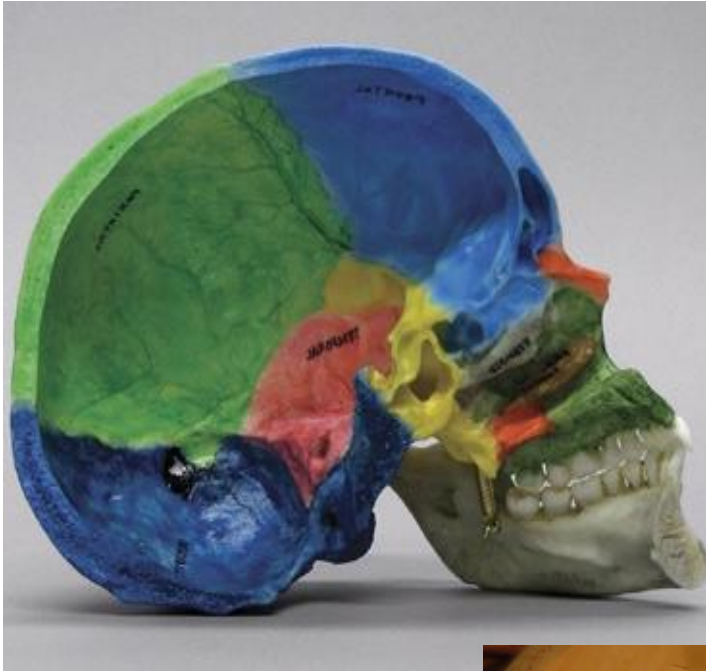# Caldwell view PA with angle



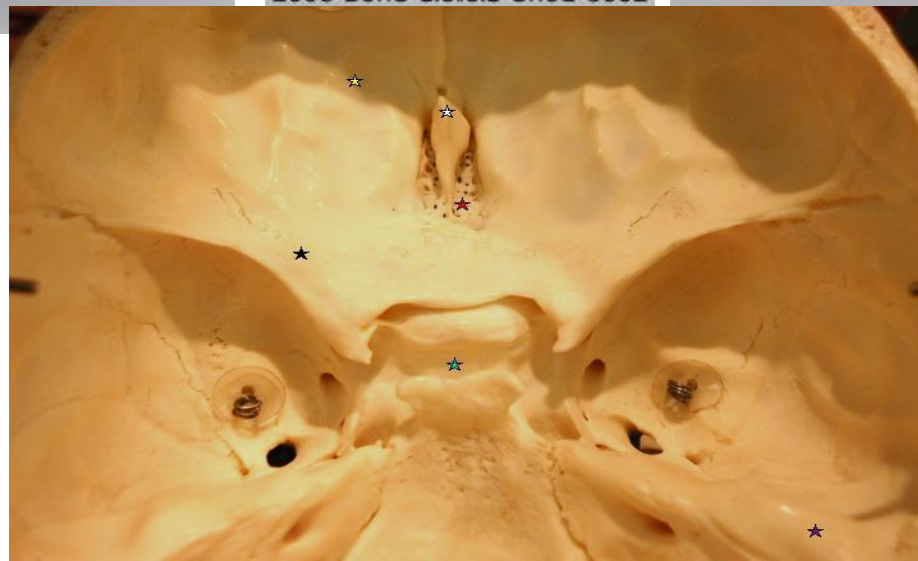
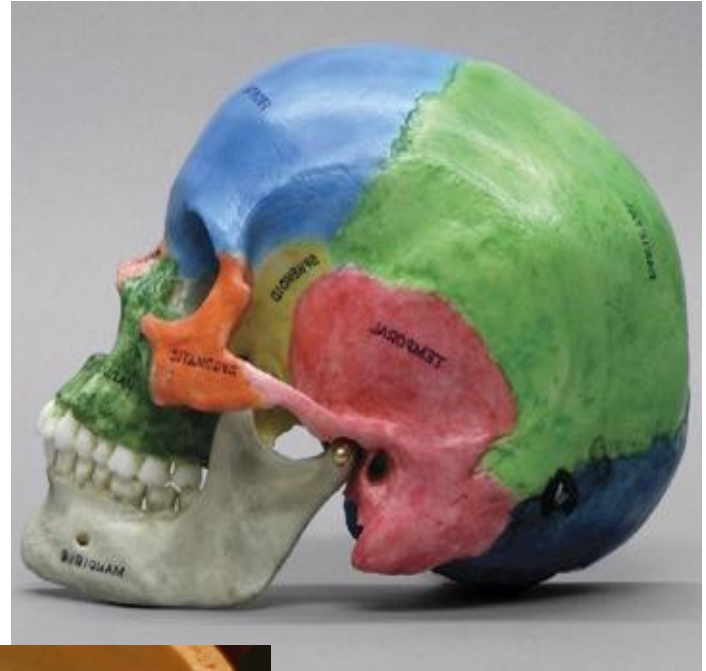
# Lateral skull



# Sphenoid

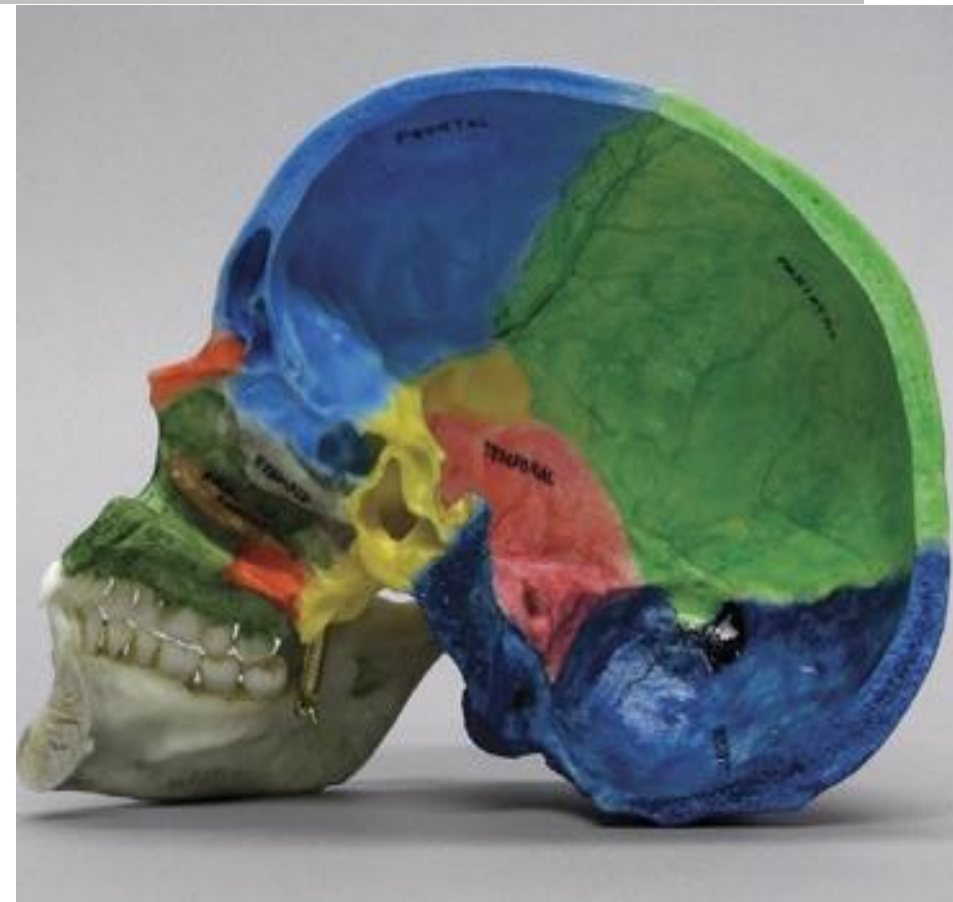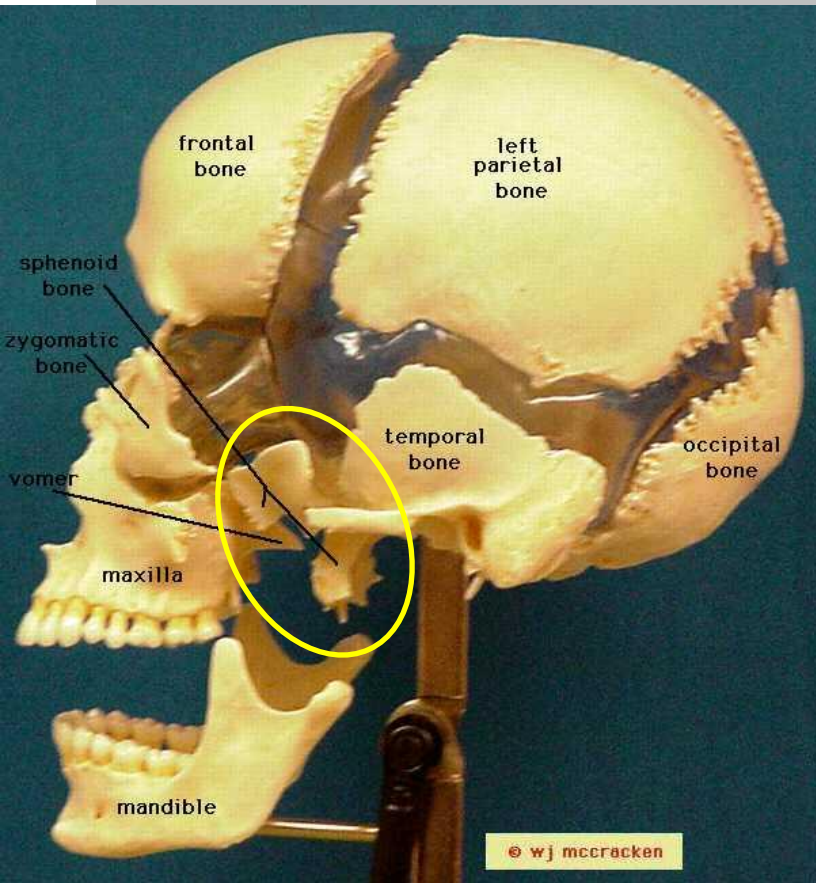


2008 Bone ClotID en08 800S

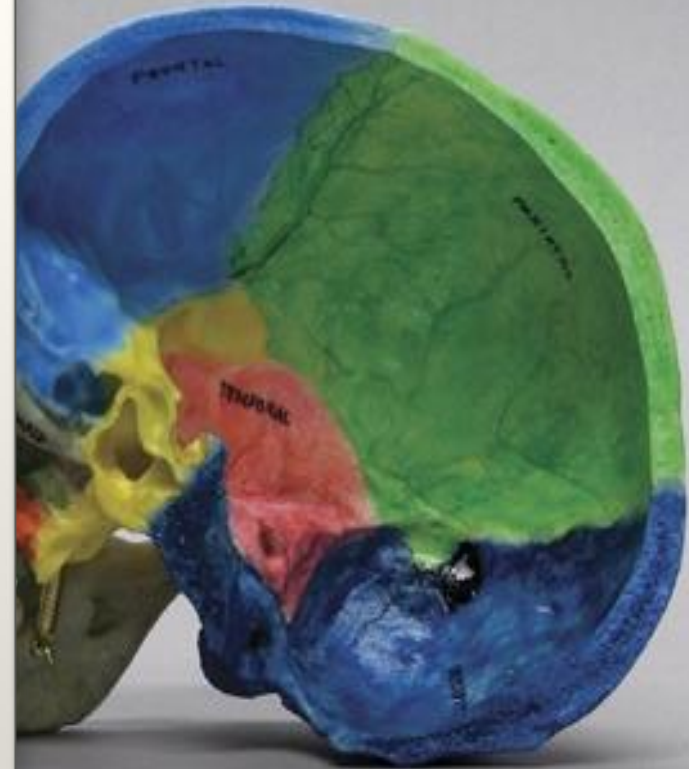
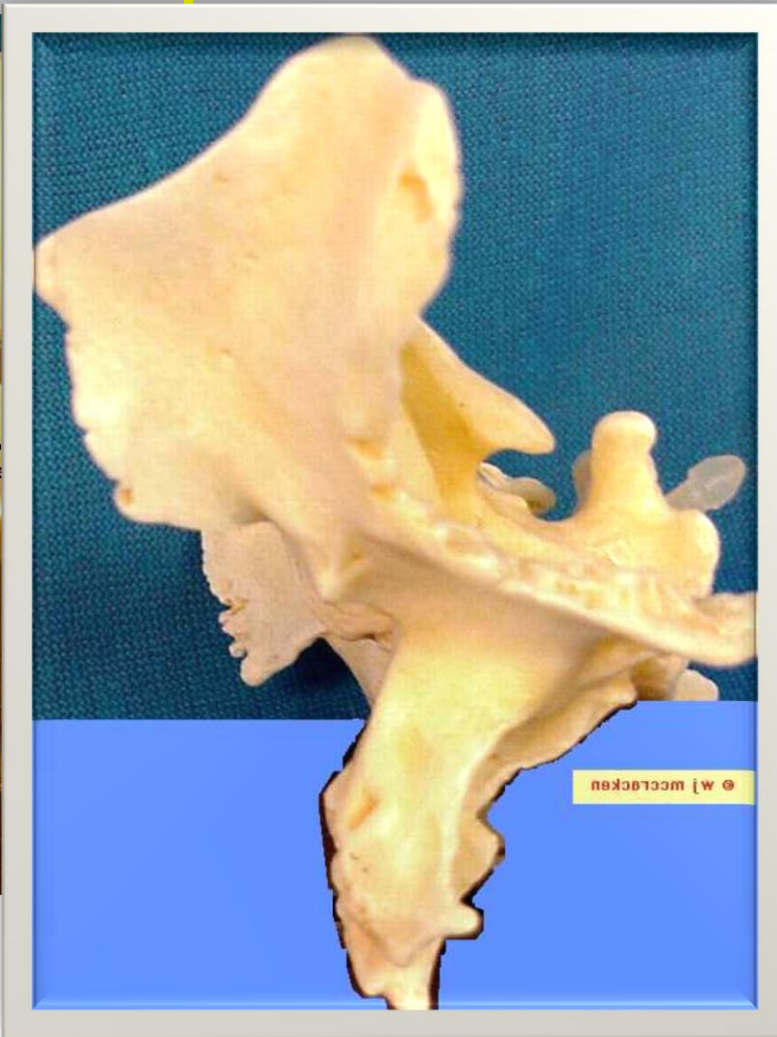
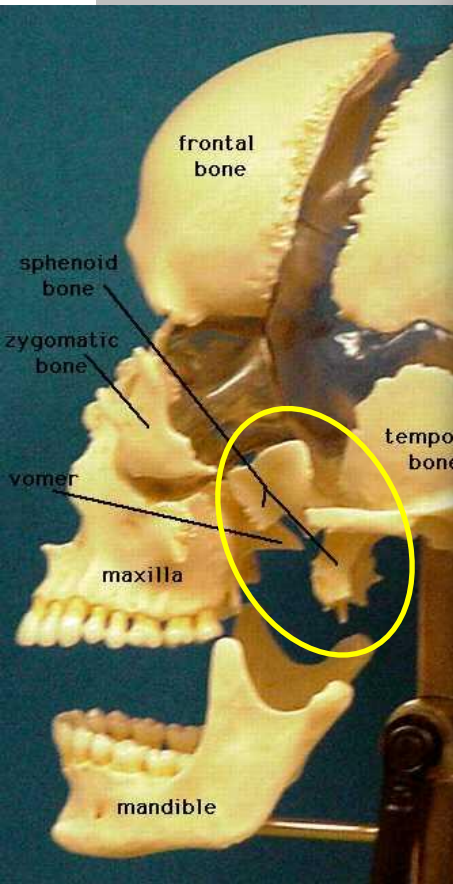




# Sphenoid lateral

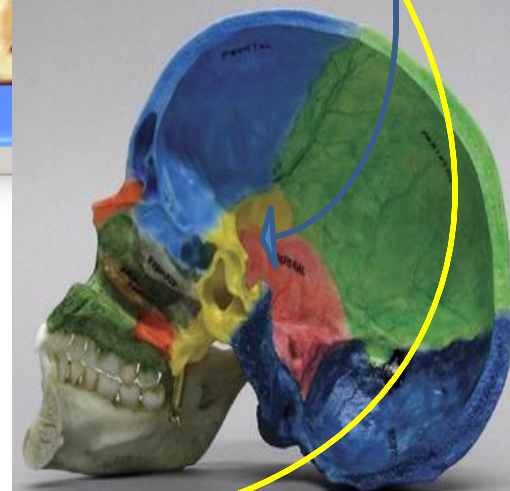
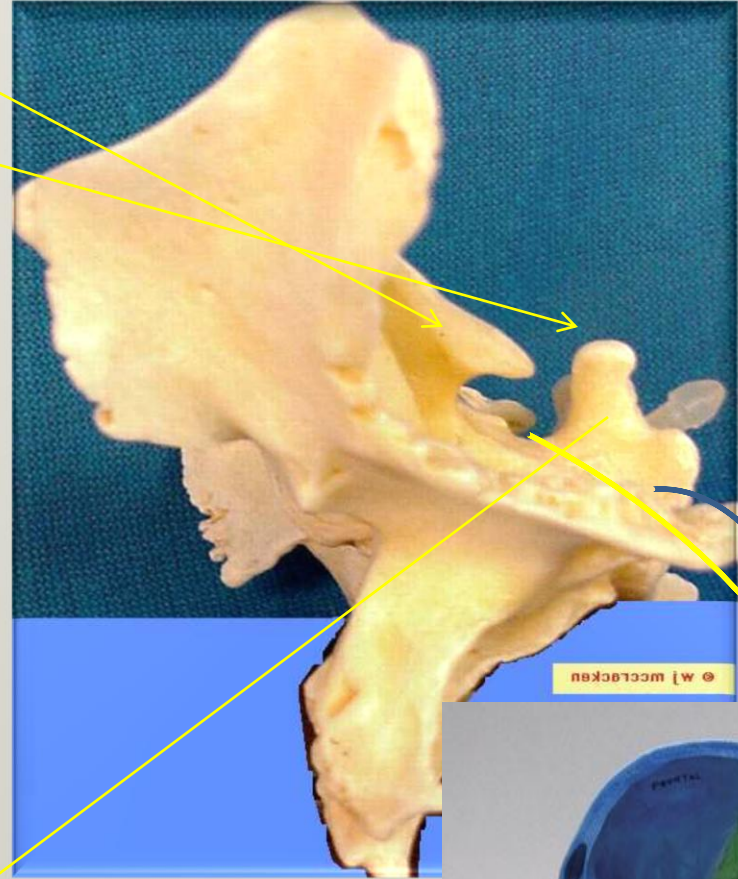
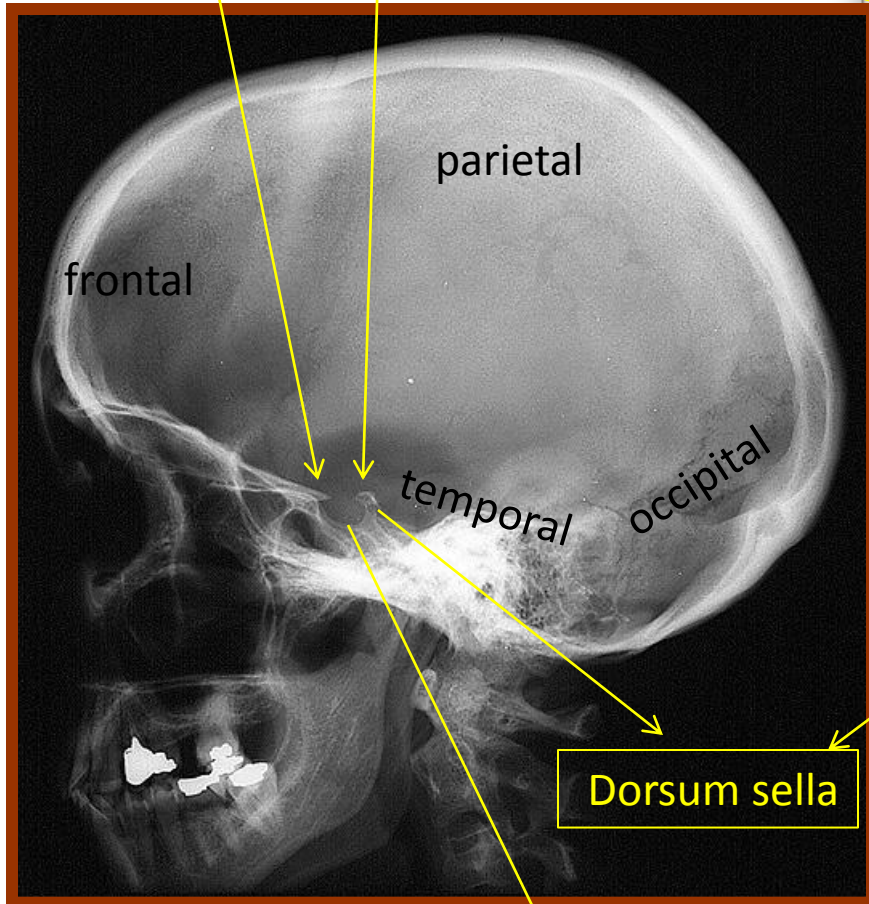


# Sphenoid lateral



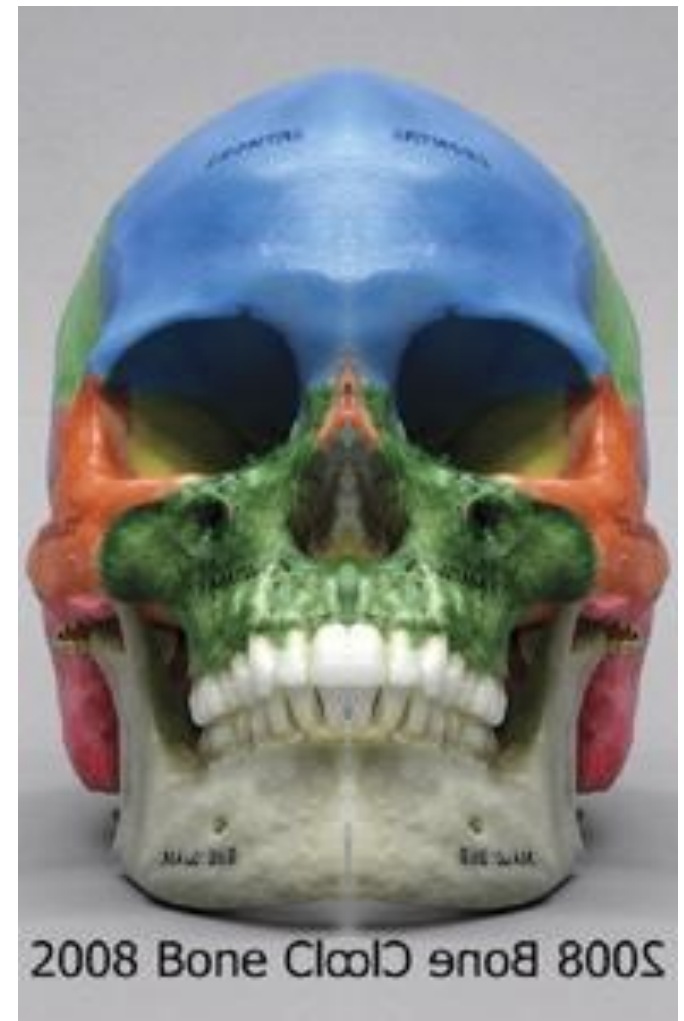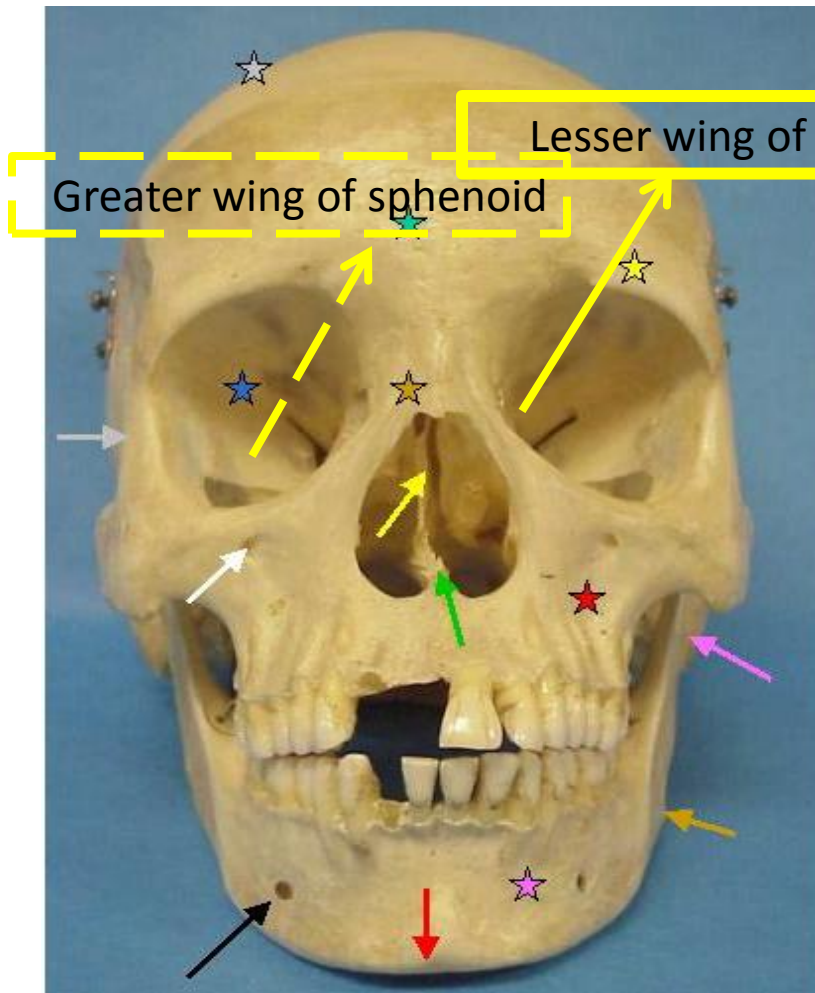
Anterior clinoid processes in the lesser wing

Posterior clinoid processes



Sella turcica

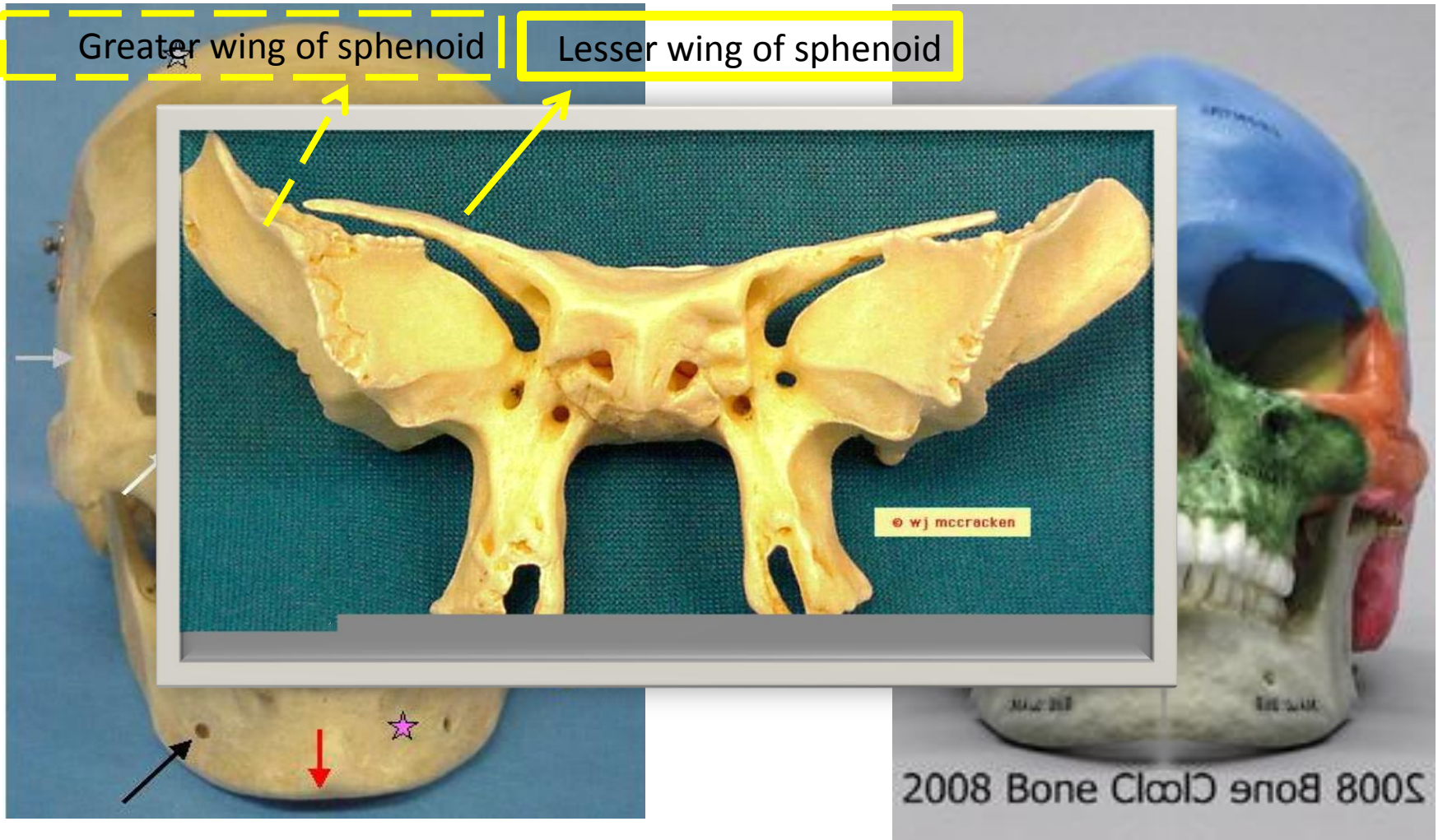
# Sphenoid anterior view

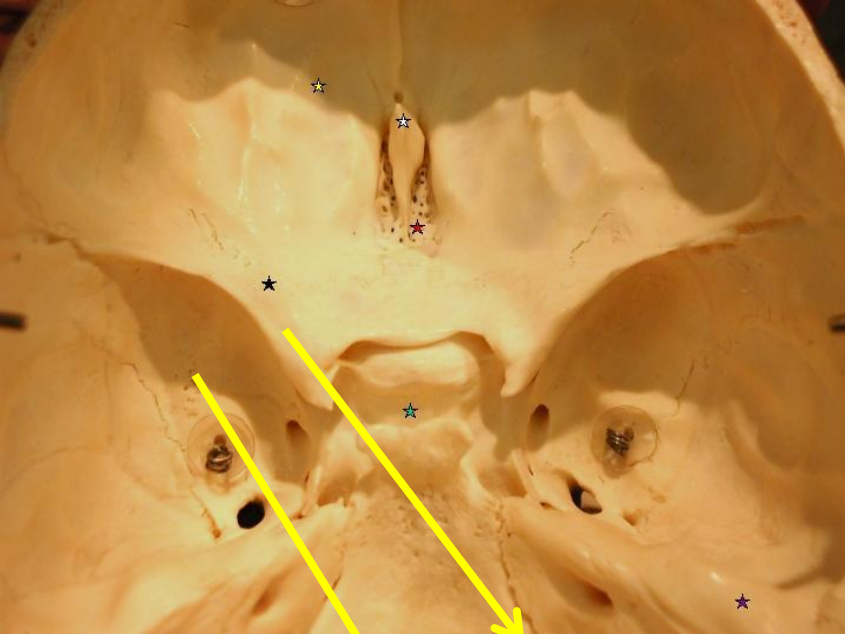


# Sphenoid anterior view

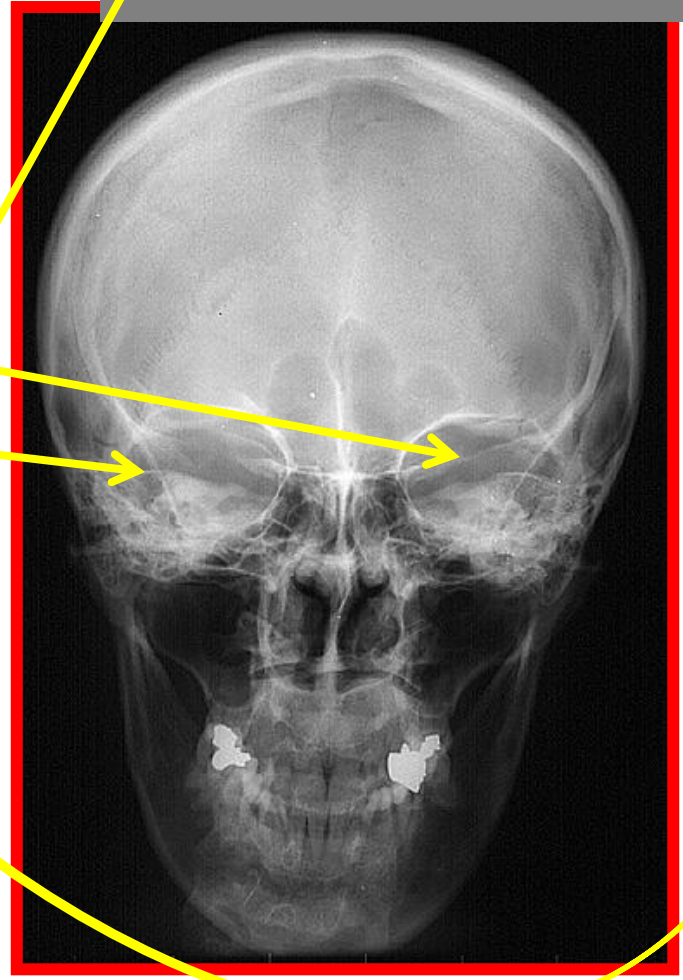
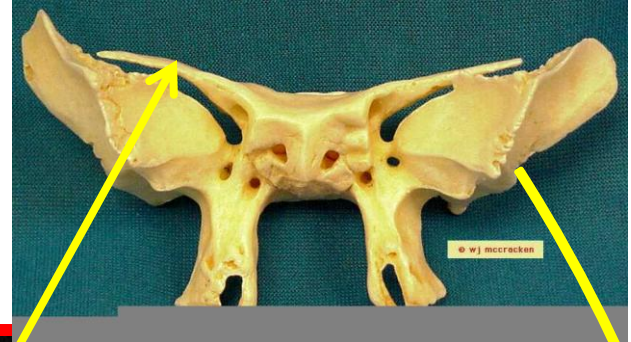
Greater wing of sphenoid

Lesser wing of sphenoid



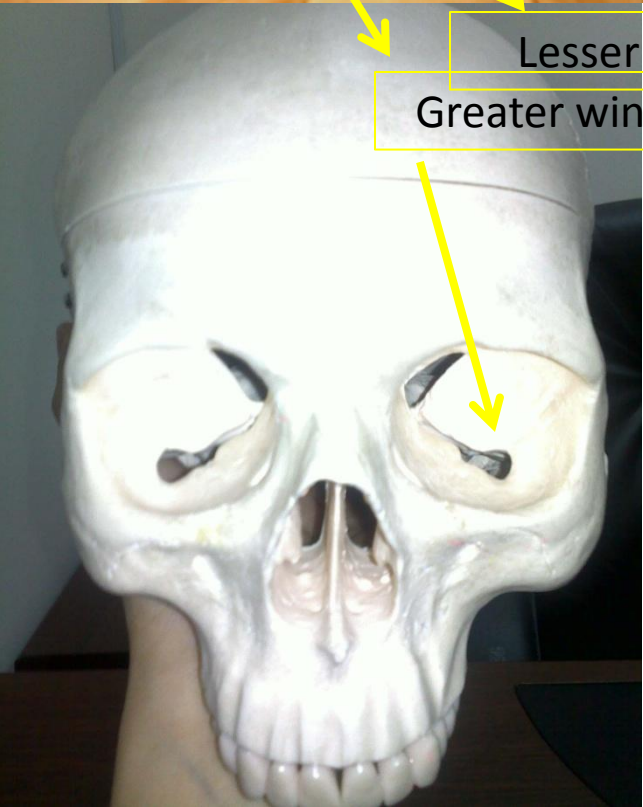


PA

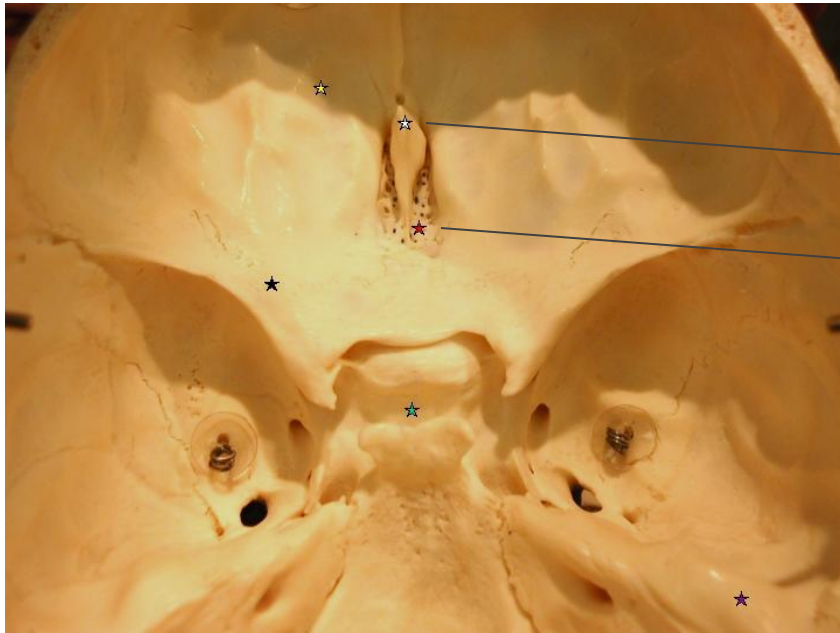
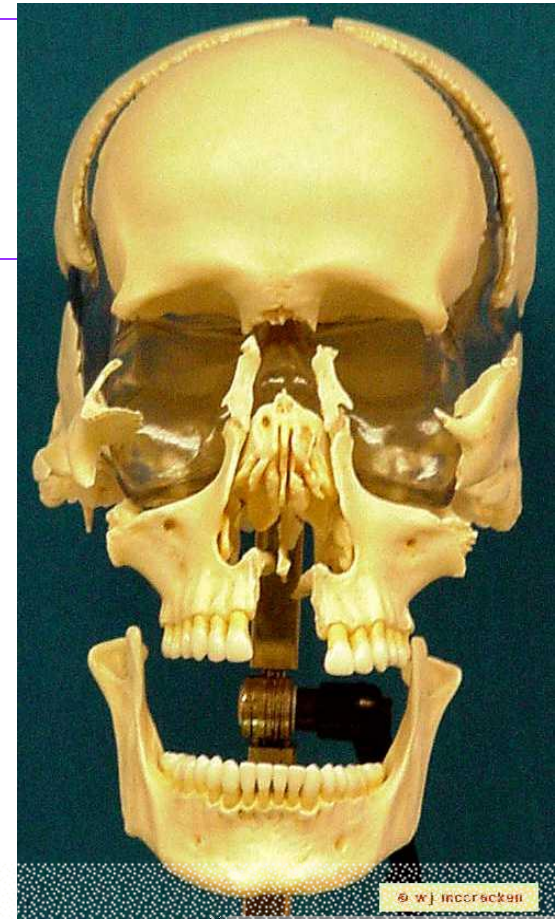
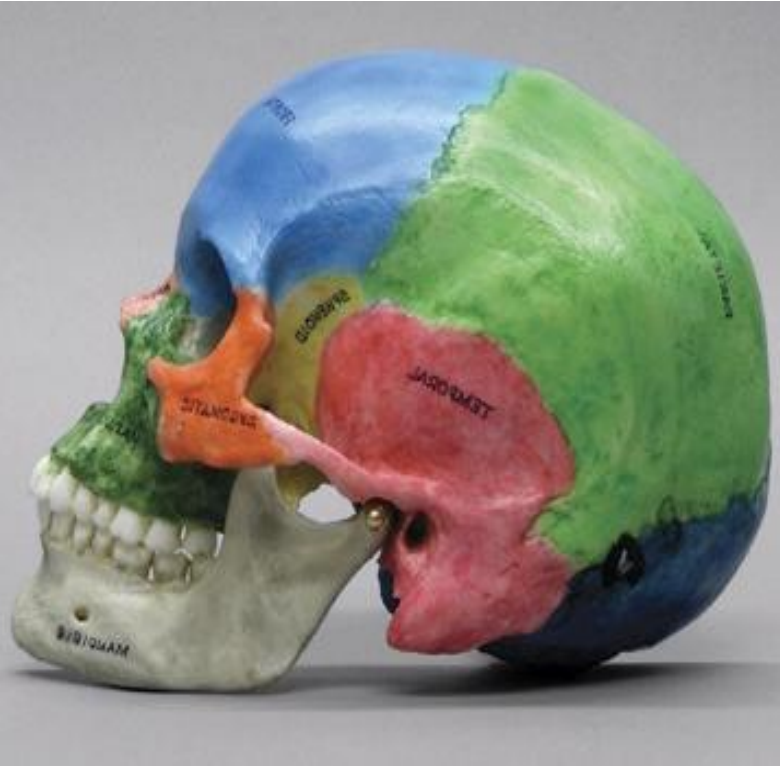


Lesser wing of sphenoid

Greater wing of sphenoid

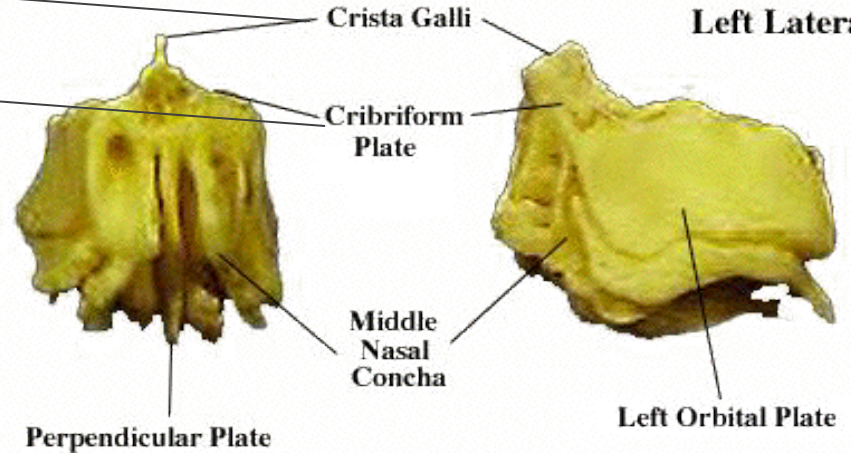


# Ethmoid

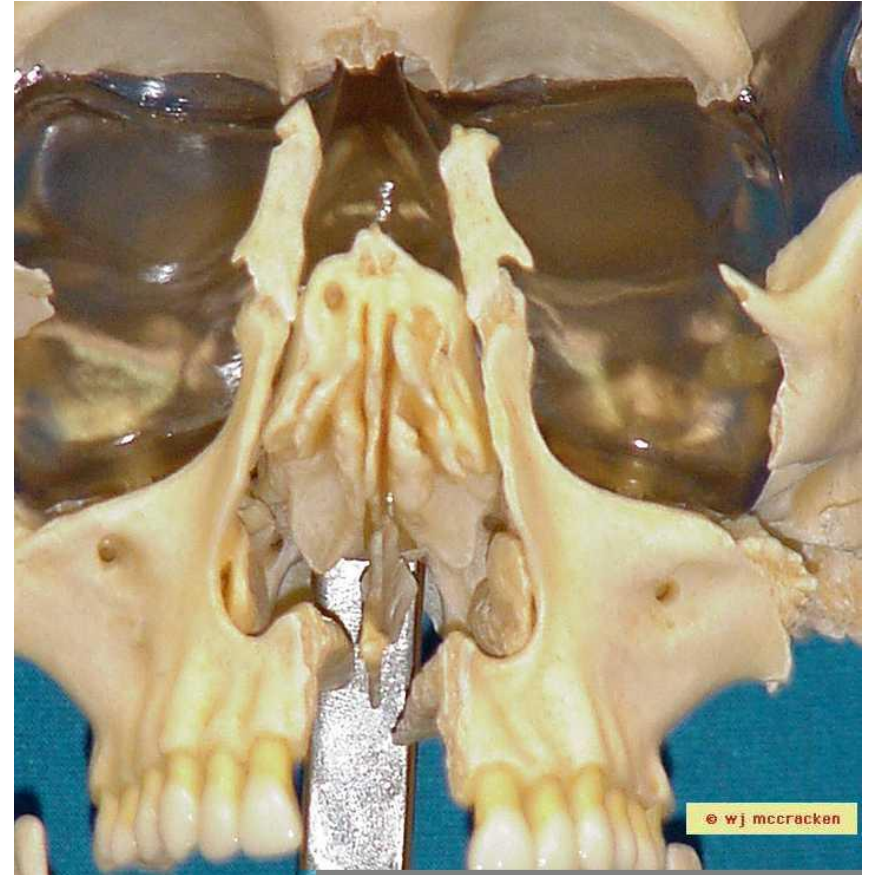
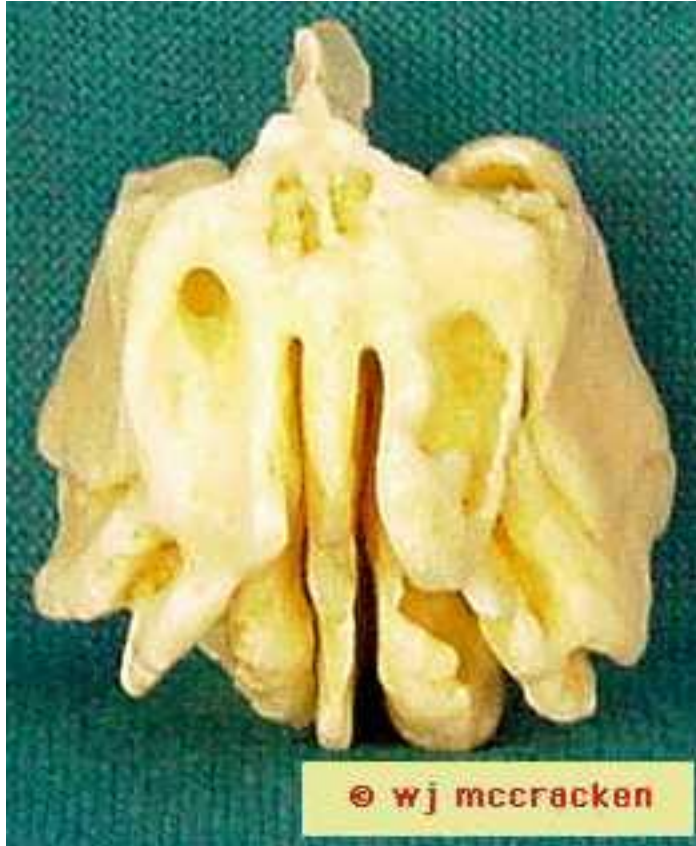


**Anterior View**

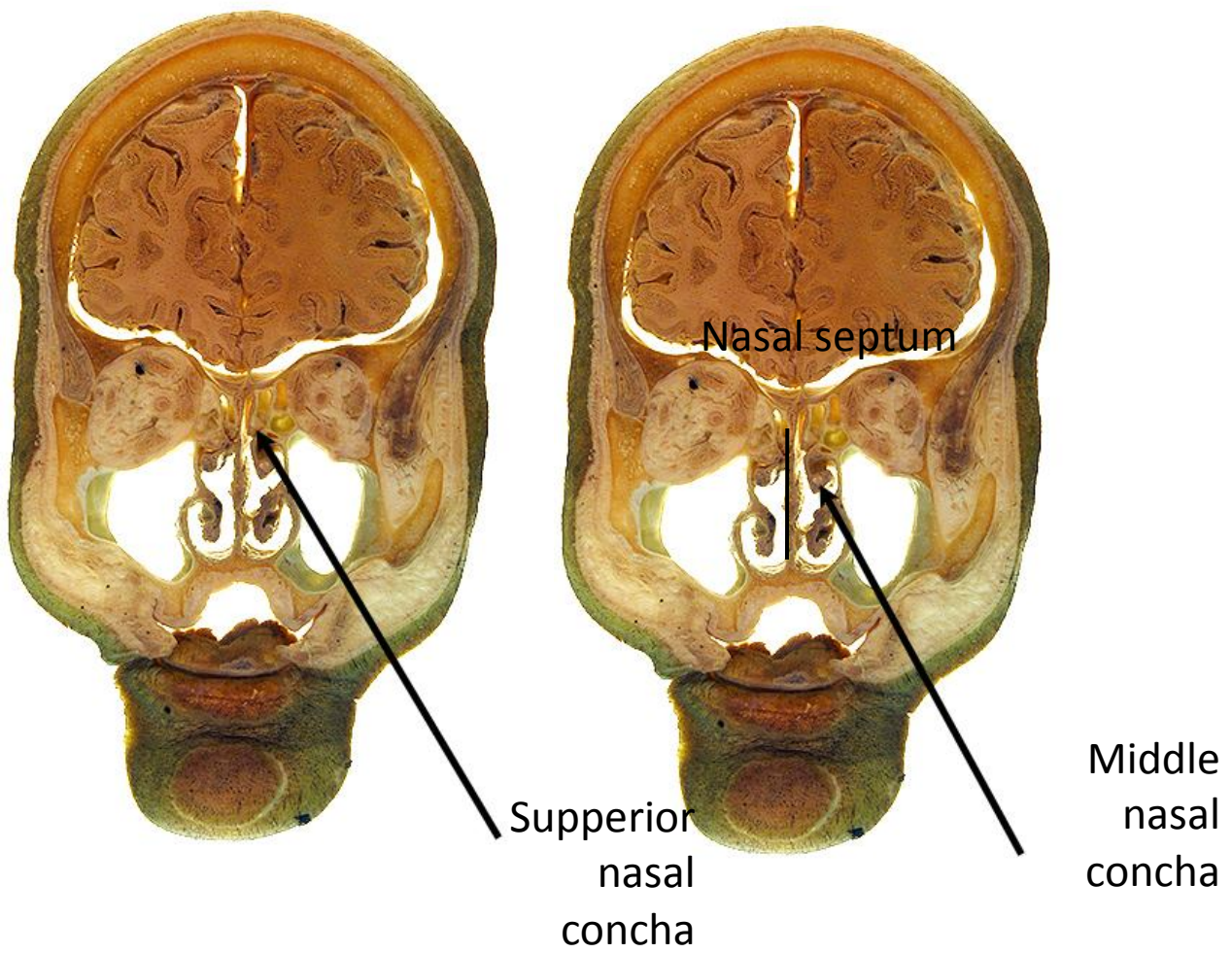
**Left Lateral View**



# Ethmoid

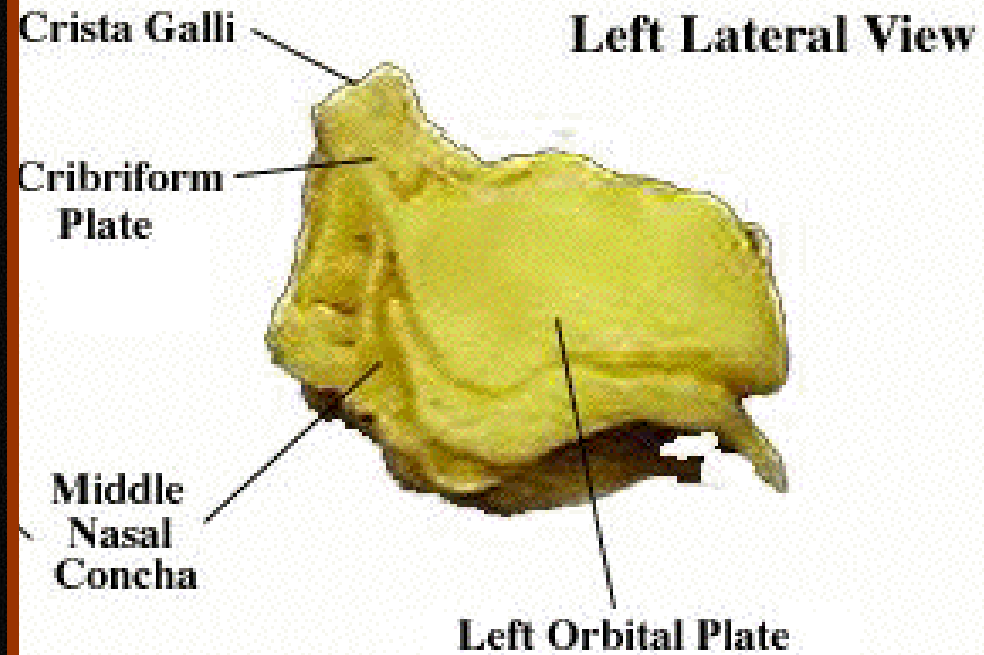
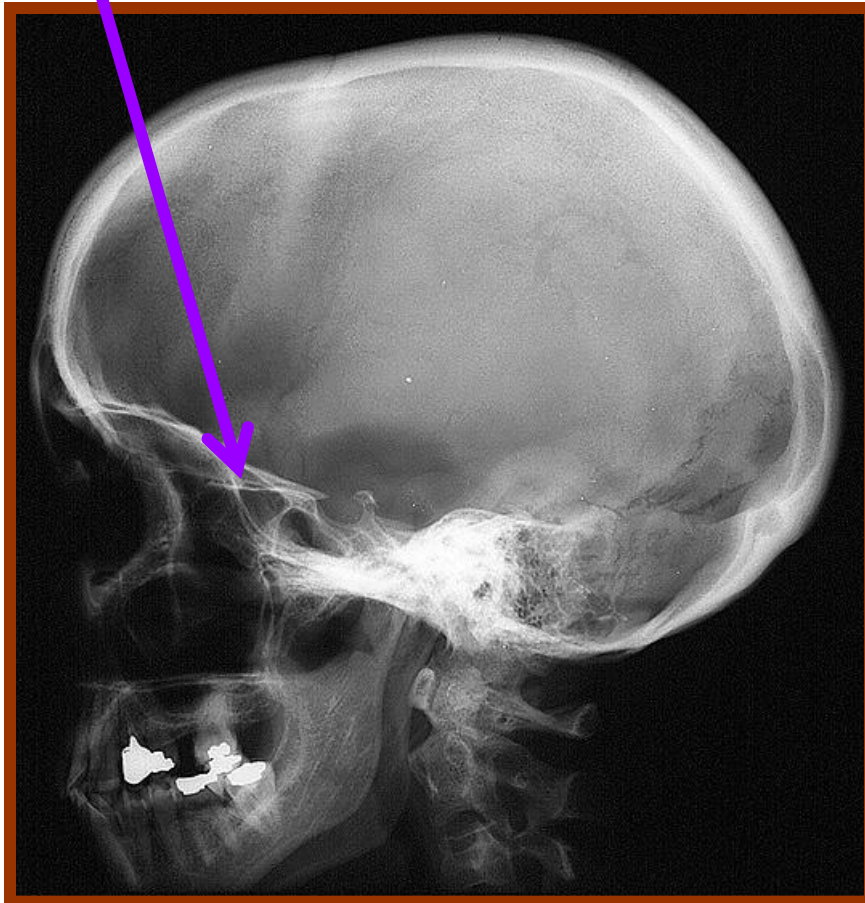




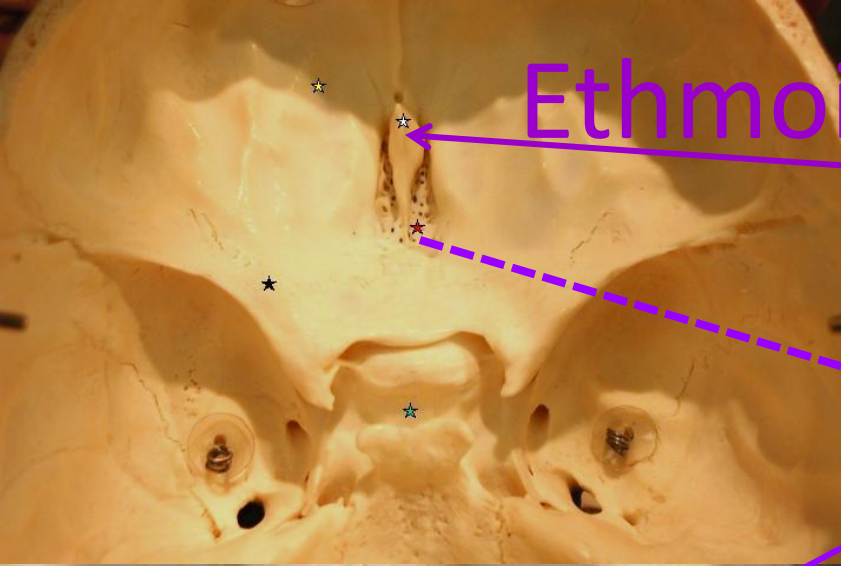


Cribriform plate

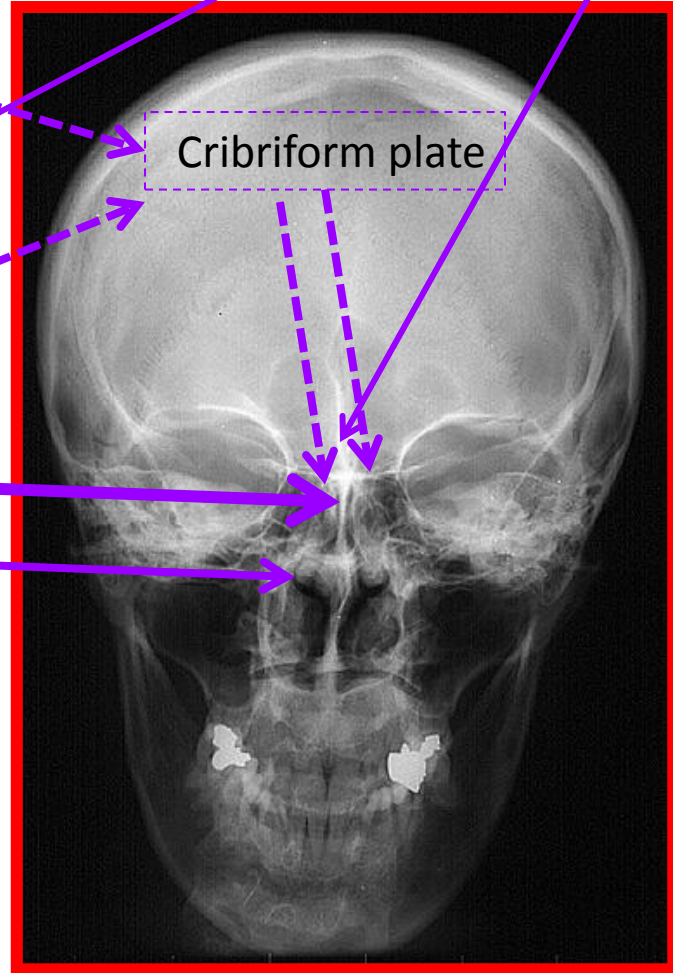
# Ethmoid in Skull Lateral View



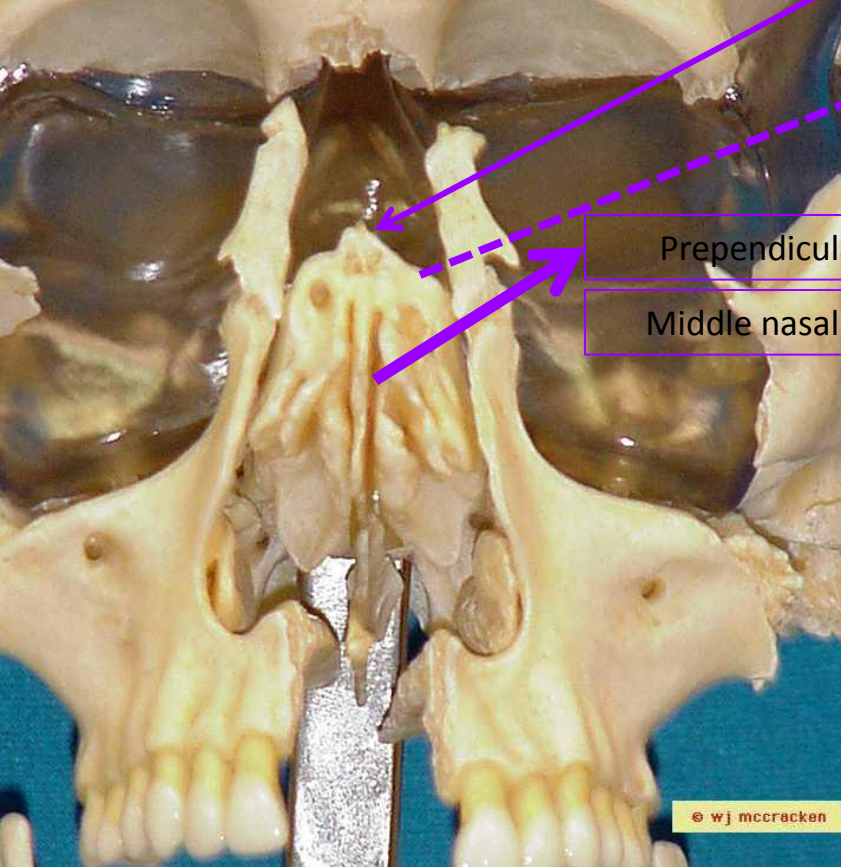
# Ethmoid in PA view



Crista galli of ethmoid



Cribriform plate



Perpendicular plate

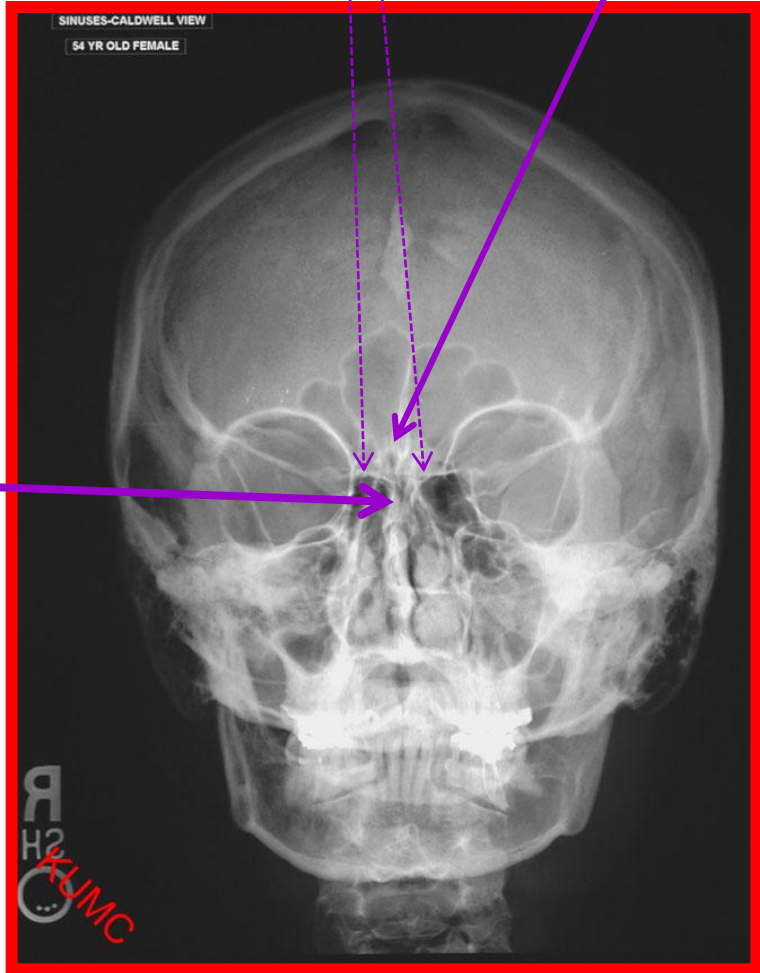
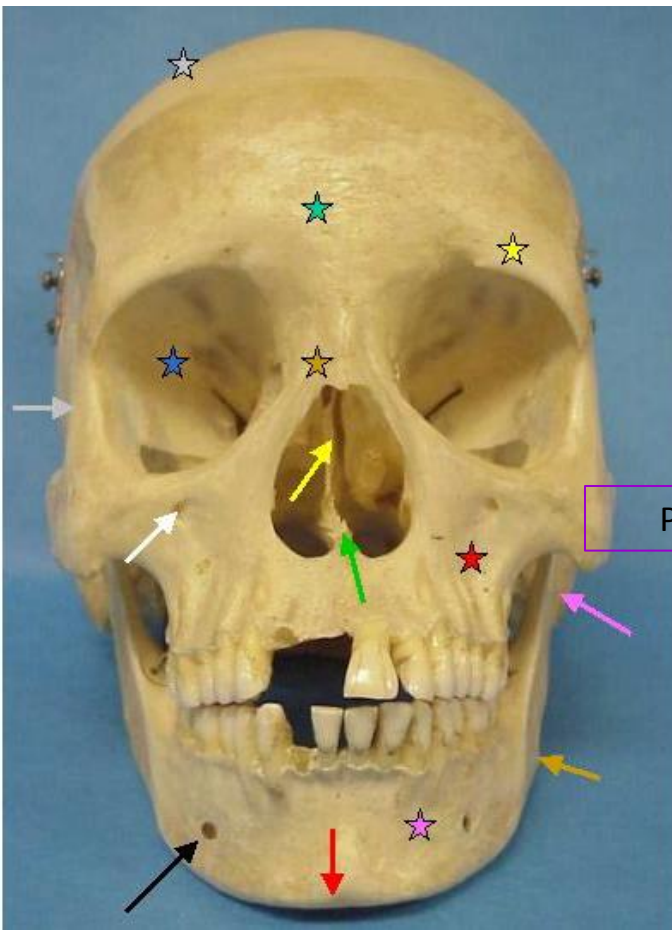
Middle nasal concha

# Caldwell view PA with angle

Crista galli of ethmoid

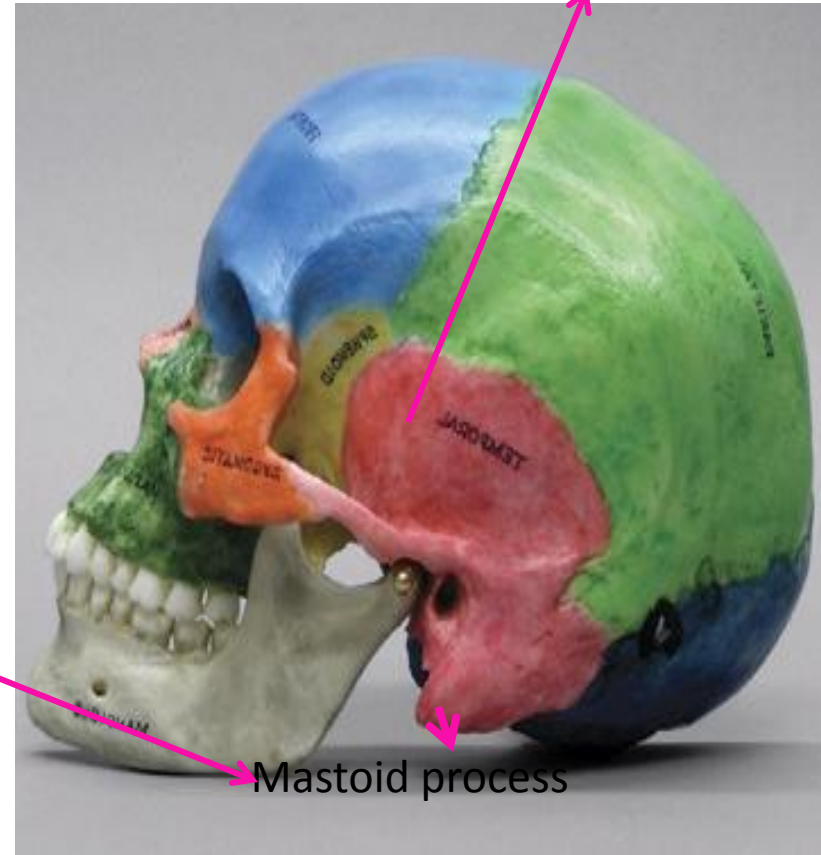
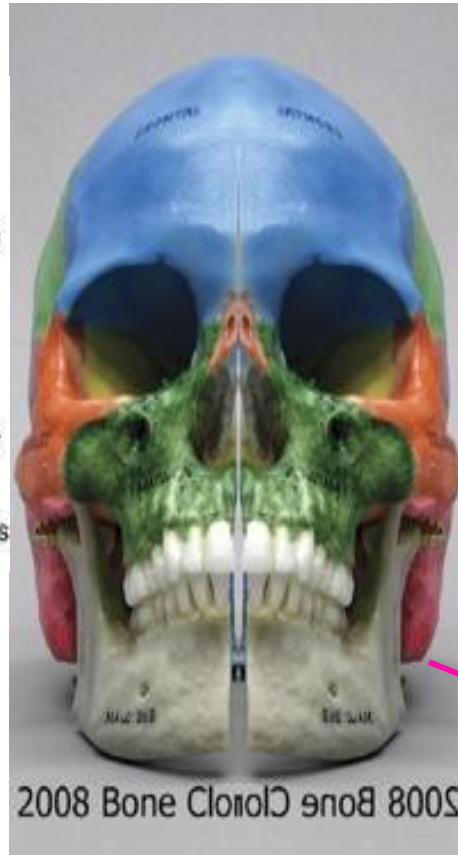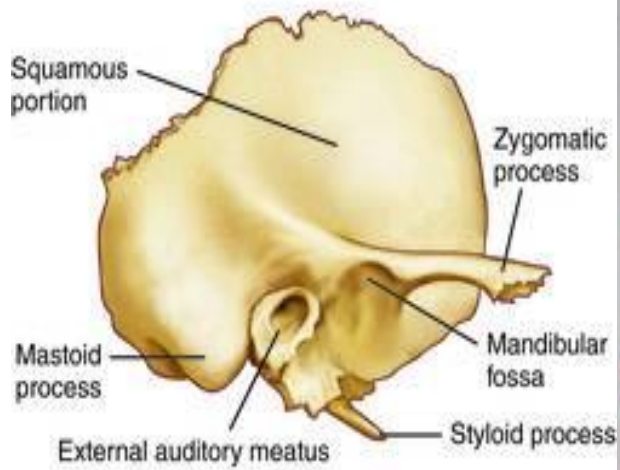
Cribriform plate

Prependicular plate

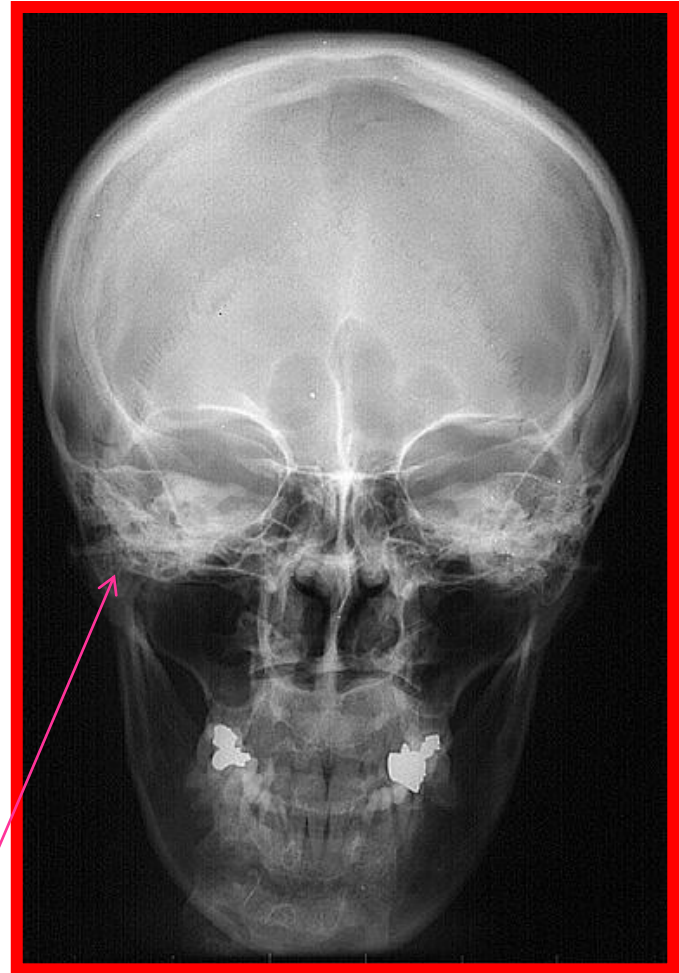
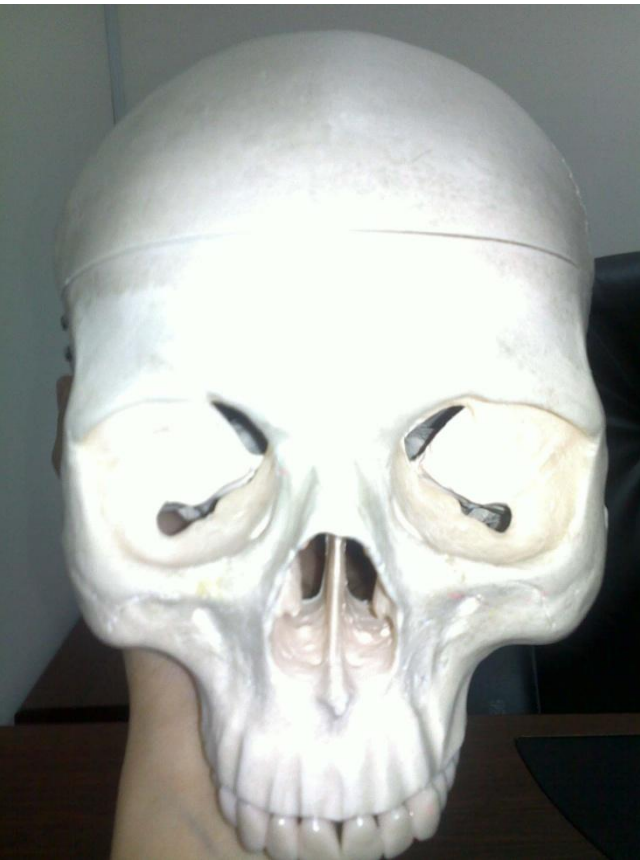
# Temporal

Squamous portion

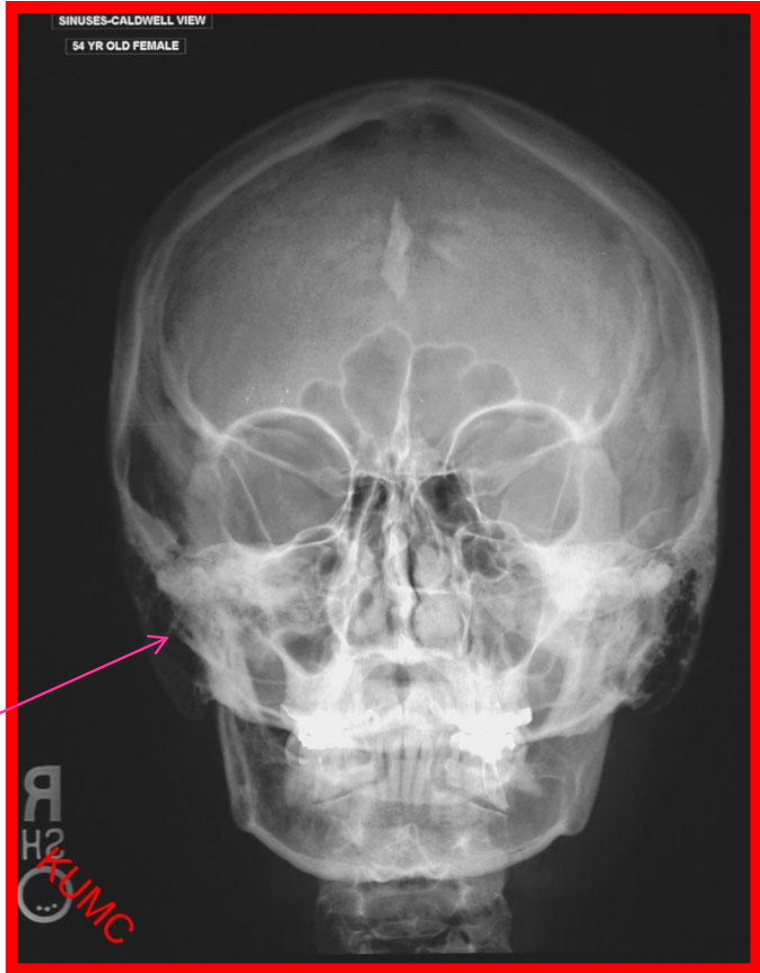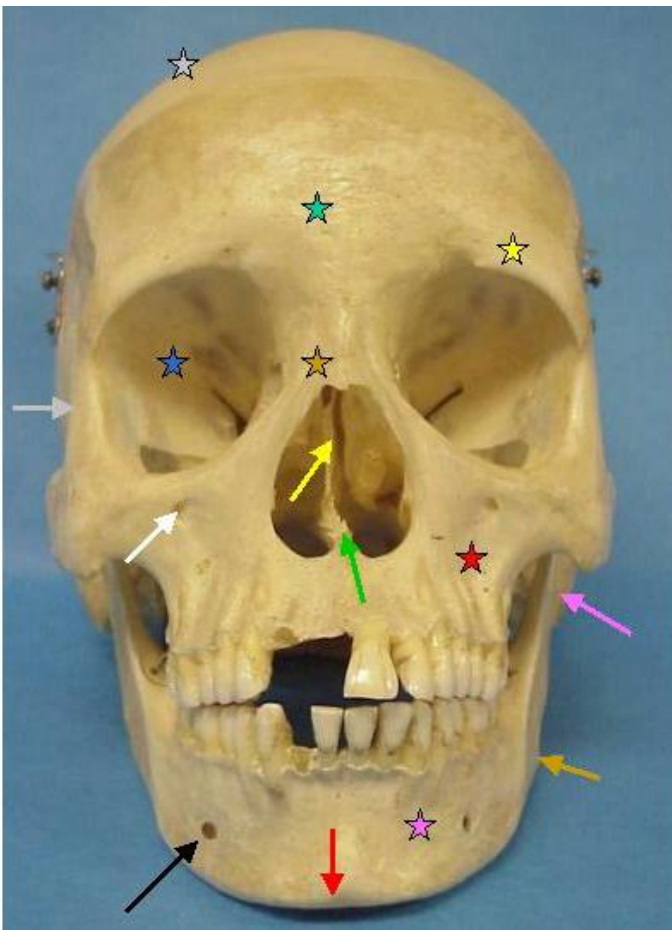


PA



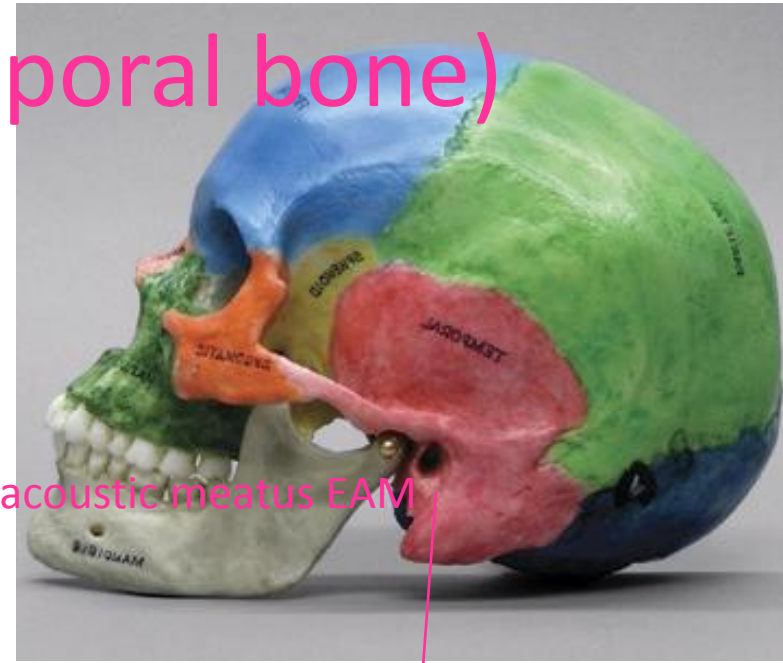
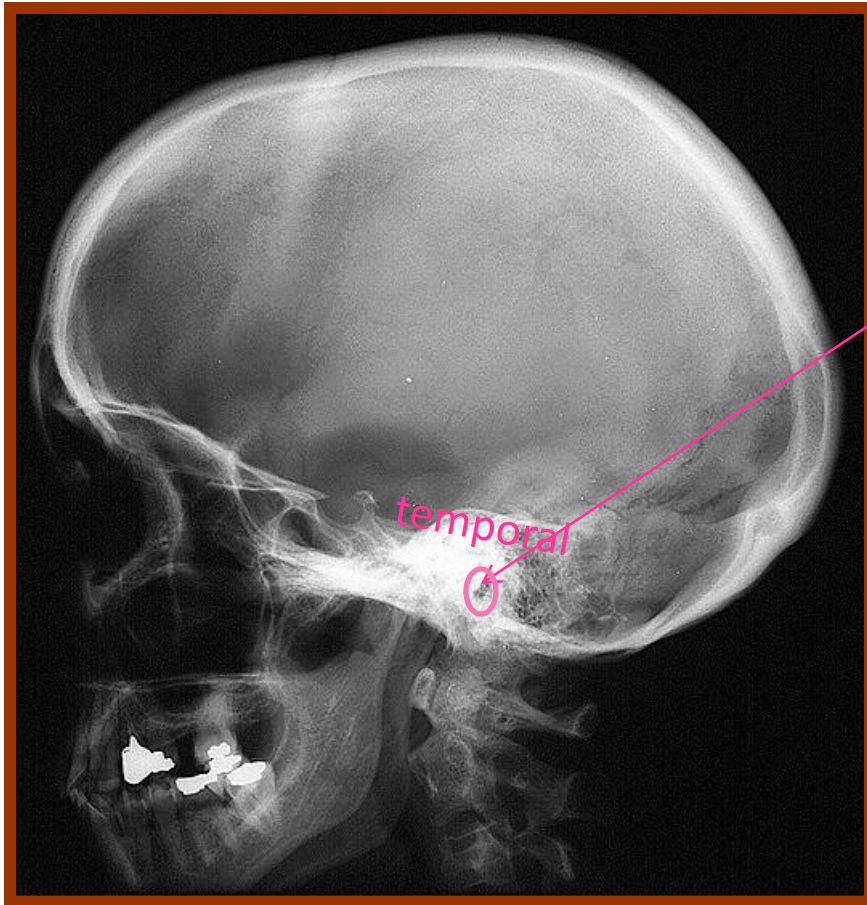
Mastoid Air cells

# Caldwell view PA with angle

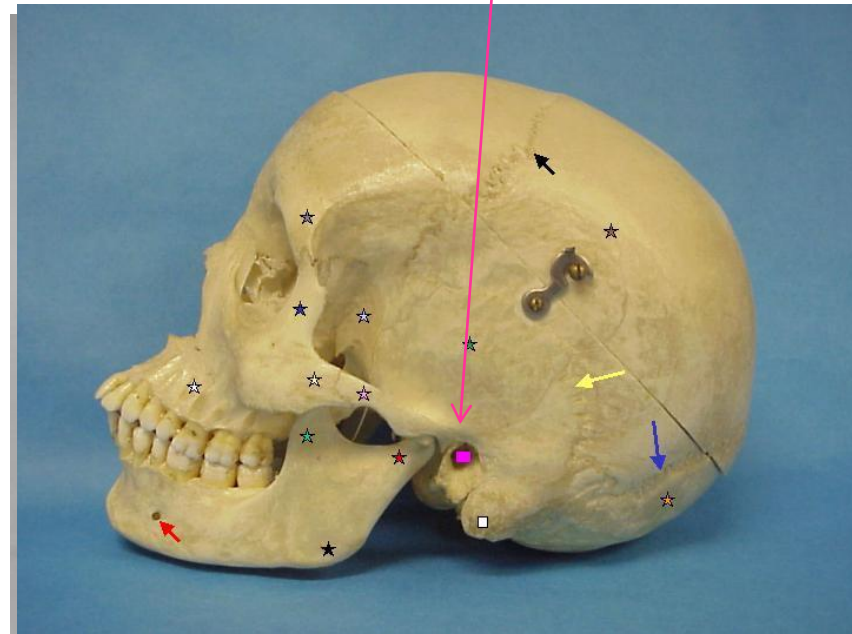


mastoid

# SKULL LATERAL(temporal bone)

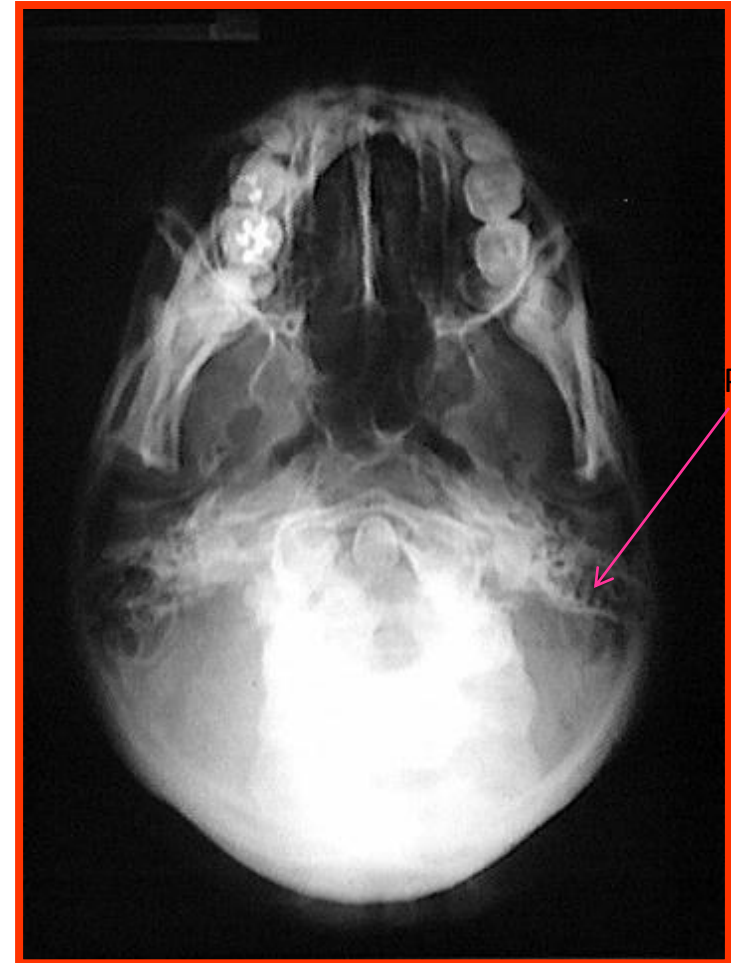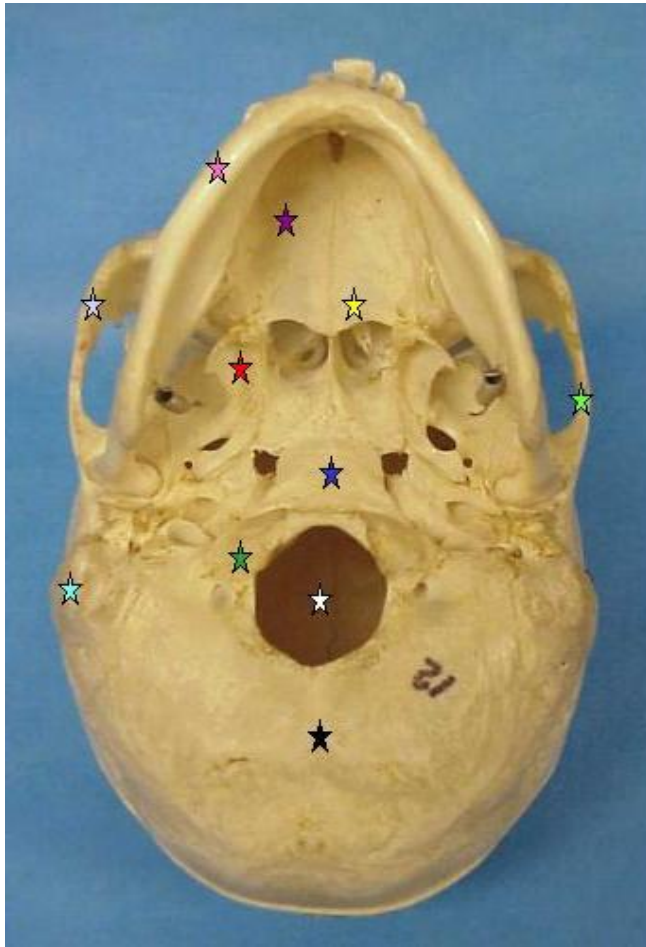


External acoustic meatus EAM

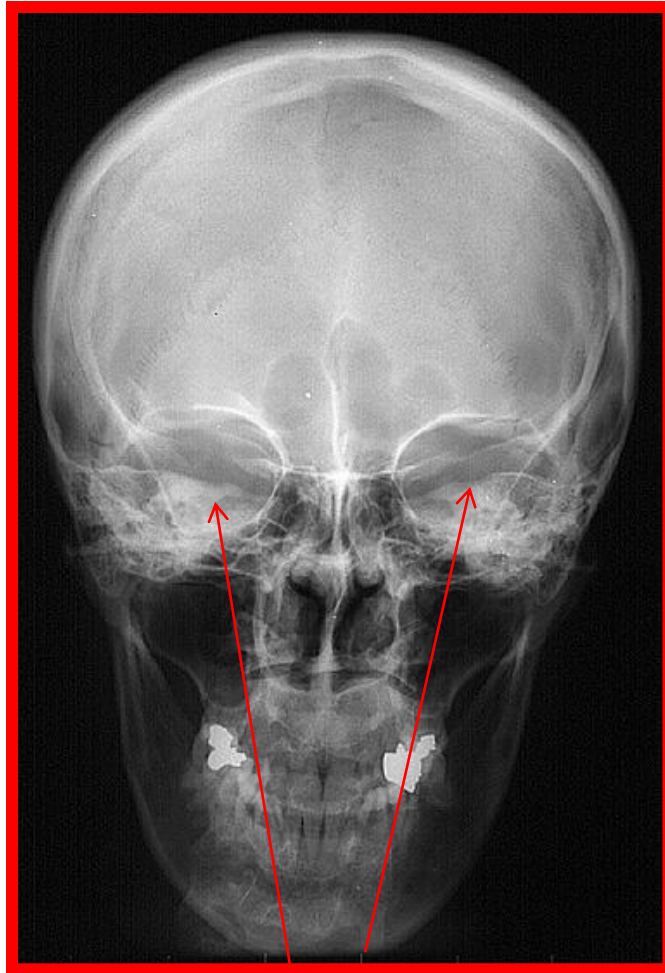




# Submentovertical view

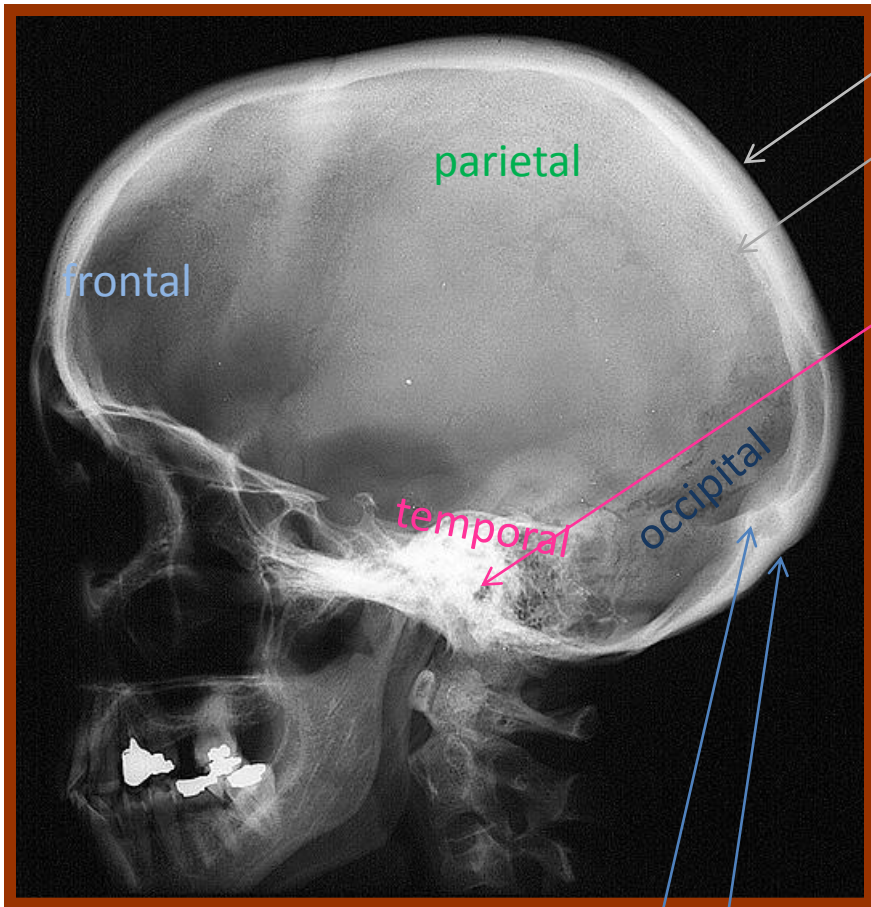


Mastoid  
Portion of  
temporal



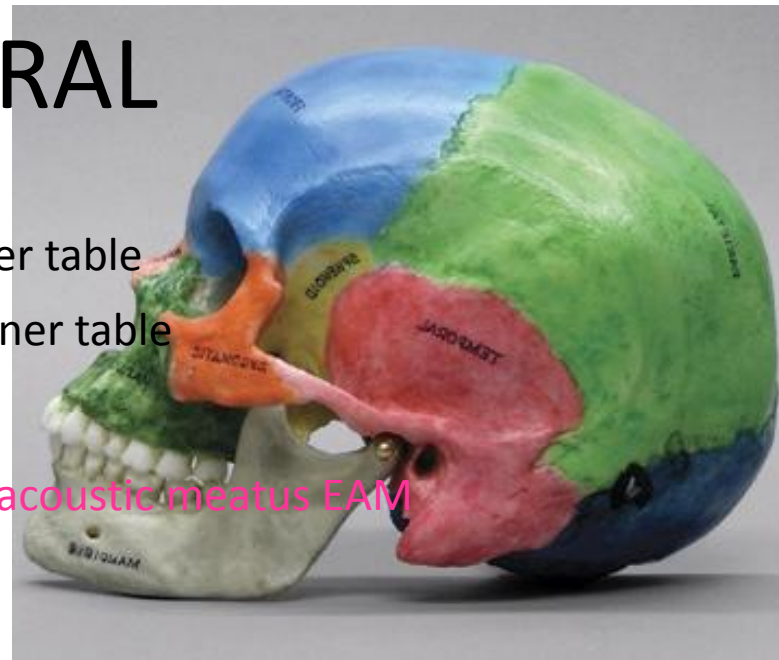petrous portion in the temporal bone

# SKULL LATERAL



Internal occipital protuberance

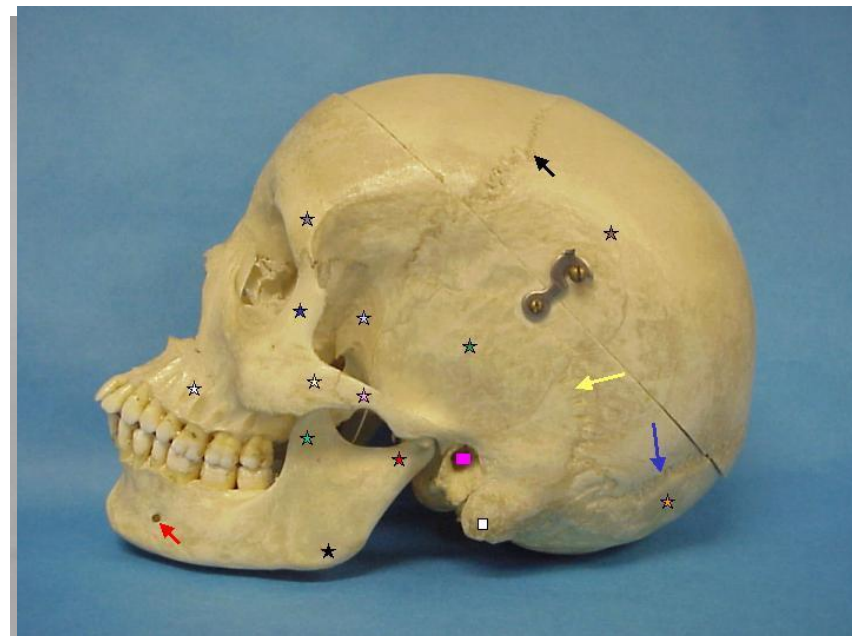
External occipital protuberance



Outer table

Inner table

External acoustic meatus EAM

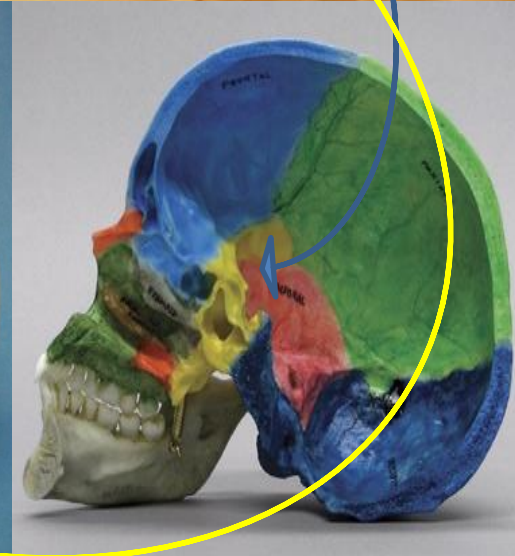
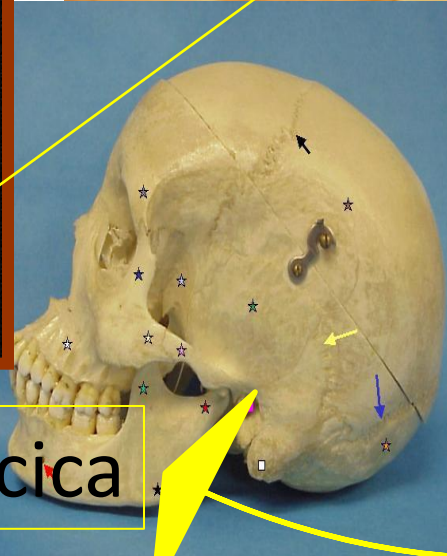
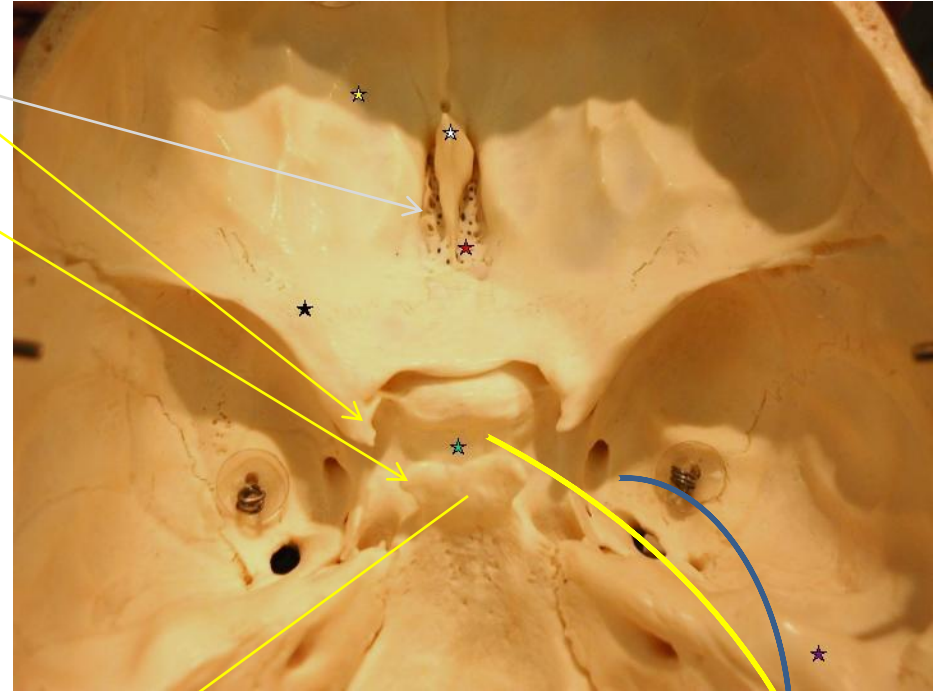
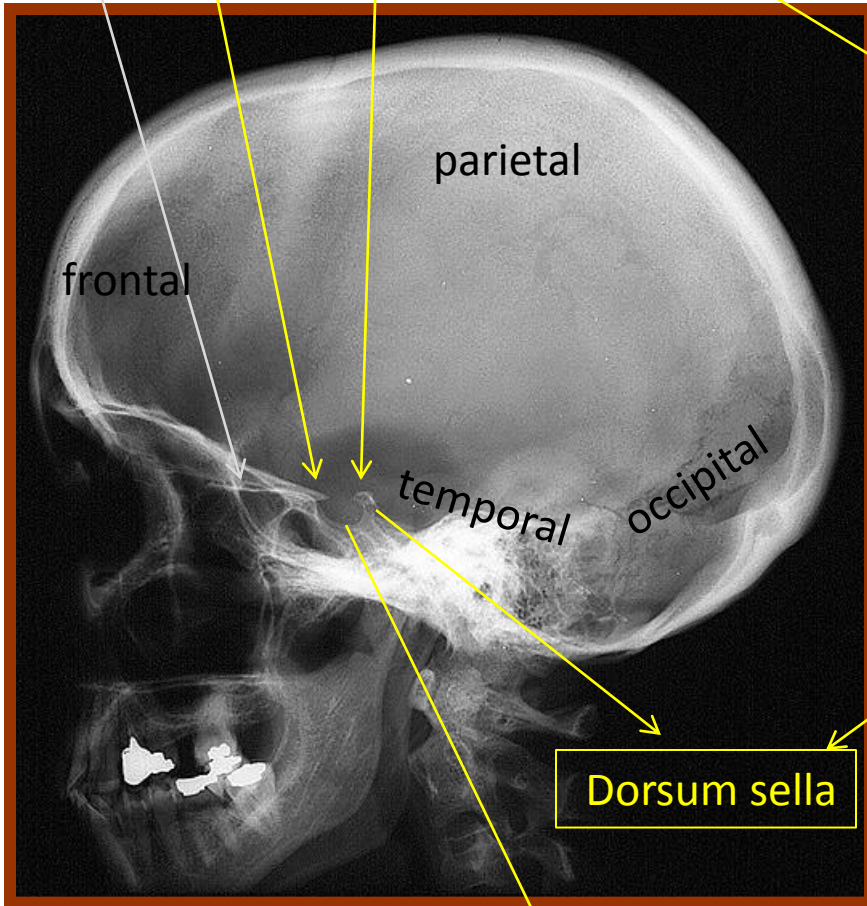


Cribriform plate

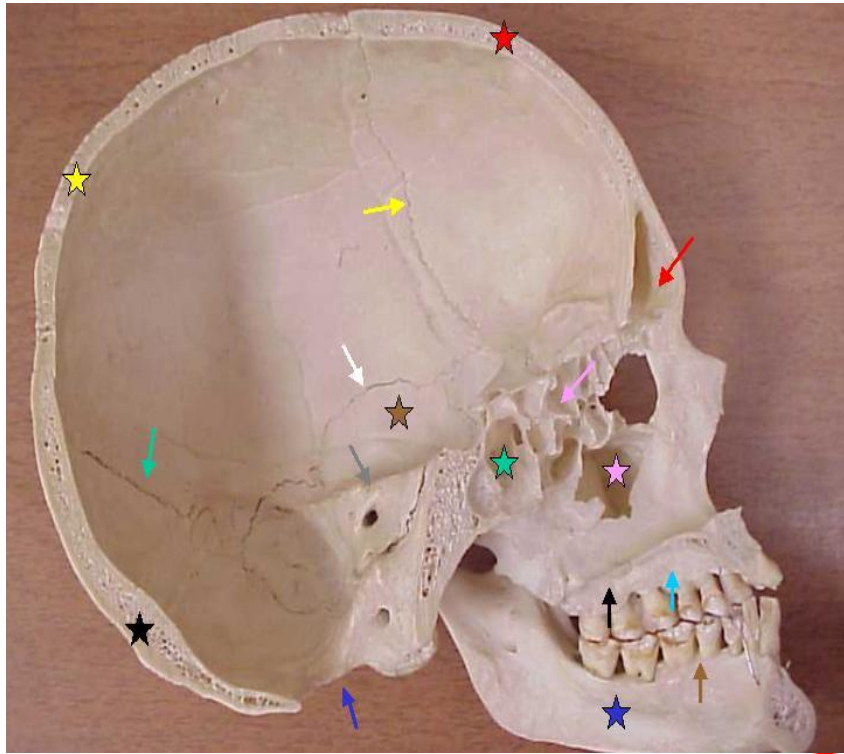
# SKULL LATERAL

Anterior clinoid processes in the lesser wing

Posterior clinoid processes



# Skull lateral

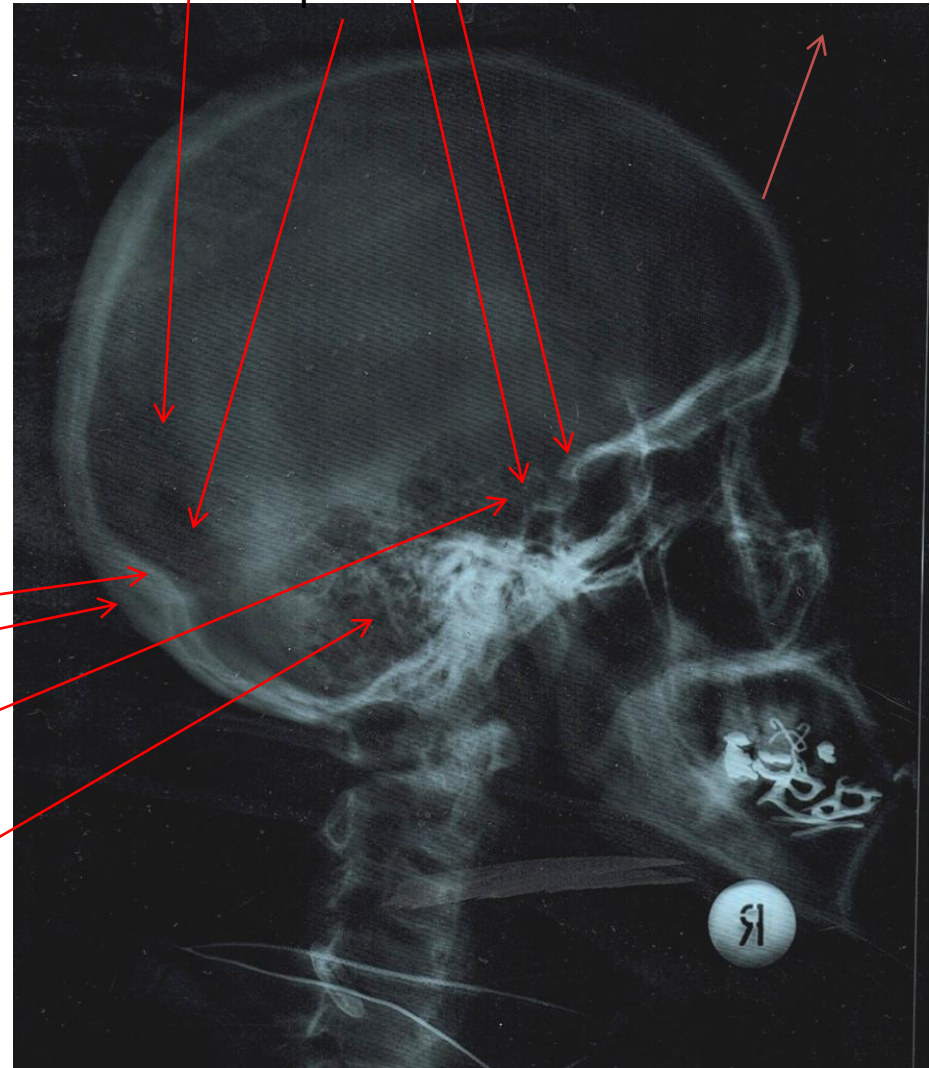


Lambdoid suture

Posterior clinoid processes  
Anterior clinoid processes

Frontal bone

occipital bone

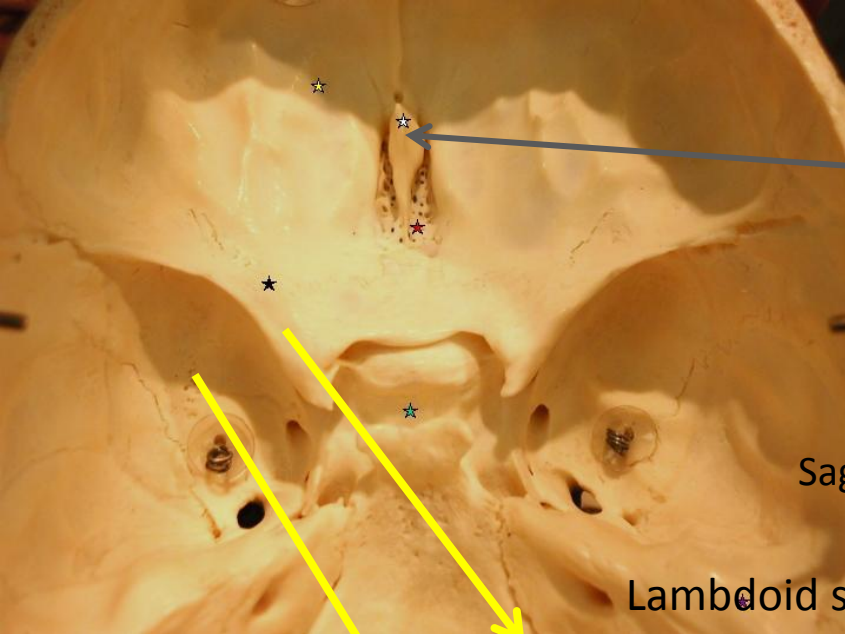


Internal occipital protuberance

(inion) External occipital protuberance

Dorsum sella

Mastoid portion of temporal



Supraorbital margin

PA

Crista galli of ethmoid

Sagittal suture

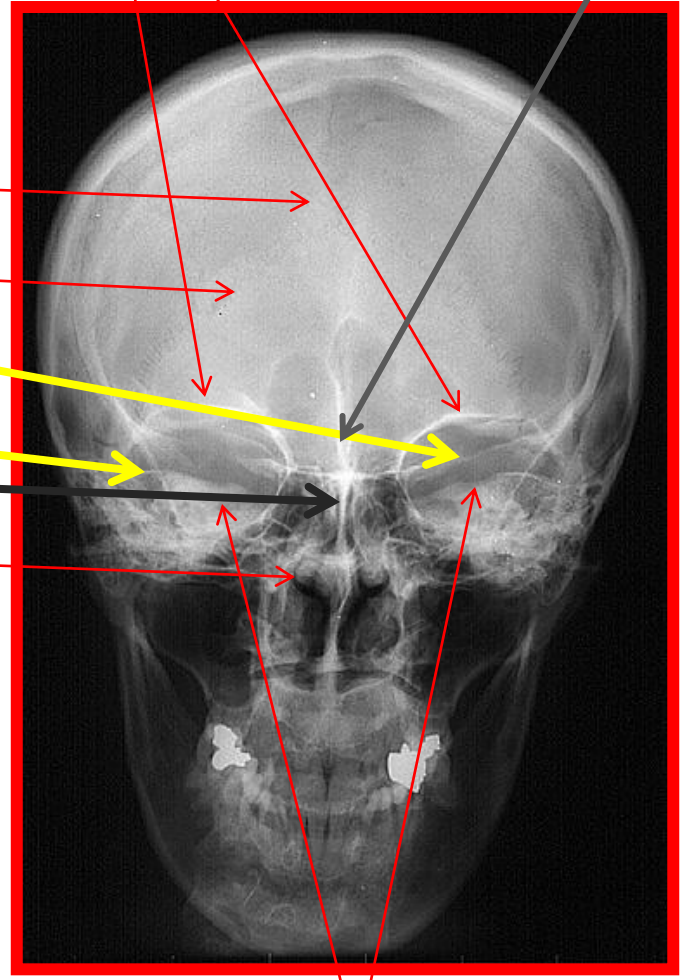
Lambdoid suture

Lesser wing of sphenoid

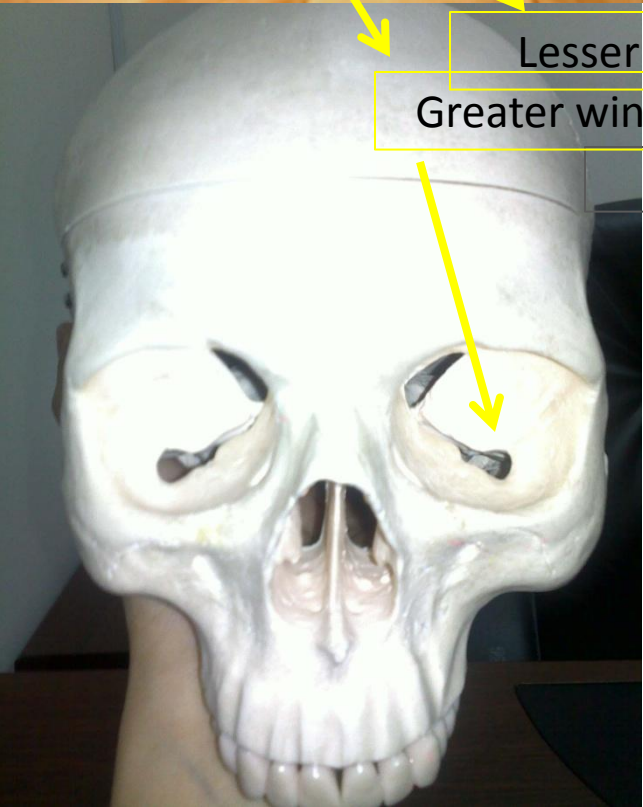
Greater wing of sphenoid

Prependicular plate

Middle nasal concha



Petrous ridge



**THANK YOU**