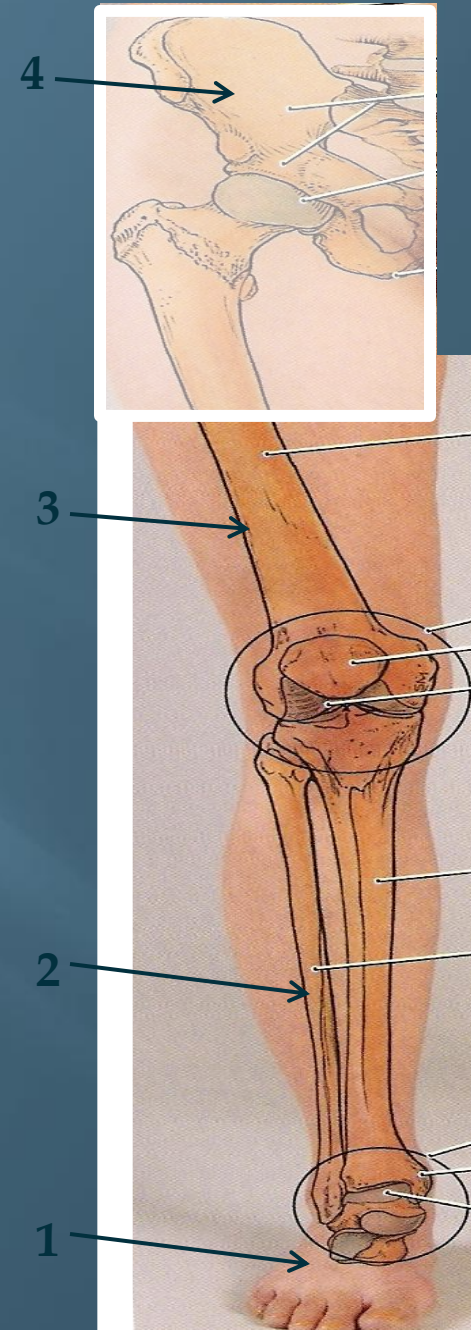


# Lower Limb

# Lower limb

The bones of the Lower limb are divided into 4 groups :

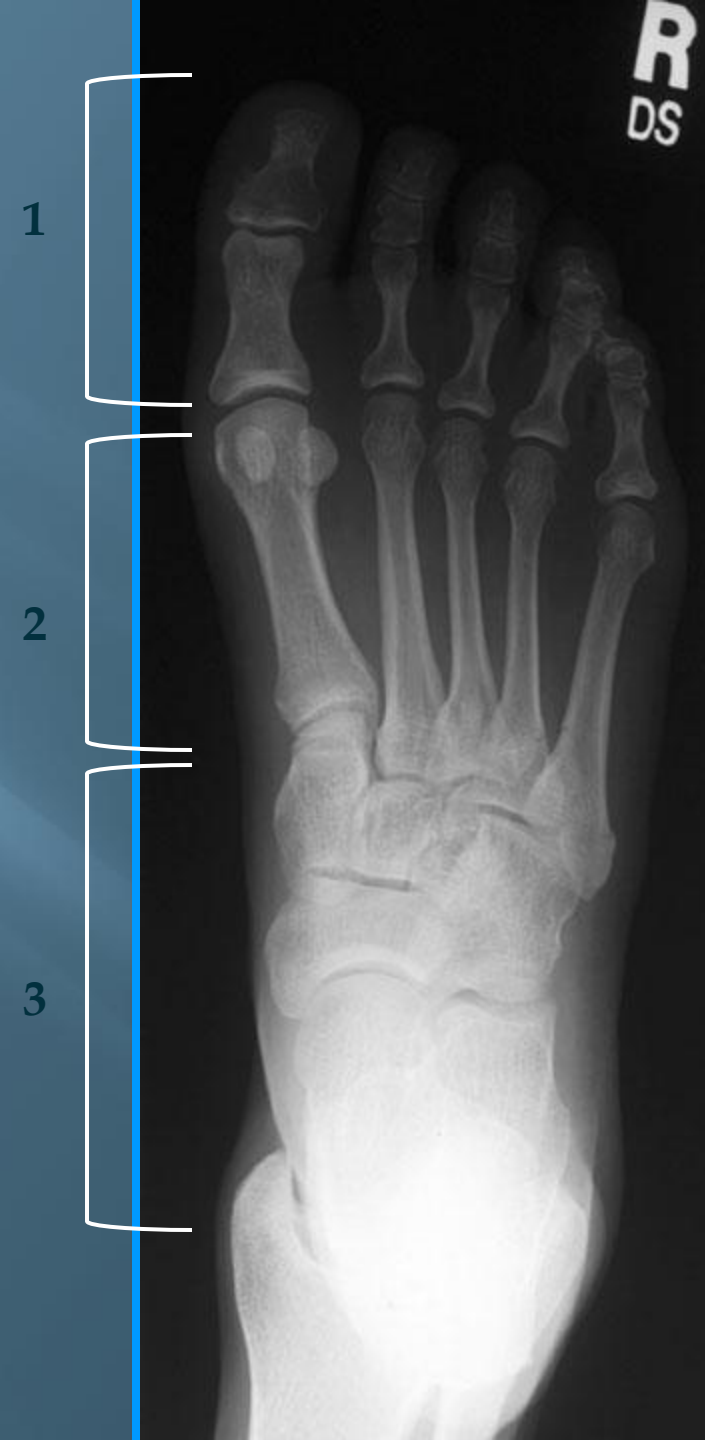1. The foot .
2. Leg .
3. Femur .
4. Hip .



# 1 - The Foot

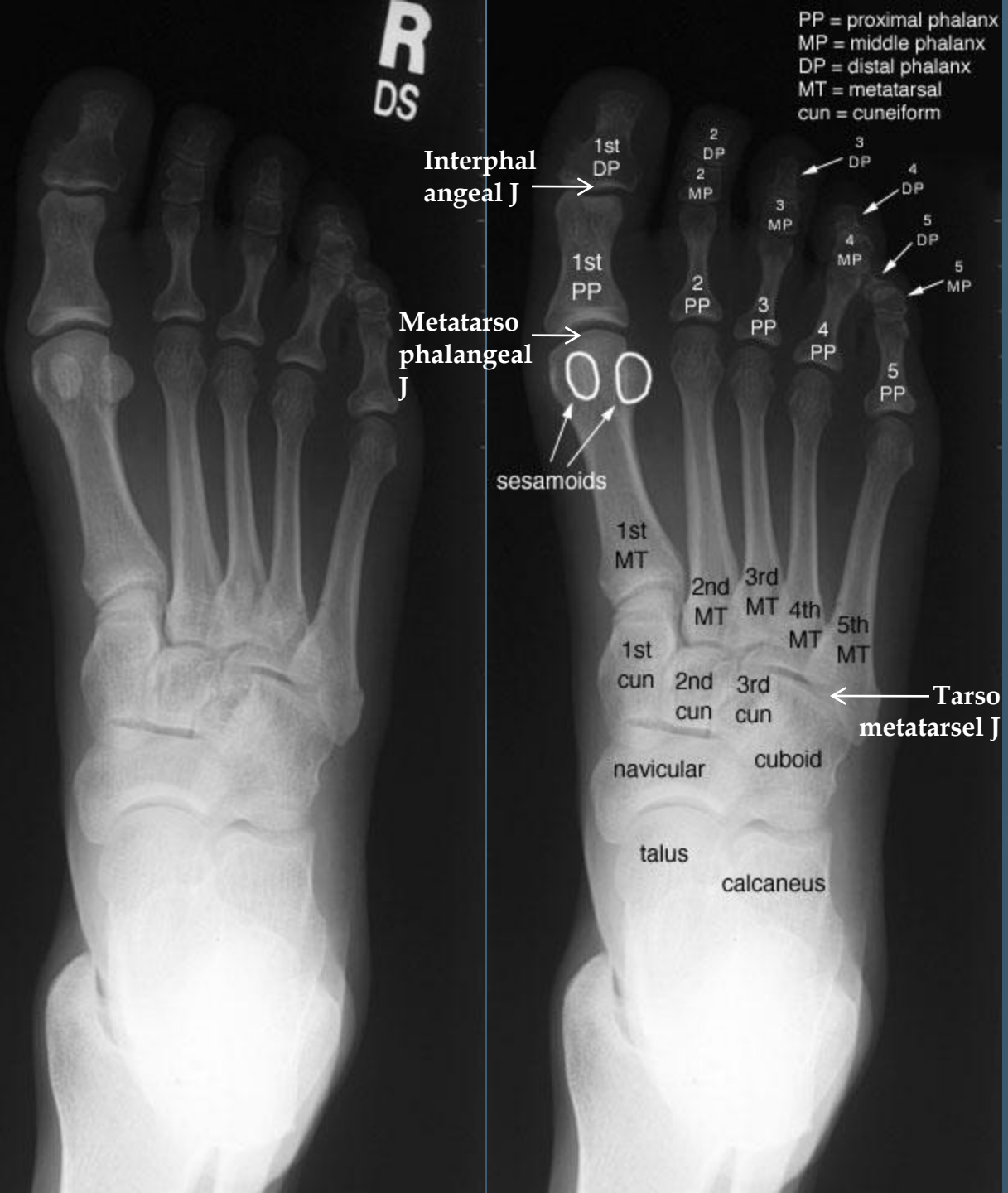
There are 26 bones of one Foot divided into 3 groups :

1. Phalanges (toes / digits )	14
2. Metatarsals	5
3. Tarsals	7
	<hr/>
Total	26



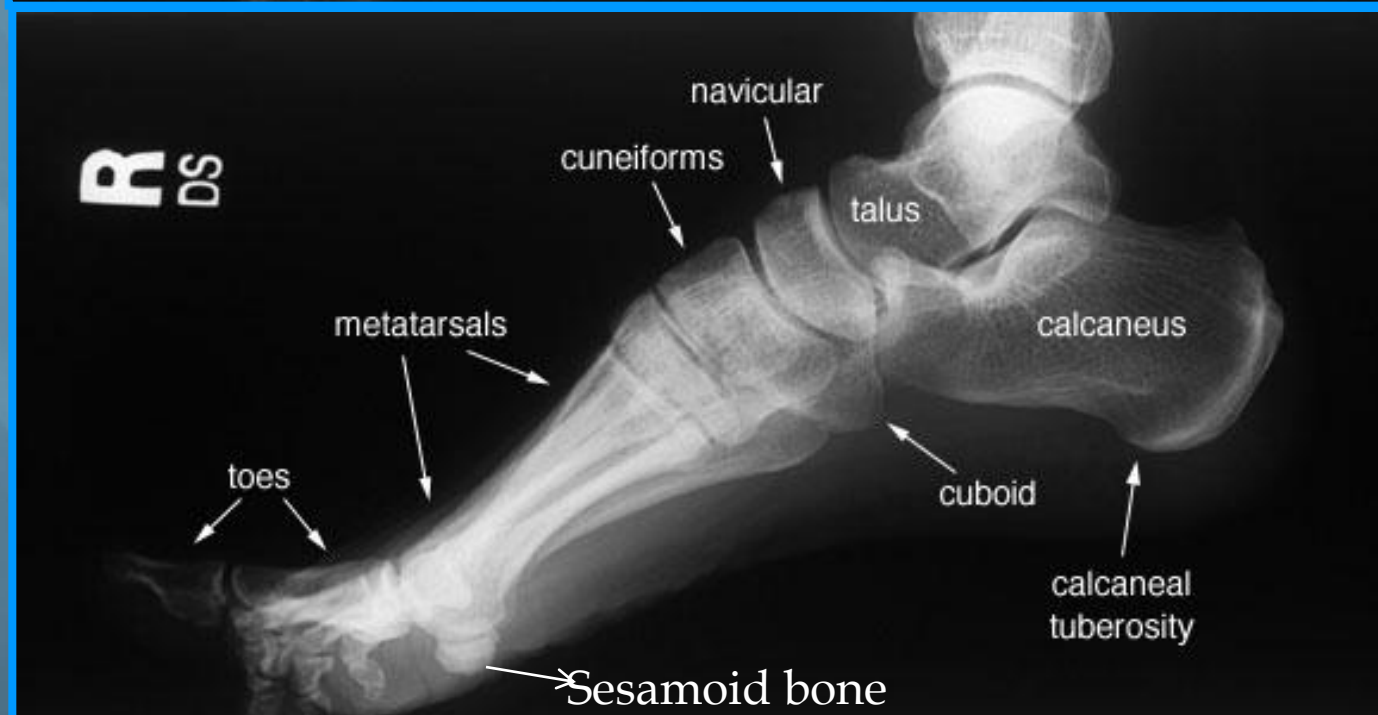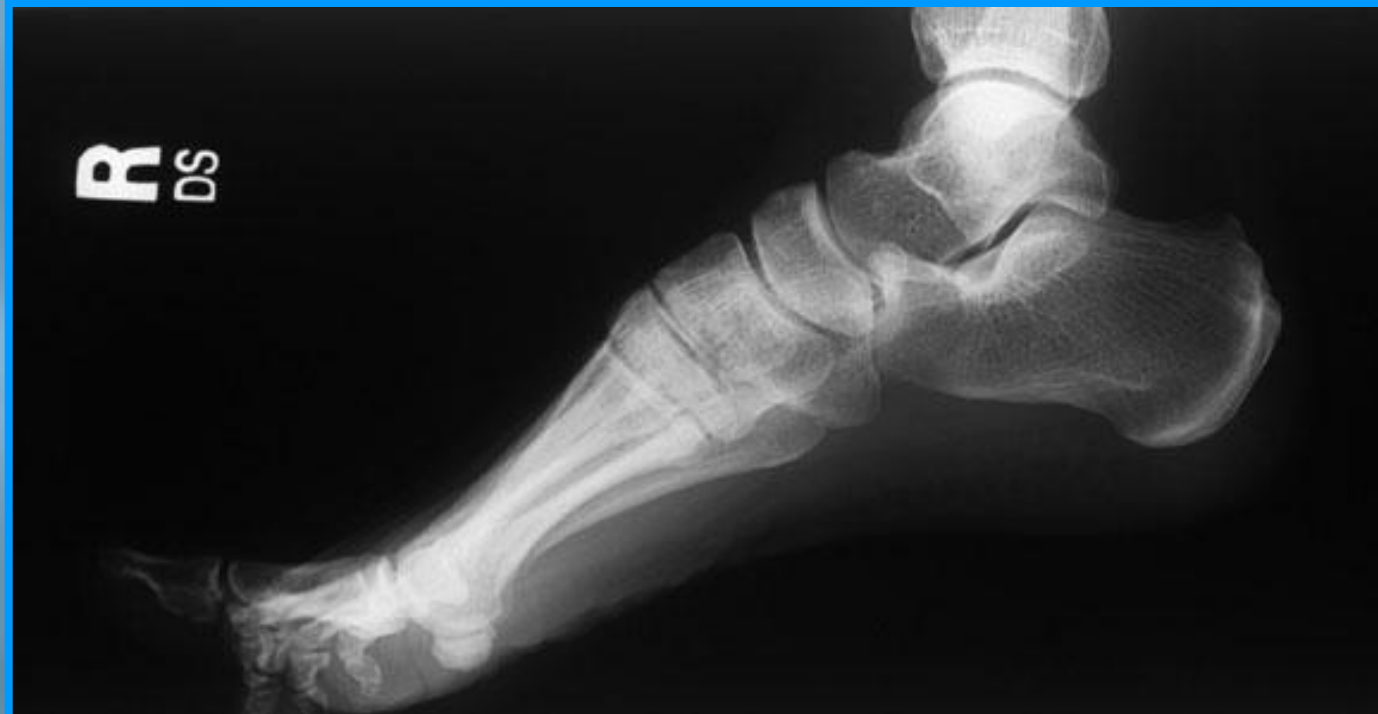# Foot

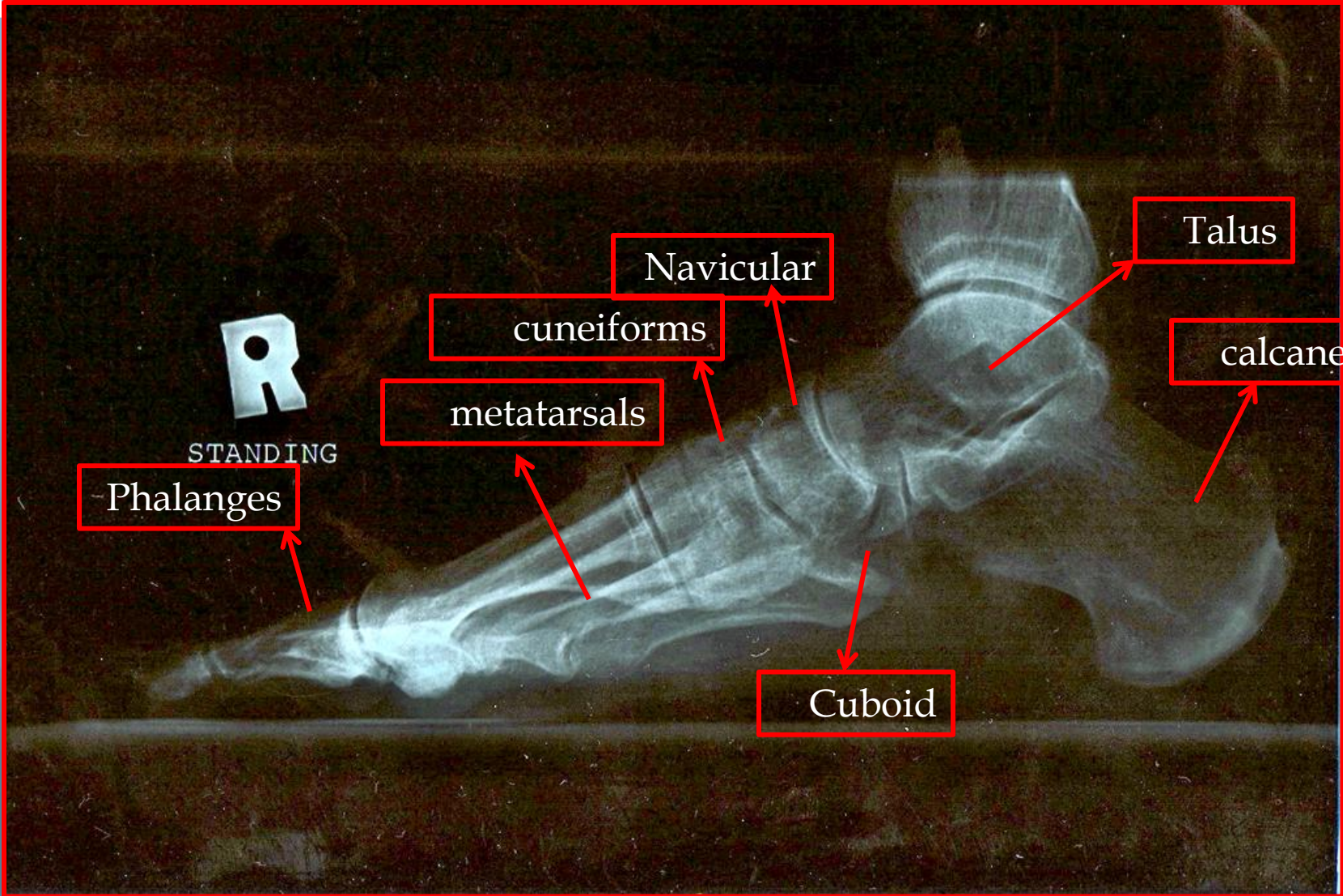
## AP view



# Foot

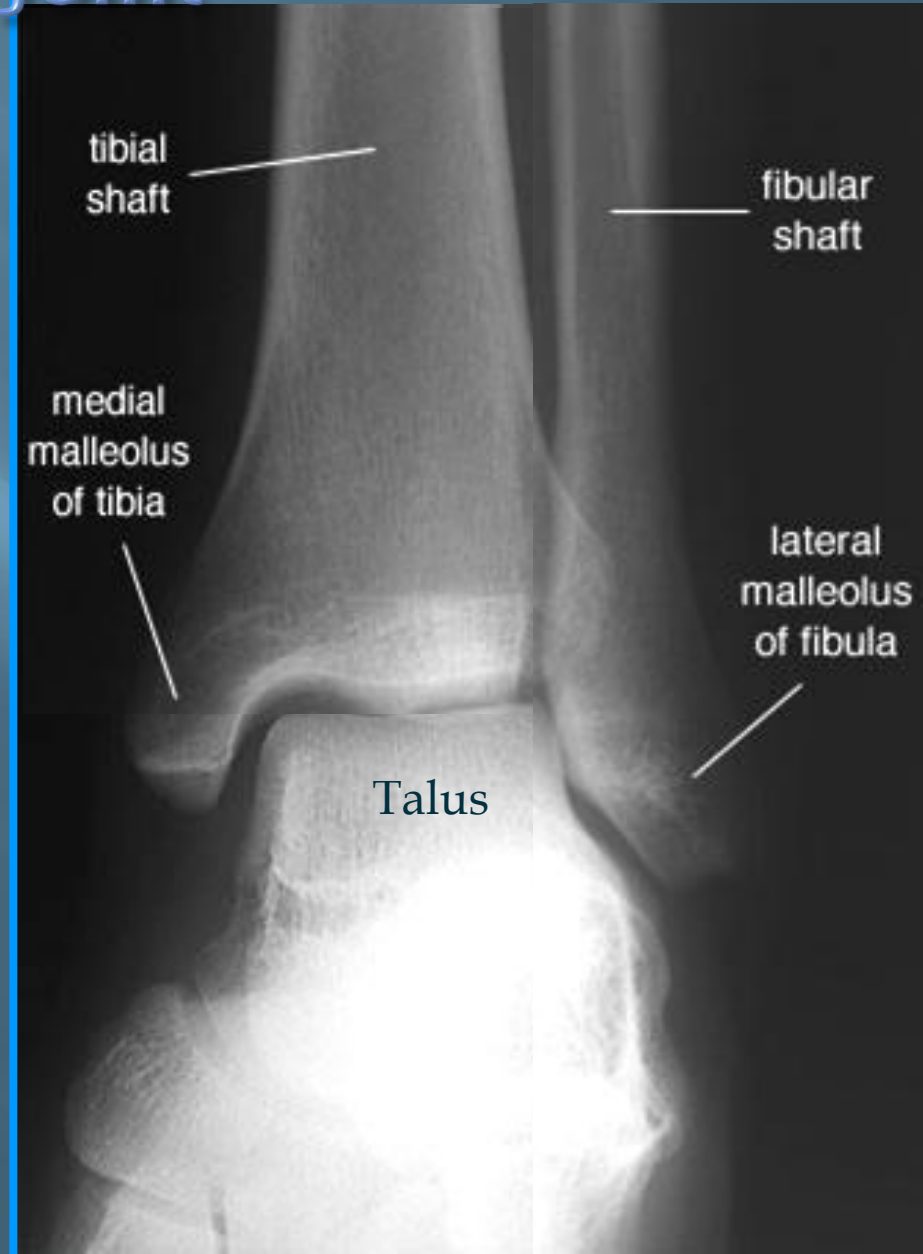
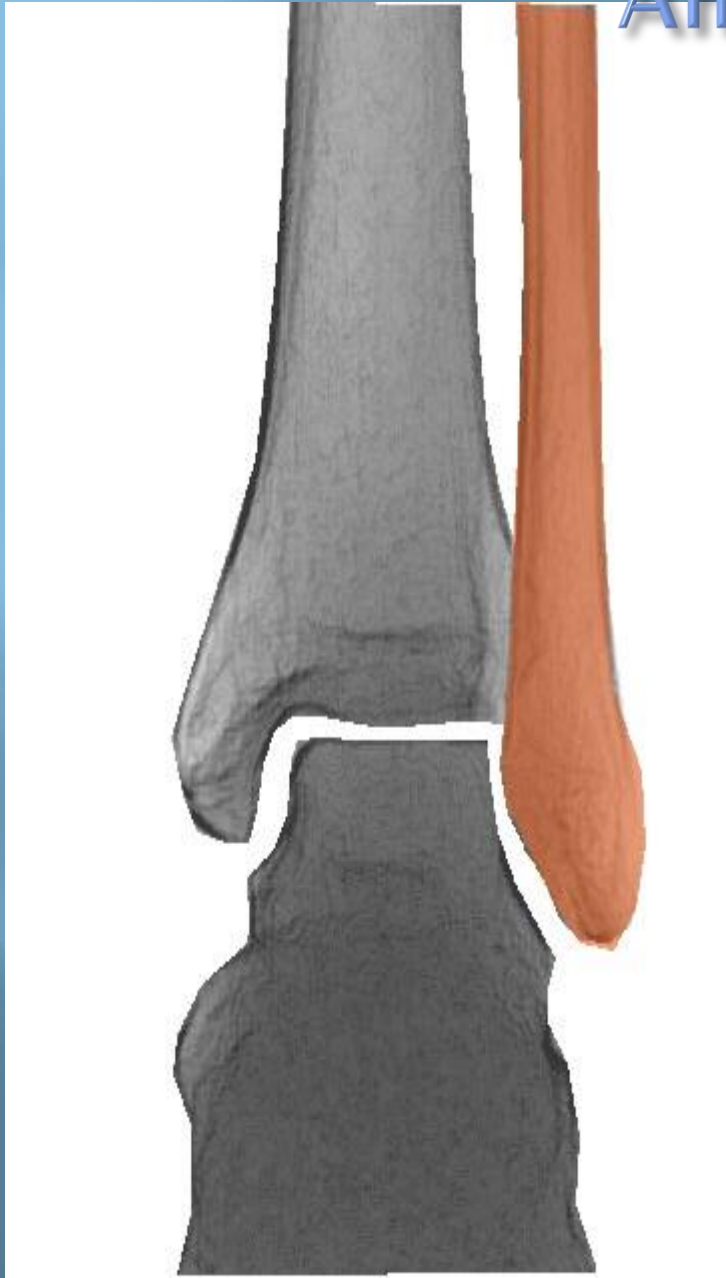
## Lateral view





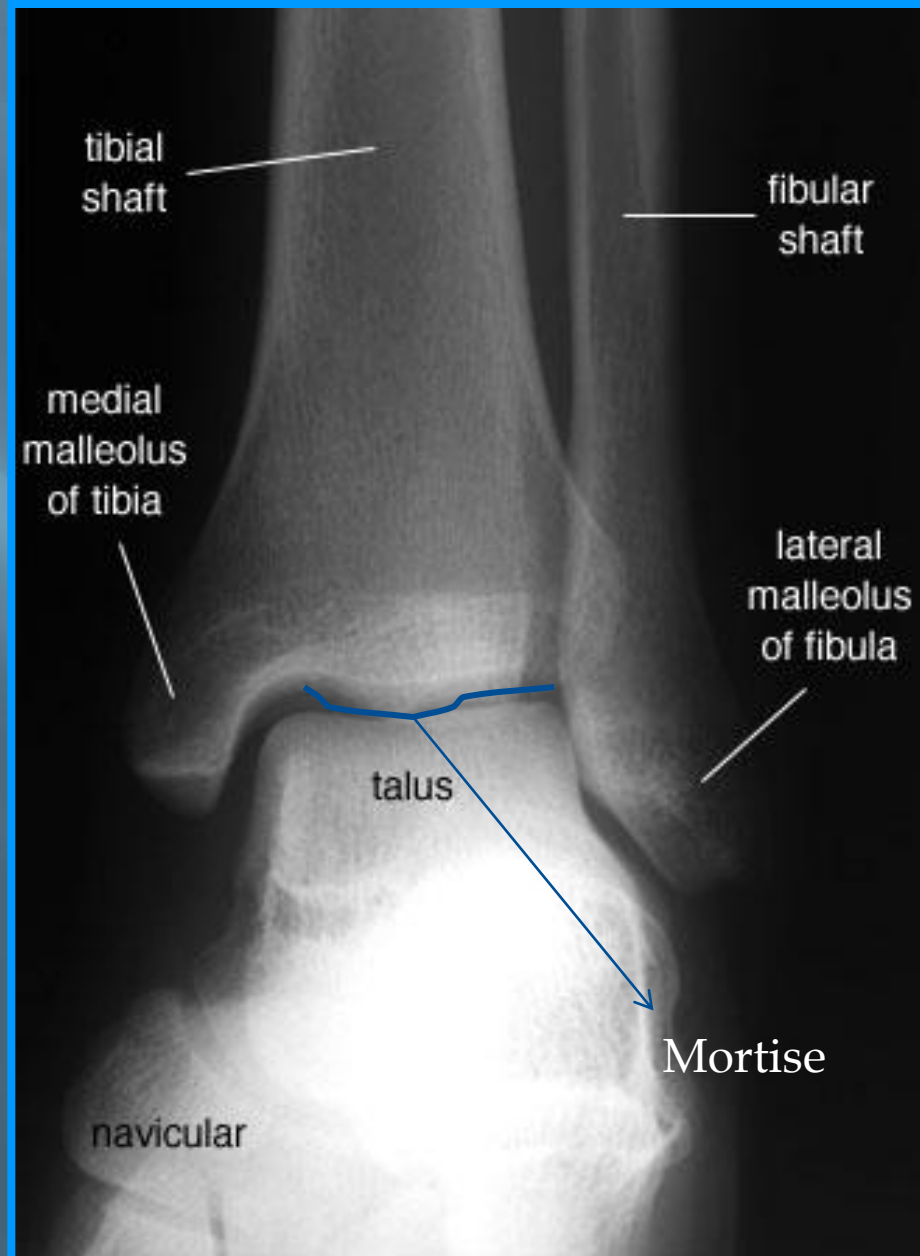
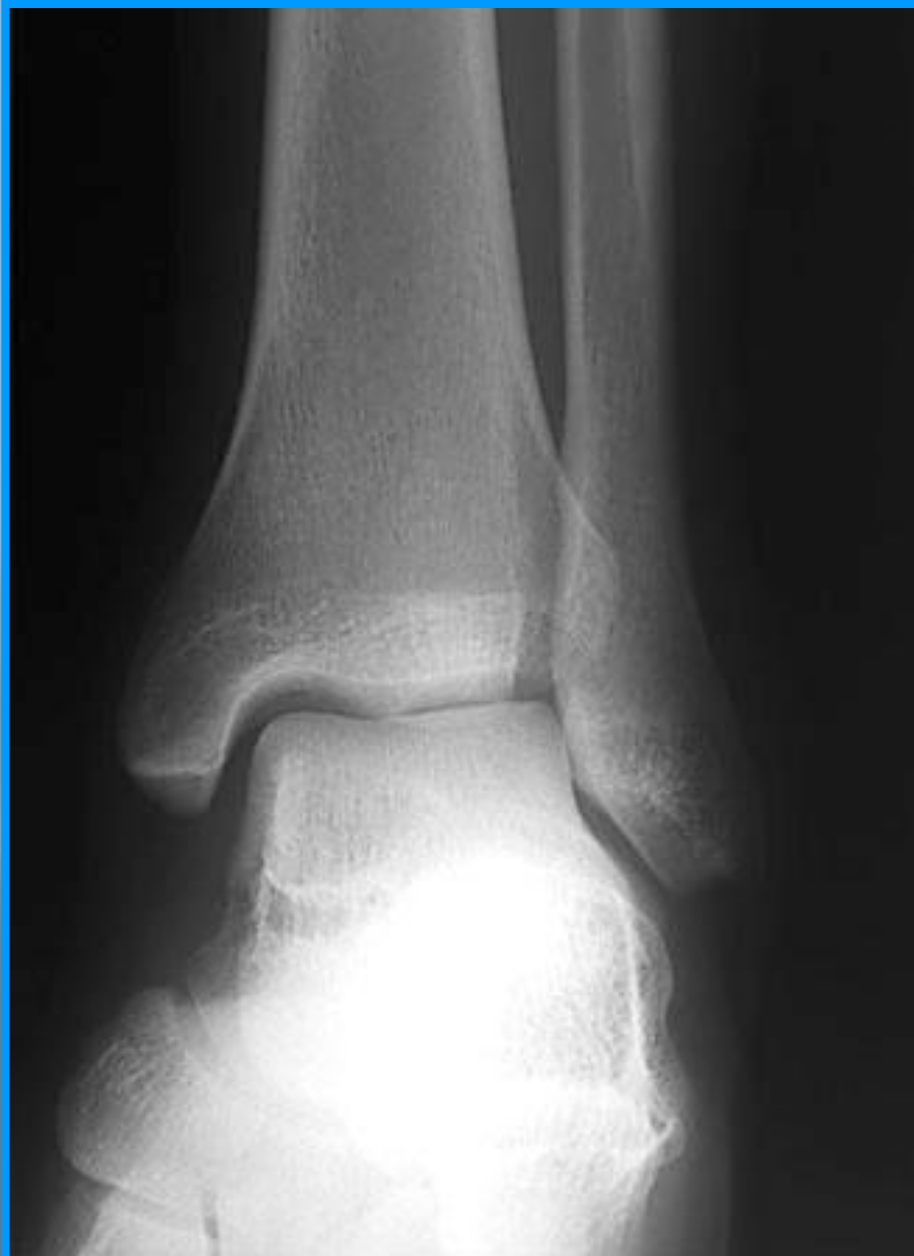# LT Ankle, AP view

## Ankle Joint



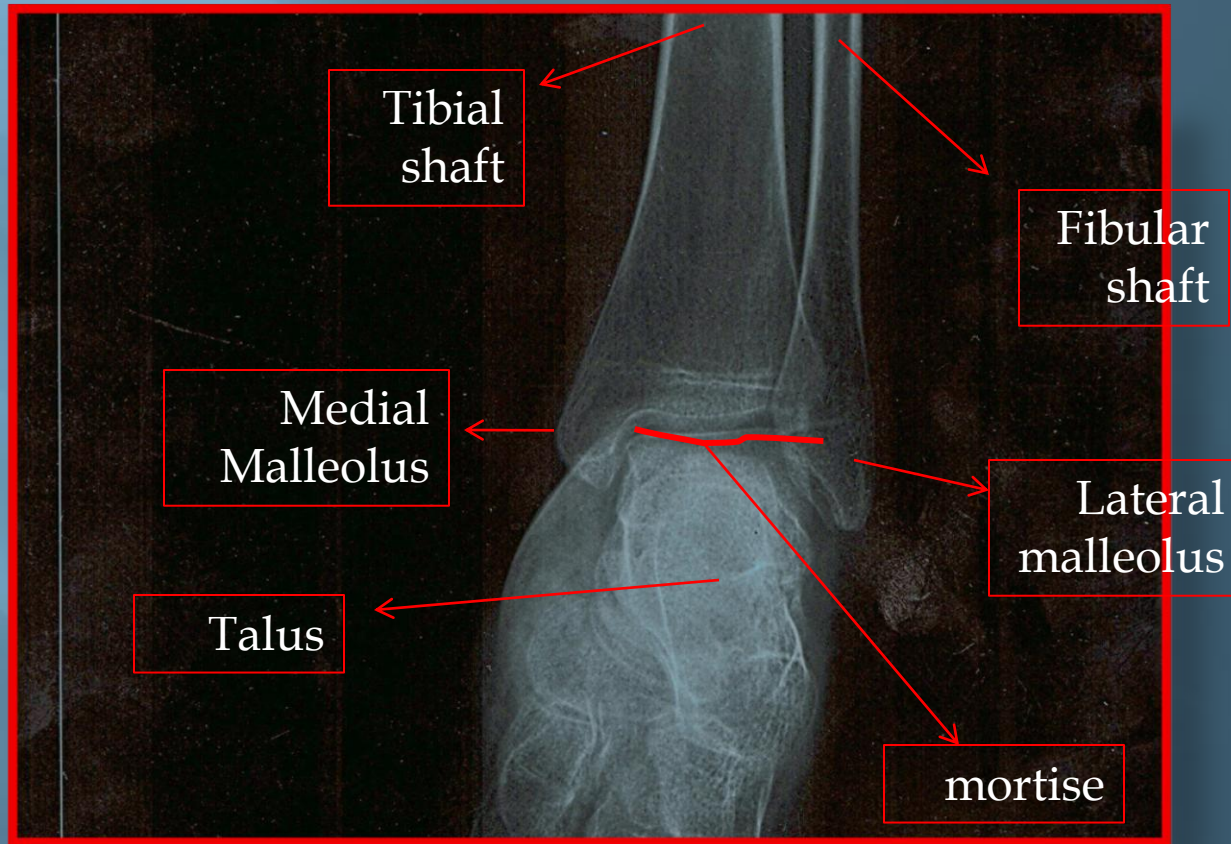
Ankle,

AP view

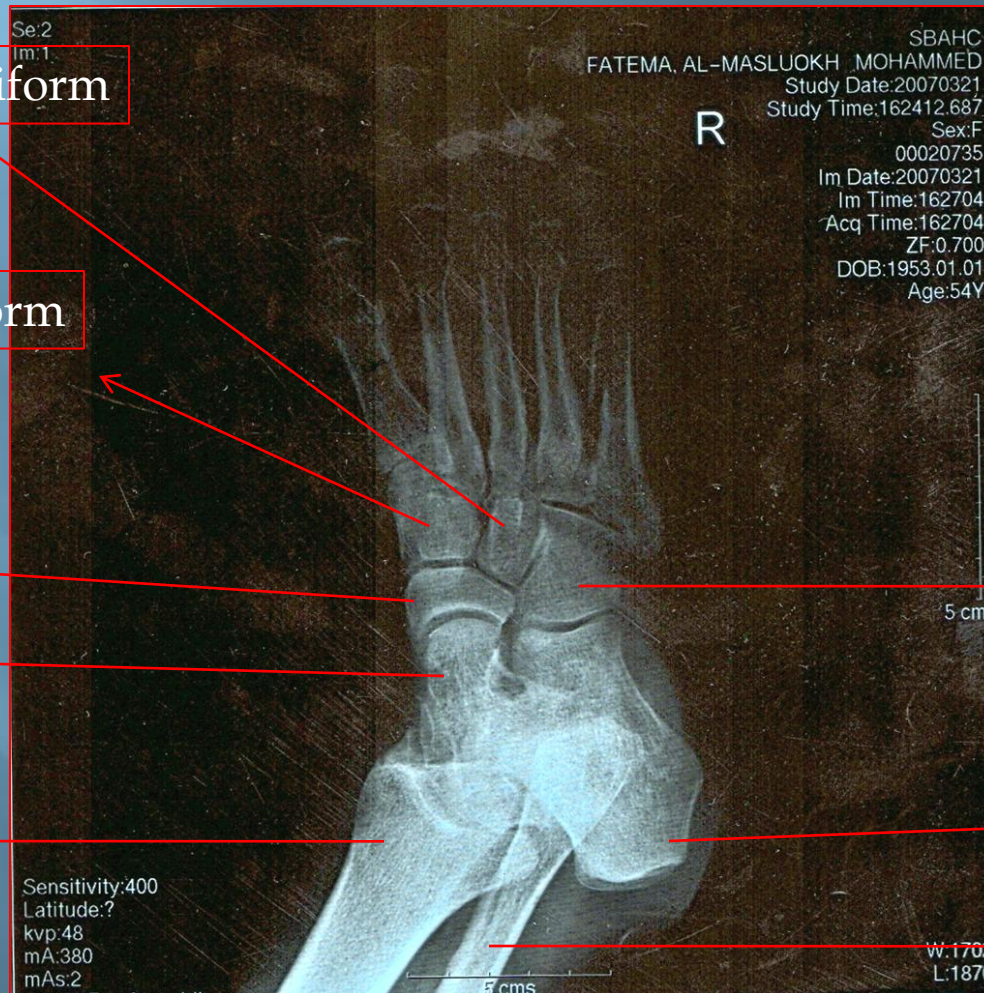




# AP Ankle L



# Rt Foot Oblique



3<sup>rd</sup> lateral Cuneiform

1<sup>st</sup> & 2<sup>nd</sup> cuneiform

Navicular

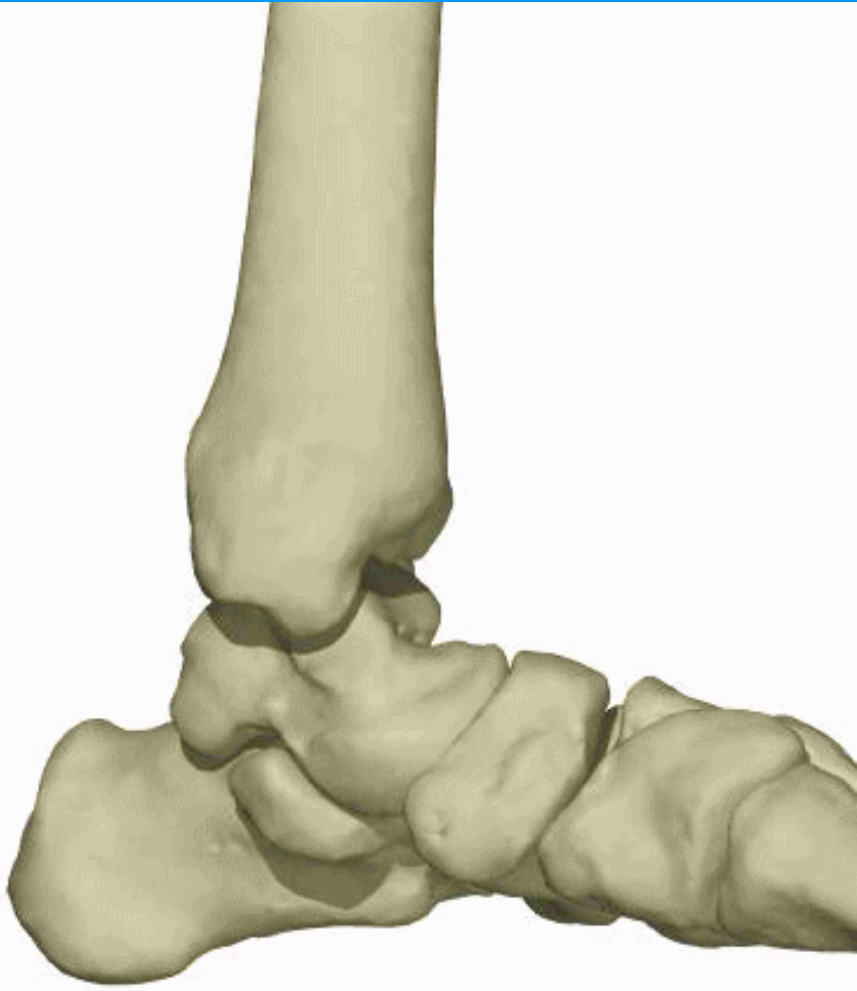
Talus

Tibia

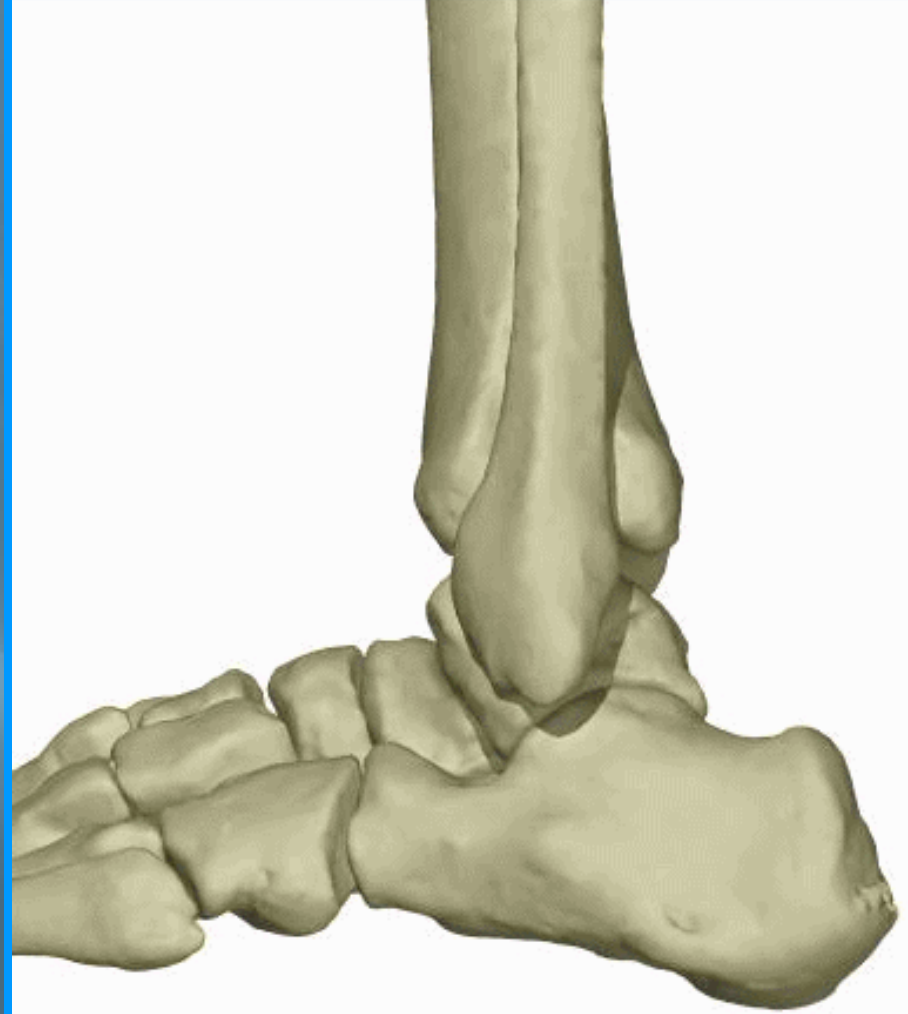
Cuboid

Calcaneus

Fibula



Medial Surface

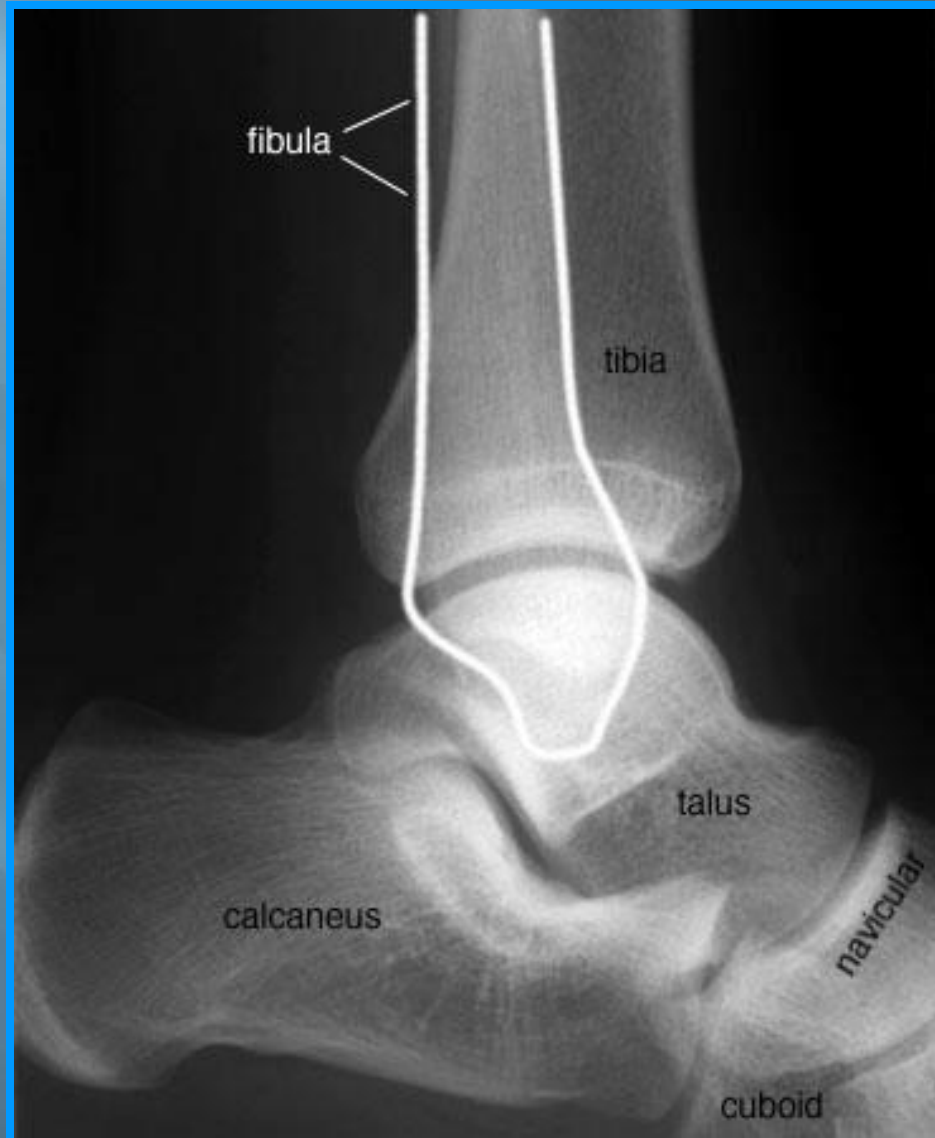

Lateral Surface

# Ankle

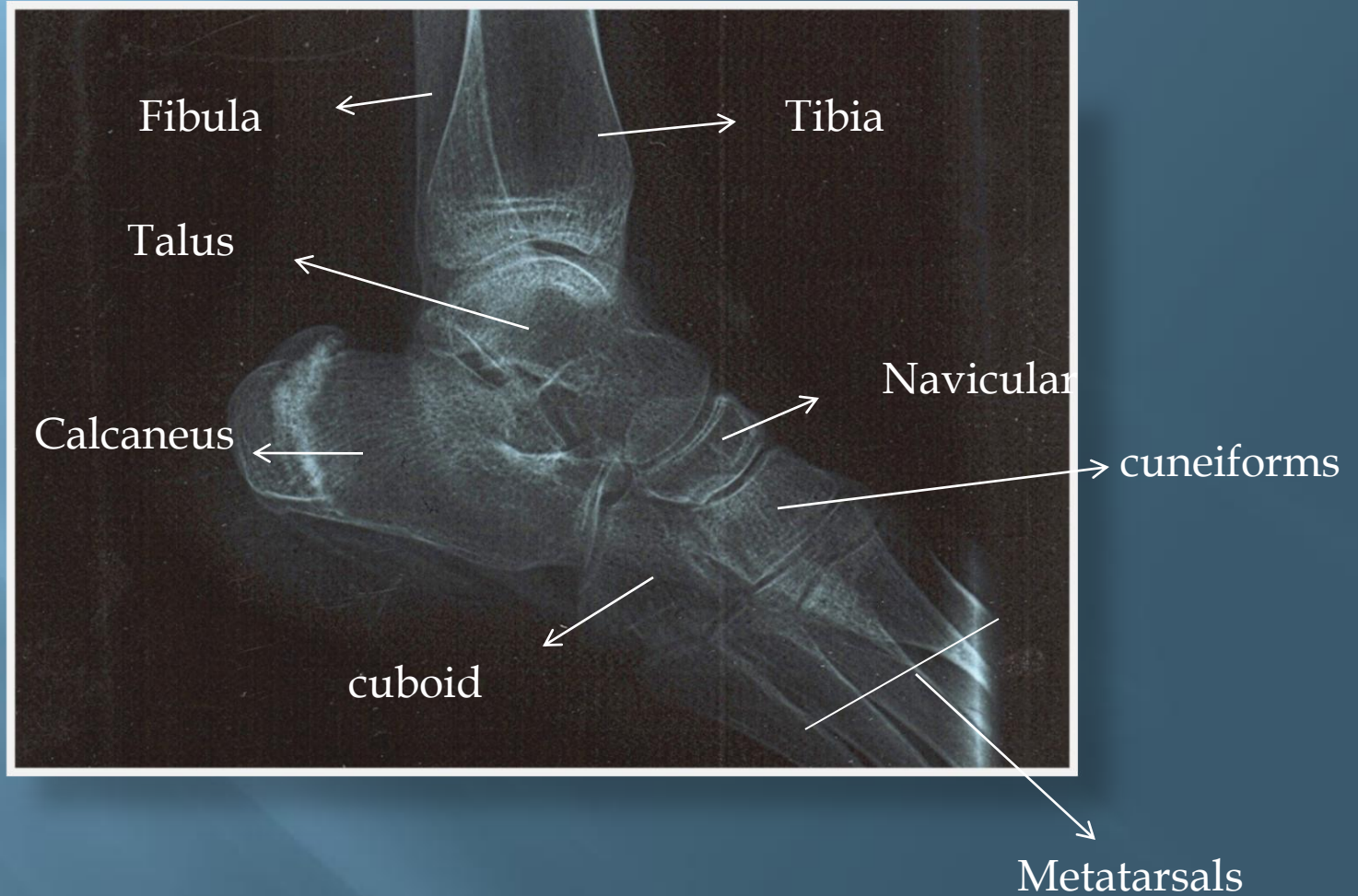
Ankle,

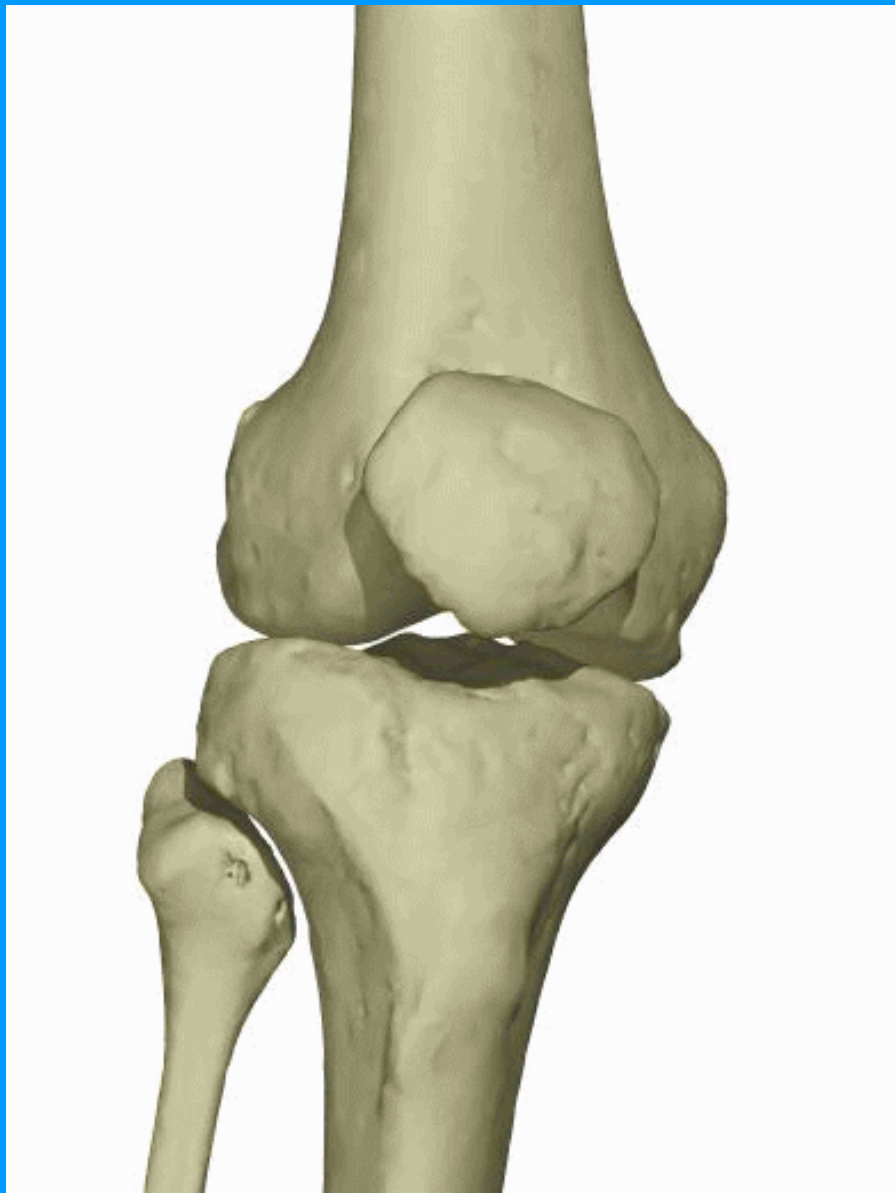
Lateral view



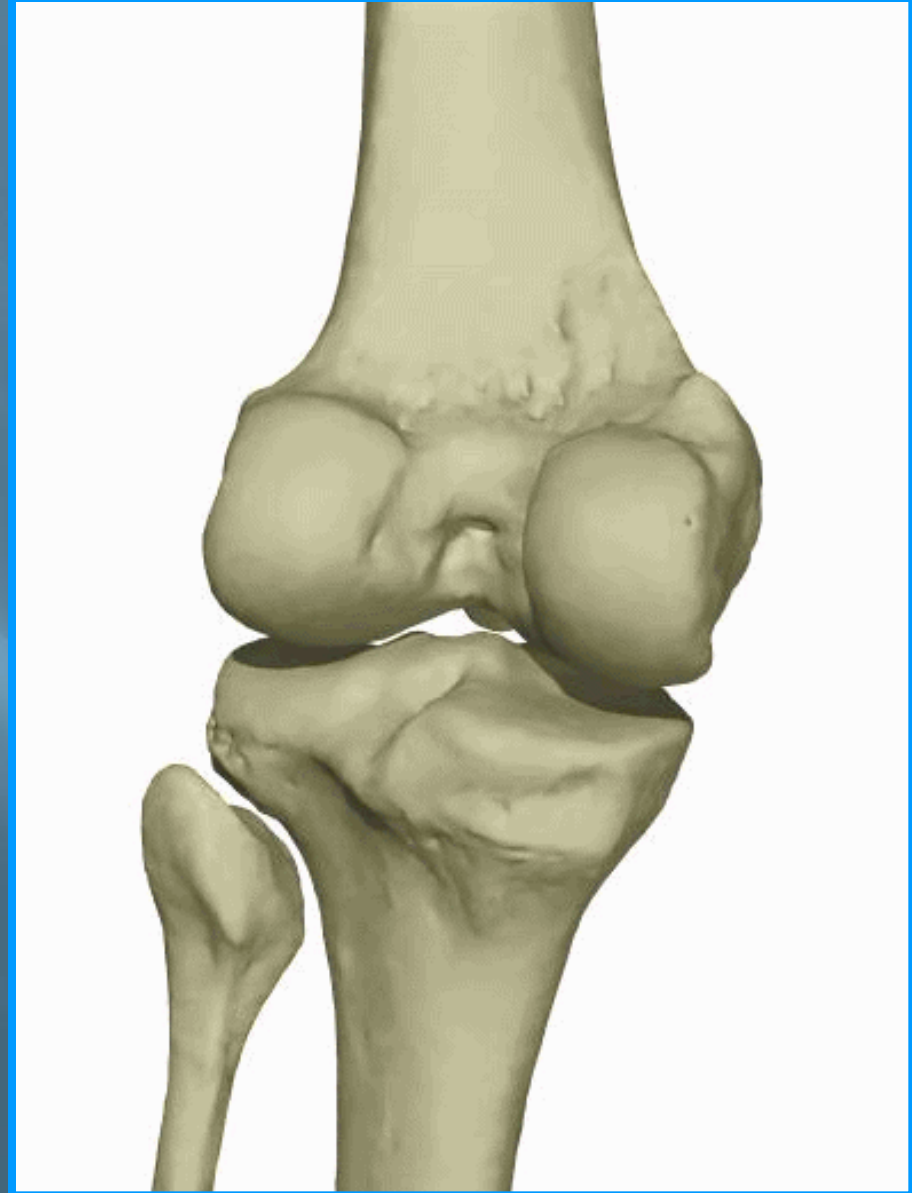
# Ankle lateral

E





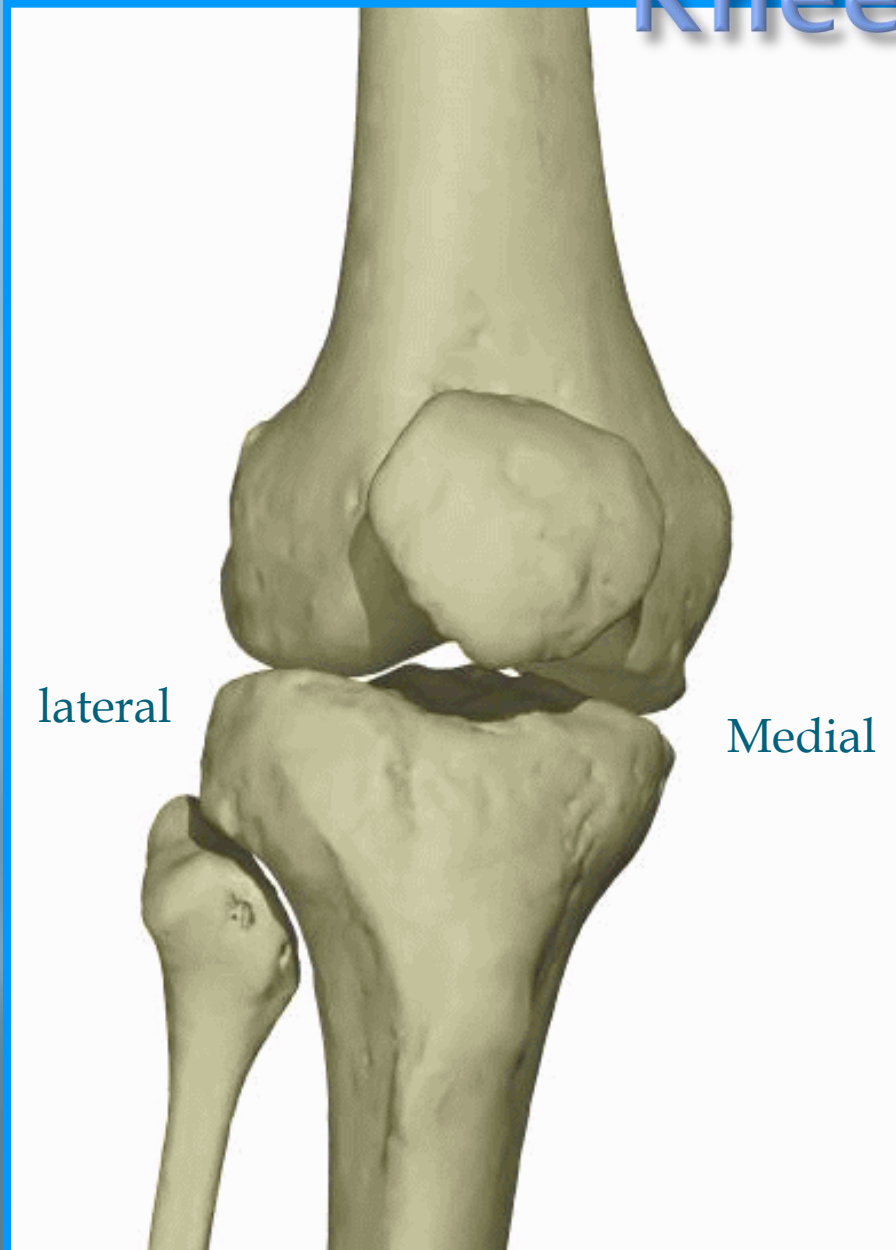
Anterior Surface



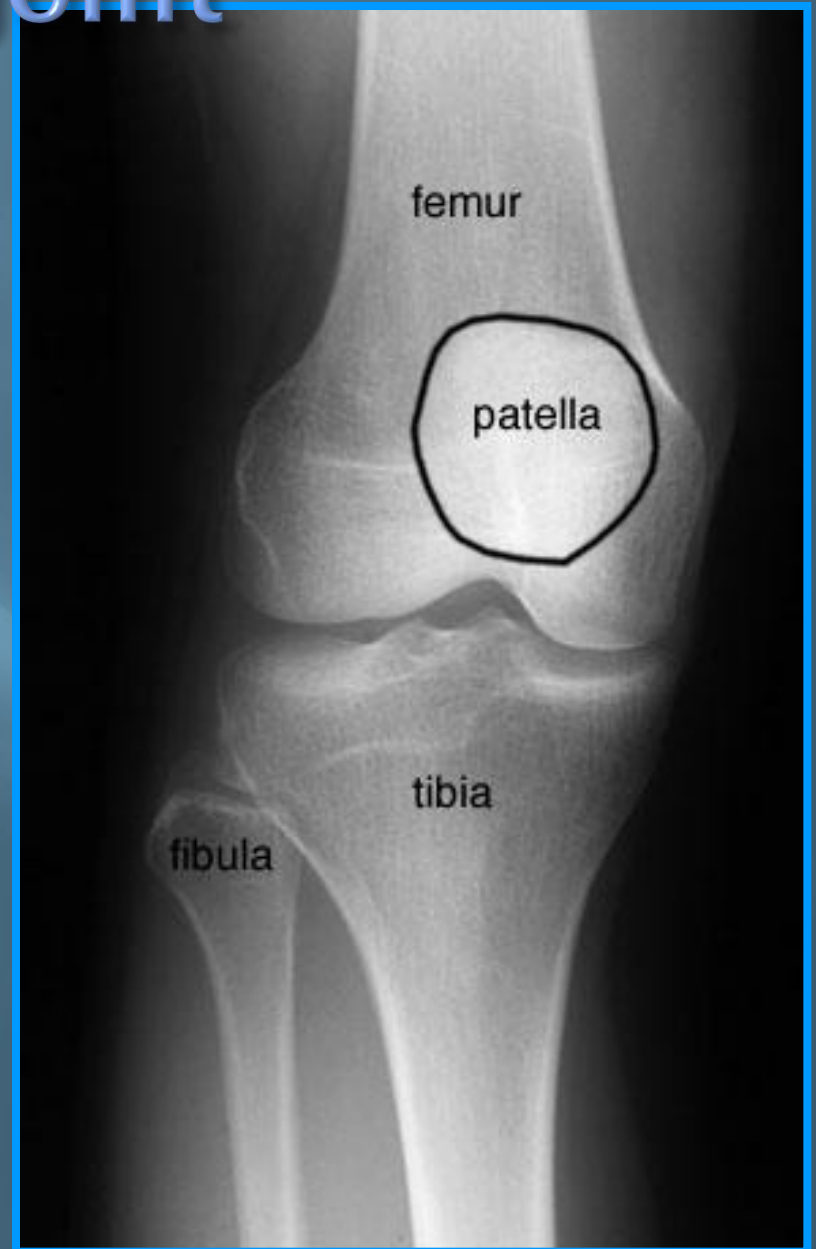Posterior Surface

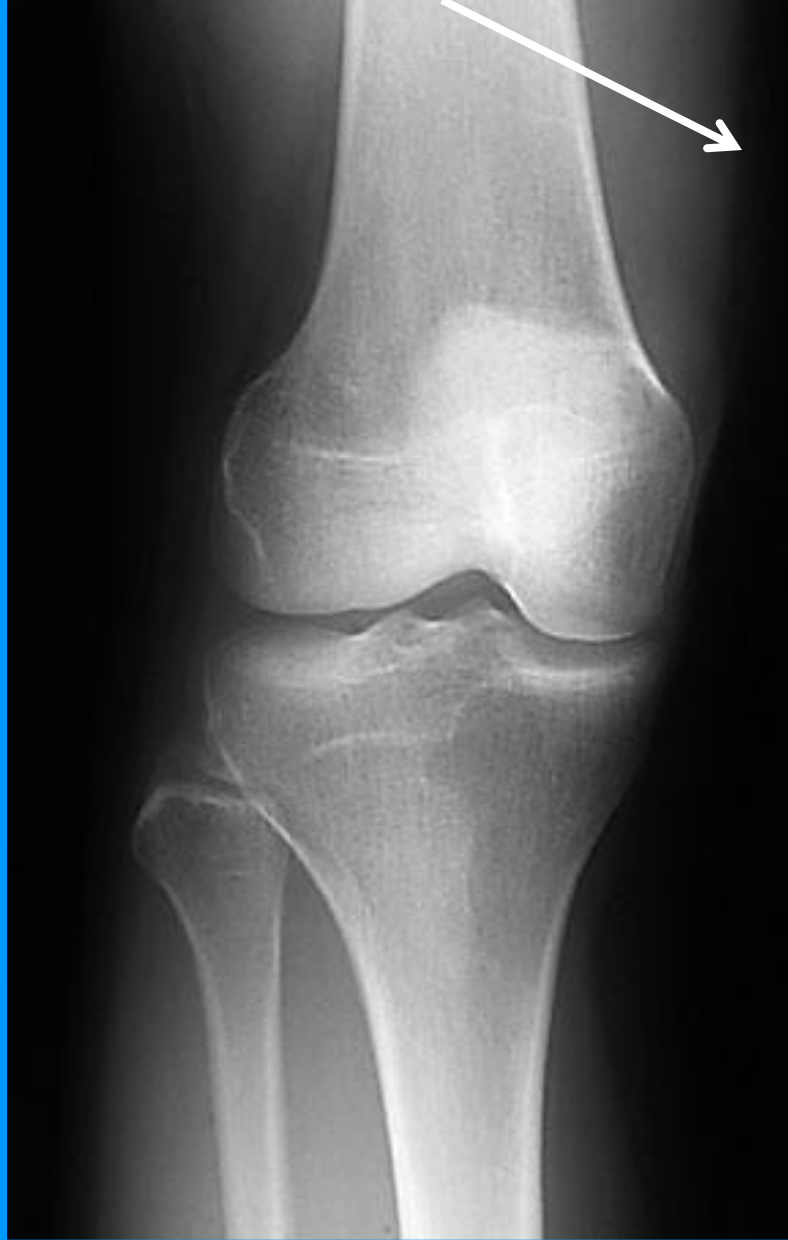# Knee

# Knee Joint

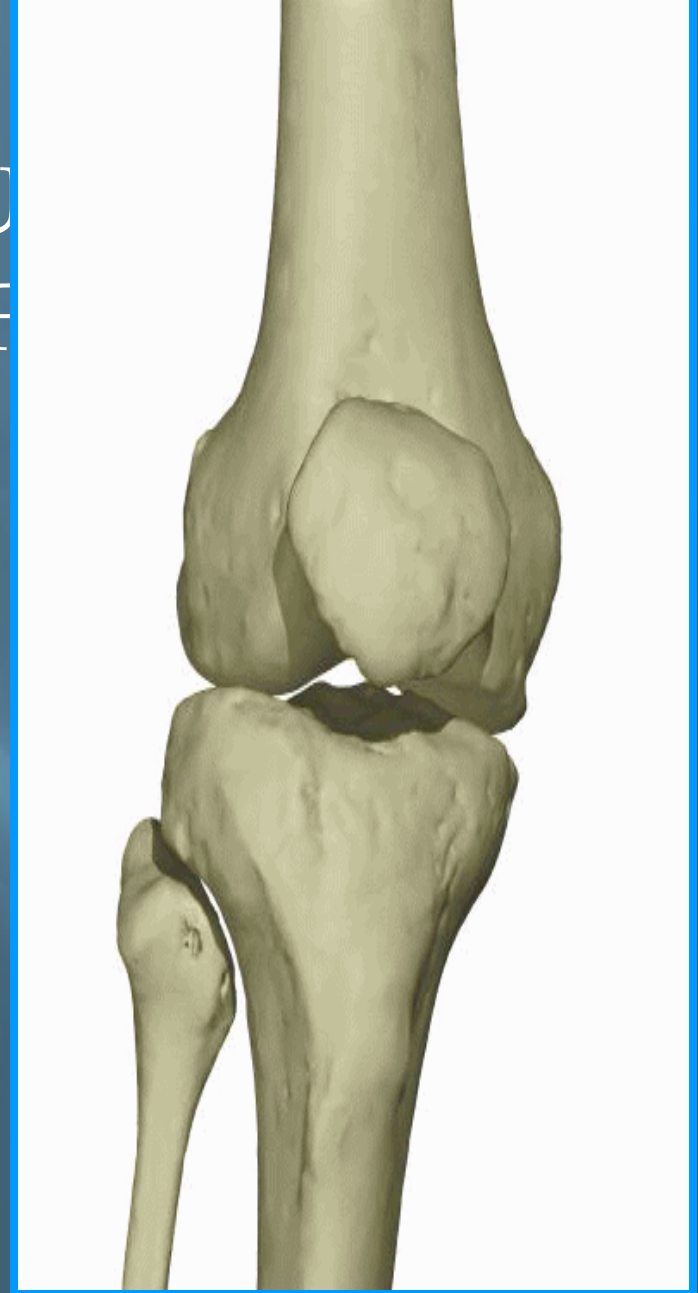


Anterior Surface

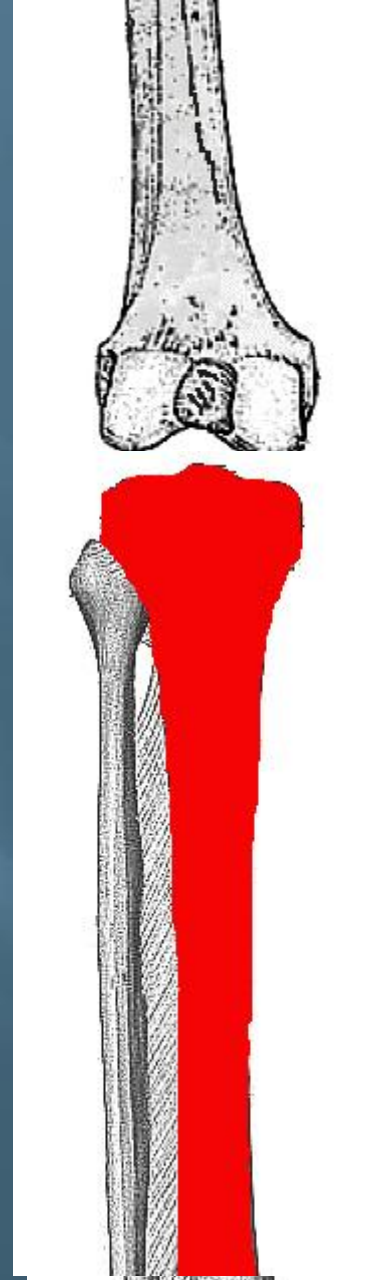
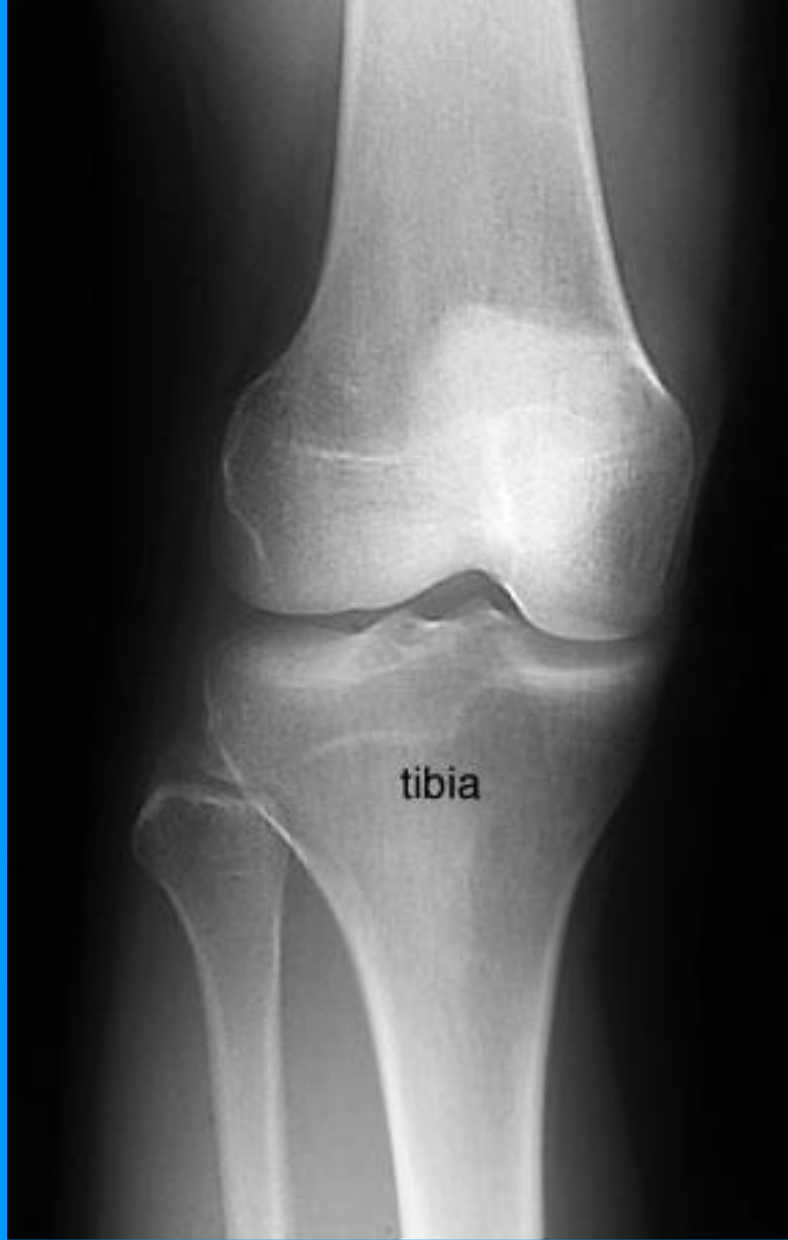

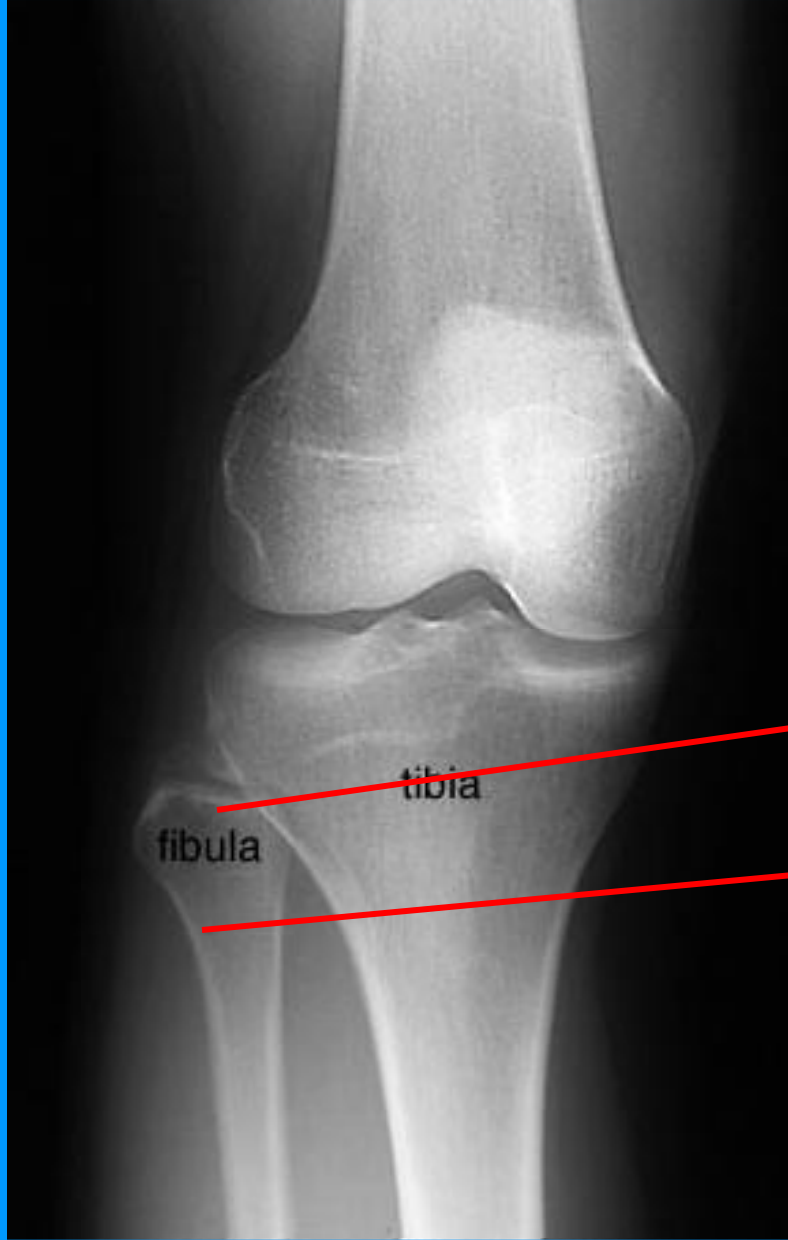


FEMUR  
SHAFT





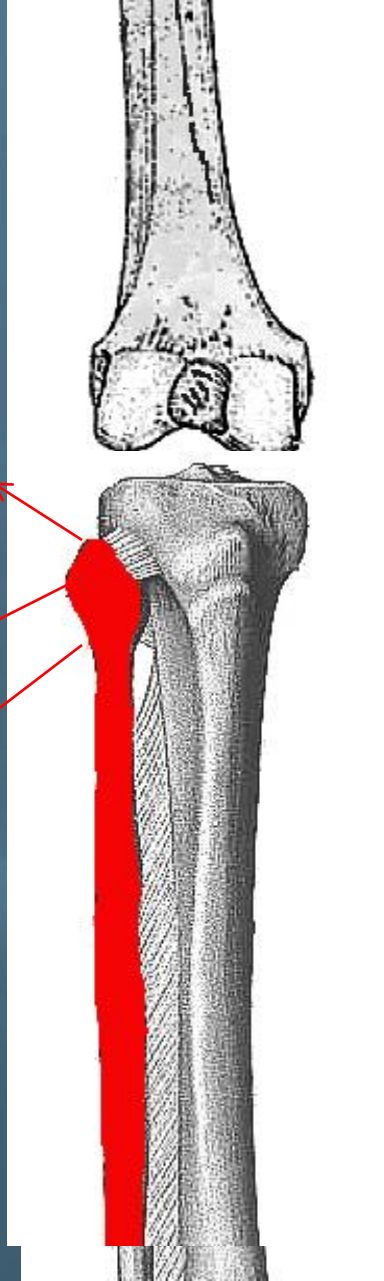


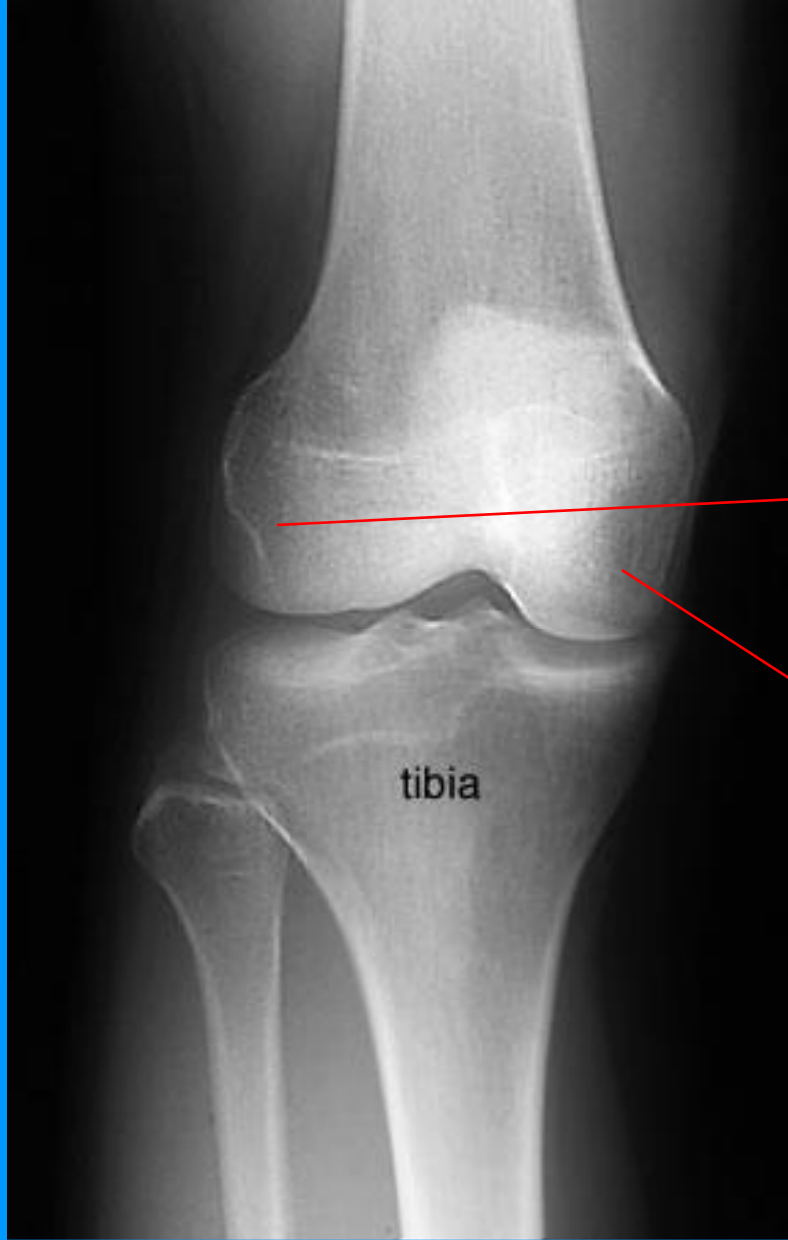


Apex styloid process

Head

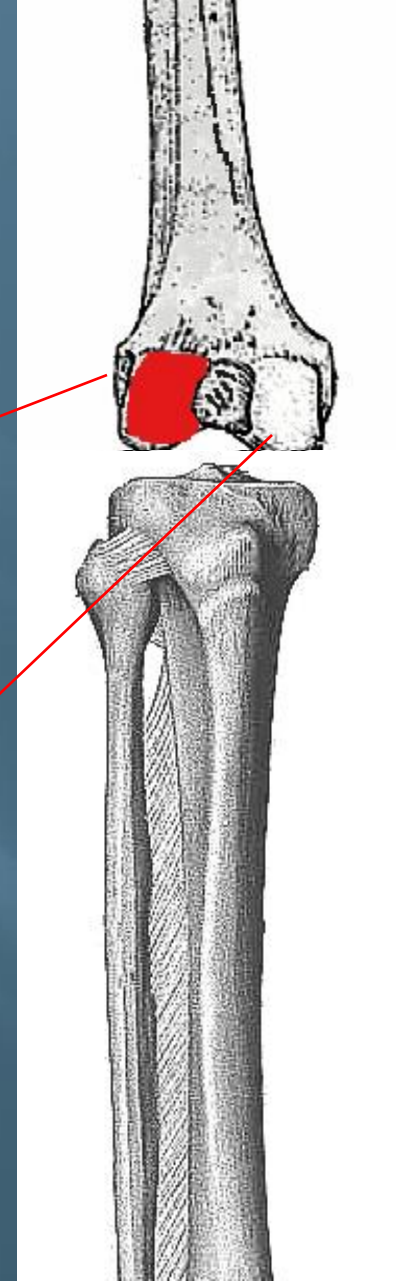
Neck

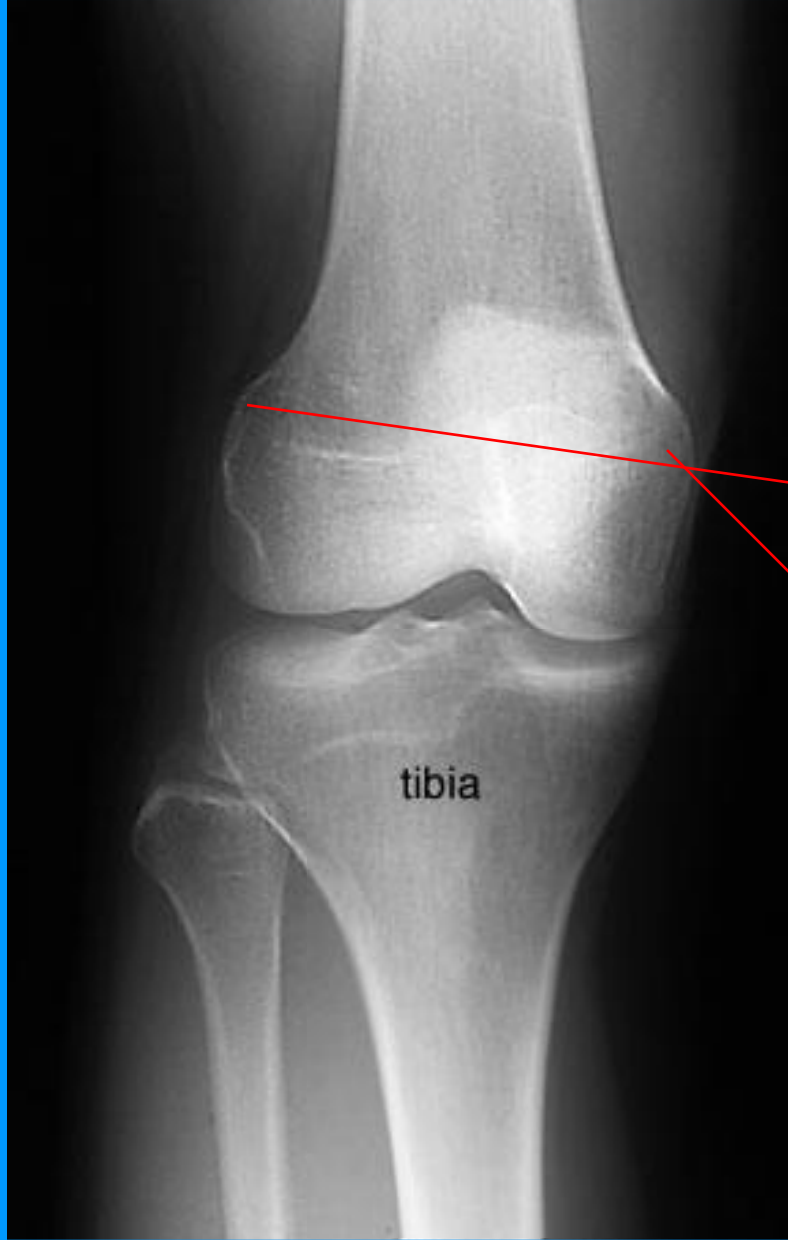



Lateral  
condyle

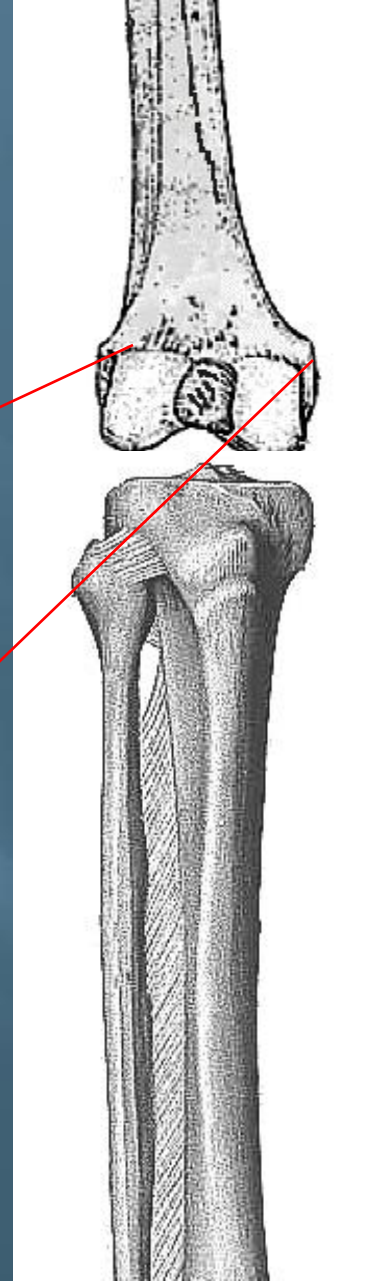
Medial  
condyle

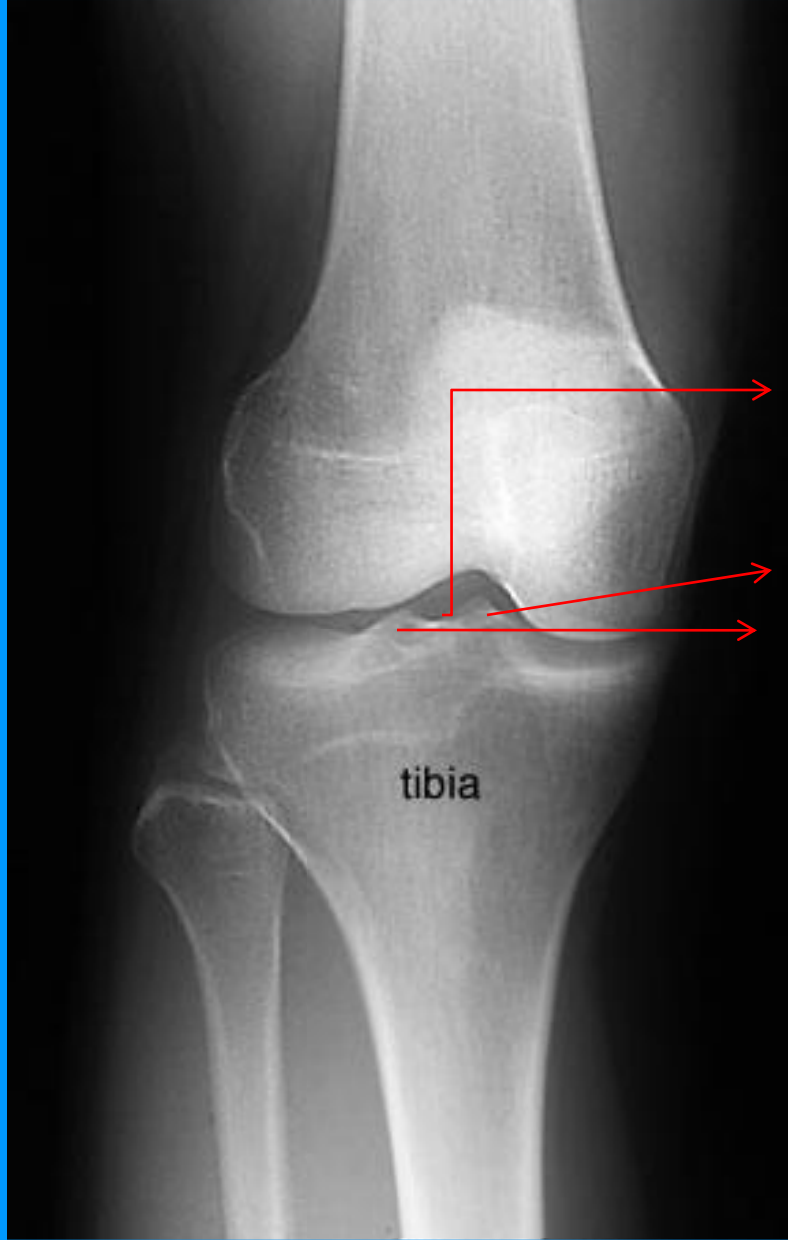




Lateral  
epicondyle

Medial  
epicondyle

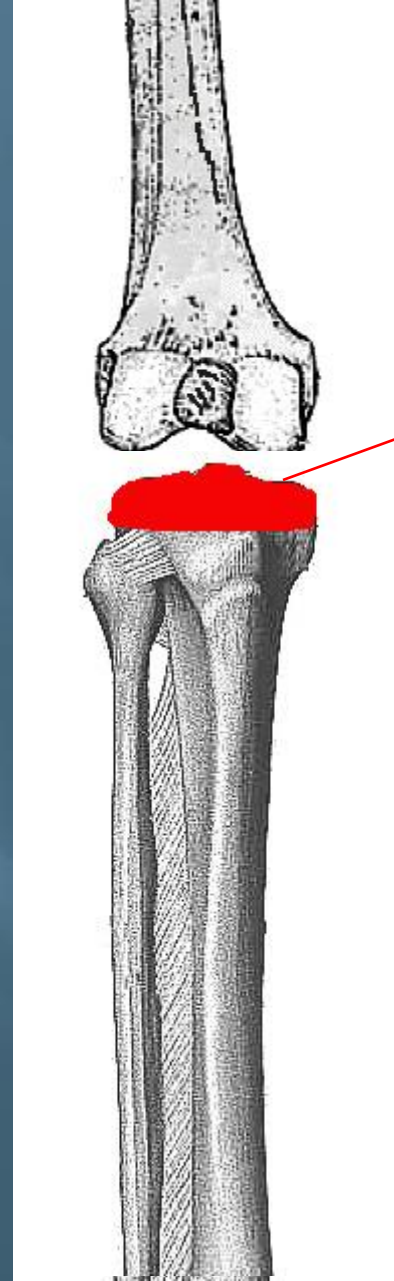




Intercondyloid  
eminence

Medial & lateral  
intercondylar  
tubercles

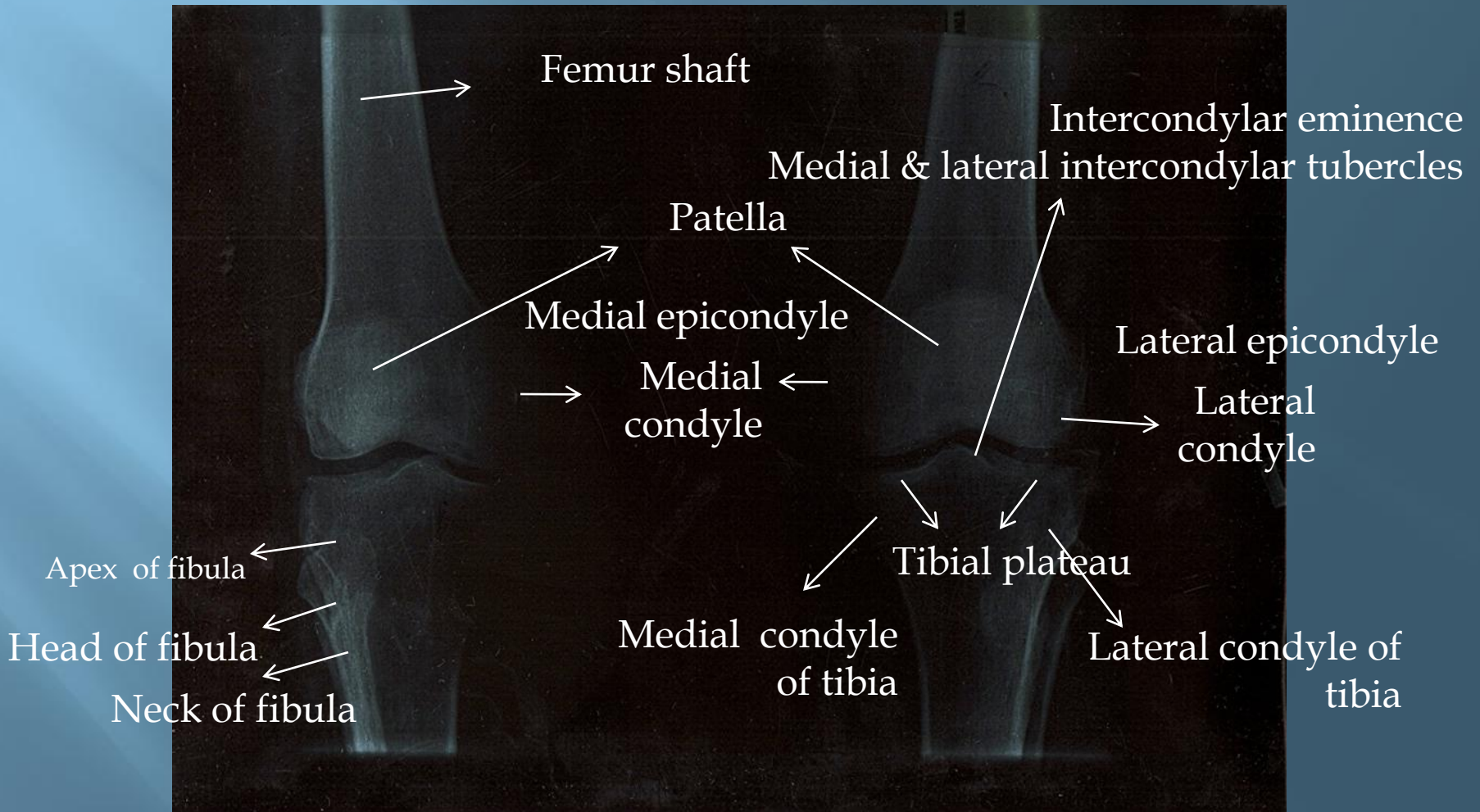
tibia



Tibial  
plateau

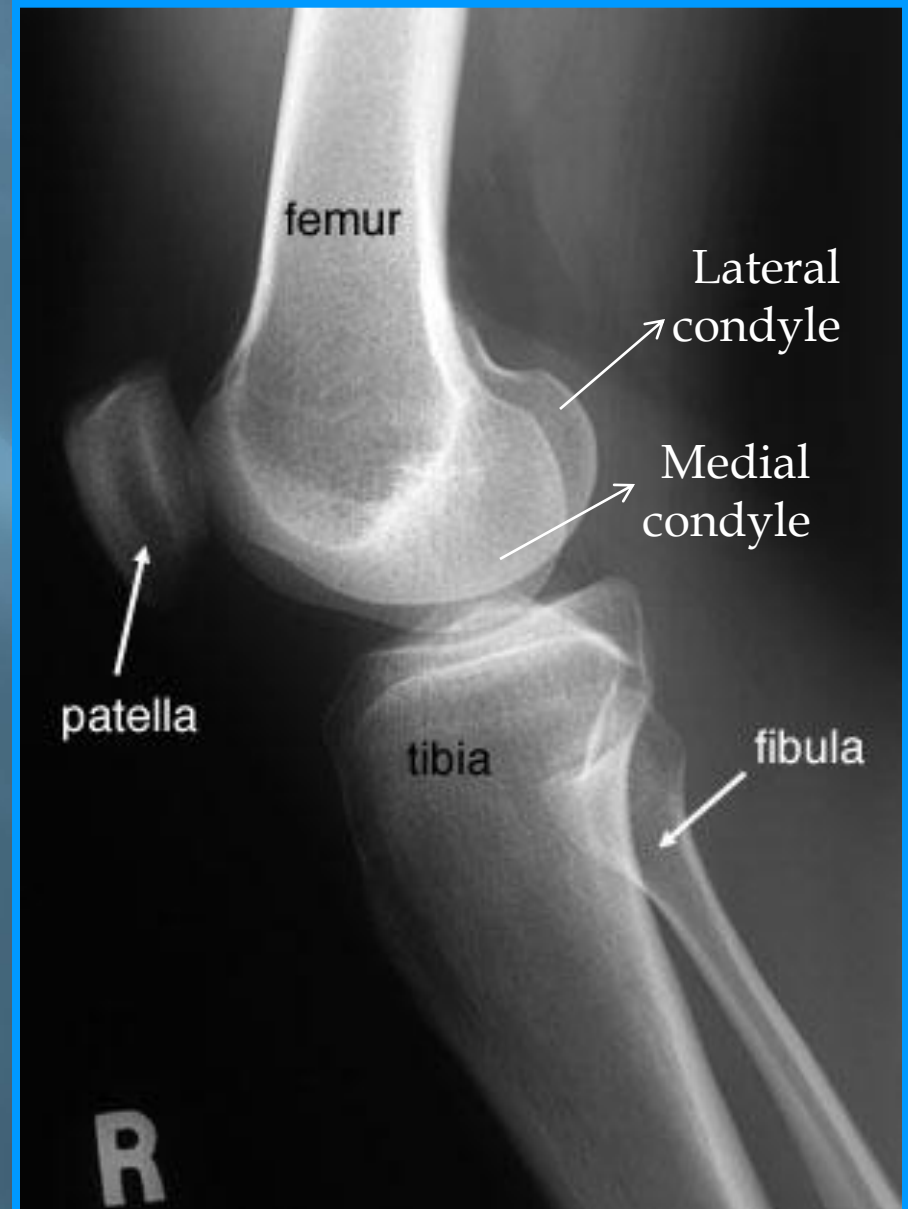
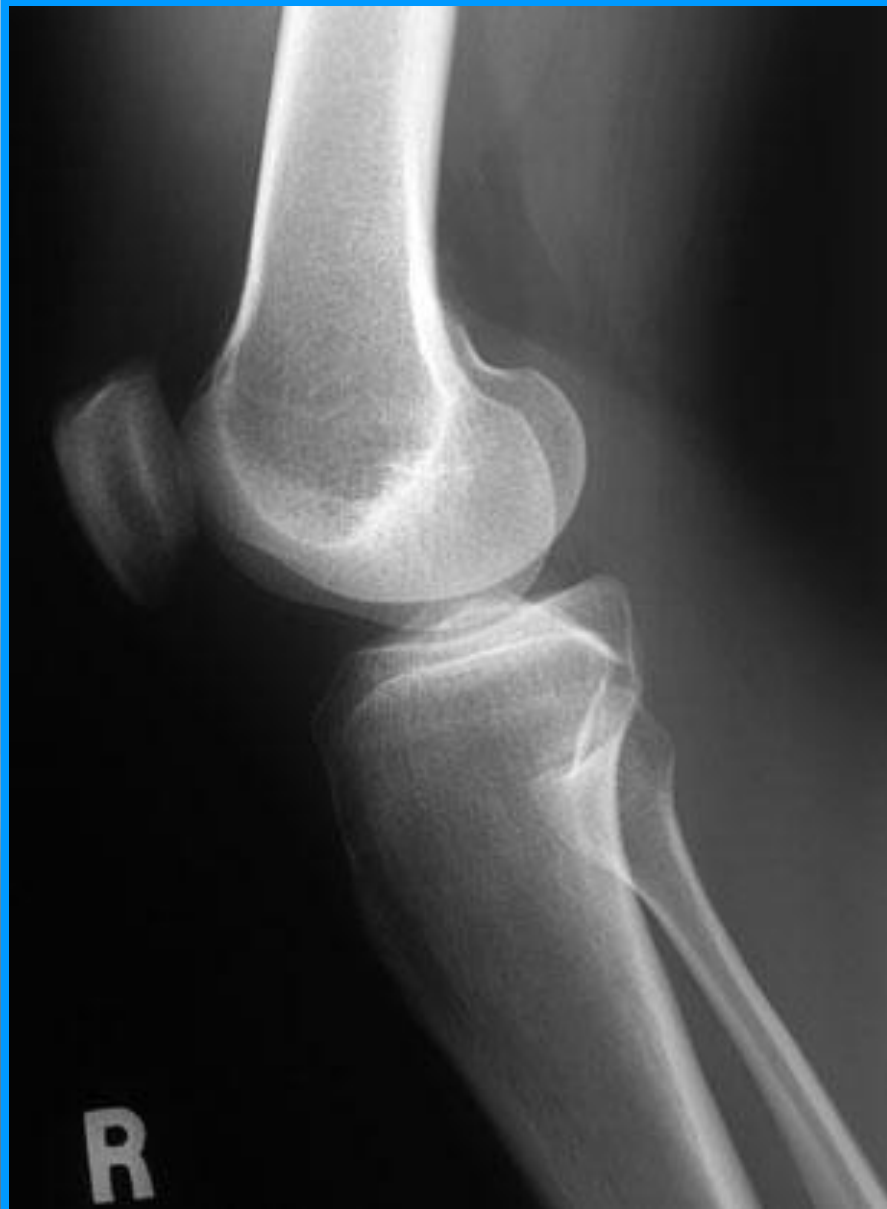# Knee AP View

F



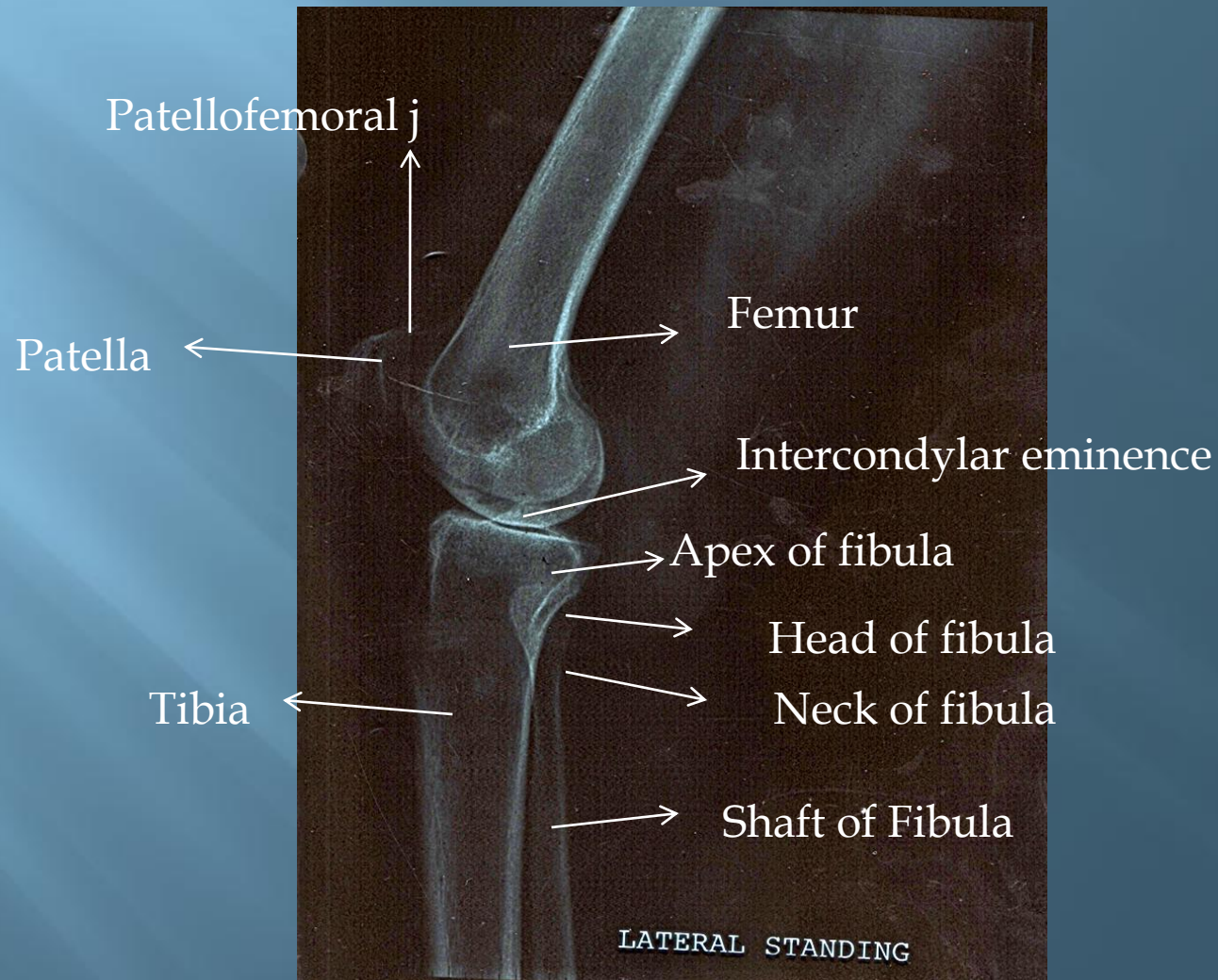
Knee,

Lateral view



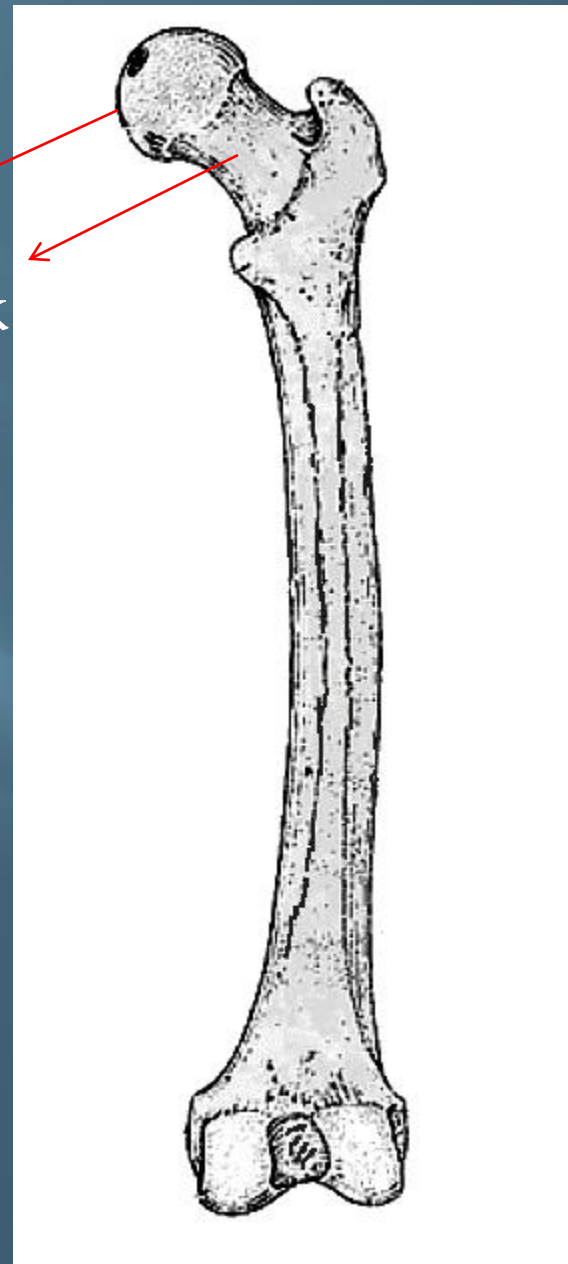
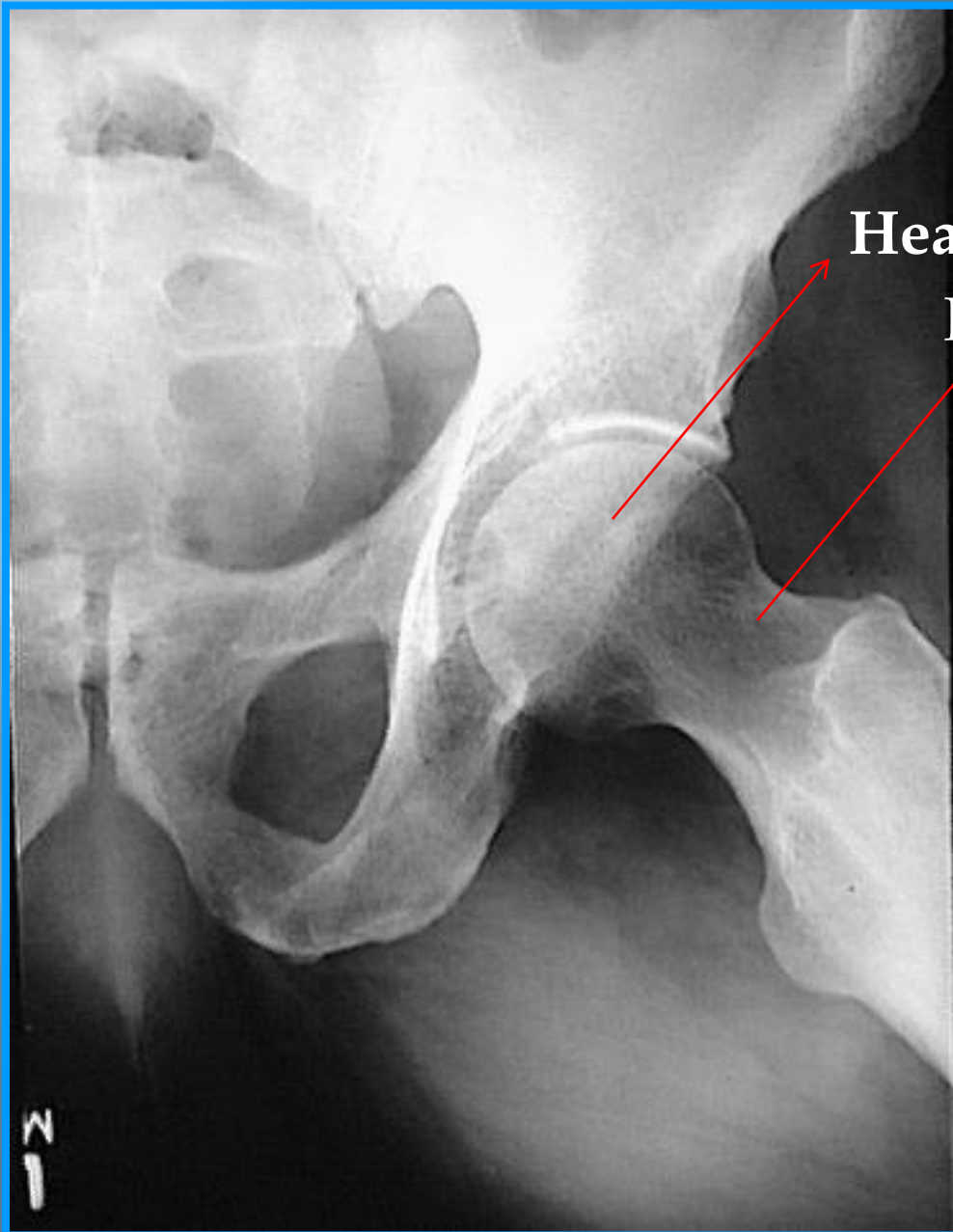
# Rt Knee Lateral

G

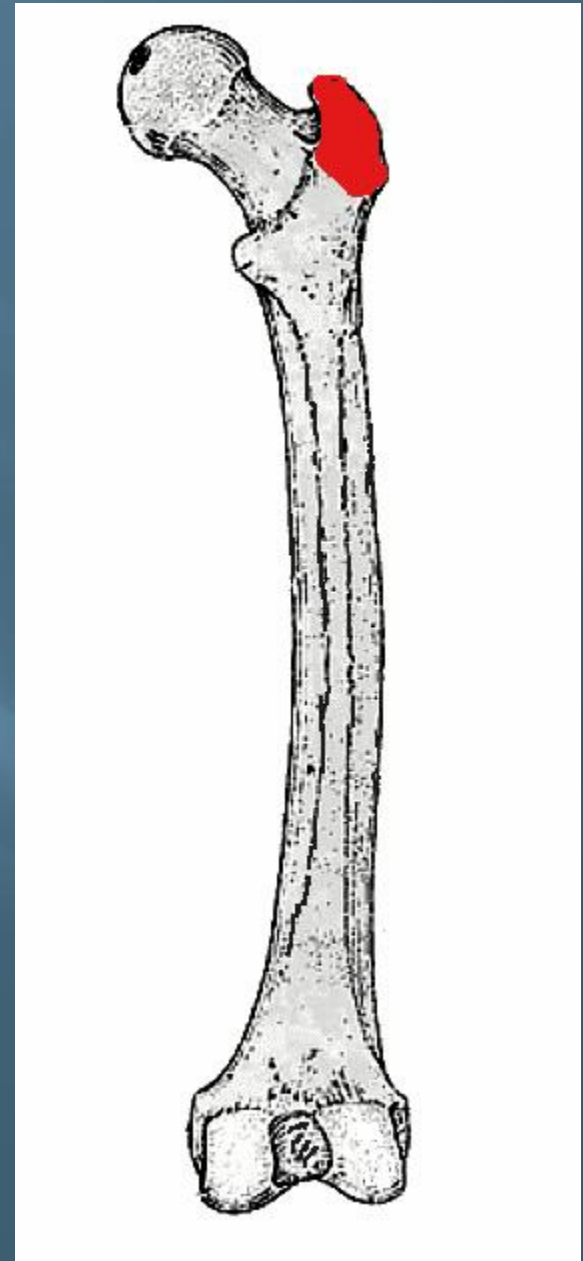
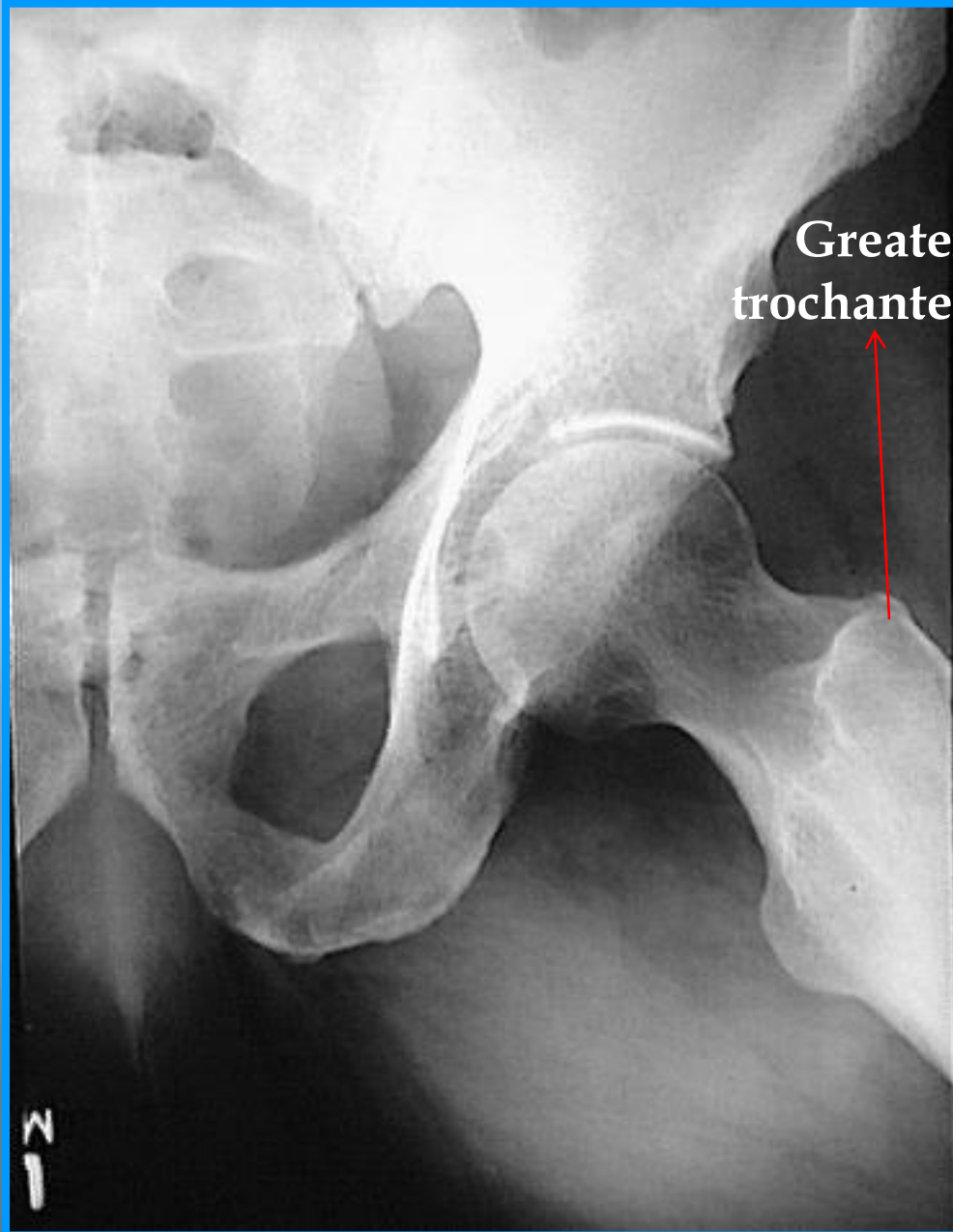

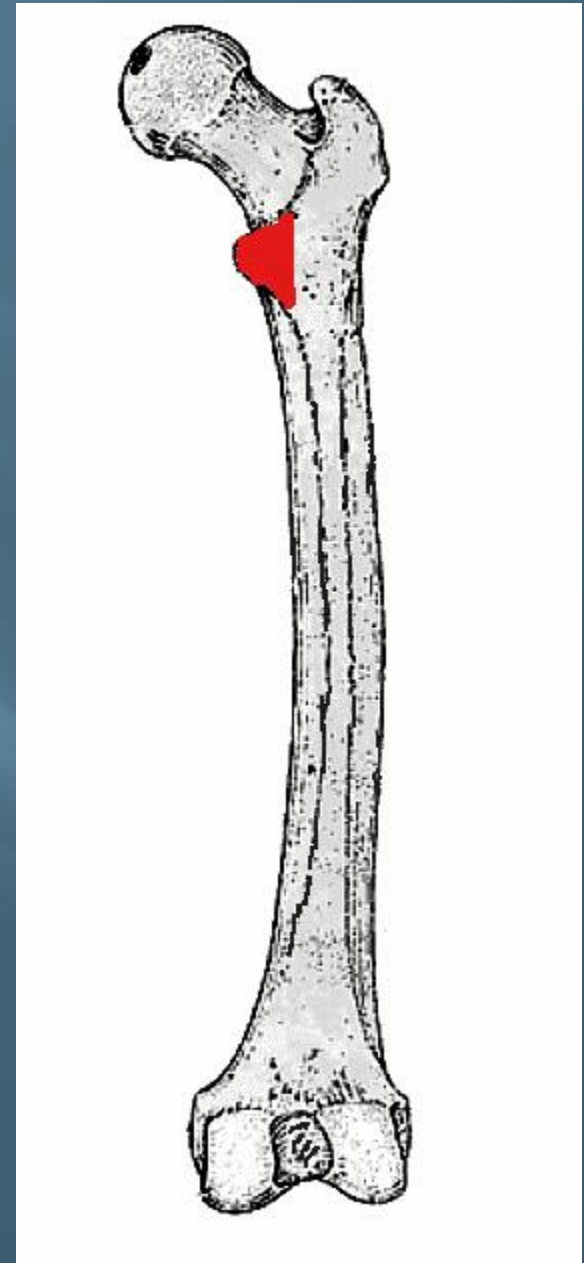
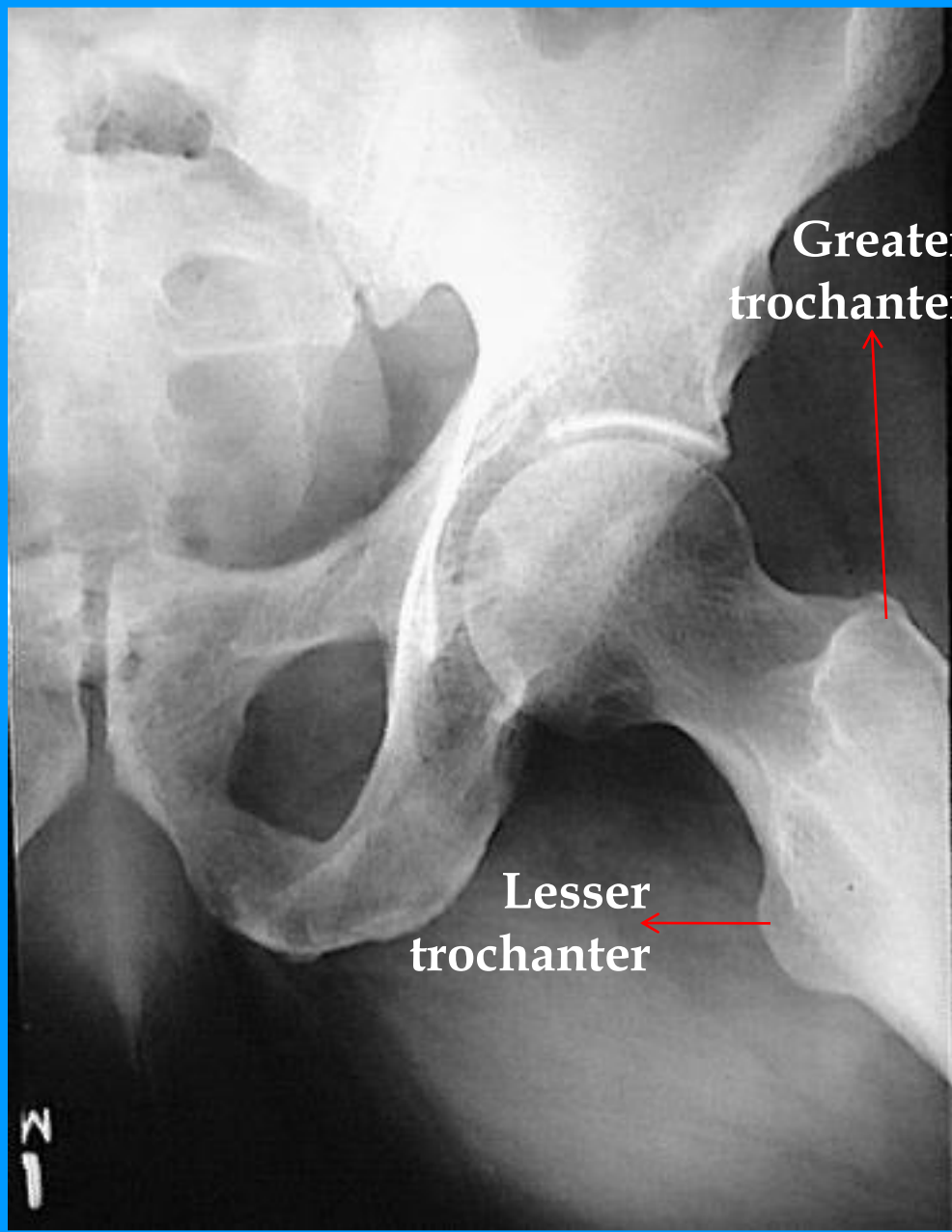


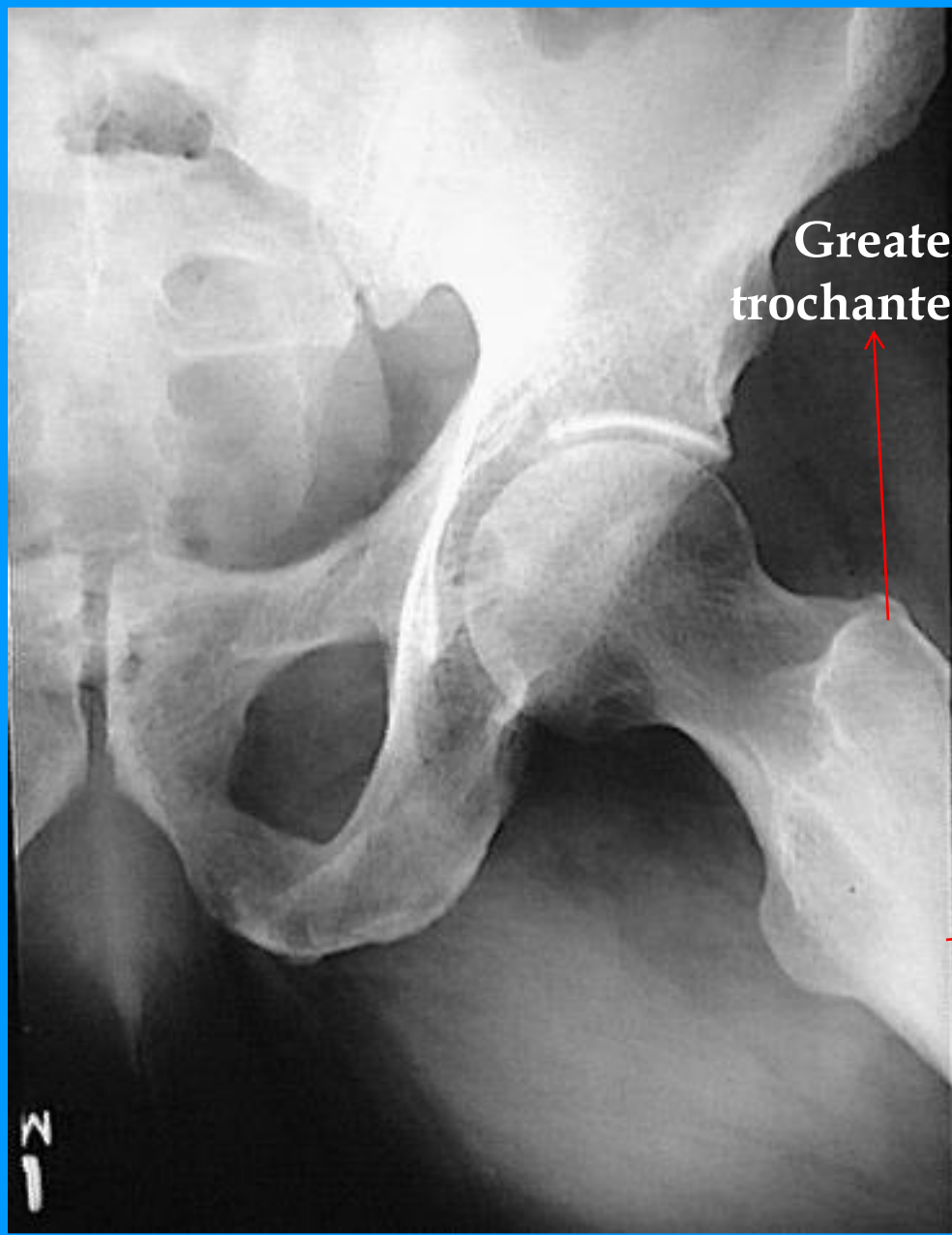# Femur



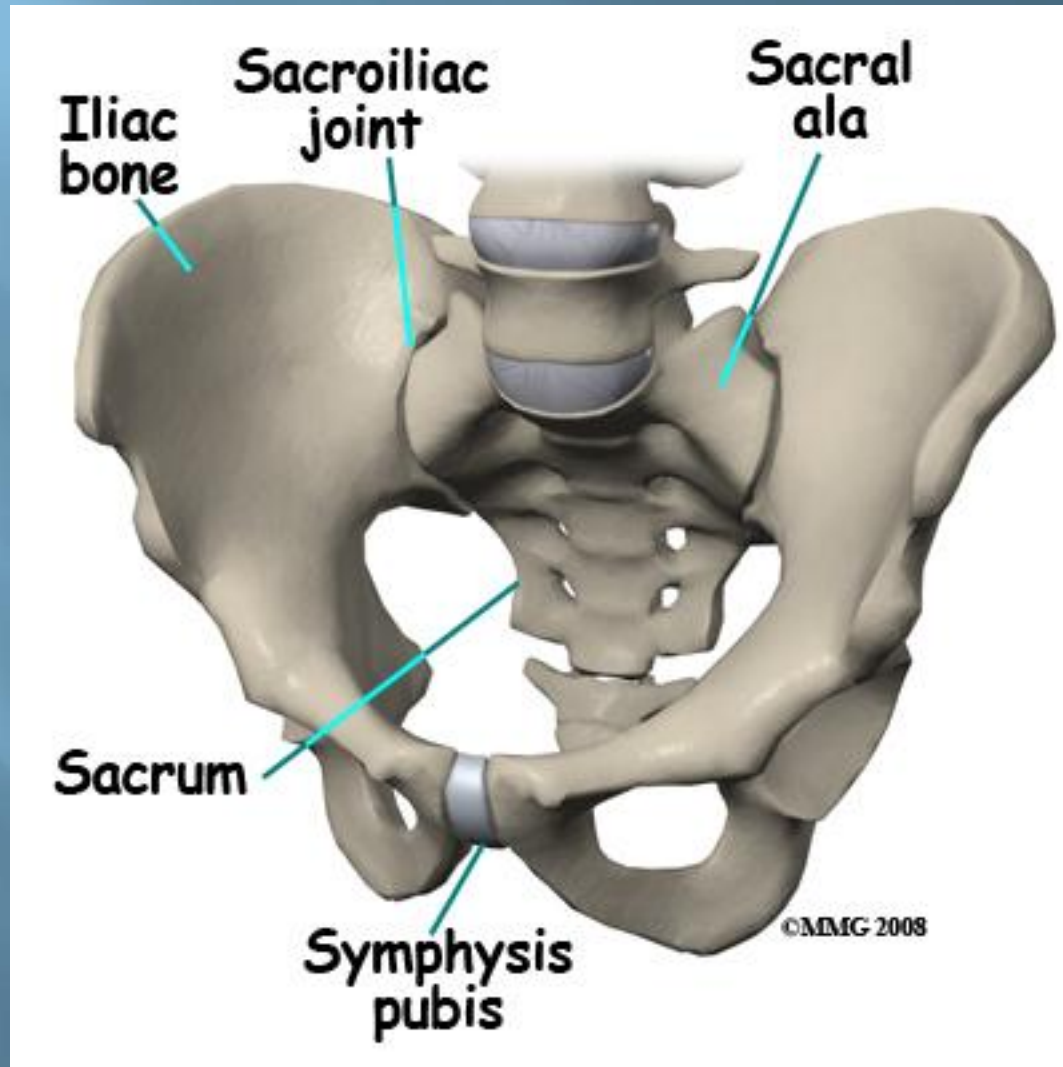
# Femur





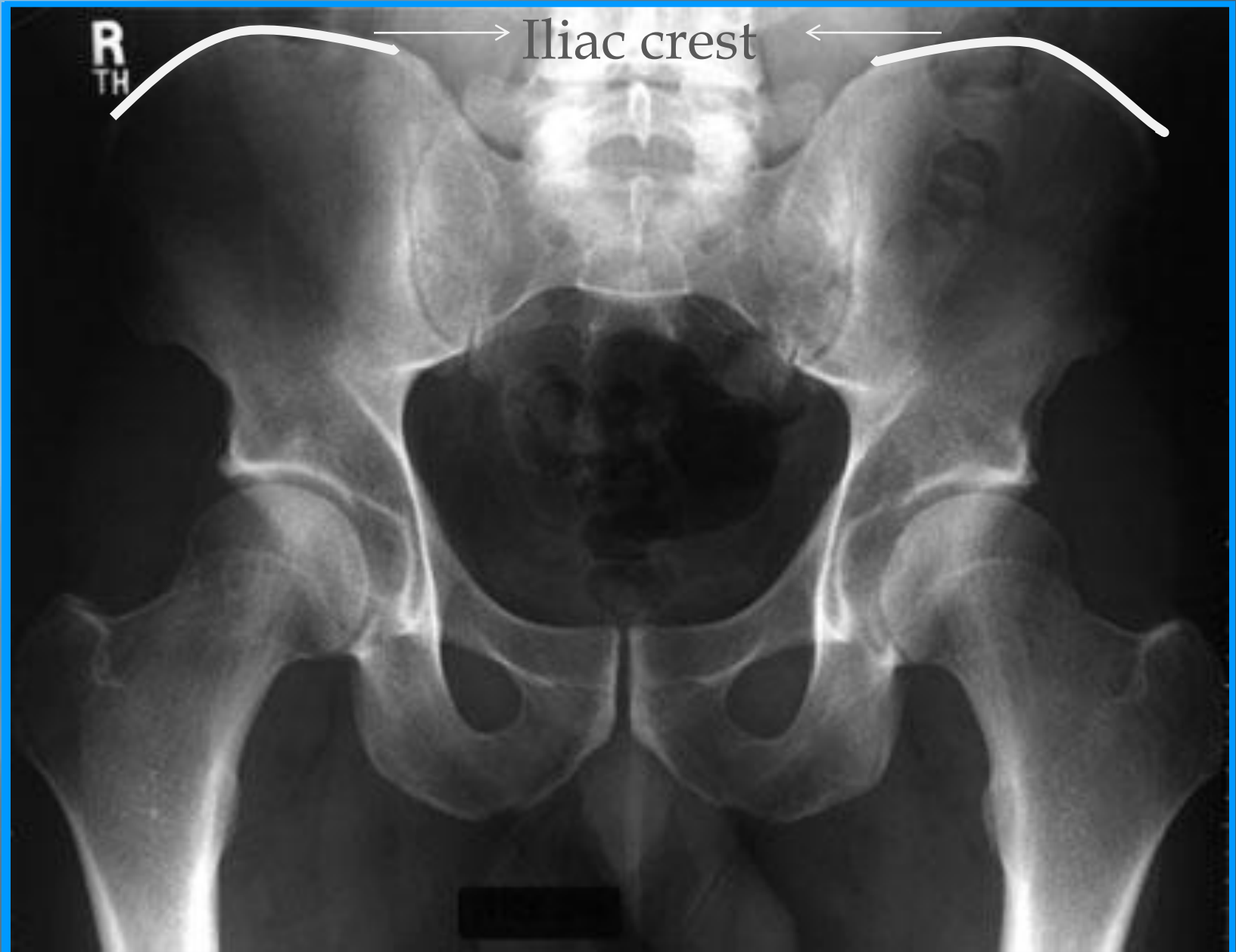

# Pelvis



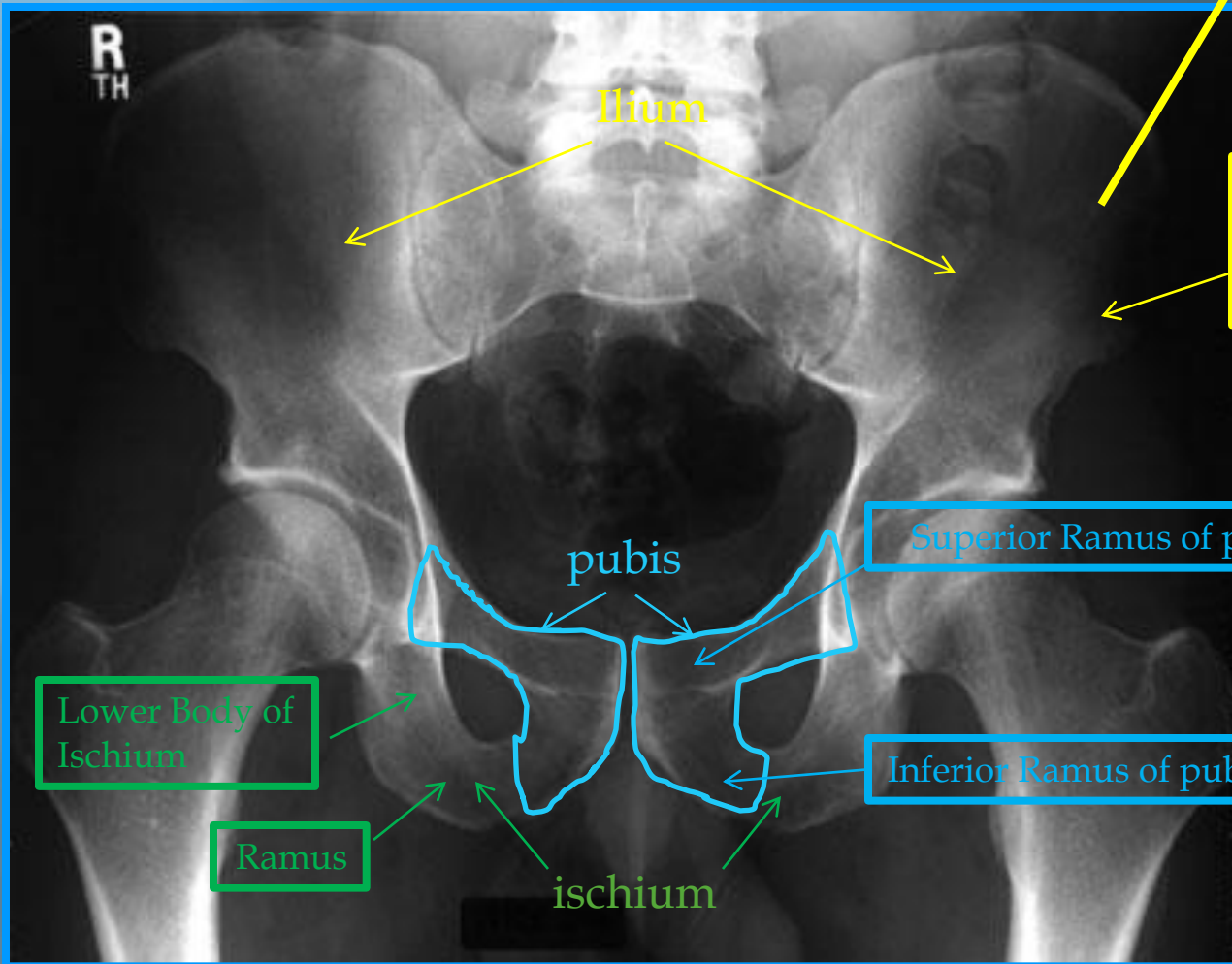
Pelvis,

AP view



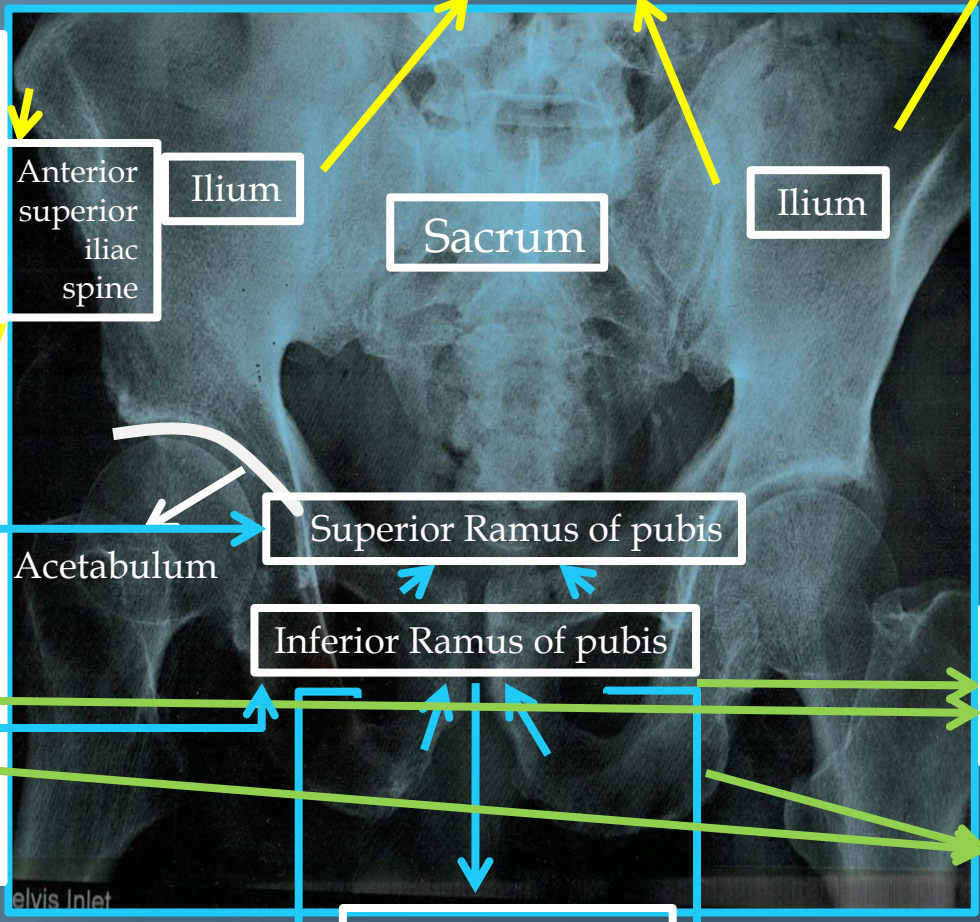
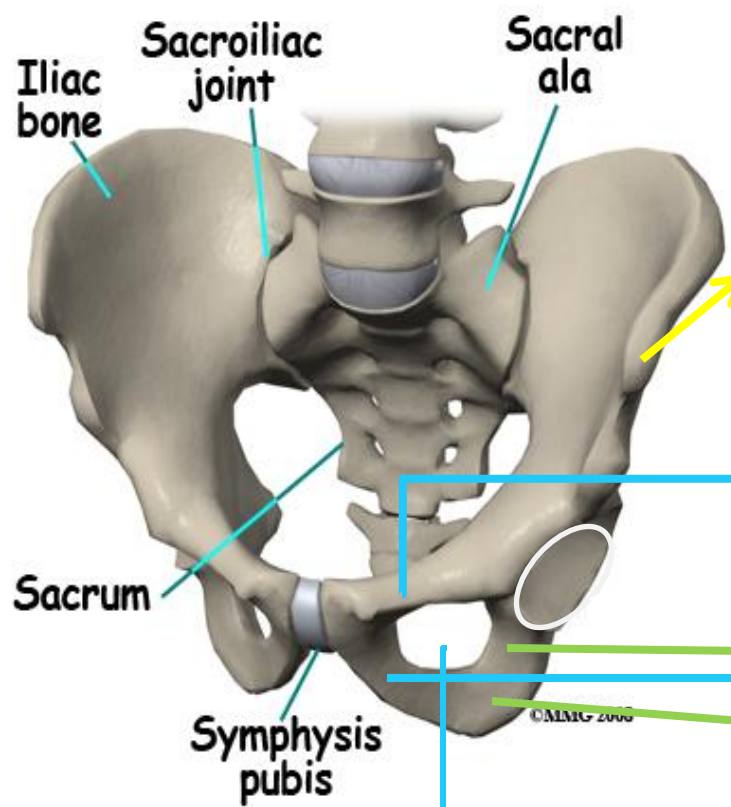
# Hip Bone

Ala, wing of ilium



# Pelvis AP male m

- pubis
- ilium
- Ischeum



Ala ,wing of ilium

Sacroiliac joints

Anterior superior iliac spine

Ilium

Sacrum

Ilium

Acetabulum

Superior Ramus of pubis

Inferior Ramus of pubis

Lower Body of Ischium

Ramus

Symphysis pubis

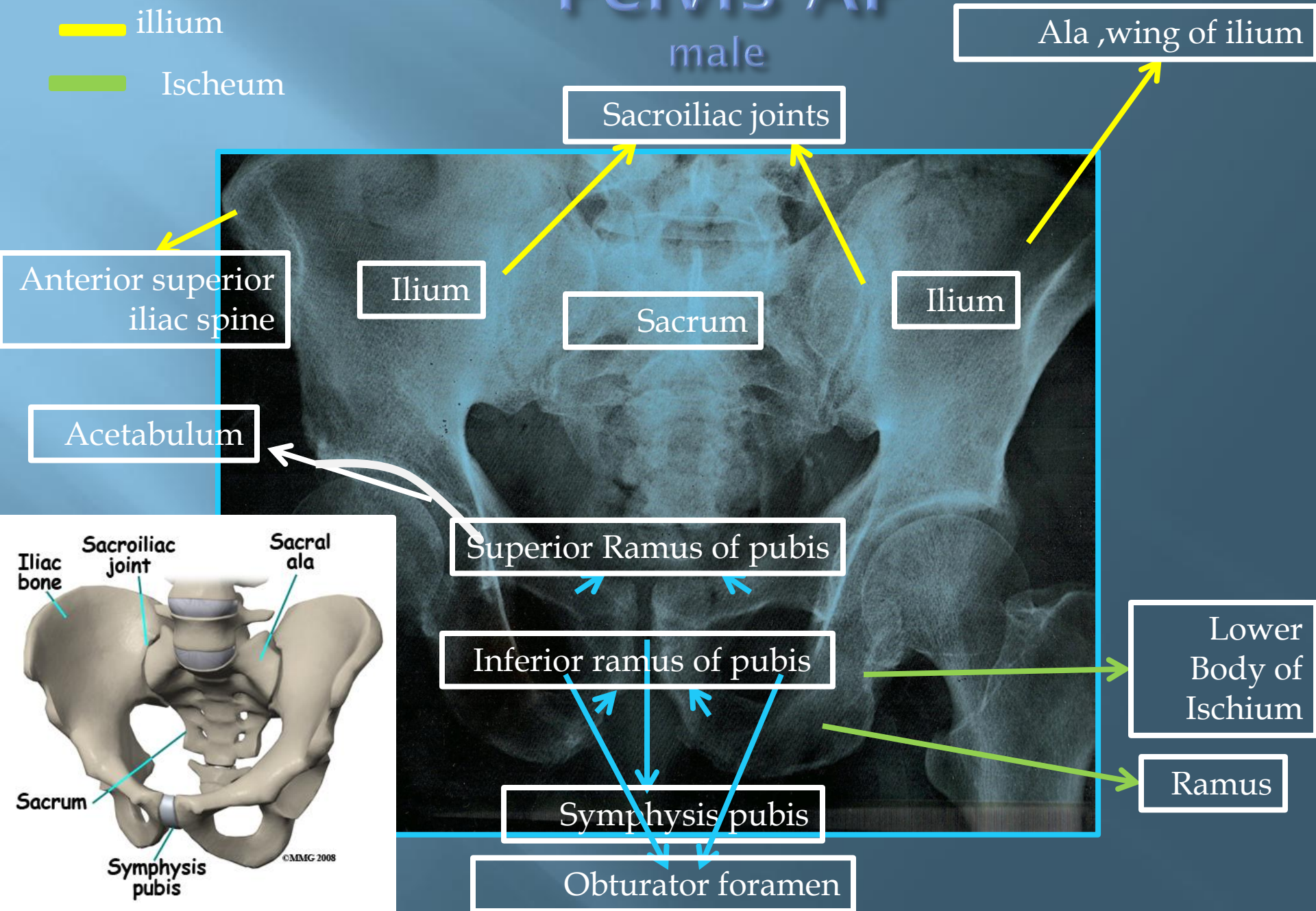
Obturator foramen



# Pelvis AP

male

- pubis
- ilium
- Ischeum



Ala ,wing of ilium

Sacroiliac joints

Anterior superior iliac spine

Ilium

Sacrum

Ilium

Acetabulum

Superior Ramus of pubis

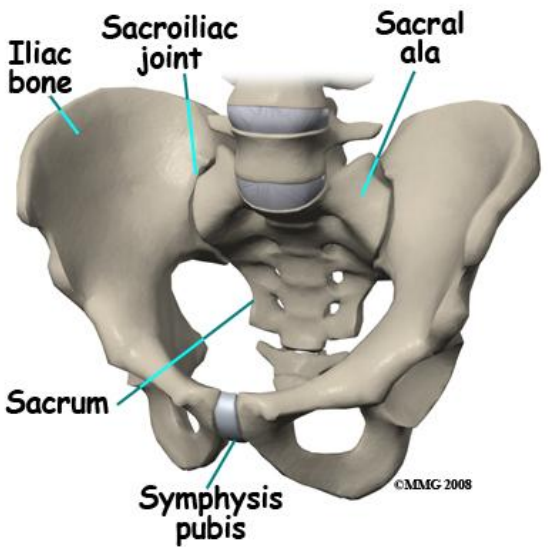
Inferior ramus of pubis

Symphysis pubis

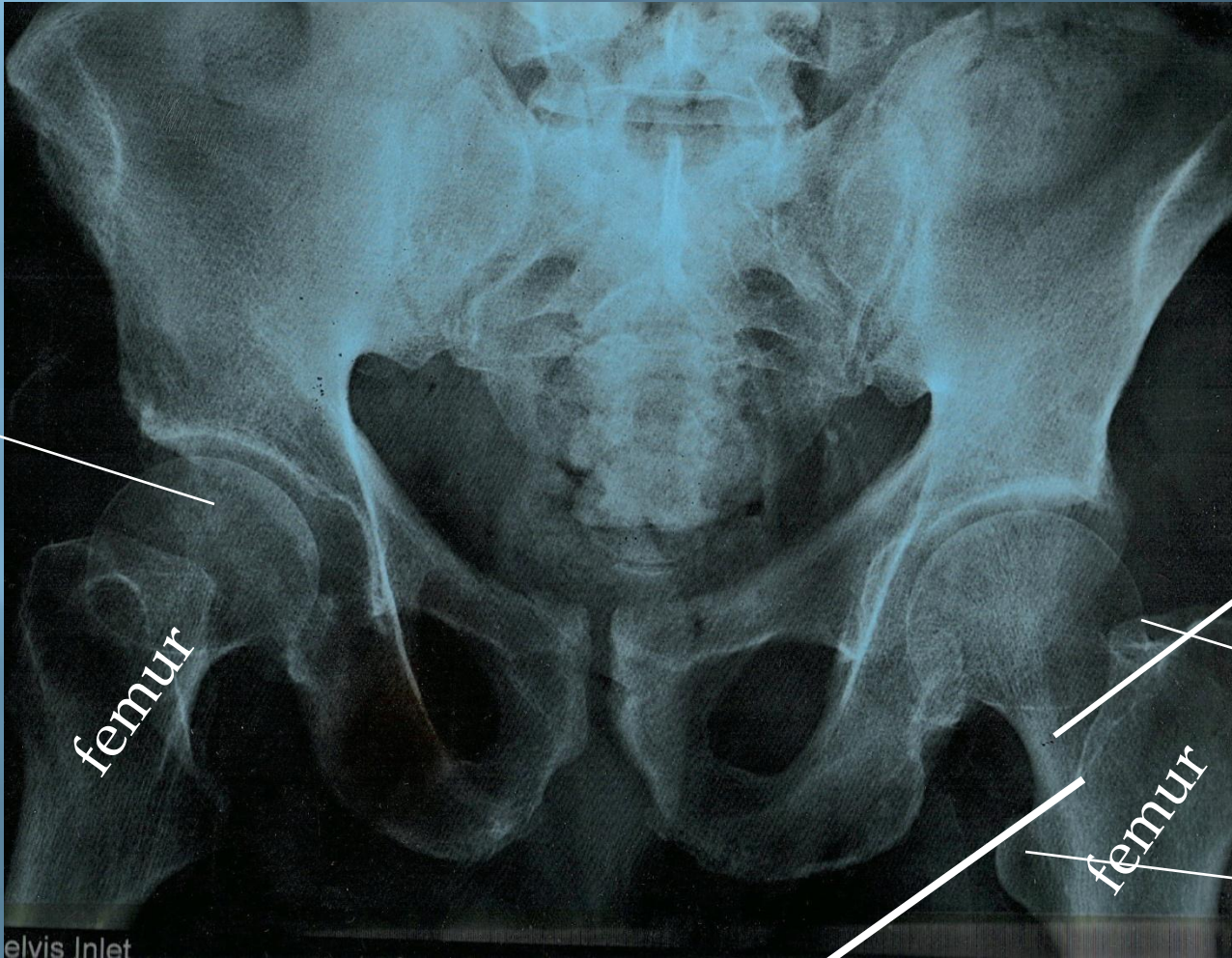
Obturator foramen

Lower Body of Ischium

Ramus



head ←



femur

femur

neck

Greater trochanter

Lesser Trochanter

Intertrochanteric crest