

Upper Limb

Upper Limb

Divided into 4 groups :

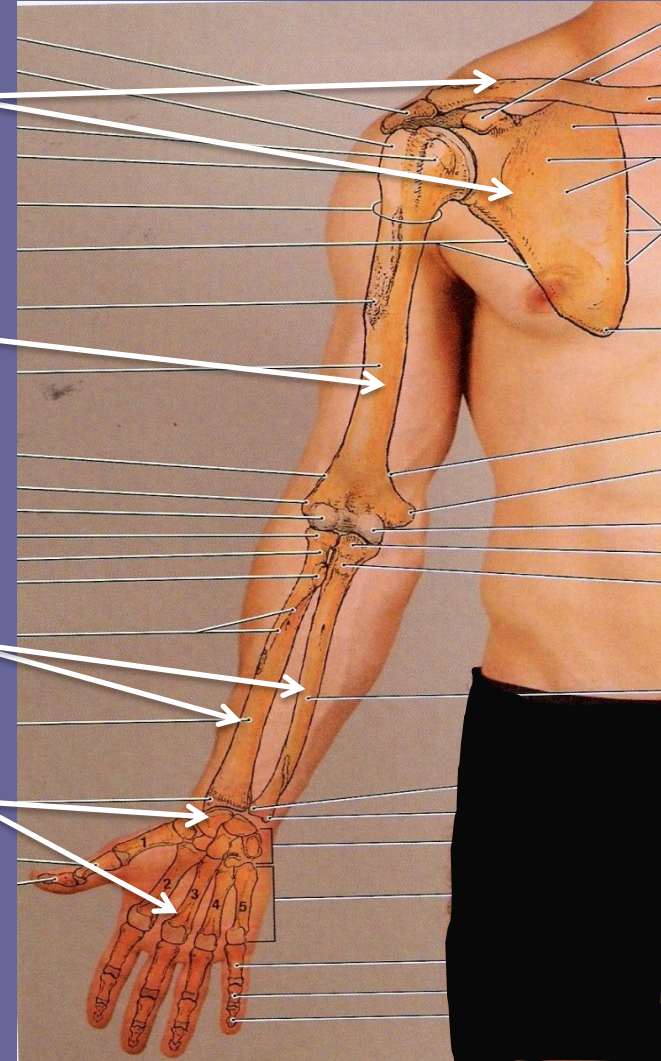
1. Hand & Wrist .
2. Forearm .
3. Humerus .
4. Shoulder .

Shoulder

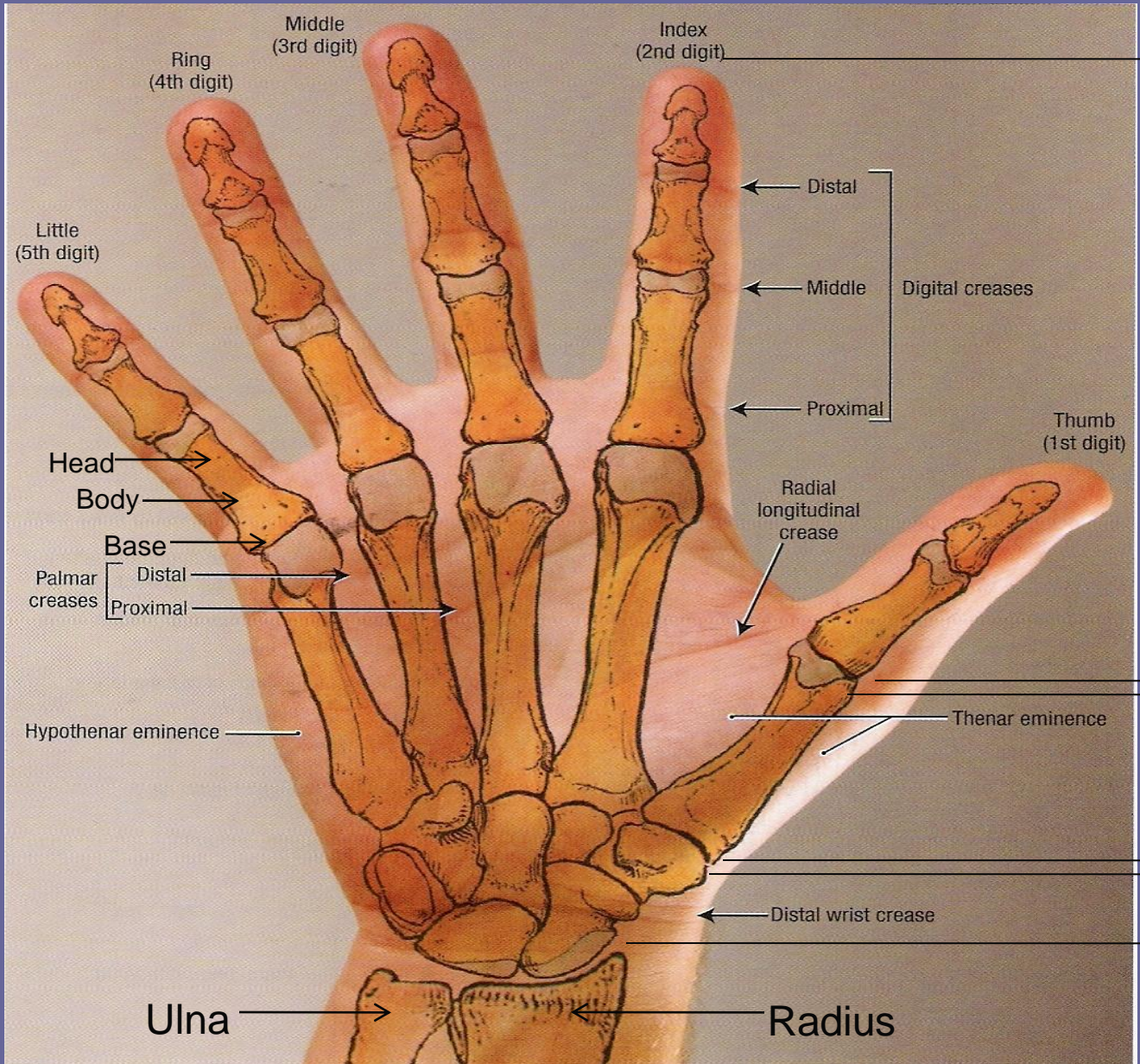
Humerus

Forearm

Hand &
Wrist

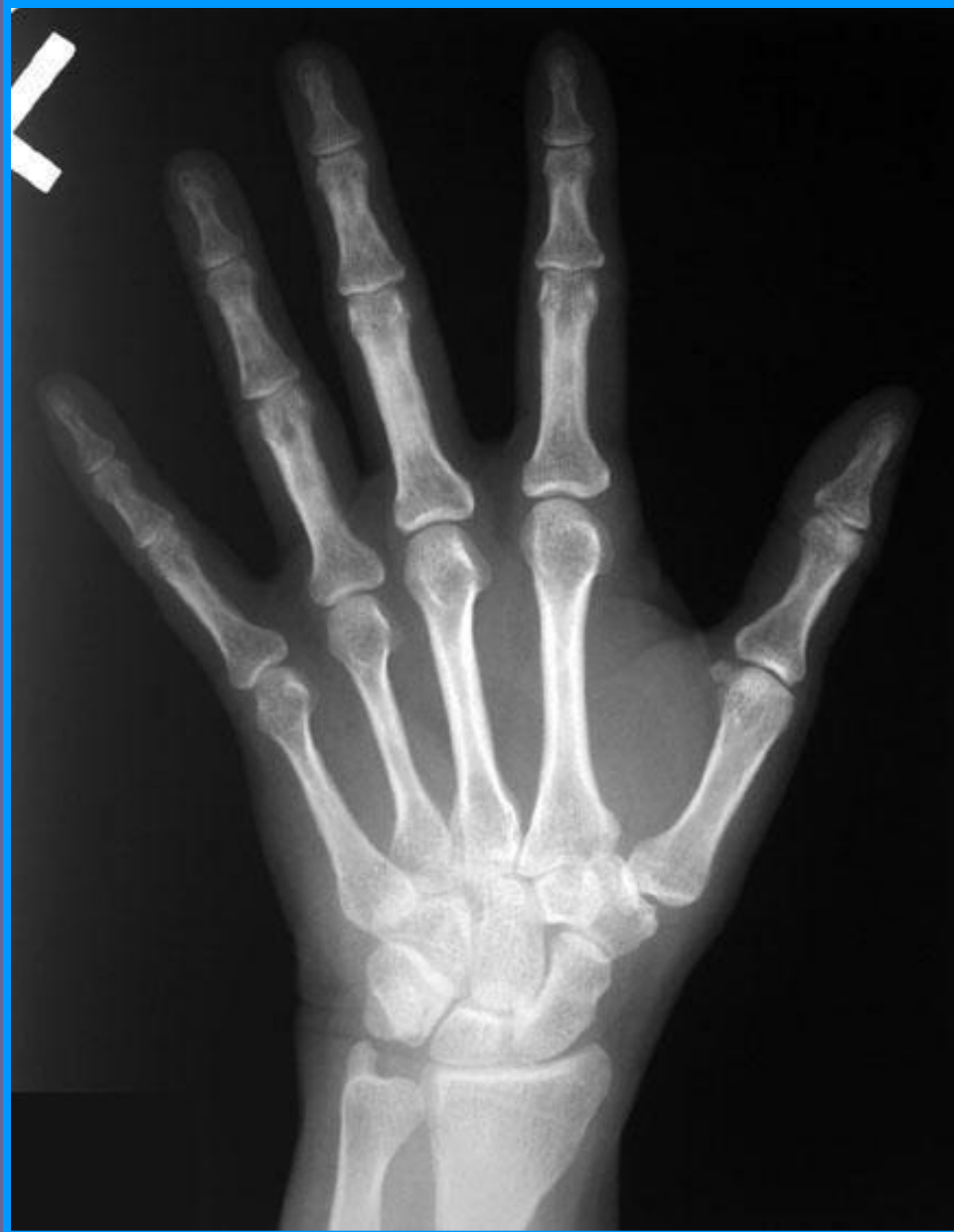
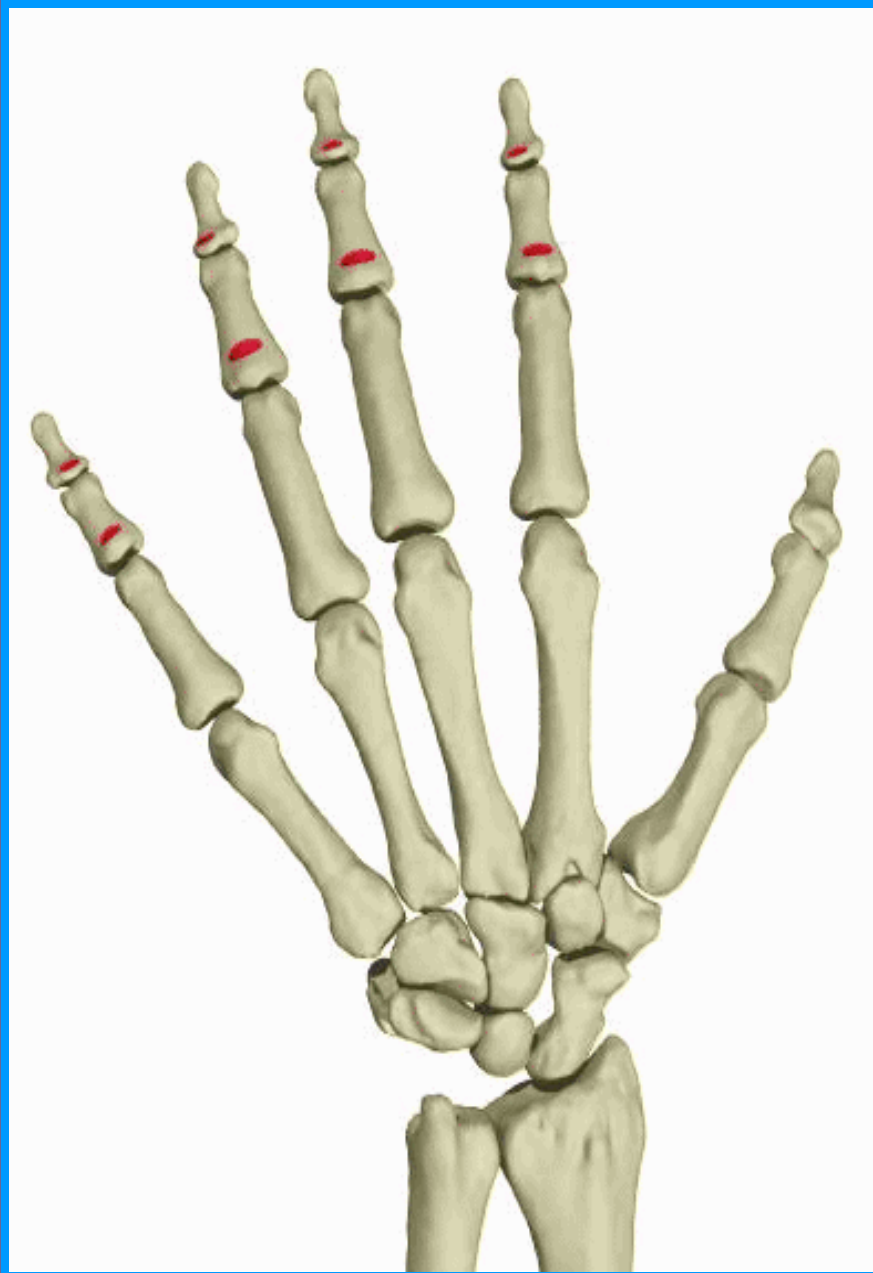
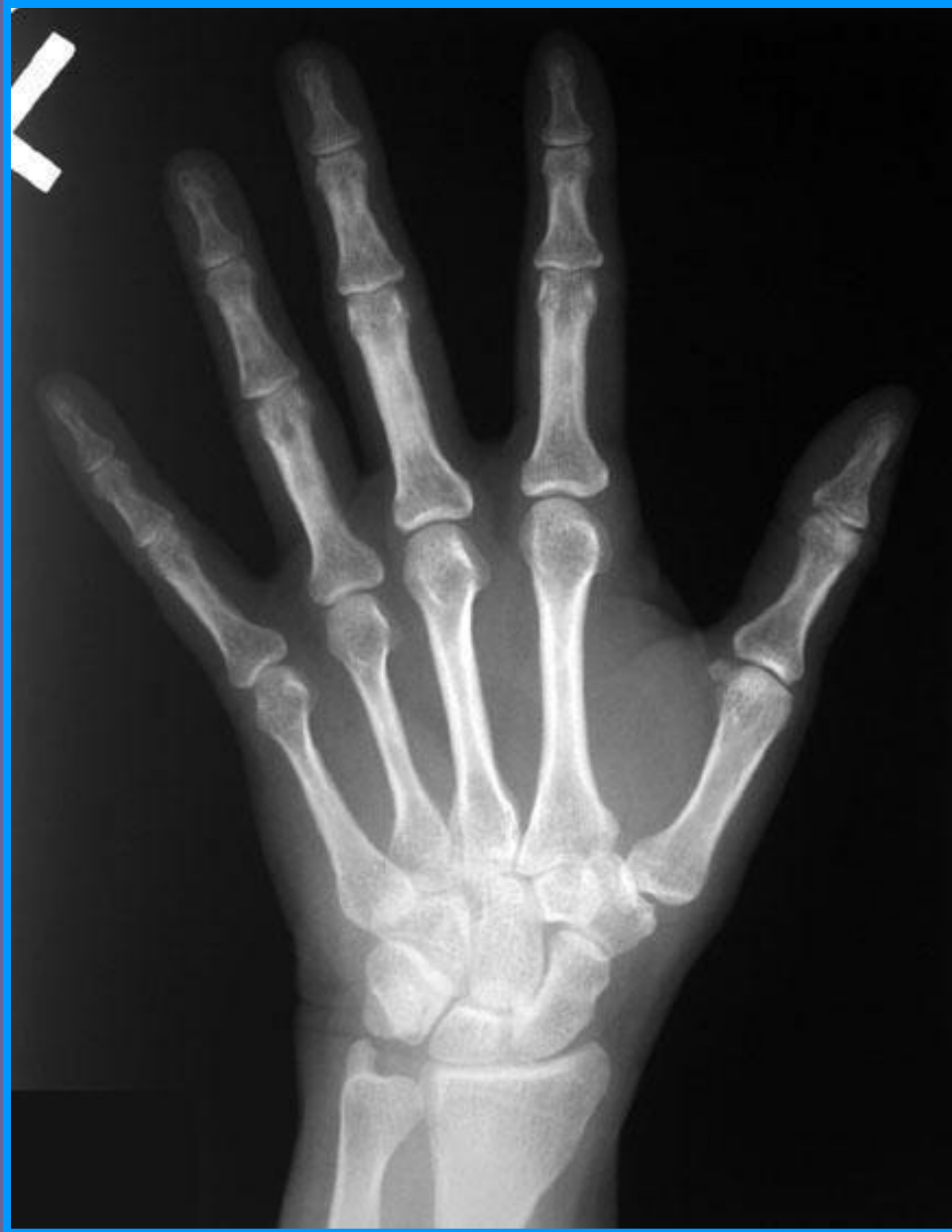1- Hand & Wrist



Phalanges	14
Metacarpals	5
Carpals	8
Total	27

Lt Hand PA





Scaphoid

Lunate

Triquetrum

Pisiform

Trapezium

Trapezoid

Capitate

Hamate

H

C

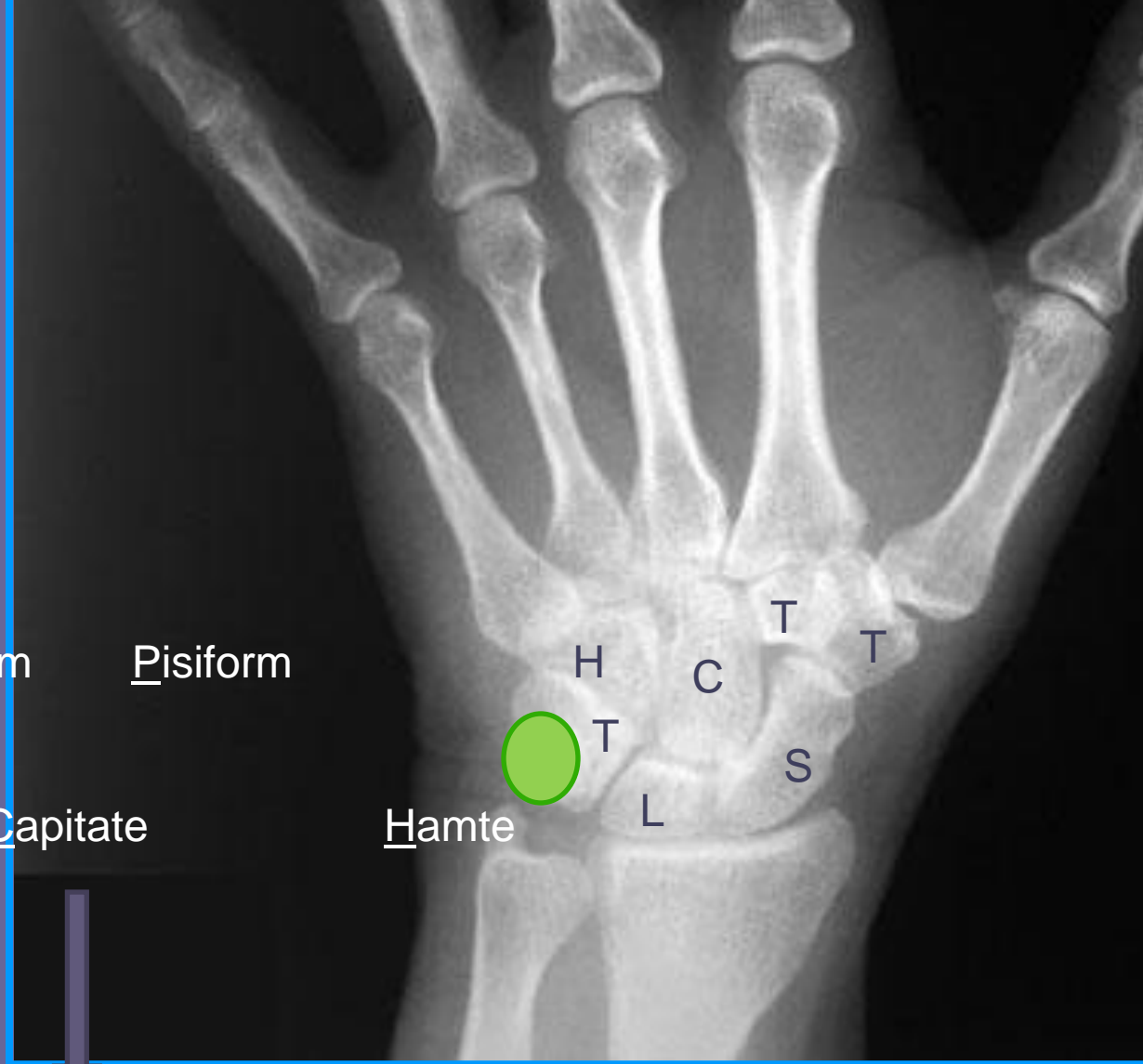
T

T

T

S

L



Articulate with 2nd MC

Articulate with thumb

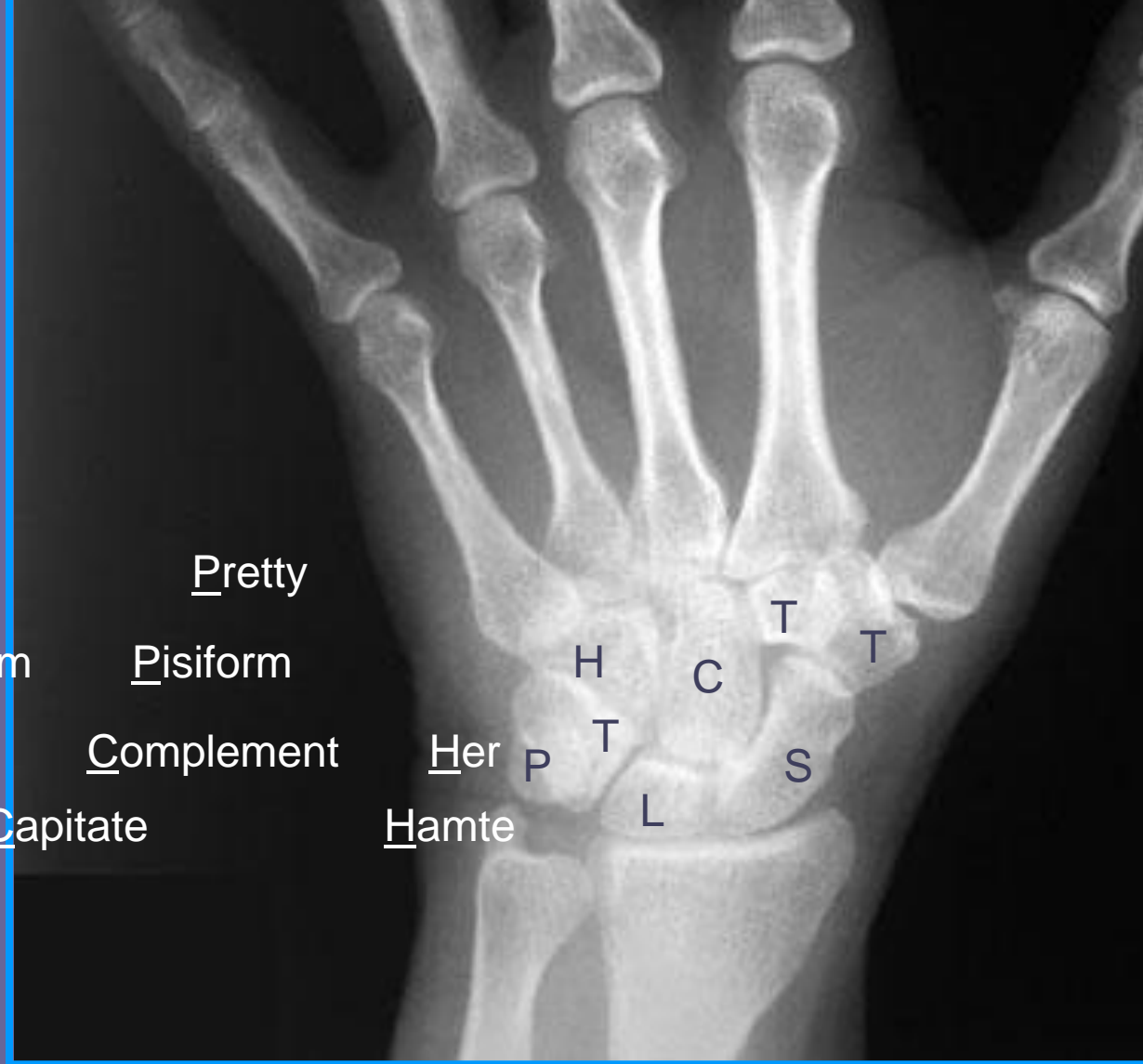
Capital letter → big

Capitate bone → biggest carpal bone

Susan Looks Too Pretty
Try To Complement Her

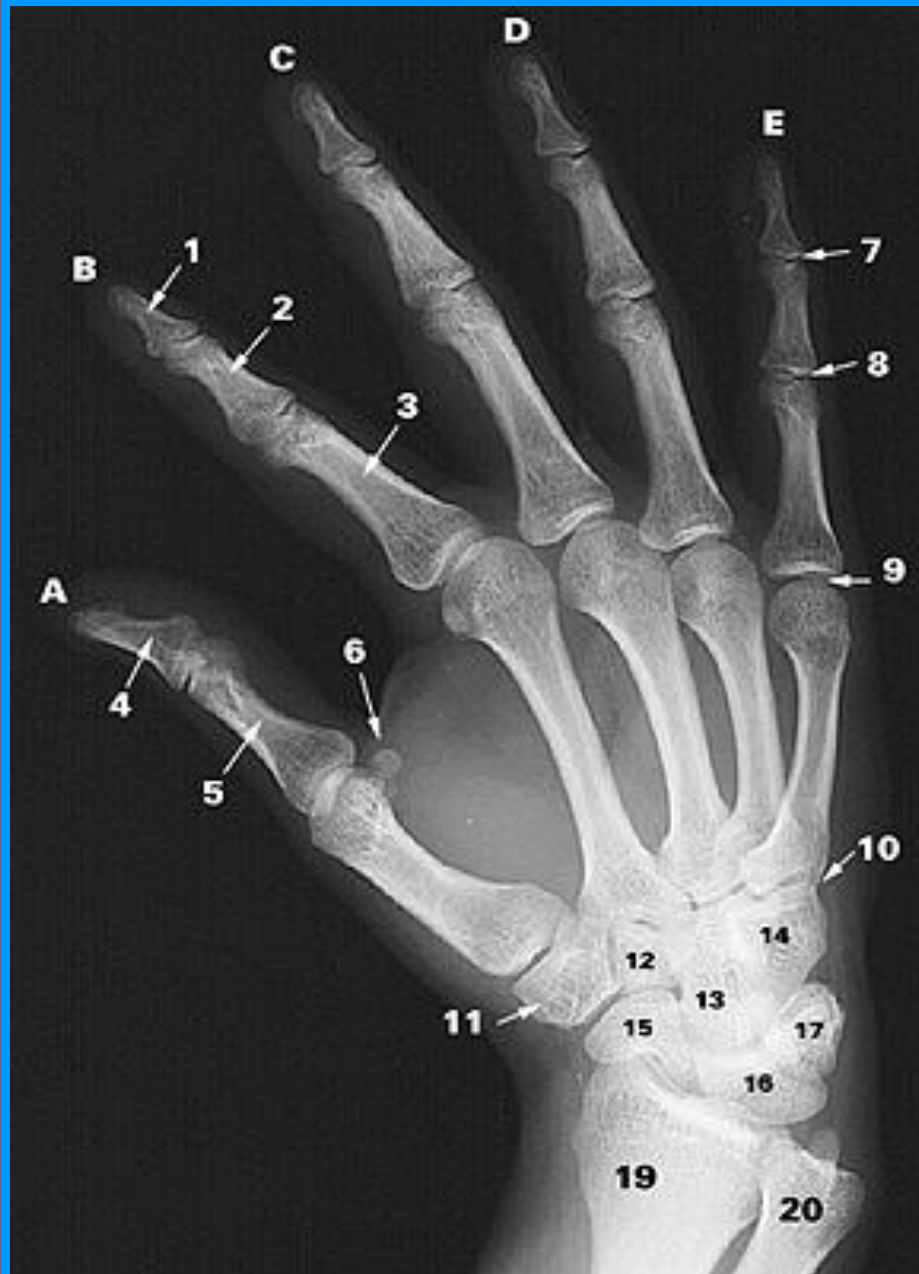Susan Looks Too
Scaphoid Lunate Triquetrum
Try To
Trapezium Trapezoid Capitate

Pretty
Pisiform
Complement Her
Hamte



When identifying •
joints & phalanges
,remember to mansion
(prox or mid or
destal),the specific_
hand & digit

Hand, Oblique view



- A. Thumb 1ST Finger(digit)
- B. Index 2nd Finger(digit)
- C. Middle 3rd finger(digit)
- D. Ring 4th finger (digit)
- E. Little 5th finger(digit)

- ∪ Distal phalanx of 2nd digit of Rt hand
- ∩ Middle phalanx of 2nd digit of Rt hand
- ∪ Proximal phalanx of 2nd digit of Rt hand
- ε distal phalanx of 1st digit of Rt hand
- ◊ proximal phalanx of 1st digit of Rt hand
- ∩ Sesamoid bones

∪ Distal interphalangeal joint of 5th digit of Rt hand

∧ Proximal interphalangeal joint of 5th digit of Rt hand

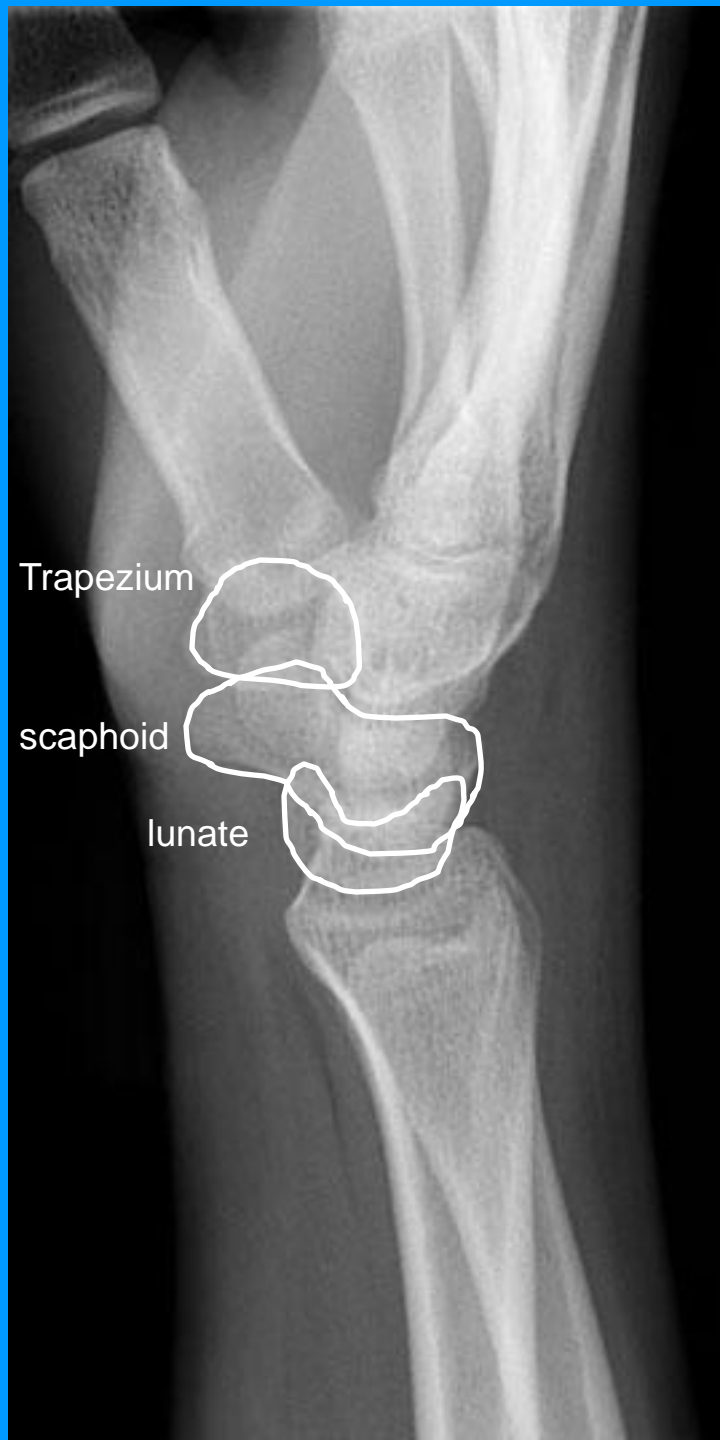∩ 5th Metacarpophalangeal joint of Rt hand

∪ 5th Carpometacarpal joint of Rt hand

∪ ∪ Triquetrum

∪ ∩ Radius

∪ ∩ Ulna



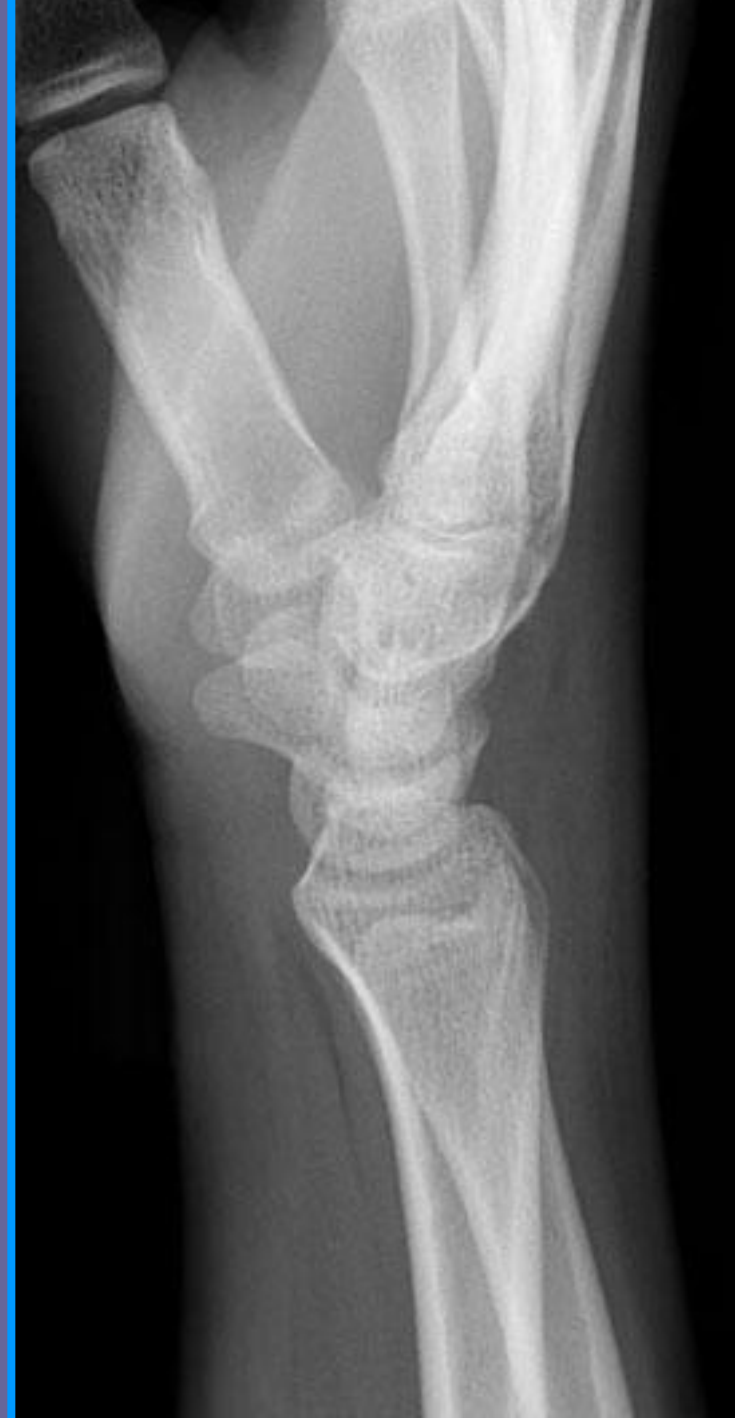Trapezium

scaphoid

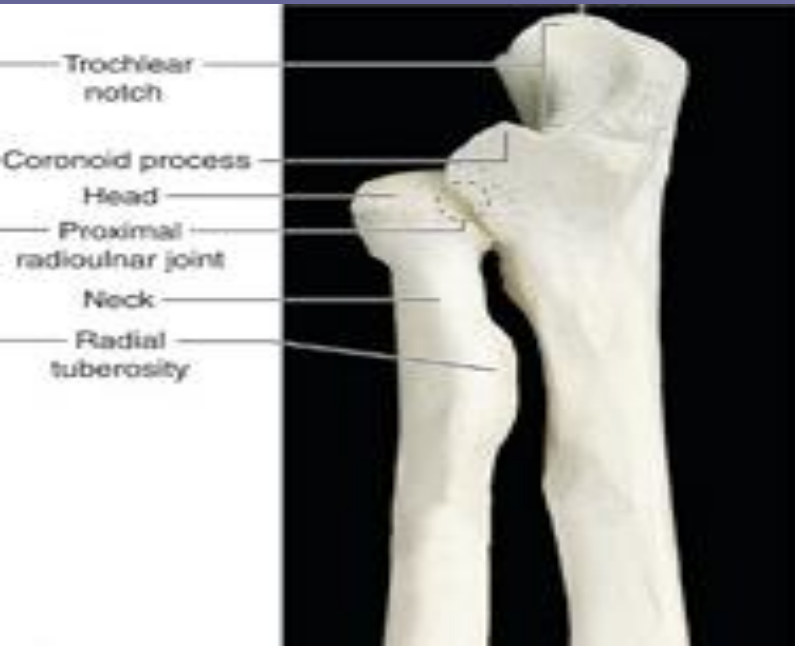
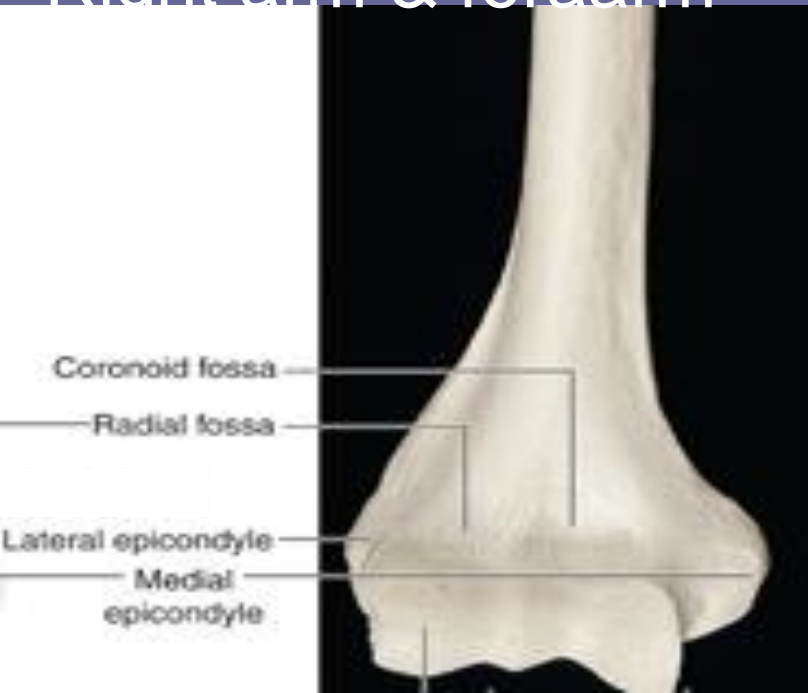
lunate

Wrist

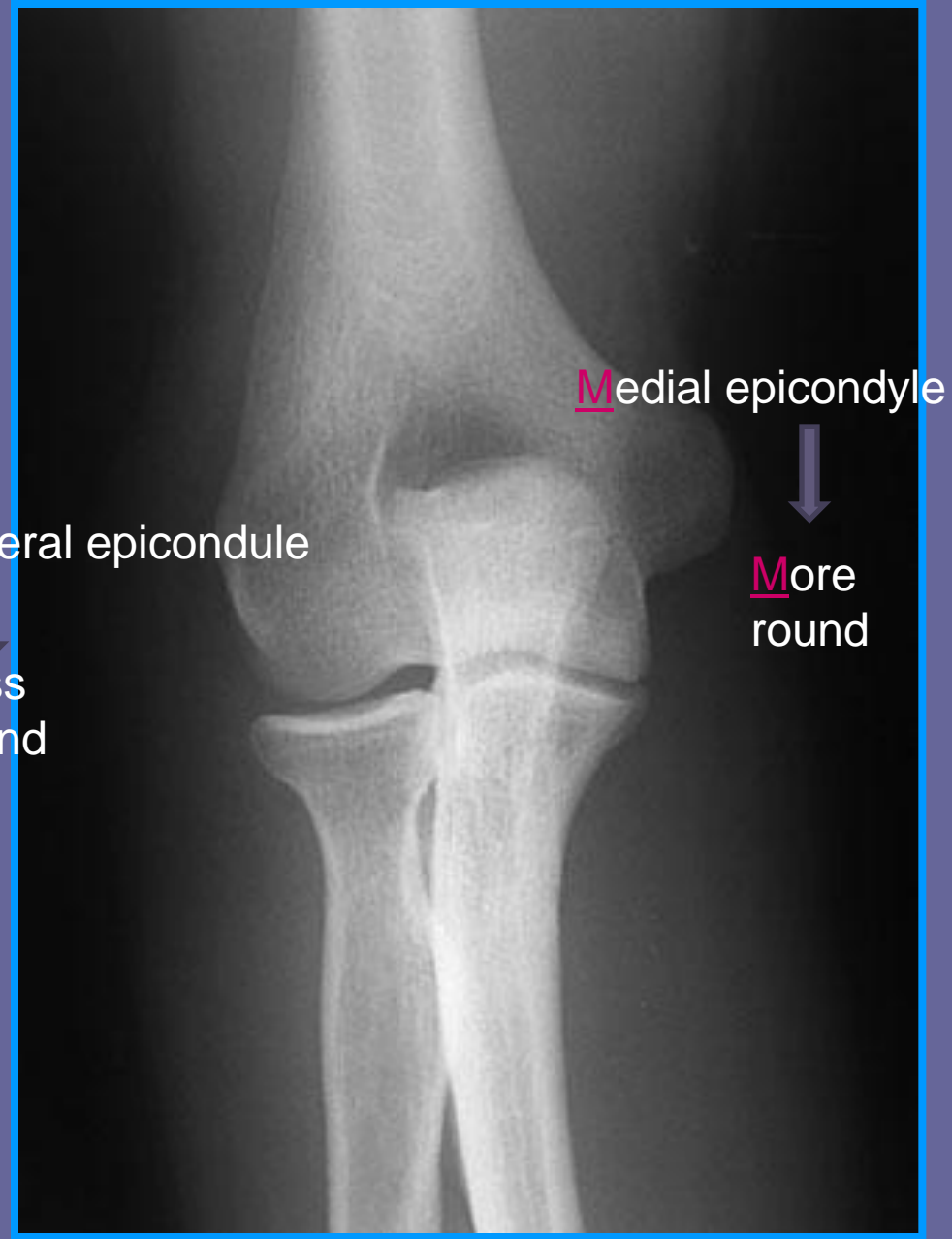Lateral view

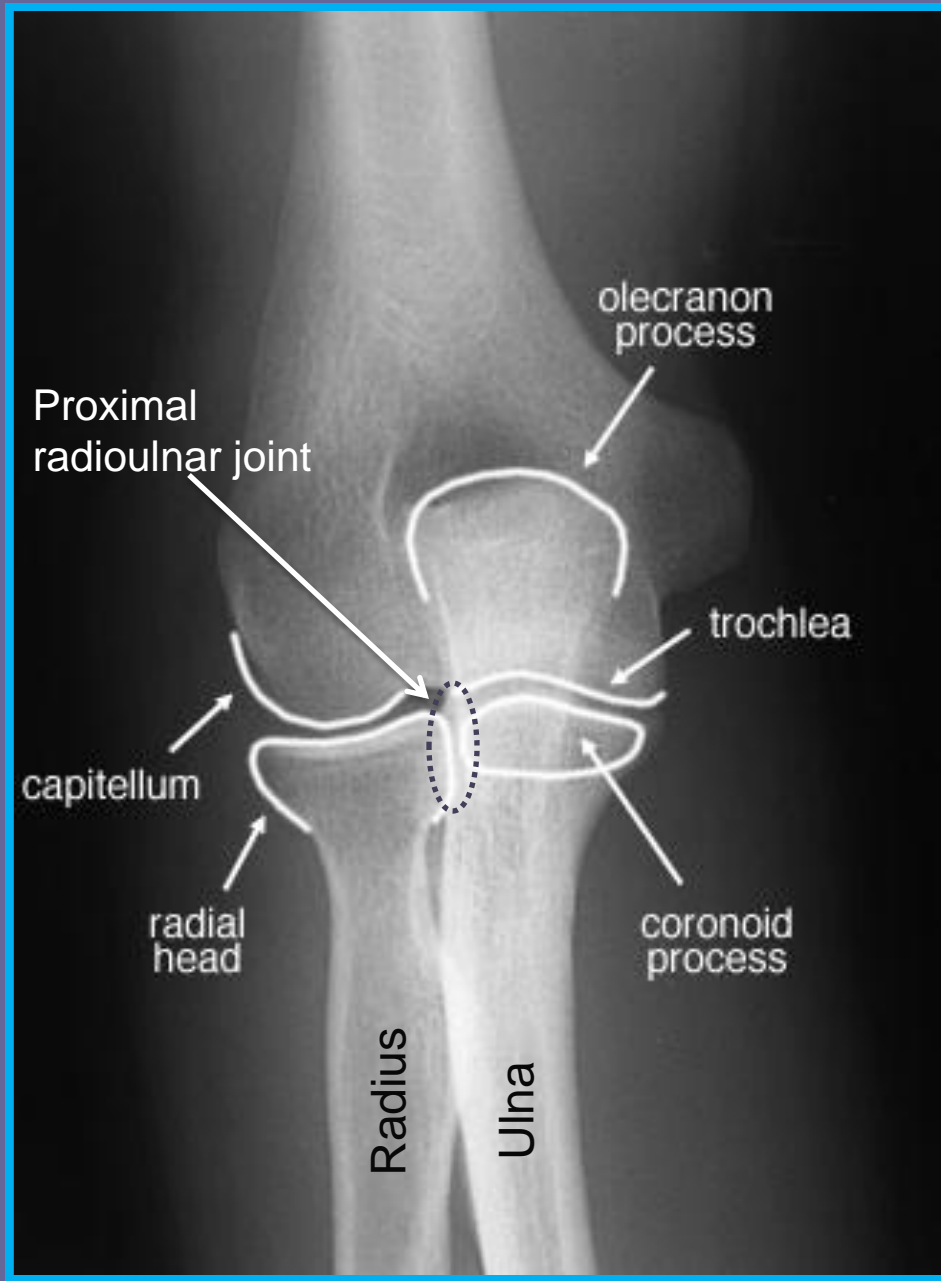
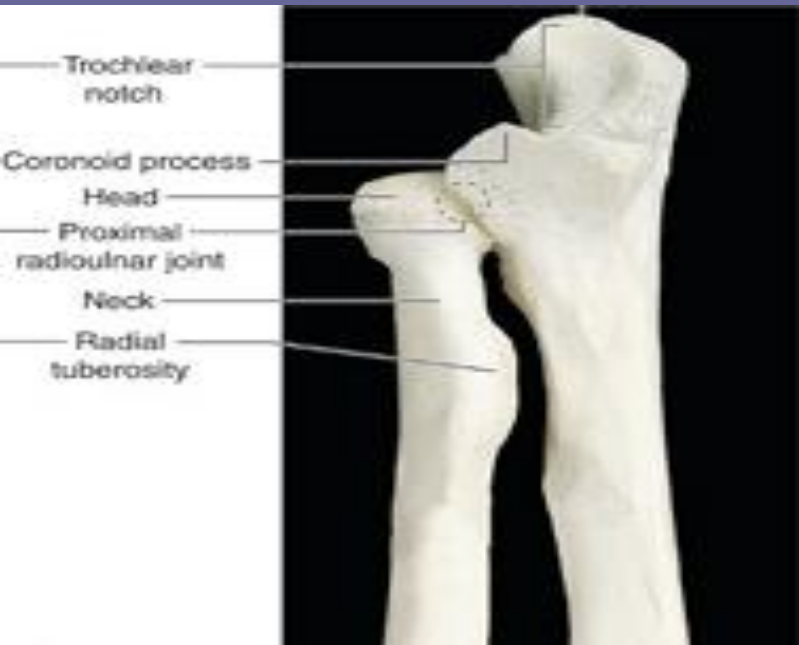
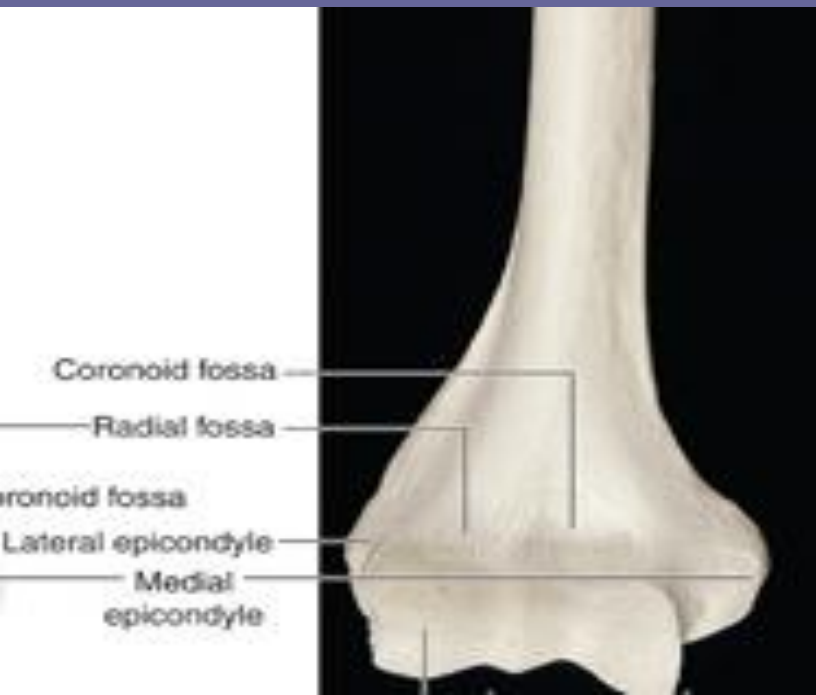


Right arm & forearm

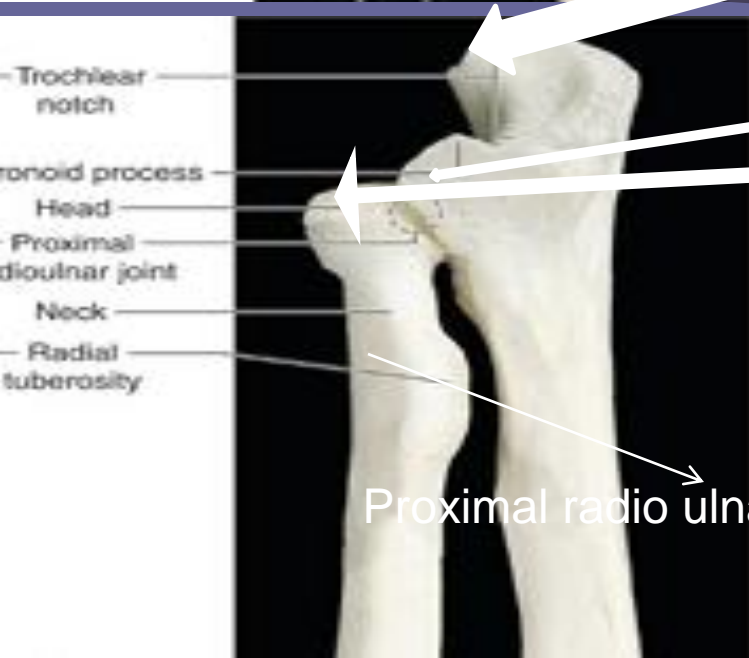
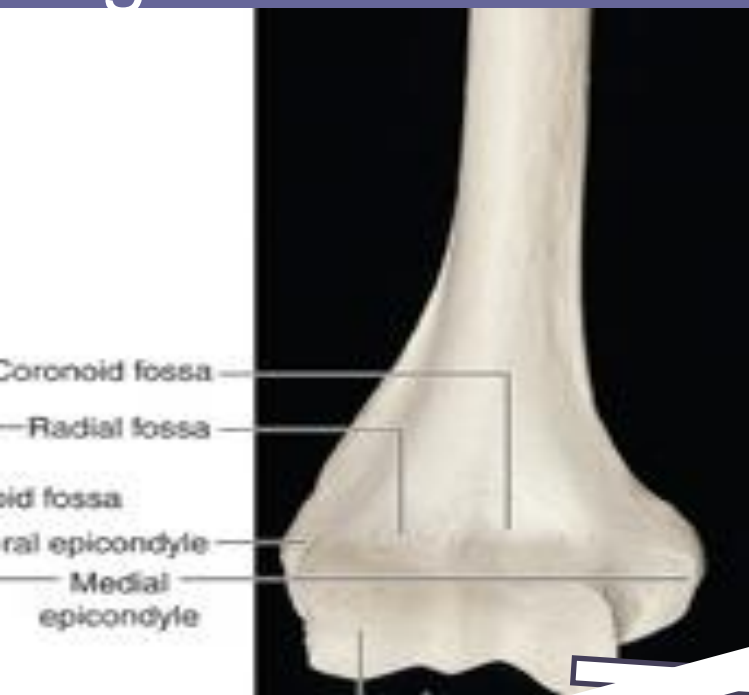


Lateral epicondyle
↓
Less round

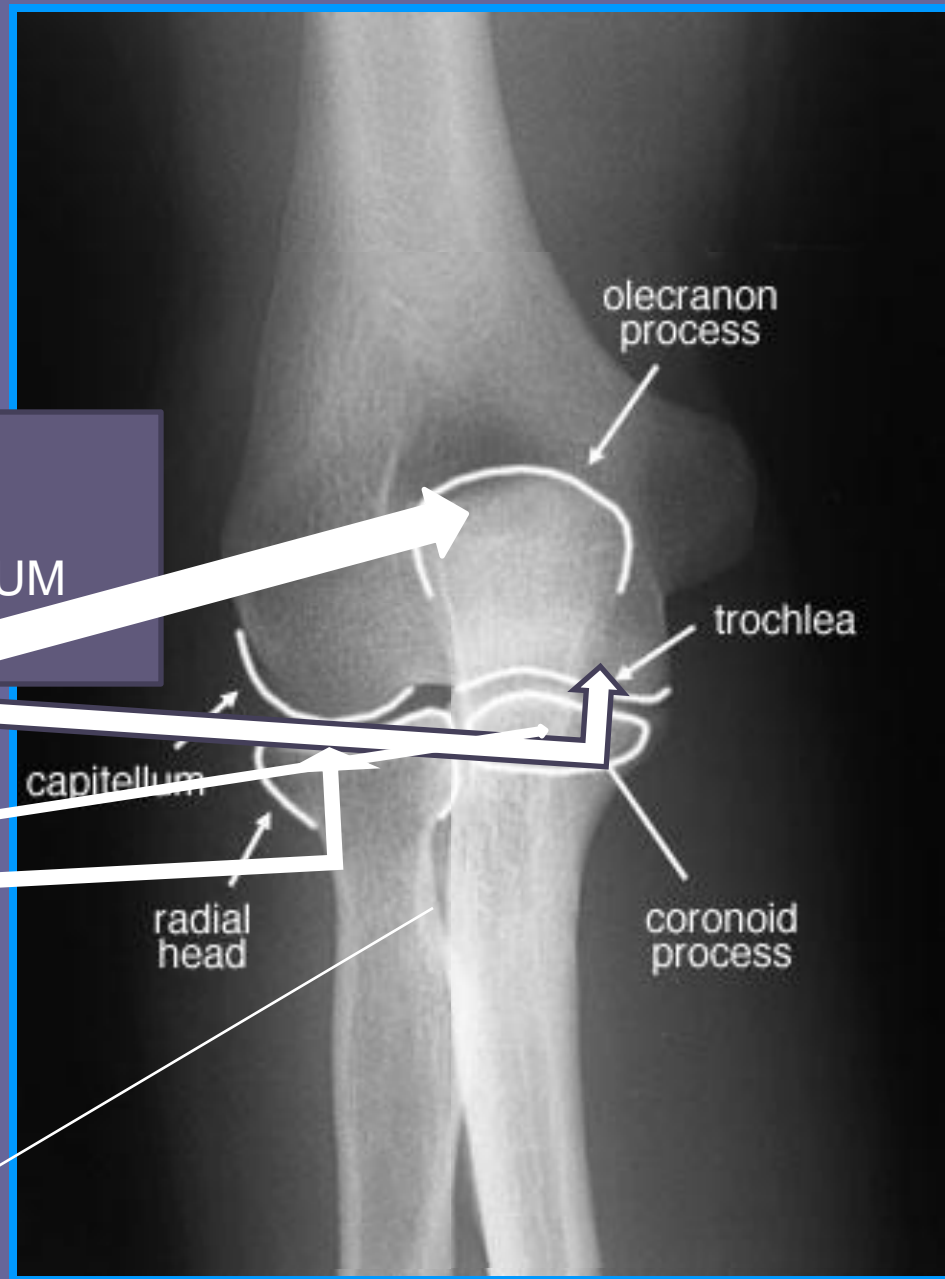




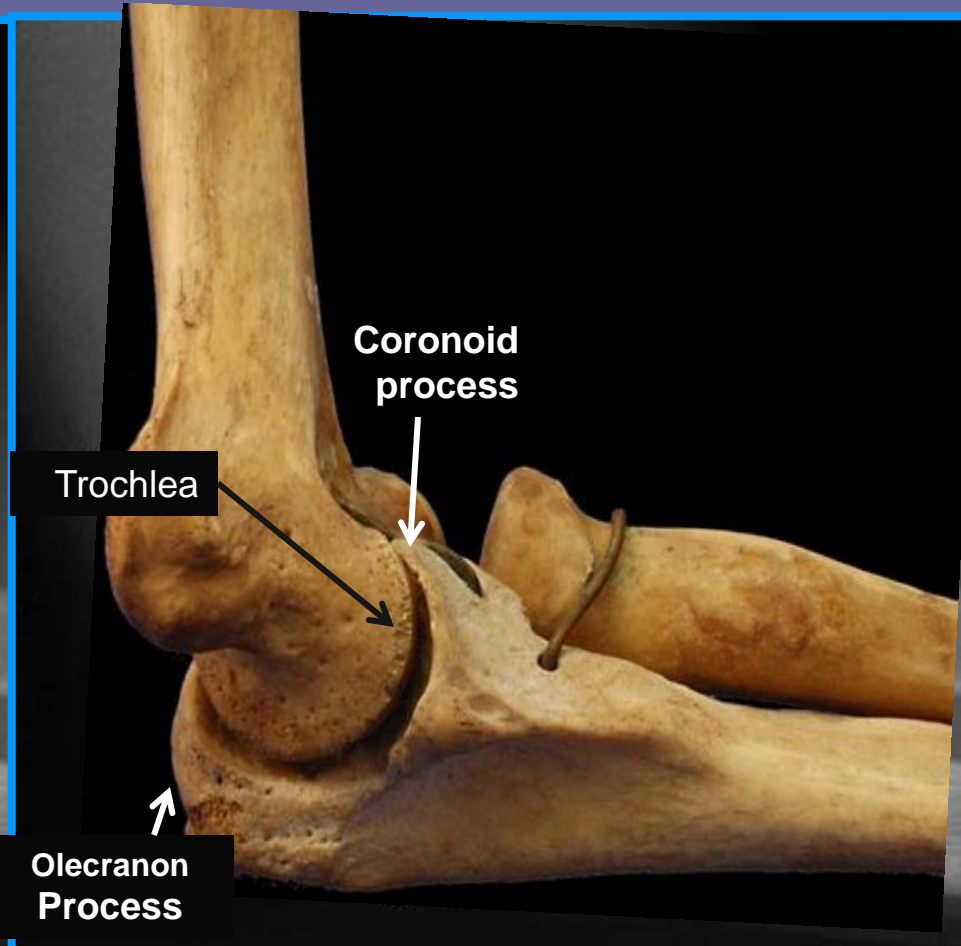
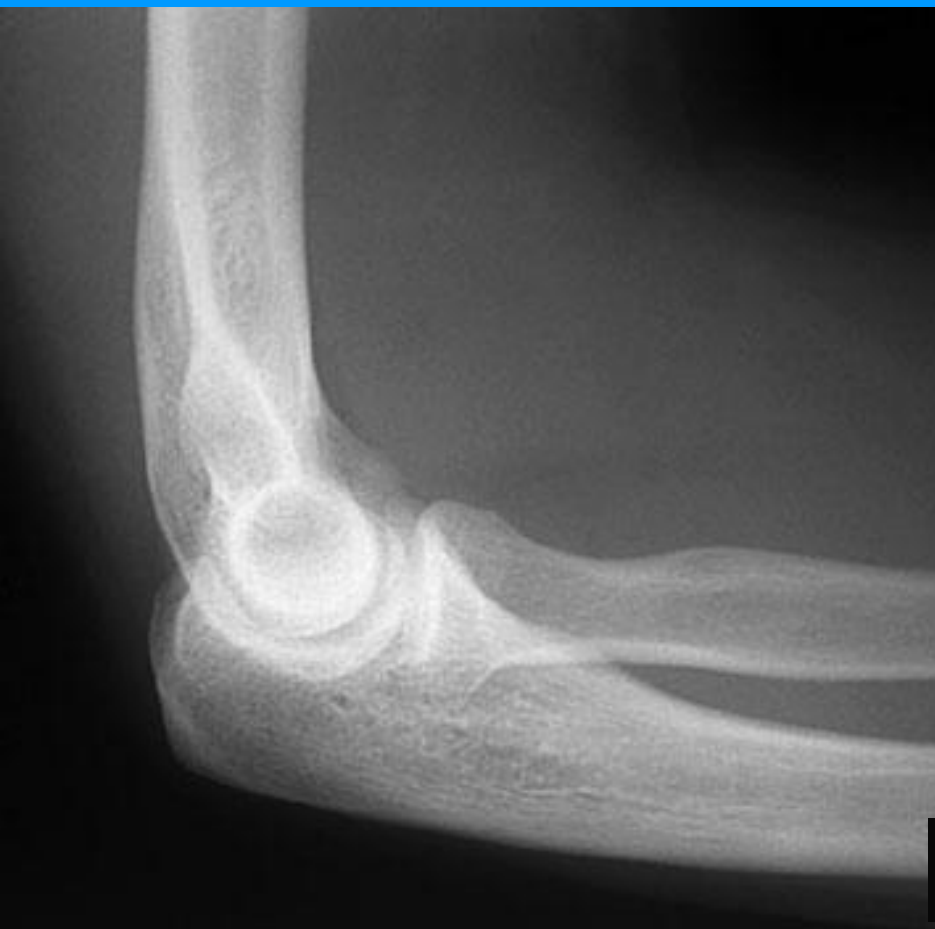Right arm & forearm

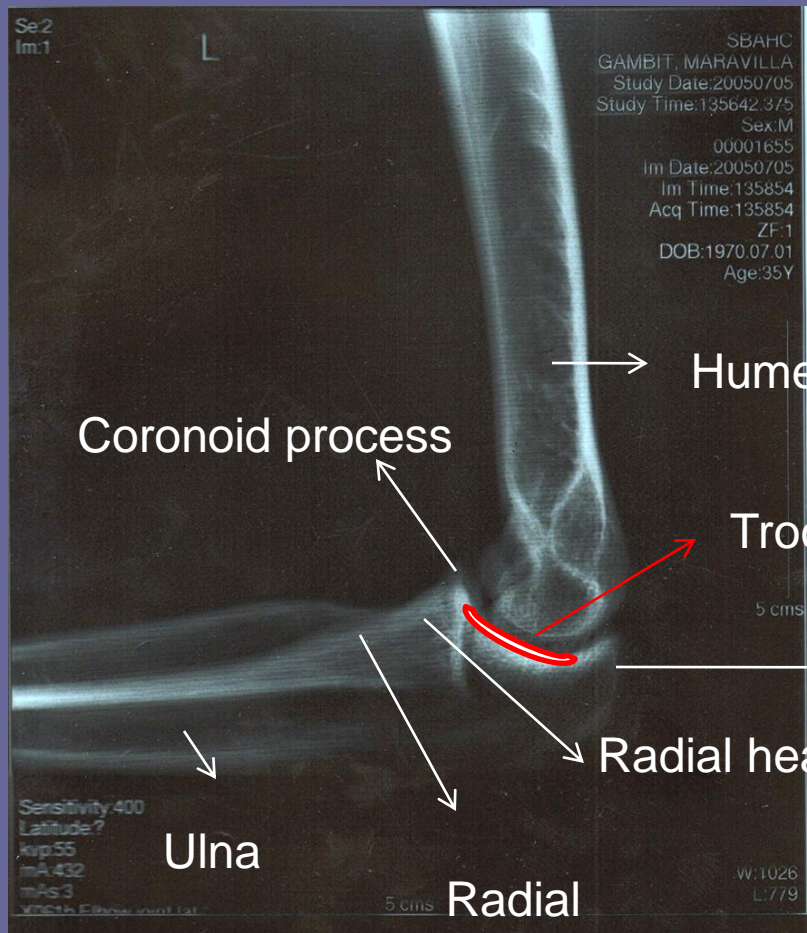


AP
CAPITULUM



Elbow, Lateral view





Coronoid process

Humerus

Trochlear notch

Olecranon process

Radial head

Ulna

Radial neck