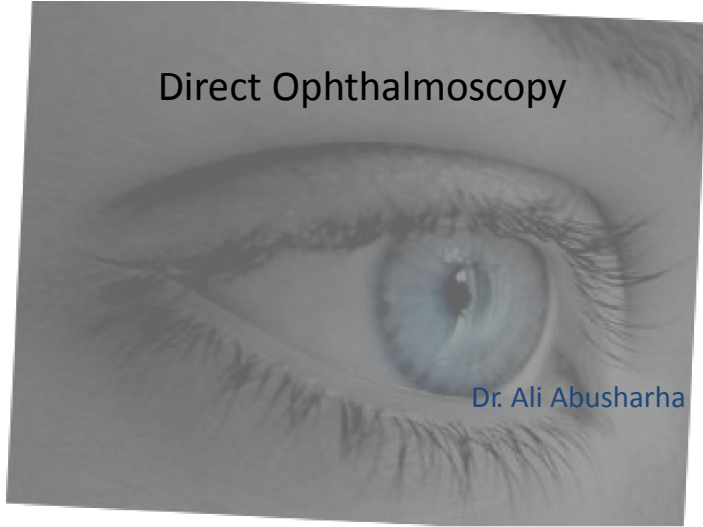



Direct Ophthalmoscopy



A bit of history...




Babbage and his direct ophthalmoscope

2



Hermann von Helmholtz (left) and his ophthalmoscope (right).

3



Helmholtz could place his eye in the path of the light rays entering and leaving the patient's eye, by looking through the source of light, thus allowing the patient's retina to be seen.

4

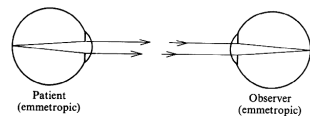


Modern Ophthalmoscope: Here light source from the batteries is reflected at 90° using a mirror placed in the head portion at 45° angle. The examiner looks through a hole in the mirror that is through the light.

5

6

Know your instrument...

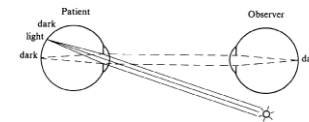


If patient and observer are both emmetropic, rays emanating from a point in the patient's fundus will emerge as a parallel beam and will be focused on the observer's retina.

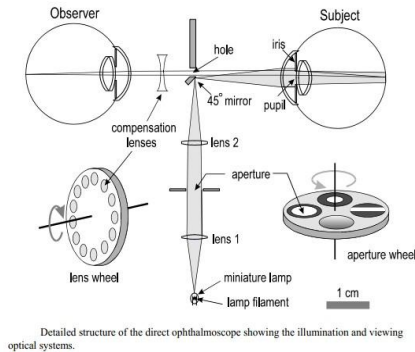
7

The illumination problem in direct ophthalmoscopy:

If the light source and the observer are not aligned optically, the observer views a part of the fundus that is not illuminated.



8

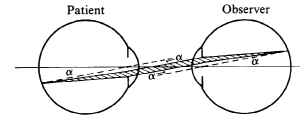


Detailed structure of the direct ophthalmoscope showing the illumination and viewing optical systems.

9

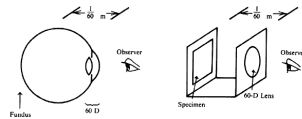
Field of view

- “ The maximum field of view is determined by the most oblique rays that can still pass from one pupil to the other.
- “ pupil to the other.
- “ Angle α , the field of view, is increased when the patient's or the observer's pupil is dilated or when the eyes are brought more closely together.
- “ Most ophthalmoscopes project a beam of light of about one disc diameter.



Magnification

- “ Viewing the fundus through the optics of the patient's eye (60 D in the reduced eye) can be compared with viewing a specimen under a 60-D magnifier.
- “ How much larger does the patient's disc appear than does the disc of a dissected eye viewed at 25 cm?
 - -60D lens allows a viewing distance of 1, 67m, 15 times shorter than the reference distance of 0.250 m. Thus, the viewing angle is 15times larger, and the magnification is said to be **15 times**.








11

Image	Virtual / Erect
Field of view	2DD = 10°
Magnification	15X
Area of fundus seen	% 70-50
Image brightness	4Watts
Working distance	2-1cm
Stereopsis	None

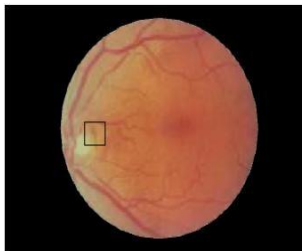12



13

- 
Small Aperture: For easy view of fundus through the undilated pupil. Always start with this while looking at the fundus.
- 
Large Aperture: Standard aperture for dilated pupil and general examination of the eye, particularly the red reflex.
- 
Sm Micro Spot Aperture: Allows easy entry into very small, undilated pupils.
- 
Slit Aperture: Helpful in determining various elevations of lesions, particularly tumors and edematous discs.
- 
Fixation Aperture: The pattern of an open center and thin lines permits easy observation of eccentric fixation without masking the macula.

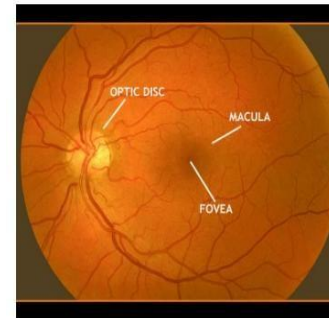
14



A view of direct fundoscopy

A view of indirect fundoscopy of a normal fundus with the focus area of direct fundoscopy highlighted.

15



16

How to perform?

4. Tilting slightly at 15-25° lateral to the patient, move forward as you direct the light beam into the pupil. The optic disc should be within view as you are about 1-2 inches from the patient's eye. remember that the optic disc is slightly towards the nasal aspect of the fundus.
5. The optic disc may not be focused as you see it, as hypermetropic patients require more "plus" (green numbers) lenses for clear focus of the fundus while myopia patients require more "minus" (red numbers).
6. Examine the optic disc for:
 - color
 - contour (margin, shape, elevation, etc)
 - cup-disc ratio
 - caliber of vessels (normal AV ratio around 2:3.

17

19

1. Fundoscopy should be done on the same side for patient and the examiner. This being said, while examining the right eye, hold the fundoscope with your right hand, and examining with your right eye on the right side of the patient.
2. Setting the illuminated lens disc at positive (Green) usually from 4-10, stand from approximately 1 arm's length from the patient while illuminating the patient's both eyes using the large aperture. This enable you to examine the red reflex of the patient.
3. Select "0" on the illuminated lens disc and start with the small aperture as you approach the patient while fixing the "red reflex" pupil as your target. Remember to ask the patient to look straight at a distance to maintain pupil dilation.
7. Follow each vessel as far to the periphery as you can and look for any abnormalities such as venous dilatation, AV nipping, etc.
8. To examine the periphery, ask the patient to:
 - Look up for examination of the superior retina
 - Look down for inferior retina
 - Look temporally for temporal retina
 - Look nasally for nasal retina.
9. Lastly, locate the macula which is approximately 2 disc diameters temporally, between the superotemporal and inferotemporal vessels. Or you can ask the patient to look at the light of the ophthalmoscope, which would put the macula in good view. Look for abnormalities. Red filter facilitates the view of macula.
10. For the examination of the left eye, the same procedure can be repeated, but with left hand and left eye on the left side.

18

20

- ~ The routine fundus examination in neurologic patients is generally done through the undilated pupil.
- ~ A crude estimate of the narrowness of the iridocorneal angle can be made by shining a light from the temporal side to see if a shadow is cast on the nasal side of the iris and sclera.
- ~ The risk of an attack of acute narrow angle glaucoma due to the use of mydriatic drops has been estimated at .0.1%
- ~ Mydriatic drops are best avoided in situations where assessment of pupillary function is critical, such as patients with head injury or other causes of depressed consciousness.

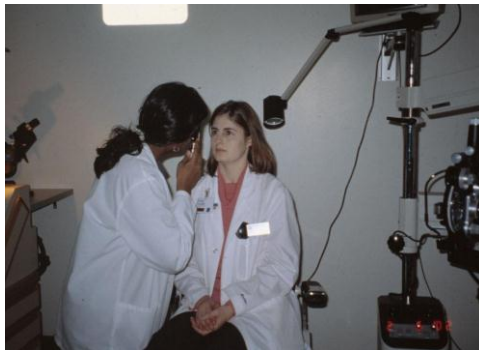21

Adjust
light)left(and power)right(



22

Examiner right eye, hand, right
patient eye



23

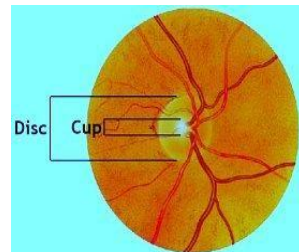
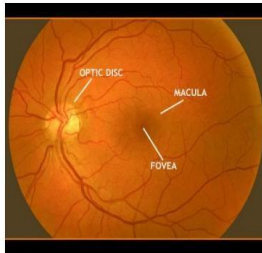
Accessories

- ~ **A fixation star**, a dot or a star-shaped figure, may be used to determine the patient's fixation.
- ~ **A slit diaphragm** is often provided to allow slit-lamp type observation of elevated retinal lesions.
- ~ **A pinhole or half-circle diaphragm** may be used to reduce reflections by limiting the illumination beam. It is also helpful in the observation of certain fine retinal details
- ~ **A "red-free" filter**. Lack of red light makes the red elements very dark so that vessels and pinpoint hemorrhages stand out more clearly.
- ~ **A blue filter** may be provided to enhance the visibility of fluorescein, for use in fluorescein angiography and as a hand-held light source for fluorescein staining of the cornea.
- ~ **A set of crossed polarizing filters** in illuminating and viewing beam is sometimes used to reduce reflections

24

Some Anatomical & Pathological aspects

25



27

Optic disc

- " The point where the optic nerve enters the retina (Blind spot)
- " The vertical cup disc ratio in a normal person is 0.1-0.5
- " Pathological changes are suspected in ratios more than .0.5
- " The cup is always on the temporal side of the optic disc, while there is crowding of vessels on the nasal side of the optic disc.

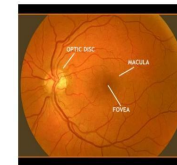
26

" Macula

- . The pigmented area of the retina
- . Lies about 2 disc diameters temporal to and slightly below the disc
- . Rich in cones
- . Responsible for clear detailed vision.

" Fovea

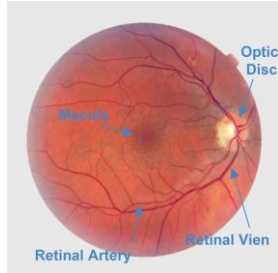
- . A small rodless area of the macula that provides acute vision.



28

~ Vessel branches

- . There are 4 main branches of vessels from the optic disc. Each branches off into different directions, mainly the superonasally, superotemporally, inferonasally, inferotemporally



29

Causes of disc swelling:

Unilateral	Bilateral
Vascular: eg. AION, CRV or diabetic papillopathy	Raised intracranial pressure: SOL, hydrocephalus, Benign Intracranial Hypertension (BIH)
Inflammatory: "papillitis", eg. uveitis, sarcoidosis, viral, SLE	Malignant hypertension
Demyelination: MS- may become bilateral	Diabetic papillopathy
Hereditary: Leber's Hereditary Optic Neuropathy	Infiltrative papilloedema
Infiltrative: tumors such as retinoblastoma, lymphoma	Toxic: ethambutol, chloramphenicol uremia
Infective: Toxoplasmosis, herpes, Lyme's disease	

30

v. Papilloedema vs Optic Neuritis

	Papilloedema	Optic Neuritis
Definition	Passive swelling of the optic disc secondary to increased intracranial pressure. Eg. Space Occupying lesion, meningitis, benign intracranial hypertension (BIH)	Inflammation of the optic nerve. 2 types of optic neuritis: a. Papillitis Optic disc is swollen b. Retrobulbar neuritis Normal appearance of disc
Visual Acuity	Transient obscuration – mostly normal until late stage	Reduced
Pupil reaction	Normal, no RAPD	Positive RAPD in unilateral cases
Visual field	Enlarged blind spot	Central or paracentral scotoma
Color vision	Normal	Red desaturation

31

Optic atrophy

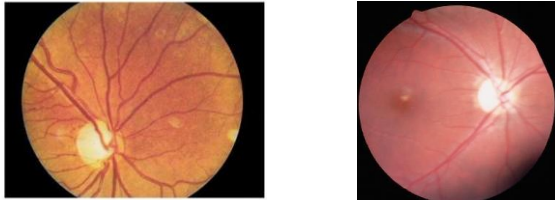
~ Primary

- . Without swelling of optic disc
- . Lamina cribrosa – LGB
- . White flat disc with clearly delineated margins
- . ↓no. of blood vessels (Kestenbaum sign)
- . Causes: RBN, Trs, Aneurysms, Trauma

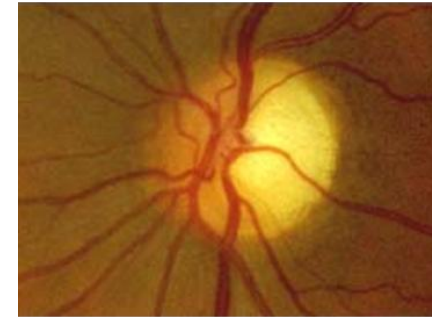
~ Secondary

- . Long-standing swelling of optic disc
- . White / dirty grey, slightly raised disc with poorly delineated margins
- . ↓no. of blood vessels (Kestenbaum sign)
- . Surrounding water marks
- . Causes: C/c papilledema, AION, Papillitis

32



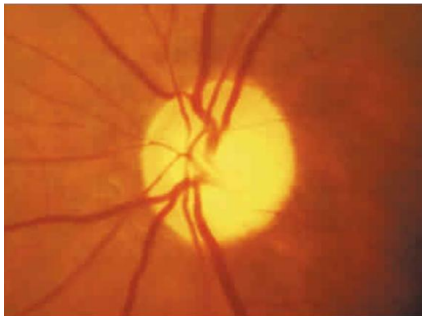
33



Temporal pallor of the optic disc:

The disc is strikingly pale, in a quadrant or crescentic manner. This is due to involvement of papillomacular bundle. Seen in Multiple sclerosis but not constant or pathognomonic.

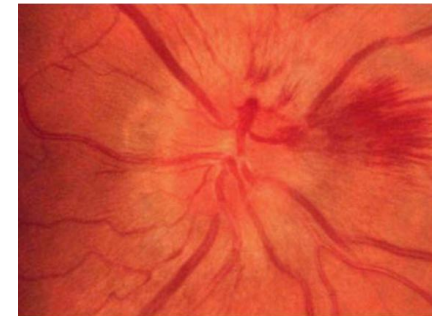
34



Primary Optic Atrophy:

The whole disc appears to be white in color, standing out dramatically like a full moon against a dark red sky. The margins of the disc are distinct and the whiteness is uniform.

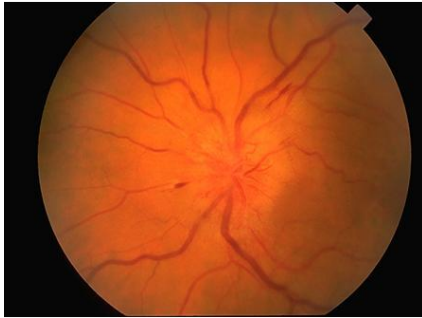35



Papilledema:

The area covered by the disc is larger. Margins of the disc cannot be defined. Irregular radial streaks of blood, are seen surrounding the disc, giving the disc an angry appearance.

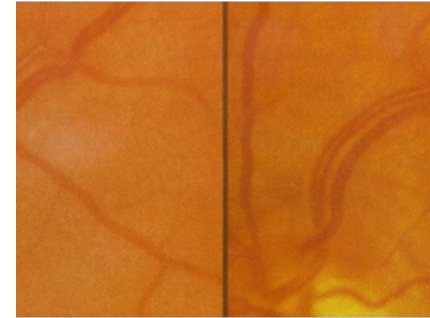
36



Papillitis or optic neuritis:

The degree of swelling is usually slight and the area of the disc is not enlarged and the humping is only mild. It is usually unilateral. The veins are not engorged & hemorrhages absent.

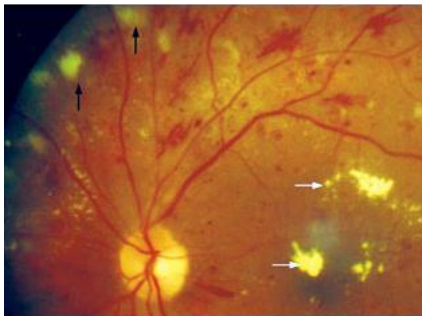
37



Arteries and veins:

The retina as seen by ophthalmoscopy will have the optic disc, the macula and the fovea. The retinal vessels are seen emerging from the optic disc, the veins larger than arteries.

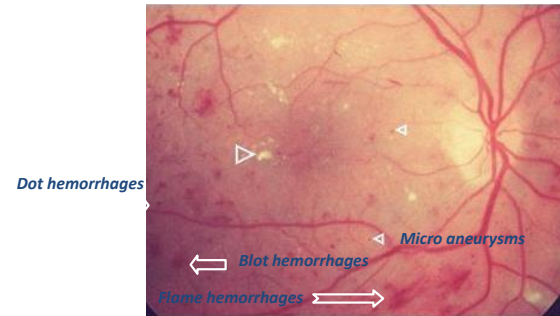
38



Soft exudates and hard exudates:

Soft exudates, otherwise called as cotton wool spots, are fluffy shadows, with indistinct margins, indicating micro-infarcts of neuronal axons. Hard exudates are due to leakage of proteins.

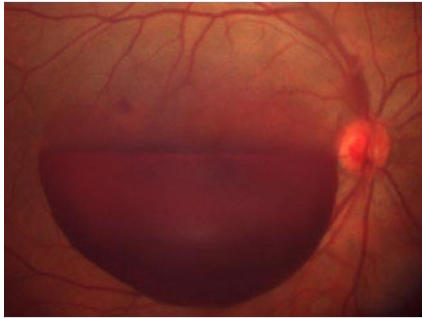
39



Micro-aneurysms, dot and blot hemorrhages:

Micro aneurysms are small rounded pin head size swellings of retinal vessels. On the other hand the dot and blot type of hemorrhages are having irregular shape and fluffy margins.

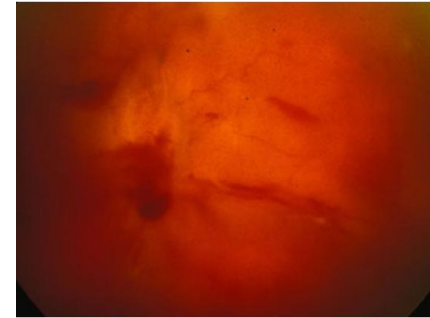
40



Sub-hyaloid or pre-retinal hemorrhage:

They appear as large effusion of blood, related to and often below the disc, with a crescentic inner and clear cut outer margin extending forwards towards the lens. Seen in S. A. H.

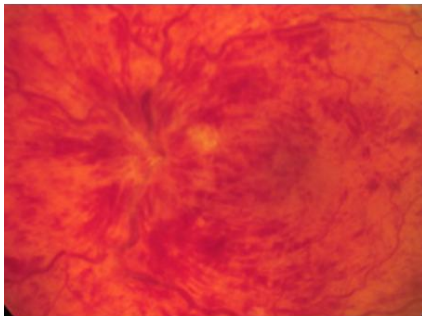
41



Vitreous Hemorrhages:

Hemorrhages in the vitreous have more non homogenous appearance with diffuse haziness of the vitreous making it almost impossible to visualize the details of the retina behind.

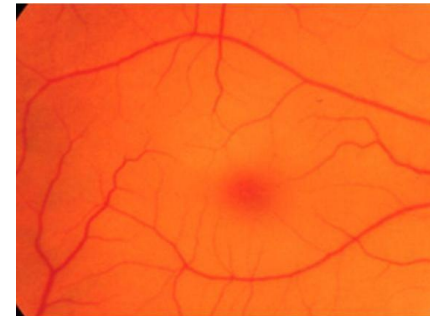
42



Central Retinal Vein Occlusion:

This gives rise to the picture of extensive blot and dot hemorrhages of the retina, giving it a "blood and thunder" appearance. Disc margins are also swollen and indistinct.

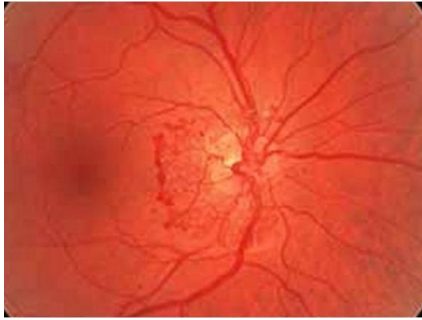
43



Central Retinal Artery Occlusion:

In contrast to the appearance of CRV Occlusion there is extensive pallor of the retina with a very characteristic cherry red spot in the region of the fovea. Disc is normal.

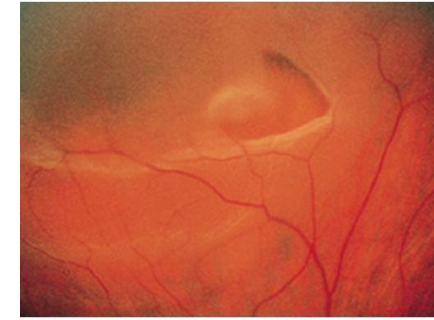
44



Neovascularization of the disc:

When a fresh leash of new vessels are seen anterior to the retinal disc it is called neovascularization. This is secondary to the ischemia of the retina resultant of hypoxemic stimulus.

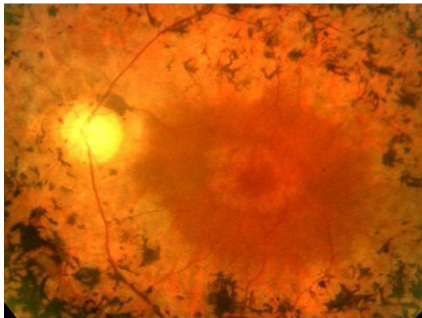
45



Retinal detachment:

Appears as an elevated sheet of retinal tissue with folds. If the fovea is spared the visual acuity is usually normal. If there is a superior detachment there will be an inferior scotoma.

46



Retinal pigmentation:

Black deposits of irregular clumps of pigment called as bone spicules are seen especially in the periphery of the retina. Called so because of their resemblance to the cancellous bone

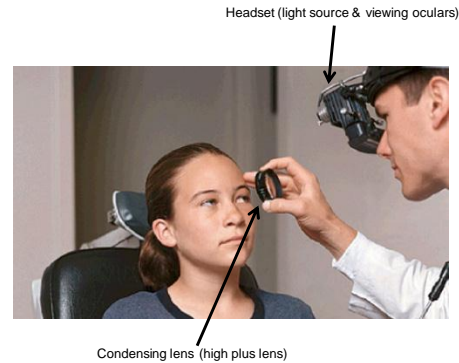
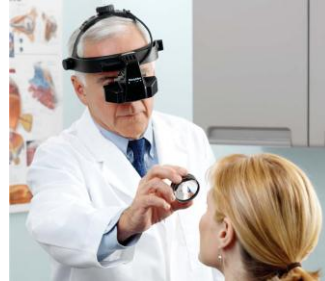48

Some tips...

- “ Don't think about your / patients' spectacles.
Set at ""0
- “ Right with right & left with left
- “ Keep other eye open
- “ Get very close to the patient, this gives wider field of vision

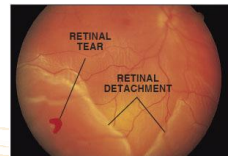
49

Indirect Ophthalmoscope



Clinical Uses

- ” To compare the red reflex in each eye.
- ” To test the response from each pupils.
- ” Stereoscopic view of the ocular fundus. (retinal detachment (retinal break, vitreoretinal abnormalities, high myopia



Functions of hand-held condensing lens:

- § Direct the light source of the instrument through the patient's pupil.
- § Generate an indirect aerial (real) image of the illuminated retina at the lens focal length, allowing maximum field of view and satisfying the condition for stereopsis

