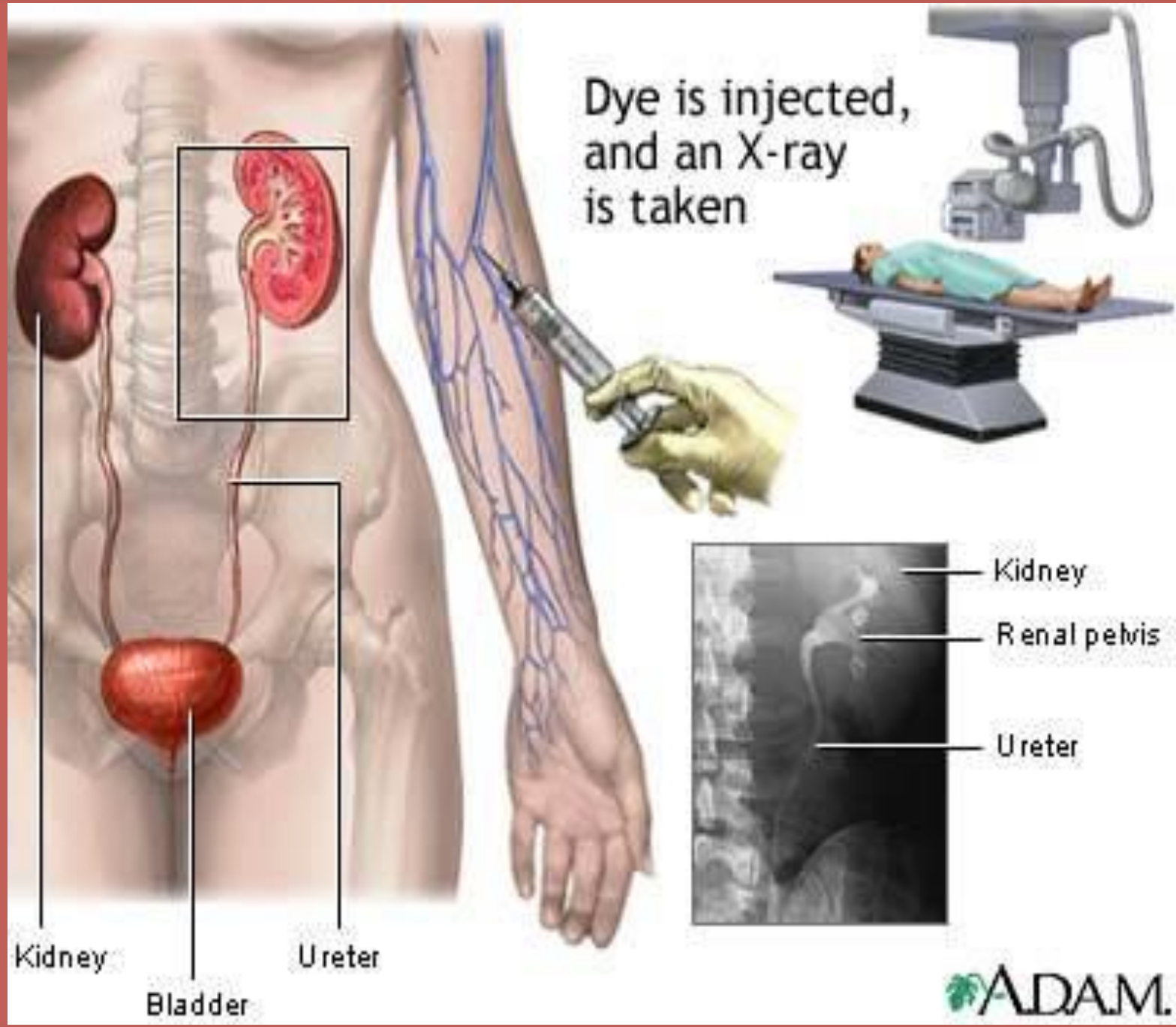


IVU

((INTRAVENOUSUROGRAM))





Dye is injected,
and an X-ray
is taken

Kidney
Bladder
Ureter

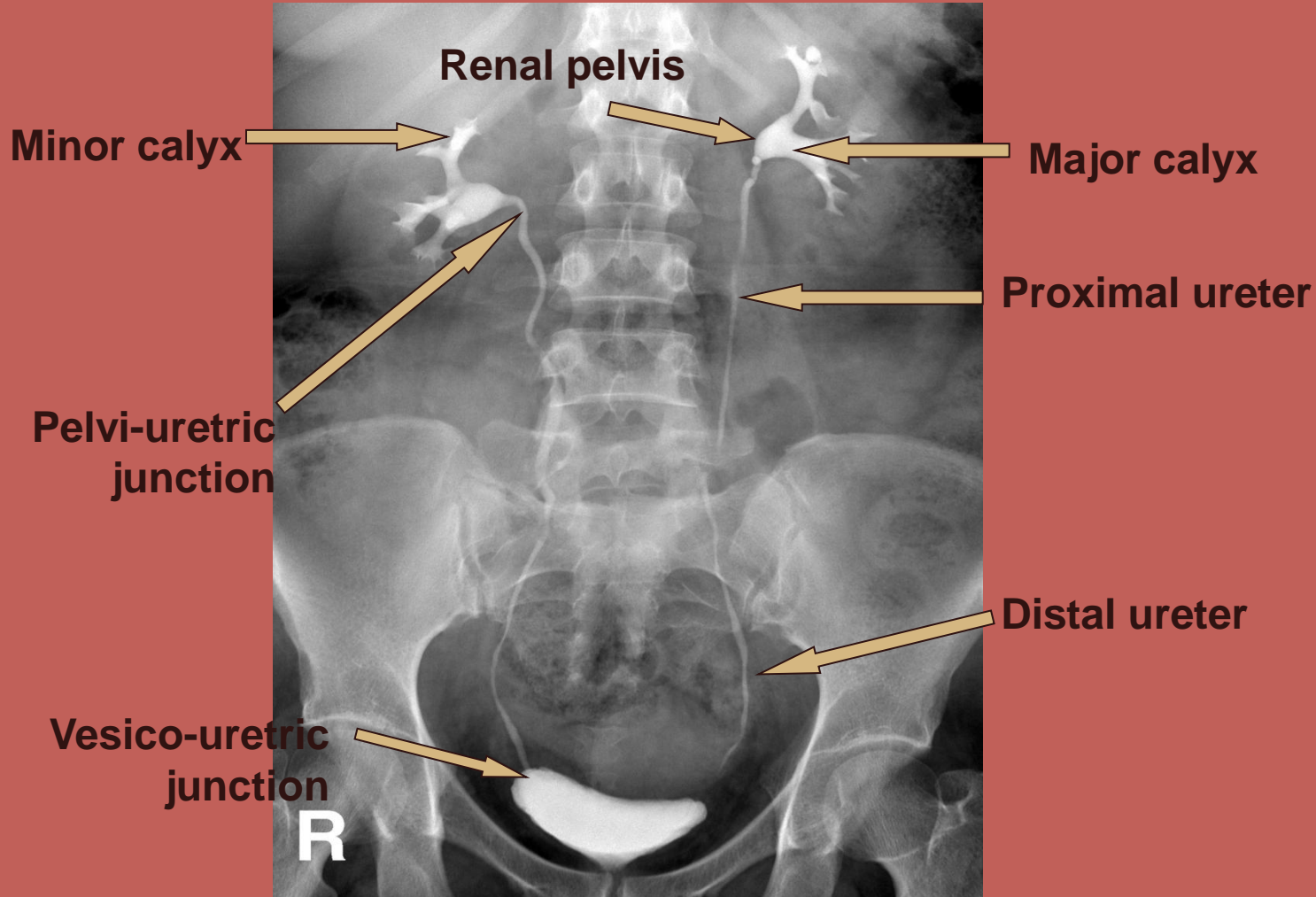
Kidney
Renal pelvis
Ureter



Anatomy

The urinary system consists of the following :

2 kidneys, 2 ureters, 1 bladder , 1 urethra



CONTRAST MEDIA: Is a pharmaceutical given to the patient to enhance the original organ or tissue, e.g. **kidneys, ureters, bladder.**

There are two types of contrast : positive contrast & negative contrast

1- **positive contrast** → with ↑ atomic number (Z), e.g. barium sulphate and iodine compounds

2- **negative contrast** → with ↓ atomic number (Z), e.g. air, oxygen & carbon dioxide.

Administration of contrast media:

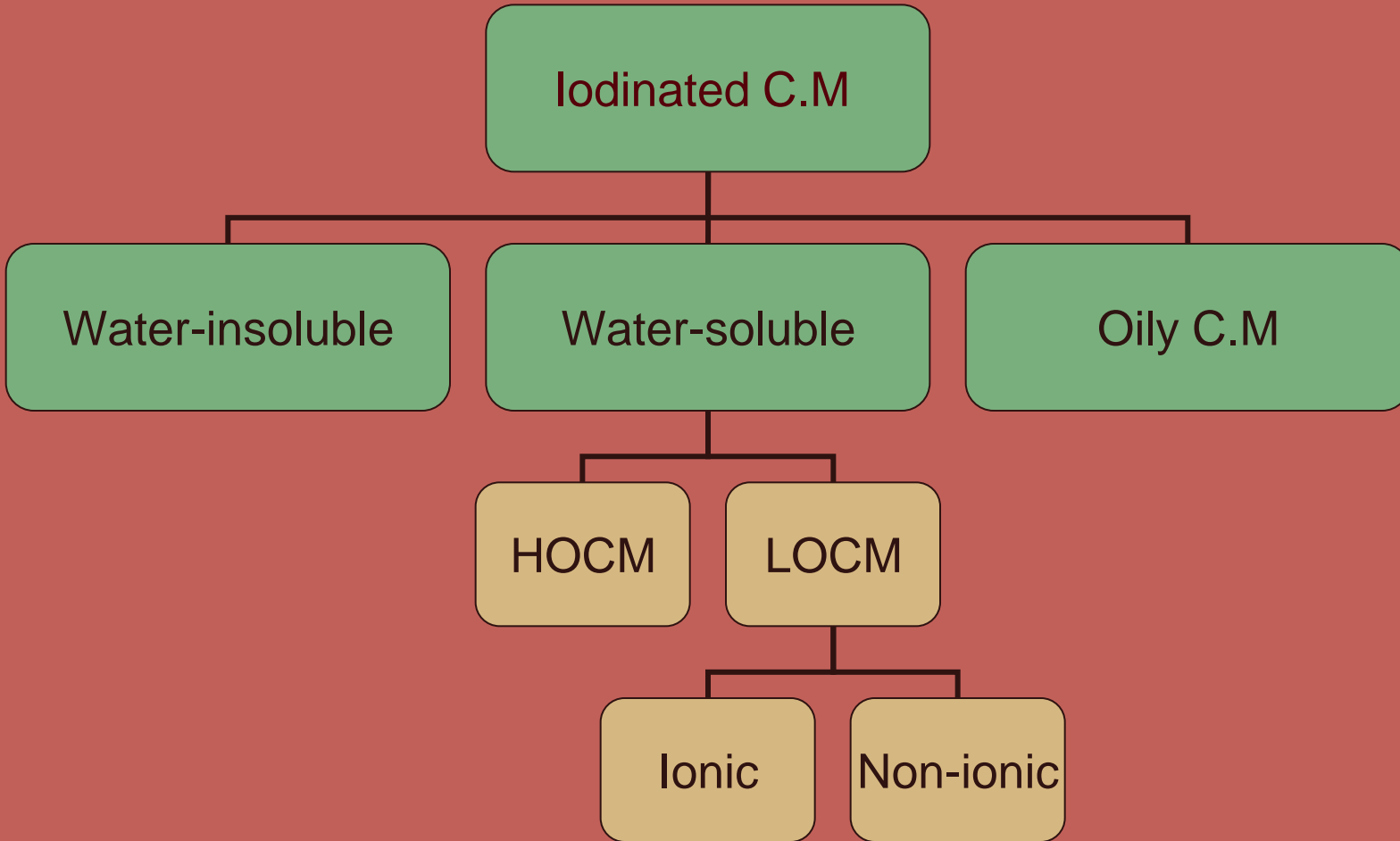
1- injected intravascularly as in IVU exam.

2- ingested as in barium meal examinations

3- injected into the (CSF) cerebrospinal fluid.



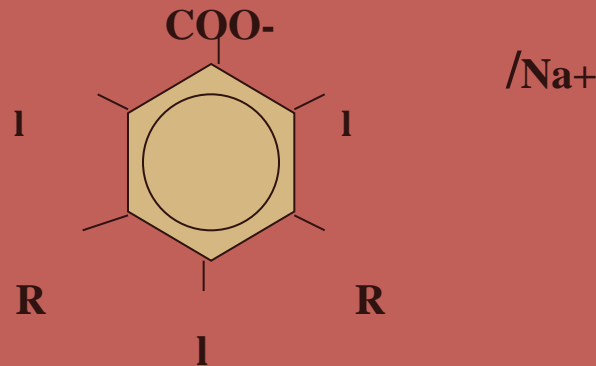
Iodinated Contrast Media



Contrast media can also be divided into :

1- (HOOCM) high osmolar contrast media : osmolality is 4-7 times that of human blood. This HOOCM consists of a benzene ring with 3 iodine atoms and a positive cation (usually sodium or meglumin) and a negative anion (usually carboxyl group). Once injected into the plasma the cation dissociates from the compound creating two separate ions in the blood ,these free ions cause an imbalance in homeostasis and an increase in plasma osmolality .This increase in osmolality causes the body to have a reaction. Iodine to particle Ratio=3/2 .

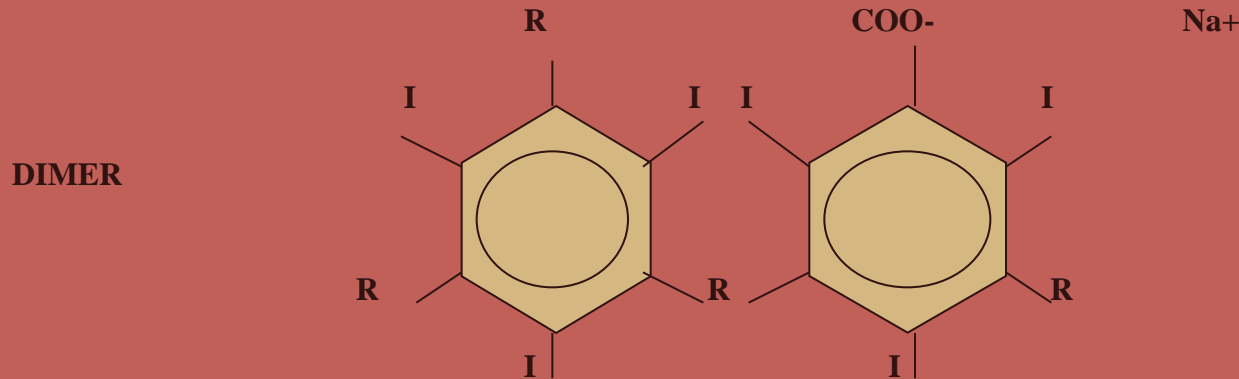
Monomer



so by reducing the number of free cations which do not contribute to the diagnostic image and are responsible for 50% of reactions , it was possible to ↓the toxicity of the contrast .

2-(LOCM) low osmolar contrast media: osmolality is 1/3 of HO CM.

By adding another benzene ring with an organic side chain, they were able to increase the iodine concentration with less number of cations Ratio=6/2



Then they were able to modify the contrast even further by eliminating the cation and replacing it with an amide or glucose group when injected into the blood remains intact .

e,g LOCM Niopam ,Omnipaque ,Isovist ,Ultravist ,Hexabrix . They are all Low osmolar non-ionic contrast media except for Hexabrix it is Low osolar ionic contrast media

WHEN SHOULD WE USE (LOCM)?

- 1-infants & small children**
- 2-pt with renal and /or cardiac failure**
- 3-poorly hydrated pt**
- 4-pt with diabetes os sickle-cell anemia**
- 5-pt who have had previous reactions to CM or have a strong allergic history.**



Adverse Reactions to C.M:

CONTRAST REACTIONS



```
graph TD; A[CONTRAST REACTIONS] --> B[MILD]; A --> C[MODERATE]; A --> D[SEVER];
```

MILD

No need for medication
Just reassure the pt
e.g. flushing,urticaria
nausia,vomating,pruritis

MODERATE

Needs medication
& observation
e.g. facial oedema,
Bronchospasm
hypotension

SEVER

Needs immediate
response or CPR
e.g.convulsions.
cardiac arrest

IN CASE OF REACTION TO C.M :

**Adrenaline ,Aminophylline ,Atropine,Hydrocortisone
,Lignocaine,Antihistamine, Dopamine**

CONTRAST DOSE :

adults : 1ml per kg - minimum dose is 50 ml

paediatrics :2 ml per kg

Neonates :4ml per kg

Before starting an IVU exam always checke the following:

- Creatinine levels ↑ levels of creatinine indicates renal disease.**
- Consent must be signed .**
- In case of female pt do a pegnancy test**

PT PREPARATION :

**a- pt should be NPO for 8 hours.(fluid restriction is contra-
indicated in pts with renal failure ,or myelomatosis, infants &
children) and the last meal should be at 7:30 without any dairy
products.**

**b- instruct the pt to take 60 mg of castor oil the night before the
Exam at around 8 :30 pm.**

**c-pt should preferably be ambulant ? so to avoid the accumulation
of intestinal gas .**



**d-cleansing enema before the exam to reduce bowel gas.
e-in case of female pt make sure that she is not pregnant(10 day rule).**

f-pt must micturate immediately before the examination .

**Preparation for allergic pt :prednisone tablet 2x25mg twice a day ,
one day before the exam and the day of the exam .**

Then 2x5mg twice a day for the 2 days after the exam.

Then 5mg one tablet twice a day then stop.

KV	mAS	FFD (SID)
65 -80	50-100	100-115

IMAGES TAKEN:

1-Preliminary film,(scout film), (control film):

It is (KUB):supine full length AP of the abdomen , it should include the symphysis pubis.

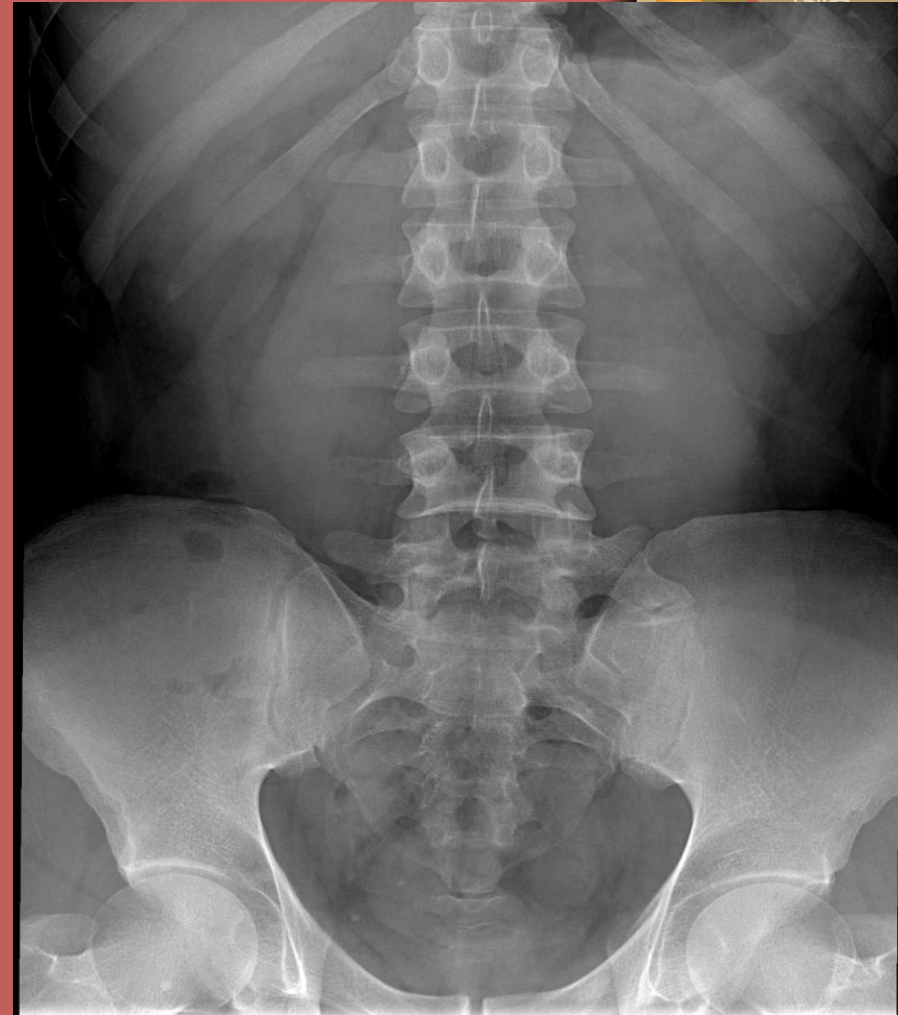The control film is taken to:



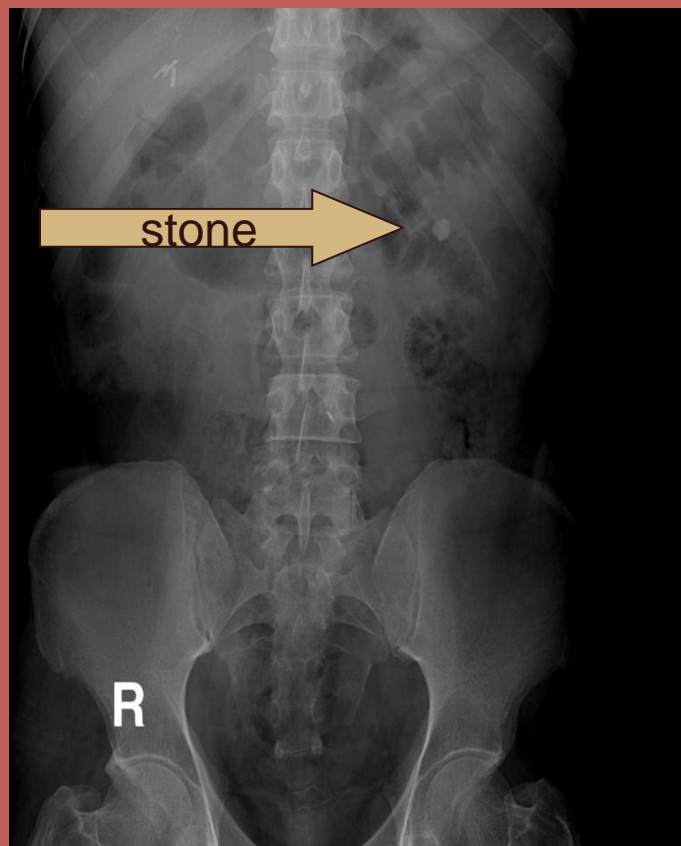
preliminary film :

the control film is taken to:

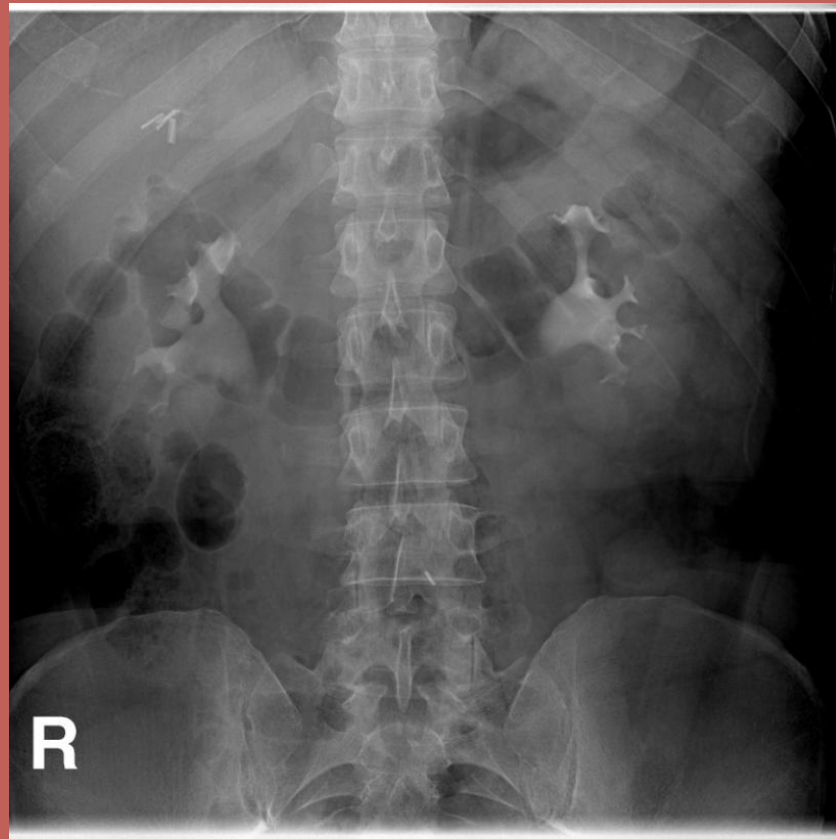
- a) verify pt position.**
- b) verify exposure factors.**
- c) check pt preparation .**
- d) rule out any calcifications or stones.**



Calcification appearing better in plain film



plain film



5 Min film



2-kidney area :

AP supine of the renal area

The preliminary films are shown to the radiologist to cheque further views may be required .e.g. oblique views.

The pt is injected with the contrast media.

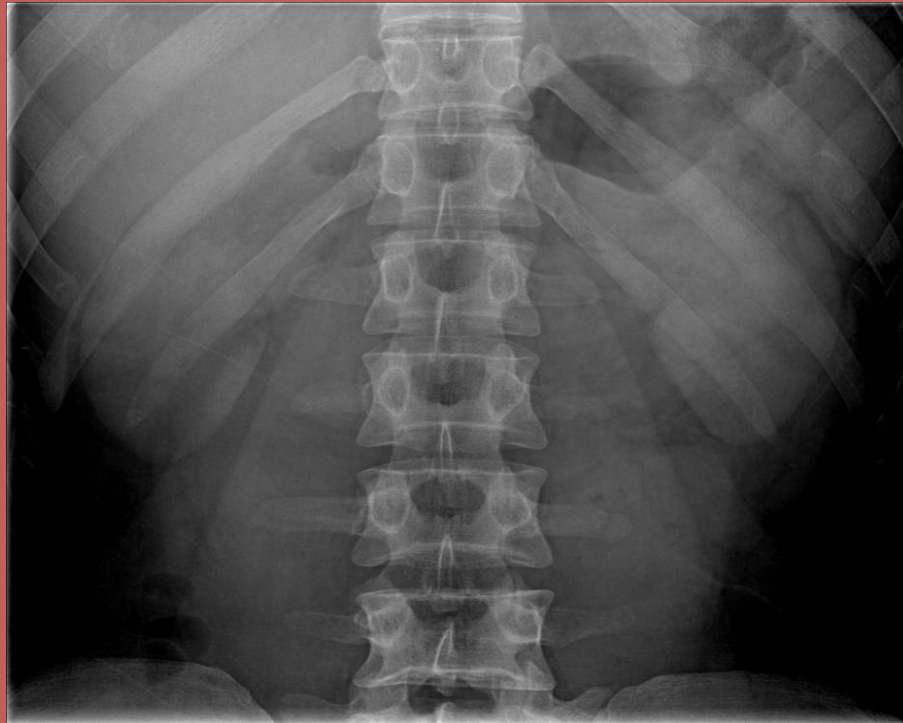FILMS TAKEN AFTER INJECTION:

1-IMMEDIATE FILM:

It is for the renal area to show the nephrogram phase (the renal parenchyma opasified by contrast media in the renal tubules) and to reveal any difference in function between the two kidneys.

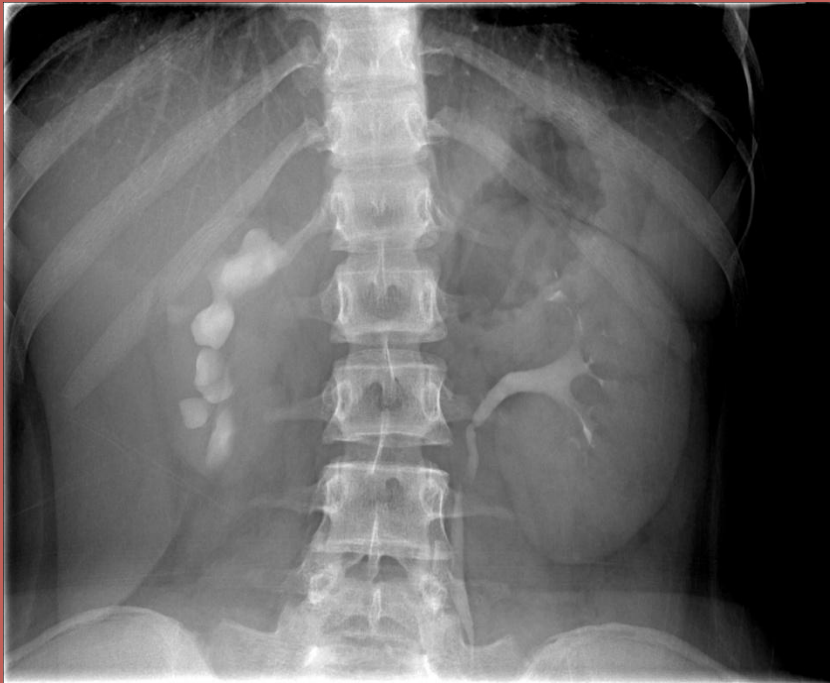


Immediate (kidney area)



2-5 MIN FILM :

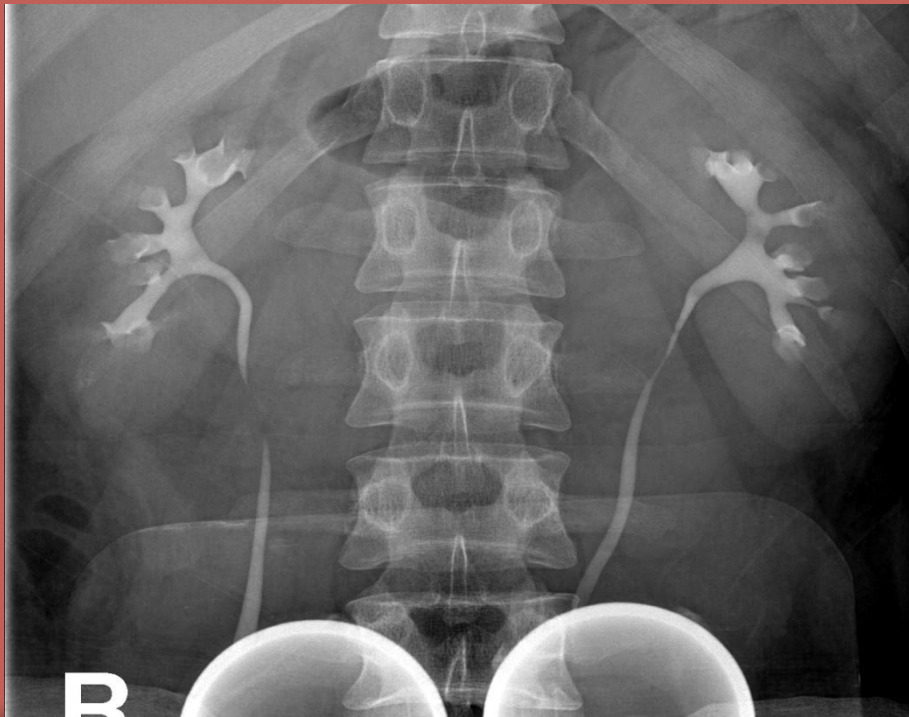AP of the renal area to reveal any difference in function or excretion between the two kidneys.



A compression band is now applied and the balloon is positioned midway between the A.S.I.S. (over the ureters as they cross the pelvic brim).The aim is to retain the contrast within the pelvi-calyceal system and upper ureters .

3-10 OR 15 MIN FILM :

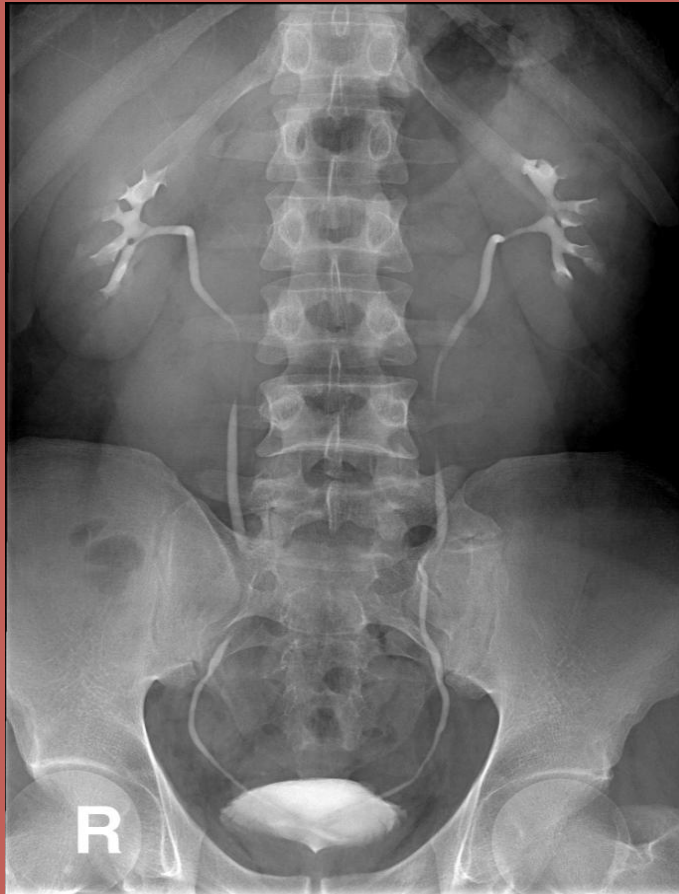AP of renal area . there is usually adequate distension of the pelvi-calyceal system by this time.



If satisfactory demonstration of the pelvicalyceal system has been achieved, compression is released.

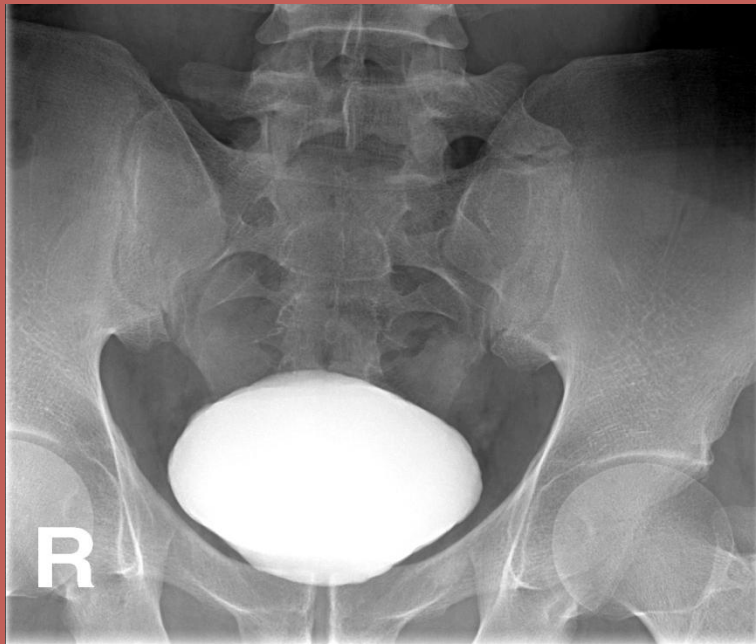
4-RELEASE FILM :

It is a full length supine film taken to show the whole urinary tract



5-FULL BLADDER FILM:

It is a coned view of the bladder. This is taken to show if there are any abnormalities in the bladder. If the pt is not full bladder after the release film you may ask him/her to wait in the waiting area until he/she is full then take the full bladder film.



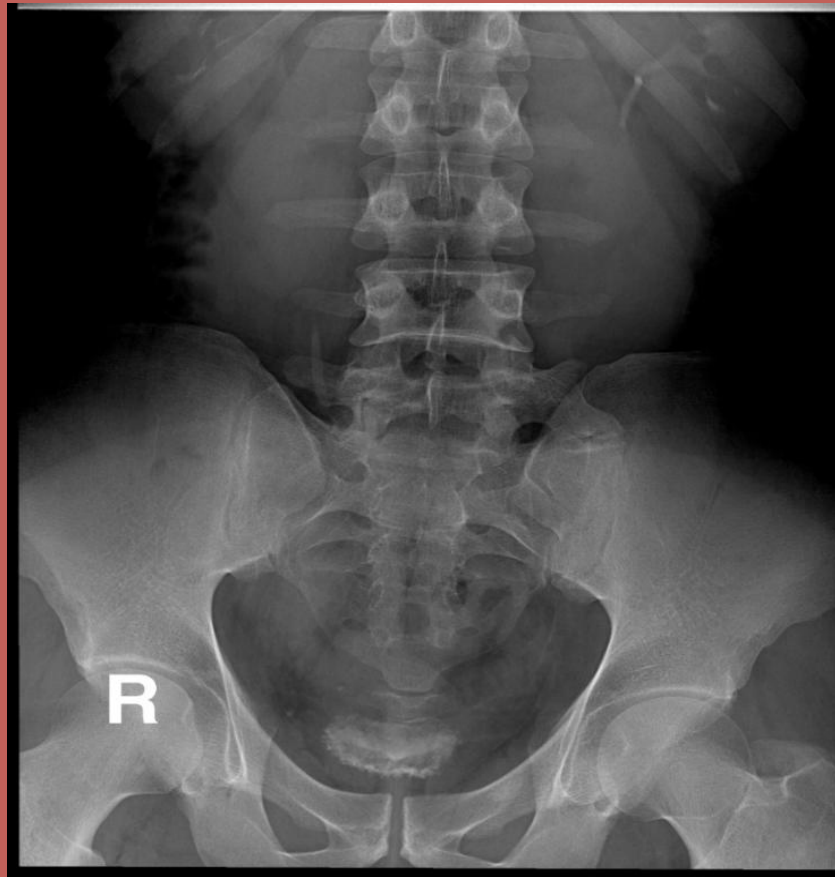If this film is satisfactory ,the pt is asked to empty his/her bladder.

6-POST MICTURITION FILM :

Based on the clinical findings & the radiological findings on the earlier films , this will be either a full-length abdominal film or a coned view of the bladder area with the tube angled 15 ° caudad.The value of this film is to assess bladder emptying , to demonstrate a return to normal dilated upper tract after the relief of bladder pressure ,to aid in diagnosis of bladder tumours,or diverticulms,to confirm vesicouretric calculi, to R/O reflux



Post void film



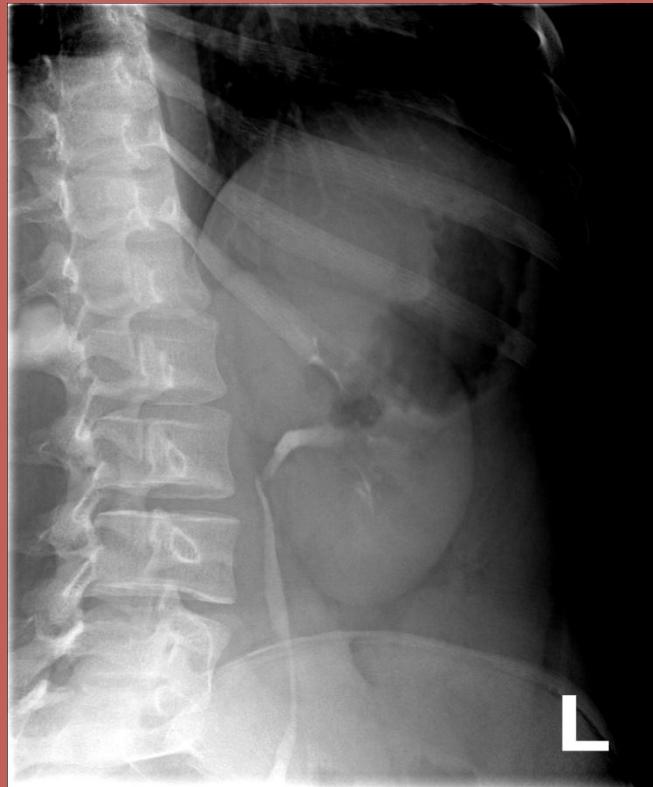Compression is contraindicated in the following cases :

- a) after abdominal trauma .**
- b) after recent abdominal surgery**
- c) abdominal mass.**
- d) uretric stone .**
- e) infants and small children .**
- f) severe abdominal pain .**

ADDITIONAL FILMS:

6-OBIQUE VIEWS:

**for either the ureters
or the bladder .**



7-PRONE VIEW :it may provide better visualization of the ureters by making them more dependent.

8-DELAYED FILMS : in cases of obstruction delayed films may be necessary for up to 24h.

THINGS TO REMEMBER

1-DON`T FORGET TO PUT THE MARKER BEFORE EXPOSURE .

2-MAKE SURE YOU HAVE THE CORRECT (SID) BEFORE EXPOSURE.

3-ALWAYS PAY ATTENTION TO THE TIME OF INJECTION , AND MAKE SURE THAT THE EXPOSURE IS DONE AT THE CORRECT TIME IT SHOULD BE DONE.

4-IF THE PATIENT IS FEMALE ALWAYS MAKE SURE SHE IS NOT PREGNANT!

Case study:

- Pt history.
- Symptoms and signs .
- Pt preparation.
- Procedure + technique .
- Images taken .
- Additional images and why.
- Show pathology in images .
- Talk briefly about pts disease.



MARK DISTRIBUTION

431

	MARK
ATTENDENCE	20
CASE PRESENTATION	20
FINAL PRACTICAL EXAM	60
TOTAL	100



MARK DISTRIBUTION

321

	MARKS
ANATOMY	20
FINAL ORAL EXAM	40
TOTAL	60

