



POSTER PRESENTATION

Dental implant displacement in the maxillary sinus: A case report



Mohamad Alanbari ^{a,*}, Abulrahman Alamri ^b, Ra'ed Al Sadhan ^c, Ayman Alaraik ^c

^a Prince Sultan Military Medical City, Riyadh, Saudi Arabia

^b Al-Iman Hospital, Riyadh, Saudi Arabia

^c Department Of Oral Medicine and Diagnostic Sciences, College of Dentistry, King Saud University, Saudi Arabia

Received 31 January 2019; accepted 4 February 2019

Available online 21 February 2019

Abstract *Case report information:* This case report describes clinical and radiographic features of a 30 years old female patient suffering from an accidental displacement of dental implant into the maxillary sinus.

Clinical presentation: She started to feel dyspneic, voice changing, headache and nocturnal snoring. She went to see an otorhinolaryngologist to address those symptoms, a complete clinical and radiographic work up revealed; adenoid with unilateral nasal blockage that could be associated with displaced dental implant into the right maxillary sinus.

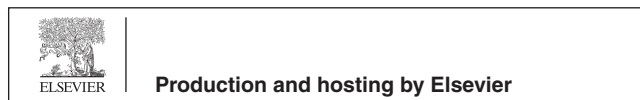
Clinical examination: The patient had poor oral hygiene and bad attitude toward dentistry. She presented with multiple missing teeth and many defective prosthesis. A panoramic film showed the horizontally displaced implant and the significance of the iatrogenic damage. Computerized tomography (CT) Report Computerized tomography (CT) sections in the coronal (A), sagittal (B), axial (C) and surface rendered view (D), of the paranasal sinuses showed that both extension of the maxillary sinus floor inferiorly and severe marginal alveolar bone loss have resulted in marked reduction in the dimensions of the residual alveolar ridge in the area of the missing posterior teeth in the upper right side. An unloaded dental implant was dislodged into the right maxillary sinus which is totally opacified with blockage of the ostium communication between the sinus and the nasal cavity. The wall of the right maxillary sinus is interrupted at the posterioinferiolateral corner (white arrow).


Conclusion: The dental implant preoperative assessment of sites in the maxillary premolar and molar areas must include radiographic assessment of the residual maxillary alveolar ridge relation to the maxillary sinus in all dimension. Although the recommended post implant insertion

* Corresponding author.

E-mail address: ruud-17@windowslive.com (M. Alanbari).

Peer review under responsibility of King Saud University.





radiographic examinations are intraoral radiographs and panoramic radiographs, when surgical complication are expected, the radiographic examination should include sectional images in all dimensions acquire. CBCT or CT that will help in the diagnosis, treatment planning and treatment.

© 2019 King Saud University. Production and hosting by Elsevier B.V. All rights reserved.
