



Wound healing of different molecular weight of hyaluronan; *in-vivo* study



Moustafa M.G. Fouda^{a,d,*,1}, A.M. Abdel-Mohsen^{b,c,d,**,1}, Hossam Ebaid^{e,f,***,1},
Iftekhar Hassan^e, Jameel Al-Tamimi^e, Rasha M. Abdel-Rahman^g, Ali Metwalli^f,
Ibrahim Alhazza^e, Ahmed Rady^e, Ayman El-Faham^{a,h}, J. Jancar^{b,c,i}

^a Chemistry Department, College of Science, King Saud University, P.O. Box 2455, Riyadh 11451, Saudi Arabia

^b CEITEC-Central European Institute of Technology, Brno University of Technology, Technicka 3058/10, 616 00 Brno, Czech Republic

^c SCITEG, a.s., Brno, Czech Republic

^d National Research Centre, Textile Research Division, Pre-treatment and Finishing of Cellulosic Fibers, Dokki, P.O. 12311, Cairo, Egypt

^e Department of Zoology, College of Science, King Saud University, P.O. Box 2455, Riyadh 11451, Saudi Arabia

^f Department of Zoology, Faculty of Science, El-Minia University, Egypt

^g Institute of Organic Chemistry and Technology, Faculty of Chemical Technology, University of Pardubice, Studentská 573, Pardubice CZ-532 10, Czech Republic

^h Department of Chemistry, Faculty of Science, Alexandria University, P.O. Box 426, Ibrahimia, Alexandria 21321, Egypt

ⁱ Faculty of Chemistry, Institute of Materials Chemistry, Brno University of Technology, Technicka 3058/10, 616 00 Brno, Czech Republic

ARTICLE INFO

Article history:

Received 31 March 2016

Received in revised form 2 May 2016

Accepted 5 May 2016

Available online 10 May 2016

Keywords:

Wound healing

Hyaluronan

Animal models

ABSTRACT

Recruitment of cells and mediators is altered during impaired wound healing, thereby delaying this process. To overcome this problem, the correlation of wound healing in older rats, and the impact of different molecular weight of hyaluronan without silver nanoparticles; (low-HA1), (High-HA2), (Medium- HA3) and with silver nanoparticles (High-HA4) is investigated. The superior HA were selected to be further investigated onto diabetic wounds. Our results pointed to a marked deficiency in wounds granulation in older rats, which was accompanied with impairment of healing process. In older rats group treated with HA2 or HA4, granulation and dermal construction were improved. Furthermore, the number of pathogenic bacteria on wounds was declined throughout the first 24 h by HA2 and HA4. The wound size in HA4-treated older rats was significantly smaller than that in other HA1, HA2 or HA3-treated older ones. Also, diabetes impaired the level of inflammatory cytokine, in diabetic model. On contrary, HA4 was found to normalize the level of inflammatory cytokine, in the diabetic model. Furthermore, HA4 was found to recover all oxidative and toxicity markers in diabetic models. This data confirms the critical role of HA4 to improve granulation and inflammatory mediators in impaired older and diabetic rat wound healing.

© 2016 Elsevier B.V. All rights reserved.

Abbreviations: GP, glutathione; MDA, malondialdehyde; ROS, reactive oxygen species; SOD, superoxide dismutase; INF- γ , interferon gamma; PMN, polymorphonuclear cells.

* Corresponding author at: Chemistry Dept., College of Science, King Saud University, P.O. Box 2455, Riyadh 11451, Saudi Arabia.

** Corresponding author at: CEITEC-Central European Institute of Technology, Brno University of Technology, Technicka, Brno 3058/10, Czech Republic.

*** Corresponding author at: Department of Zoology, College of Science, King Saud University, P.O. Box 2455, 11451 Riyadh, Saudi Arabia.

E-mail addresses: m.gaballa@yahoo.com (M.M.G. Fouda),

abdel-mohsen@ceitec.vutbr.cz, abdo.mohsenncr@yahoo.com

(A.M. Abdel-Mohsen), hossamebaid@yahoo.com (H. Ebaid).

¹ These authors contribute equally to this work.

1. Introduction

Despite the great clinical efforts, impaired wound healing is still a medical challenge with daily increasing of its health complications. Thus, studies of how aging [1,2] and diabetes effects wound healing have become a research priority. The cell migration, fibroblastic differentiation, collagen remodeling, and proliferation are decreased in impaired healing. This may be attributed not only to cellular defects but also to changes in mediators associated with the senescence [3] and diabetic process.

A combination of various factors comprising hormonal parameter, free oxygen radicals and impaired angiogenesis seems to be the reason of postponed cutaneous healing in elderly [4]. Anti-age agents seemed to assist wound healing by decreasing inflammation

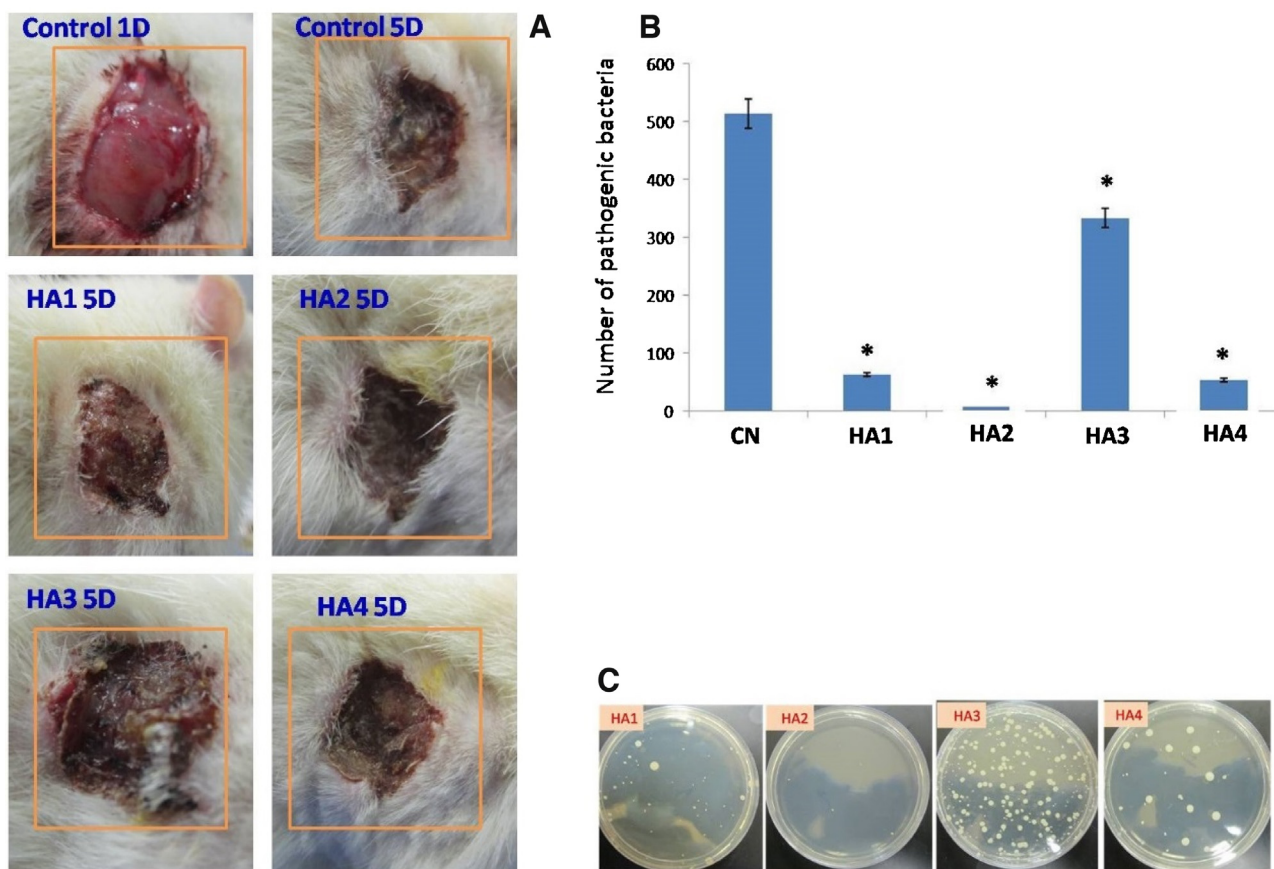


Fig. 1. A: Representative external photographs of full thickness skin wounds in control untreated and different treated groups. Photographs were taken from different rat groups two weeks post-wounding (Wound was rectangle, 10 × 20 mm). This figure shows that the wound size becomes smaller in groups II–IV in comparison to the control wound size or the group I wound size. B: The total count of the pathogenic bacteria grown on the full thickness wounded skin from older untreated (Control) and treated rats. Full thickness skin samples were taken from different rat groups one day post-wounding (Wound was rectangle, 10 × 20 mm). Values shown are means ± SD. *Shows the significance in comparison with the control group. C: Agar bacterial culture from different groups.

and stimulating the recovery process [5]. TGF- β is potentially used for the treatment of wound injuries, including ulcers in the elderly [6].

The wound healing process in diabetic patients can be adversely affected by several elements, comprising unrelieved pressure, infection, and concurrent underlying conditions. Sodium aescinate [7], whey proteins [8,9], chromogenic acid [10] and many other natural products may effectively control and improve wound healing in diabetic rats via its anti-inflammatory and antioxidant activities.

Recently, silver nanoparticles (AgNPs) have gained a great deal of interest among researchers in different area of applications such as textiles [11–16], biomedicine [17], medicine and pharmaceuticals. Several green methods of AgNPs preparation such as chemical reduction methods have been reported [17–21].

The treatment of impaired wounds involves the use of biomaterials that can deliver mechanical and biological lines to the surrounding environment [22]. Haluronan (HA) is a straight forward chain glycosaminoglycan polymer consisting of repeating entities of disaccharide and is found in vertebrates [23] and human body, comprising skin and soft tissue [24]. Due to the impact on signaling pathways, HA plays a significant role in wound-healing process [25]. According to Antonella et al. [26], the molecular weight of hyaluronan plays a significant rule in the wound repair process *in vitro*, however, there is no any *in vivo* study in the literature till now focusing on the effect of molecular weights of hyaluronan with and without silver nanoparticles. Also, in this previous study [26], the author(s) claims that, higher molecular weight of HA can accumulate and binds fibrinogen that is essen-

tial for clot formation. Therefore, in our study, the investigation of the effect of different molecular weights of HA with and without silver nanoparticles could be effective factor to study *in-vivo*. The use of hyaluronan leads to better proliferation of granulation tissue as well as epithelialization with respect to wound healing diabetic conditions in rats [27]. Many recent studies investigated the impact of HA either single or in combination with different compounds on wound healing process [28–31]. To the best of our knowledge, there is no such comparative study, *In-vivo*, of molecular weights of nanocomposite (hyaluronan/silver nanoparticles) on the healing of diabetic ulceration. Therefore, for the 1st time, the impact of four different preparations from HA and its combination with silver nanoparticles on impaired wound healing in old and diabetic models are tested and evaluated.

2. Materials and methods

Different molecular weights of hyaluronan (low, medium, high molecular weight) was used, kindly provided by Sigea S.r.L., Trieste (Italy). Milli-Q water was used for all experiments. All chemicals were used before further purification.

2.1. Preparation of hyaluronic acid solution with and without silver nanoparticles

1% of different molecular weight of hyaluronan was dissolved in Milli-Q water under stirring at room temperature and marked as low molecular weight hyaluronan(LHA1), High molecular

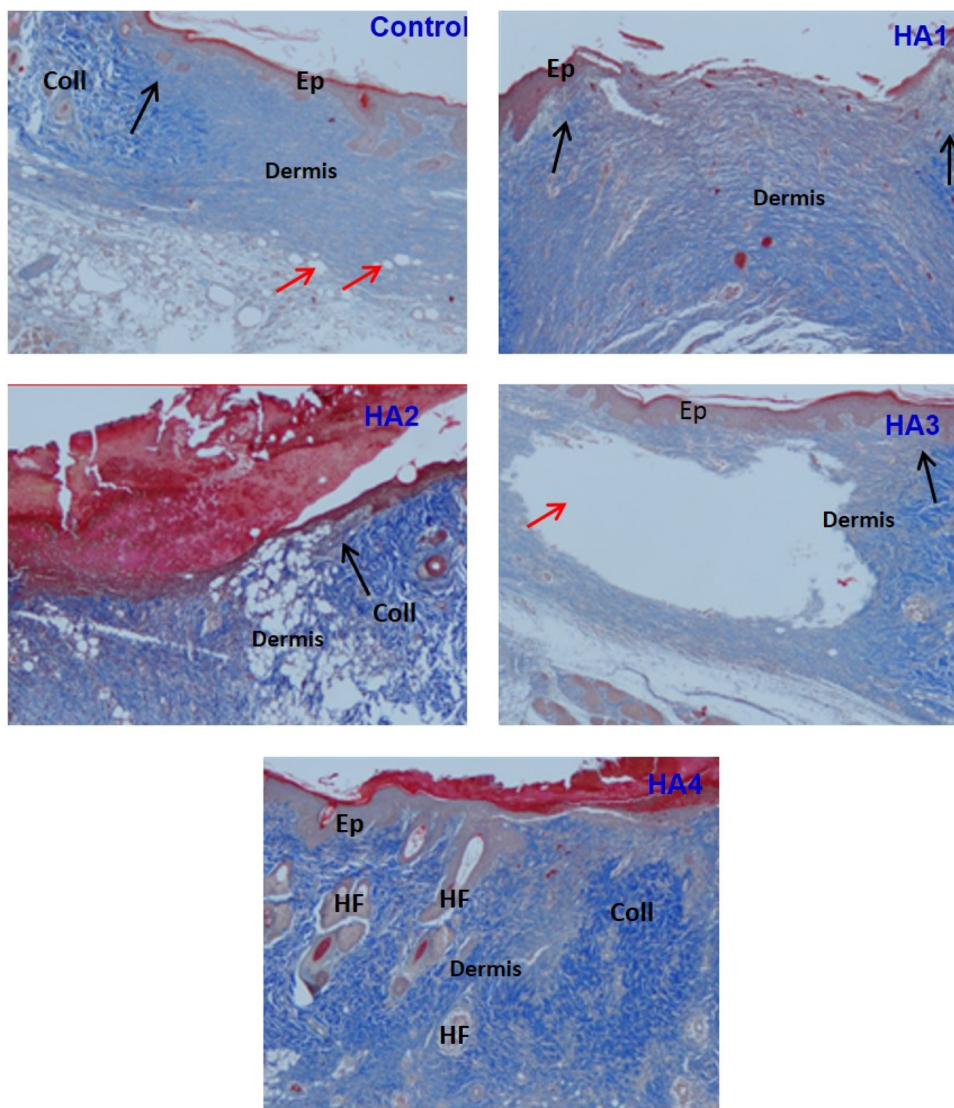


Fig. 2. Representative Masson Trichrome staining of full thickness wounded skin from older untreated (Control) and treated rats (group HA1-HA4) (X 100). Full thickness skin samples were taken from different rat groups two weeks post-wounding (Wound was rectangle, 10×20 mm). Epidermal cells (Ep); Collagen fibers (Coll); Epidermal tongues (black arrows); Bubbles (red arrows); Hair follicles (HF).

weight hyaluronan (HHA2), medium molecular weight hyaluronan (MHA3) and high hyaluronan/silver nanoparticles composite (HHA4/AgNPs).

2.2. Preparation of silver/hyaluronan nanoparticles composite

Silver nanoparticles were synthesized according to previous work with small modification [32,33]. High molecular weight hyaluronan was dissolved in Milli-Q water at room temperature with 1% concentration, then 1 ml of 10 mM of silver nitrate was added drop-wise into hyaluronic solution, the pH of the solution was raised until 7–8 with sodium hydroxide (1 M) and the reaction mixture was kept under stirring for 1 h at room temperature until the solution color converted from colorless to yellowish color indicated silver nanoparticles were obtained. The formation of silver nanoparticles was characterized by using UV–vis spectrophotometer, where a sharp significant peak appeared at 420 nm which is corresponding to the silver nanoparticles. Also, TEM was used to measure the size and size distribution of silver nanoparticles formed (the size of AgNPs was 100 nm), (data not shown).

2.3. Experimental design

Two experiments were performed to test the current lab prepared compounds. In the first experiment, about 40 older male rats were divided into 5 equal groups ($n = 8$). Wounds were performed in all rats in equal sizes to facilitate effect comparison of the four prepared compounds. The first group was remained as a control group. The remained four groups, each of them locally received one of four compounds on the cutaneous wound daily for 7 days. Because their superior effects on wound healing of older rats, compounds 2 and 4 were selected to be tested in the second experiments on the diabetic rat model. In the second experiment, about 40 male rats were divided into 5 equal groups ($n = 8$). The first group was remained as control un-wounded, while the second group was wounded control. The three other groups were diabetic rats; one of them was wounded and the two groups were wounded and locally received compound 2 and compound 4, respectively.

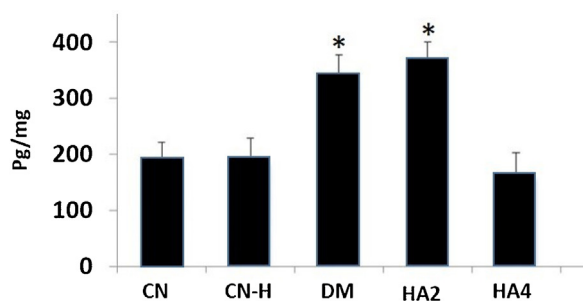


Fig. 3. The level of interferon gamma in the different treated groups. Values shown are means \pm SD. *Shows the significance in comparison with the control group.

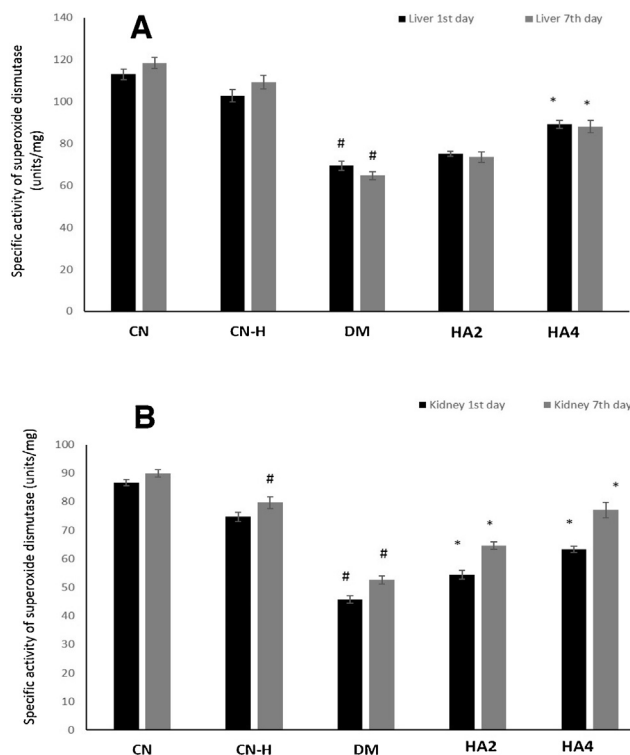


Fig. 4. The level of Superoxide dismutase in liver (A) and kidney (B) tissues from different groups. Values shown are means \pm SD. #Shows the significance in comparison with the control group. *Shows the significance in comparison with the diabetic group.

2.4. Ethical approval

“This work did not comprise endangered or protected species”. “With respect to the experimental animals, all processes were accompanied in accordance with the standards regular forth explored in guidelines for the care and use of experimental animals by the Committee for the Purpose of Control and Supervision of Experiments on Animals and the National Institutes of Health”. “The working protocol (care and handling of experimental animals) was permitted by the Animal Ethics Committee of the Zoology Department at King Saud University, College of Science”.

2.5. Excisional wound preparation

“All Rats were subjected to anesthetize, and the rate back was smooth-shaven and disinfected by ethyl alcohol”. “The wound cell removal exemplary model which is used in this test was executed as previously designated by Schwentker [34] with minor variation”. The clean-shaven skin was subjected to pinched followed by

tucked, and the wound was punched throughout the full thickness of the tucked skin to give 5 mm diameter circle under the shoulder blades of each rat.

2.6. Total bacterial count

The total bacterial count of the injured surface in rats were measured by using the viable cell counting method [35] by passing the sterilized cotton swap on the injured surface and putting the swap in 10 ml physiological rangers solution. The solution was vortexed with the swap. Appropriate dilutions were prepared and plated using the pour plate method with nutrient agar. The plates were incubated aerobically at 37 °C for 48 h.

2.7. Diabetic models

Diabetes was prompted by a single dose of newly dissolved STZ (50 mg/kg of body weight; Sigma, USA) in a 0.1 mol/l citrate buffer (pH 4.5) into the peritoneum. Control group rats were injected with citrate buffer. After seven days of STZ dose, rats were carefully chosen for serum glucose levels. Rats with a serum glucose level \geq 200 mg/dl after 2 h of glucose absorption were deemed as diabetic and designated for further studies.

2.8. ELISA estimation of INF- γ

The INF- γ level in serum of investigational groups was calculated using specific ELISA kits bought from Abcam, USA. The concentration of INF- γ was determined using a spectrophotometer at 450 nm according to the manufacturers' instructions.

2.9. Histological studies

All rats were subjected to euthanizing overdose of isoflurane. Tissue sections were collected from the wound locations in order to evaluate the wound zone. In order to identify the collagen deposition in the dermal tissues, Mallory Trichrome stain was carefully applied. The tissue damage degree was inspected blindly via a Leica DMRB/E light microscope (Heerbrug, Switzerland). Sections images were taken, followed by digitalization using Adobe Photoshop (Adobe Systems, Mountain View, CA). Wounds were detached from four rats of each handling group, just two days after being wounding by cutting a square area that comprised the whole wound site. The gathered tissues were instantly kept in a solution of formaldehyde; 10%, in phosphate-buttered saline, then washed using PBS, dehydrated in series of alcohol dilutions and inserted in paraffin. Microtome segments were cut vertically thru the wound site and adhered to slides prior to staining.

2.10. Statistics

The statistical study was accomplished by means of MINITAB software (MINITAB, State College, PA, Version 13.1, 2002). All obtained numbers were normally disseminated with uniform alterations. Consequently, one-way ANOVA statistical was utilized to define the whole influence of each treatment. This test was complemented by individual comparison between the different treatments using Tukey's method for pairwise comparisons. The results were expressed as mean (M) \pm standard deviation (SD). Only statistically significant changes with $P < 0.05$ were found between the treatment and the control group, and between the treatment and the older or diabetic group considered.

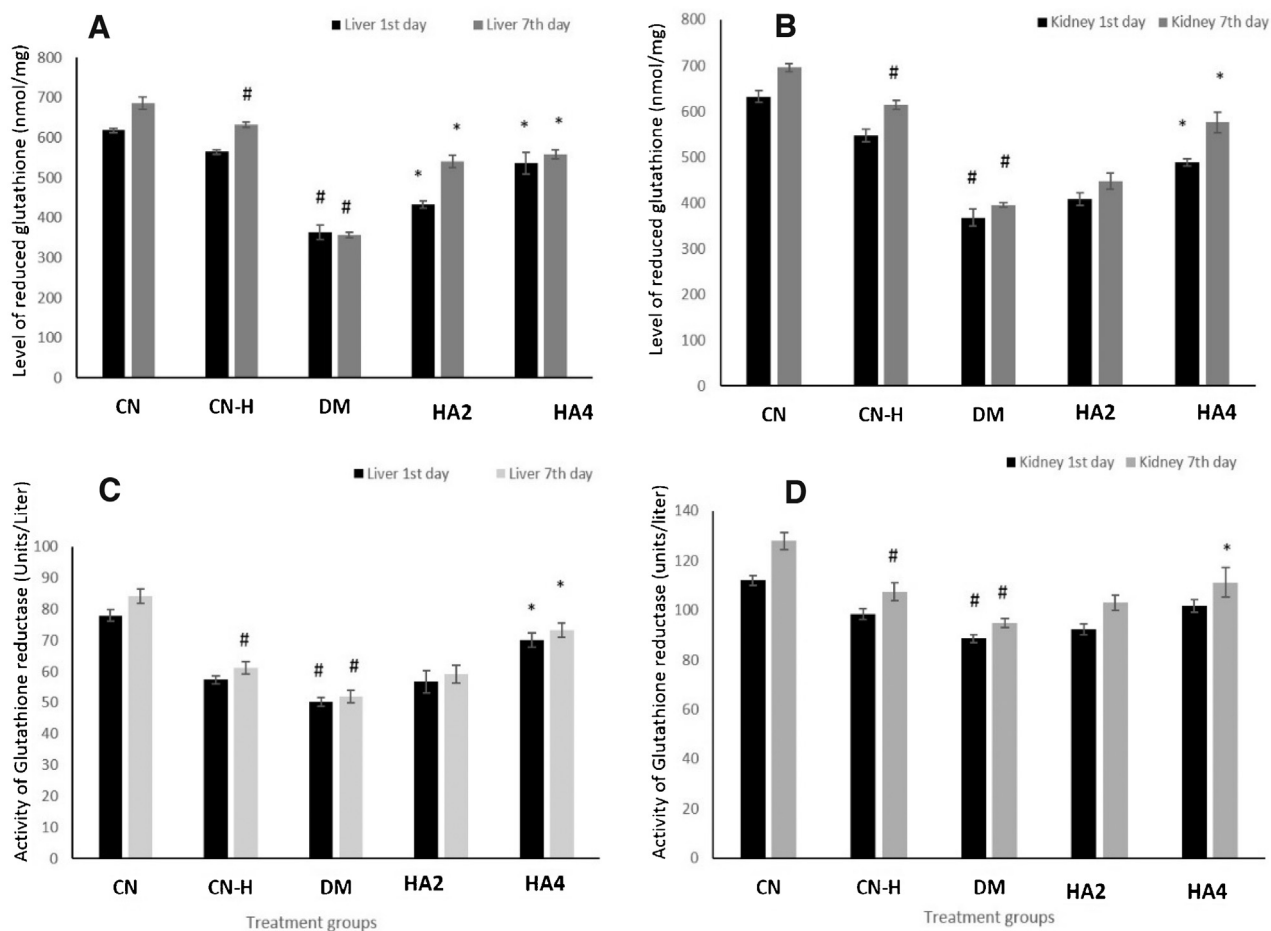


Fig. 5. The level of reduced glutathione (A,B) and glutathione reductase (C,D) in both liver and kidney tissues from different groups. Values shown are means \pm SD. #Shows the significance in comparison with the control group. *Shows the significance in comparison with the diabetic group.

3. Results

3.1. Effects of the four HA compounds on old models

3.1.1. External variations in the wound morphology

External variations in the morphology of wound were observed daily during the investigational period. The percentage of older rats displaying wound closure was significantly lesser than that of the control rats. HA4 was found to retrieve the wound closure rate in the older rats to a comparable level to that of the young rats (Fig. 1A).

To observe the improvement of wound healing, morphometric signals were assessed at two day intervals. The size of the wound opening was significantly greater in sections from older rats in contrast to those from the younger rats. The wound opening of older rats complemented with HA4 was gradually minimized, nevertheless, to become totally closed by the eighth day after wounding. Moreover, the number of new blood vessels and the depth of the dermal tissue in the wounded area were significantly decreased in older rats in comparison to the younger ones, but HA4 was found to significantly stimulate angiogenesis and the assembly of dermal constituents (Fig. 1A).

3.1.2. Inhibition of Pathogenic bacteria

We detected the quantitative changes of the bacterial load in wounded tissues over time. As shown in Fig. 1(b,c), HA2 and HA4 were found to significantly inhibit the pathogenic bacteria-growing in the wound sites throughout the experimental time in comparison

to the control non-treated rats. Although, HA1 and HA3 were found to significantly inhibit the pathogenic bacteria growing in the wound sites, they failed to completely suppress this bacterial growing comparing to HA2 and HA4 (Fig. 1b,c).

3.1.3. Histological changes in the wound region

The epidermal cells covered the wounded region and the collagen fibers started to invade the dermal tissue of the control rats. However, some bubbles were noticed in numerous slides from the control rats signifying a slow healing. In HA1 rats, the two epidermal tongues were obviously appeared. In HA2 rats, the epidermal migration under the immature scar was normally extended with some few bubbles. The dermis was very disturbed in the sections from HA3 group. Interestingly, the collagen fibers were fully distinguished and well symmetrically distributed under the new epidermal tissue with mature scar in HA4 group. Noteworthy, is the formation and proliferation of the hair follicles which designate a well dermal contraction and normal repair in comparison to the control group (Fig. 2).

3.2. Effects of the two selected HA (HA2 and HA4) compounds on diabetic models

This part of the study was dedicated to discourse the effect HA2 and HA4 in the diabetes-induced rats. As inflammatory cytokines and oxidative stress are of the major contributive factors in pathogenesis and progression of the disease, so assessment of INF- γ and

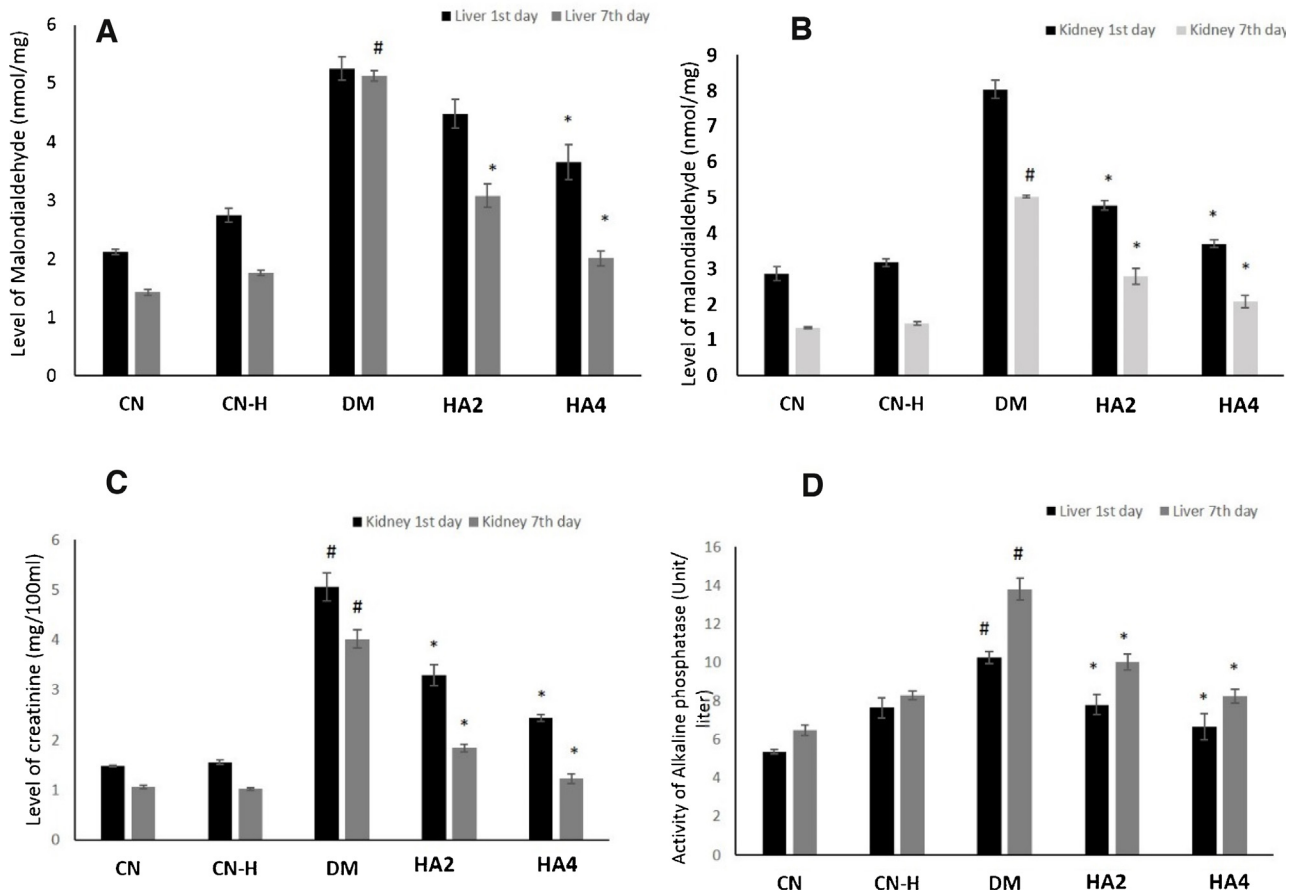


Fig. 6. The level of MDA (A,B), creatinine (C) and alkaline phosphatase (D) in both liver and kidney tissues from different groups. Values shown are means \pm SD. #Shows the significance in comparison with the control group. *Shows the significance in comparison with the diabetic group.

oxidative stress markers was the main motto of this section of the study.

3.2.1. Effect of HA2 and HA4 on the level of interferon gamma

Interferon gamma as an inflammatory cytokine was estimated after 24 h of wounding. Diabetes was found to significantly elevate the concentration of interferon gamma in comparison to the control healthy rats. On the other hand, the compound HA4 was found to obviously normalize its level in the diabetic rats. This means that HA4 stopped the elevation of inflammatory cytokines to permit the subsequent normal healing phases (Fig. 3).

3.2.2. Effect of HA2 and HA4 on antioxidant enzymes and proteins of diabetic rats

3.2.2.1. Superoxide dismutase (SOD). Liver: After 1st day of the treatment, group DM showed a decline in the specific activity of SOD by 38.55% while the CN-H demonstrated merely 8.96% of decrease as compared to the control. Among the combination groups, HA2 and HA4 exhibited an increase in its activity by 8.35% and 28.44% with respect to the group DM. After 7th day of the treatment, the animals showed similar but stronger pattern. DM group demonstrated a decrease in its activity by 45.35% while HA2 and HA4 showed an increase by 13.67% and 35.94% respectively as compared to group DM (Fig. 4A).

Kidney: After 1st day of the treatment, DM group showed a dip in its activity by 47.19% whereas HA2 and HA4 demonstrated a rise in its activity by 18.75% and 38.28% in the same sequence. After 7th day of the treatment, the decline in DM group was found to

be 41.39% while the group- HA2 and HA4 showed an increase by 22.78% and 46.35% with respect to the DM group (Fig. 4B).

3.2.2.2. Reduced glutathione (GSH). Liver: After 1st day of the treatment, DM group showed decrease in GSH level by 41.29% while HA2 and HA4 demonstrated replenishment in its level by 19.34% and 47.50% as compared to the DM group. After 7th day of the treatment, the dip in its level in DM group rose to 47.97% while HA2 and HA4 showed recovery in its level by 26.25% and 56.41% with respect to the DM group (Fig. 5A).

Kidney: After 1st day of the treatment, GSH level was found to be compromised by 41.83% in DM group as compared to the control whereas HA2 and HA4 demonstrated replenishment in its activity by 10.99% and 32.69%. After 7th day of the treatment, its level was decreased by 43.23% in the group DM whereas its level was found to be increased by 13.45% and 45.85% in HA2 and HA4 groups with respect to the DM group (Fig. 5B).

3.2.2.3. Glutathione reductase activity (GR). Liver: After 1st day of the treatment, GR activity was decreased by 35.41% and 26.40% in the DM and CN-H groups. The combination groups, HA2 and HA4 showed the increase by 12.84% and 39.35% as compared to the DM group. After 7th day of the treatment, the activity of GR was decreased by 38.41% and 27.35% in DM and CN-H groups respectively while its activity was observed to be improved by 14.04% and 40.86% in HA2 and HA4 groups respectively (Fig. 5C).

Kidney: After 1st day of the treatment, DM group showed a decrease in its activity by 20.90% followed by 12.15% in CN-H group. HA2 and HA4 groups demonstrated an increase in its activity by 4.19% and 14.79% respectively as compared to the DM. After 7th

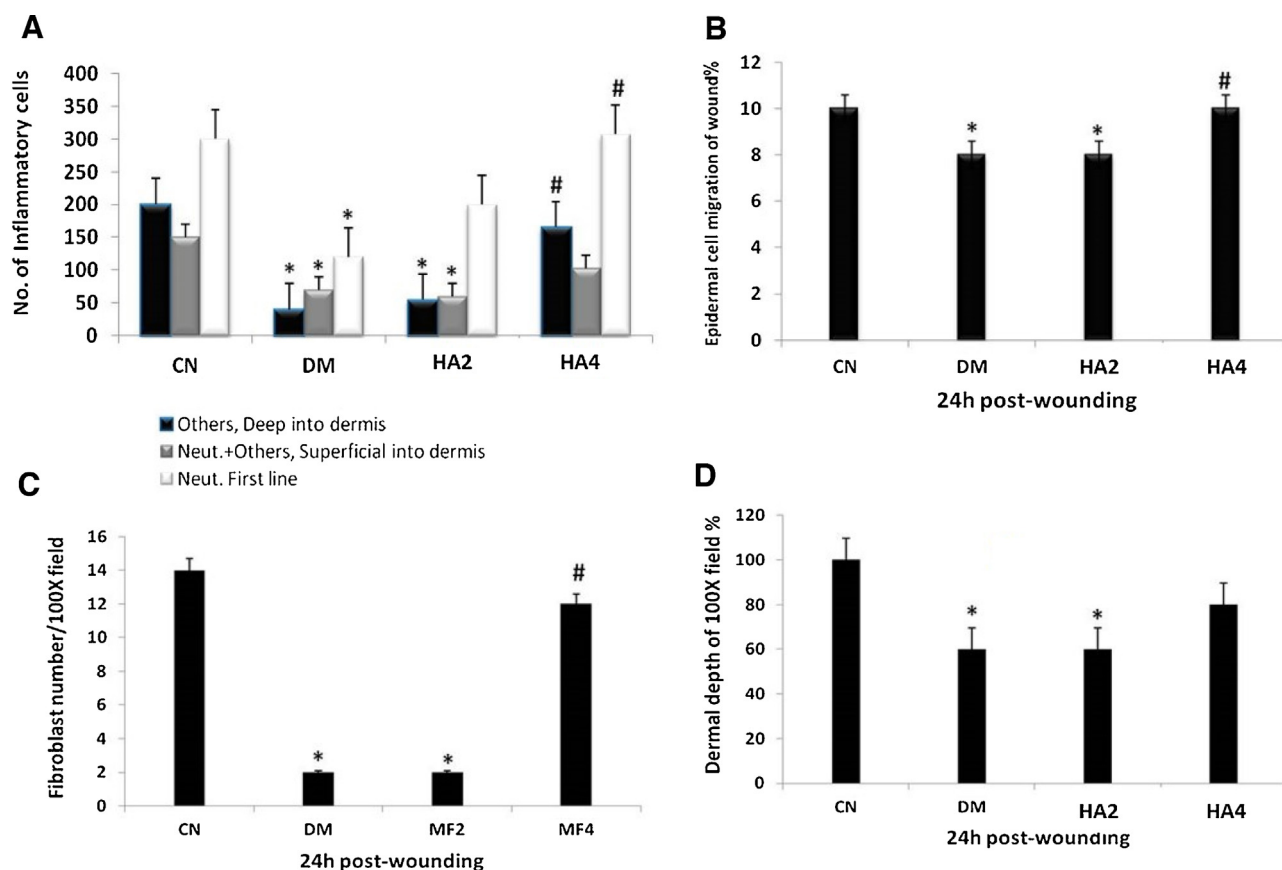


Fig. 7. Histological events one day post-wounding in different groups. A: The number of inflammatory cells (neutrophils in the first wound line, neutrophils and other cells in the superficial line of the damaged dermis and inflammatory cells deep in the damaged dermis) in the wound region. B: The epidermal migration distance (epidermal tongue) from the old epidermal periphery in relation to the wound size. C: The mean of fibroblast number read in the 100× field for each group. D: The dermal depth in relation to the diameter of 100× field. Values shown are means ± SD. *Shows the significance in comparison with the control group. # shows the significance in comparison with the diabetic group.

day of the treatment, DM group exhibited 25.94% of decline followed by 16.04% in the group CN-H while HA2 and HA4 showed the increase in its activity by 8.63% and 17.30% in the same sequence with respect to the DM group (Fig. 5D).

3.2.3. Effect of HA2 and HA4 on toxicity markers of diabetic rats

3.2.3.1. Malondialdehyde (MDA) level. Liver: After 1st day of the treatment, DM showed enhancement in the level of MDA by 147.64% followed by 29.24% in CN-H group by as compared to the control. Among the combination groups, HA2 and HA4 demonstrated a decrease in its level by 14.66% and 30.47% respectively. After 7th day of the treatment, DM demonstrated an increase in its level by 258.74% followed by 23.07% in CN-H group. However, HA2 and HA4 groups showed decrease in its level by 39.96% and 60.81% respectively (Fig. 6A).

Kidney: After 1st day of the treatment, DM group showed enhanced the level of MDA by 181.11% followed by 11.18% in CN-H group. HA2 and HA4 groups demonstrated the decrease in its level by 40.54% and 53.98% respectively. After 7th day of the treatment, DM group showed an increase in MDA level by 275% followed by 9.7% in case of CN-H group. However, HA2 and HA4 groups displayed a decrease in its level by 44% and 60% respectively as compared to the DM group (Fig. 6B).

3.2.3.2. Creatinine level. Creatinine is considered as one of the most reliable renal function marker. Its level, after 1st day of the treatment, was found to be raised by 241.89% in DM group while CN-H showed only 4.72% of increment in the kidney samples as compared

to the control. However, HA2 and HA4 showed decrease in its level by 34.78% and 51.77% in respective kidney samples. After 7th day of the treatment, its level rose to 294.11% and 3.77% in DM and CN-H groups respectively. Hitherto, HA2 and HA4 groups showed a marked decrease in its level by 38.04% and 58.58% with respect to the DM group (Fig. 6C).

3.2.3.3. Alkaline phosphatase (ALP) activity. ALP is one of most important liver function markers to assess toxic burden on the liver. In the present study, after 1st day of the treatment, its activity was raised by 42.64% and 90.87% in CN-H and DM groups respectively as compared to the control. However, groups HA2 and HA4 showed decrease in its activity by 23.80% and 34.82% with respect to the DM group. After 7th day of the treatment, DM group showed 112.80% of enhanced activity of ALP followed by 28.08% in CN-H group. However, the combination groups, HA2 and HA4 showed decrease in its activity by 27.19% and 40.17% respectively as compared to the DM group (Fig. 6D).

3.2.4. Effect of HA2 and HA4 on the histological morphometric indices

Our histological outcomes pointed to a marked deficiency in the number of neutrophils in the wounds of diabetic rats, which was complemented with impairment of the healing process. In the group of diabetic rats, inflammatory cell number in the dermal region, declined throughout the first 24 h after wounding. Both the neutrophil number and the inflammatory cell number in the dermal region recovered in diabetic rats, which received

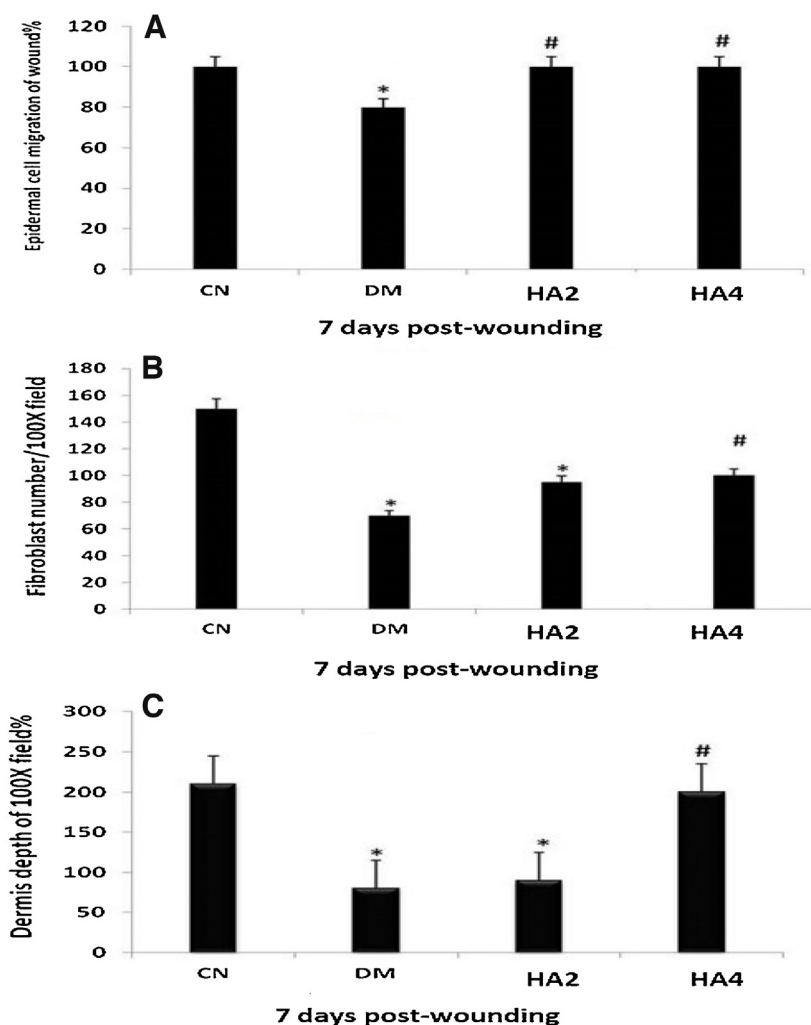


Fig. 8. Histological events seven days post-wounding in different groups. A: The epidermal migration distance (epidermal tongue) from the old epidermal periphery in relation to the wound size. B: The mean of fibroblast number in the 100× field for each group. D: The dermal depth in relation to the diameter of 100× field. Values shown are means ± SD. *Shows the significance in comparison with the control group. #Shows the significance in comparison with the diabetic group.

HA4 supplementation (Fig. 7A). Interestingly, HA4 was found to significantly recover the epidermal cell migration to the normal one (Fig. 7B). It was observed that fibroblast number was recovered in the HA4 rats (Fig. 7C). Furthermore the dermal depth was normalized by HA4 (Fig. 7D).

After seven days of wounding, the epidermal migration (Fig. 8A), the fibroblast number (Fig. 8B) and the dermal depth (Fig. 8C) were recovered in the HA4 rats. Thus, the wound size in diabetic rats treated with HA4 was significantly lower than that in diabetic ones.

4. Discussion

While it is known that recruitment of cells and mediators is altered during impaired wound healing, thereby delaying this process [1,36], little is performed to find a potential compound to outcome this problem. Recently HA was intensively applied in order to solve the impaired wound healing. Bioactivity of HA-based nanofibrous scaffolds was able to release growth factors that can activate wound healing [37] and HA was beneficial in treating diabetic foot [5] and markedly improved skin mechanical properties [38]. HA derivatives increase the healing progression in burns, epithelial surgical wounds, and chronic wounds [24]. The combination of HA, Col and EGF stimulated cell activity comprising cell migration and proliferation on the adipose tissue in a dia-

betic wound [39]. Here we investigated the impact of four newly prepared compounds from hyaluronic acid on the wound healing events in an older rat model. The high molecular weight of HA (HA2) and its combination with silver nanoparticles (HA4) were found to accelerate the wound healing process in older rat model. Silver nanoparticles also can accelerate the healing process in diabetic/non diabetic rates [32,33,40]. Combination of HA with silver nanoparticles (HA4) was superior on HA2 in the diabetic model.

This part of the study is dedicated to investigate the ameliorative potential of hyaluronic acid (HA2) and its combination with silver nanoparticles (HA4) in the Diabetes Miletus (DM) induced rats. The DM group clearly showed how most of the oxidative stress marker enzymes (SOD and GR) and the proteins (GSH) were significantly compromised concomitant with elevated level of MDA and organ function markers (ALP and creatinine) in the present study. This pattern of redox status clearly suggests that oxidative stress plays a central role in the pathogenesis of Diabetes Miletus. Interestingly, the pattern was found consistent in the DM group animals on the 1st day as well as on the 7th day after the diabetes induction. Moreover, the extent of oxidative stress mediated perturbation was found exacerbated in diabetes induced rats after one week of the induction. All these observations prove that oxidative stress is one of the major causative factors in progression and advancement of the disease that might be attributive involved in

severing of the sufferings of the diabetic patients [41,42]. Furthermore, the behavior of major organ toxicity markers (creatinine and alkaline phosphatase) indicate that the kidney is the target organ in DM group whereas the liver was found target organ in control hurt (CN-H) group. Intriguingly, hyaluronic acid was found as a very efficient antioxidant which further improved with silver nanoparticles in the diabetic induced rats. Both the treatment groups- HA2 and HA4 demonstrated significant restoration of the normal redox status after their single dose on day 1 and this further improved in most of the oxidative parameters on the 7th day of consecutive dosing. The present investigation clearly entails that hyaluronic acid has a significant dose dependent antioxidant and antidiabetic activity that further improves with silver nanoparticles.

It is well established that diabetes mellitus is a metabolic disorder whose pathogenesis and progression are based on altered redox status *in vivo* [43–46]. This notion is well presented by this section of work showing significantly elevated redox and toxicity markers in the diabetic rats that were found to be normalized by hyaluronic acid and its combination silver nanoparticles in dose and time dependent manner.

The liver is considered as a central immunological organ of the whole organism [47,48]. In the CN-H group that was hurt without any treatment, was showing more alteration most of the redox and toxicity markers in the liver sample as compared to their kidney samples. However, in diabetic rats, the kidney becomes the central target with respect to the liver. The constant high glucose concentration in diabetic induced rats put exert extra burden on the glomerular filtration in the kidneys. Besides, the glycation of key biomolecules and cellular components compromise the activity of many enzymes and key protein including the antioxidant enzymes and reduced glutathione and sulfhydryl groups [36,44]. This might be the reason for kidneys being more targeted in DM as compared to the liver. It is well known that hyaluronic acid is an effective antioxidant natural compound that occurs in various types of tissues including epithelial and epidermal cells in living organisms [49,50]. It acts as an important constituting agent as well as an immune-modulator that are important requisites in wound-healing and tissue repair mechanism [51]. Furthermore, silver nanoparticles have been documented for their antioxidant, anti-inflammatory and immune stimulant properties that make them an excellent promising drug delivery system [52,53]. These contemporary studies clearly support our findings that the antioxidant and anti-diabetic properties of hyaluronic acid increases many folds if co-administered with silver nanoparticles. These nanoparticles have the ability to enter into the cytoplasmic vicinities that enhance bioavailability of the drugs in the target organs that consequently improve the overall pharmacodynamics, efficacy and safety profile of the proposed drug.

Conclusions

This data confirms the critical role of HA4 to improve granulation and inflammatory mediators in impaired older and diabetic rat wound healing.

Competing interests

The author declares that there to be no competing interests.

Acknowledgements

This research was carried out under the project CEITEC 2020 (LQ1601) with financial support from the Ministry of Education, Youth and Sports of the Czech Republic under the National Sustainability Programme II. The authors thank the Deanship of Scientific

Research at King Saud University for funding this work through Prolific Research Group Program (PRG-1437-33; Saudi Arabia).

References

- [1] H. Ebaid, Neutrophil depletion in the early inflammatory phase delayed cutaneous wound healing in older rats: improvements due to the use of un-denatured camel whey protein, *Diagn. Pathol.* 9 (46) (2014), 1746–1596.
- [2] D.J. Kim, T. Mustoe, R.A. Clark, Cutaneous wound healing in aging small mammals: a systematic review, *Wound Repair Regen.* 23 (3) (2015) 318–339.
- [3] C.S. de Melo Rambo, J.A. Silva Jr., A.J. Serra, A.P. Ligeiro, R.P. Vieira, R. Albertini, E.C. Leal-Junior, P. de Tarso Camillo de Carvalho, Comparative analysis of low-level laser therapy (660 nm) on inflammatory biomarker expression during the skin wound-repair process in young and aged rats, *Lasers Med. Sci.* 29 (5) (2014) 1723–1733.
- [4] O.C. Soybir, S.O. Gurdal, E.S. Oran, F. Tulubas, M. Yuksel, A.I. Akyildiz, A. Bilir, G.R. Soybir, Delayed cutaneous wound healing in aged rats compared to younger ones, *Int. Wound J.* 9 (5) (2012) 478–487.
- [5] P.C. Chang, S.C. Tsai, Y.H. Jheng, Y.F. Lin, C.C. Chen, Soft-tissue wound healing by anti-advanced glycation end-products agents, *J. Dent. Res.* 93 (4) (2014) 388–393.
- [6] D.A. Cox, S. Kunz, N. Cerletti, G.K. McMaster, R.R. Burk, Wound healing in aged animals—effects of locally applied transforming growth factor beta 2 in different model systems, *EXS* 61 (1992) 287–295.
- [7] Z. Zhang, G. Cao, L. Sha, D. Wang, M. Liu, The efficacy of sodium aescinate on cutaneous wound healing in diabetic rats, *Inflammation* 38 (5) (2015) 1942–1948.
- [8] H. Ebaid, K. Hassanein, M. El-Feki, The undenatured whey protein enhanced wound healing in mice, *J. Egyptian German Soc. Zool.* 47 (2005) 267–287.
- [9] H. Ebaid, S.A. Bhandary, I.M. Alhazza, A. Rady, S. El-Shehry, Folic acid and melatonin ameliorate carbon tetrachloride-induced hepatic injury, oxidative stress and inflammation in rats, *Nutr. Metab.* 10 (1) (2013) 1743–17075.
- [10] D. Bagdas, B.C. Etoz, Z. Gul, M.O. Ozyigit, N. Kinkilic, S. Inan, N.I. Buyukcokun, K. Ozluk, M.S. Gurun, Chlorogenic acid enhances abdominal skin flap survival based on epigastric artery in nondiabetic and diabetic rats, *Ann. Plast. Surg.* (2014).
- [11] A.S. Aly, A.M. Abdel-Mohsen, A. Hebeish, Innovative multifinishing using chitosan-O-PEG graft copolymer/citric acid aqueous system for preparation of medical textiles, *J. Text. Inst.* 101 (1) (2010) 76–90.
- [12] A. Hebeish, M.E. El-Naggar, M.M.G. Fouda, M.A. Ramadan, S.S. Al-Deyab, M.H. El-Rafie, Highly effective antibacterial textiles containing green synthesized silver nanoparticles, *Carbohydr. Polym.* 86 (2) (2011) 936–940.
- [13] M.M.G. Fouda, H.M. Fahmy, Multifunctional finish and cotton cellulose fabric, *Carbohydr. Polym.* 86 (2) (2011) 625–629.
- [14] M.H. El-Rafie, M.E. El-Naggar, M.A. Ramadan, M.M.G. Fouda, S.S. Al-Deyab, A. Hebeish, Environmental synthesis of silver nanoparticles using hydroxypropyl starch and their characterization, *Carbohydr. Polym.* 86 (2) (2011) 630–635.
- [15] A.M. Abdel-Mohsen, A.S. Aly, R. Hrdina, A.S. Montaser, A. Hebeish, Biomedical textiles through multifunctionalization of cotton fabrics using innovative methoxypolyethylene glycol-N-chitosan graft copolymer, *J. Polymer. Environ.* 20 (1) (2011) 104–116.
- [16] R.M. Abdel-Rahman, A.M. Abdel-Mohsen, M.M.G. Fouda, S.S. Al Deyab, A.S. Mohamed, Finishing of cellulosic fabrics with chitosan/polyethylene glycol-siloxane to improve their performance and antibacterial properties, *Life Sci. J.* 10 (4) (2013) 834–839.
- [17] M.M.G. Fouda, M.R. El-Aassar, G.F. El Fawal, E.E. Hafez, S.H.D. Masry, A. Abdel-Megeed, K-Carrageenan/poly vinyl pyrrolidone/polyethylene glycol/silver nanoparticles film for biomedical application, *Int. J. Biol. Macromol.* 74 (2015) 179–184.
- [18] T. Textor, M.M.G. Fouda, B. Mahltig, Deposition of durable thin silver layers onto polyamides employing a heterogeneous Tollens' reaction, *Appl. Surf. Sci.* 256 (8) (2010) 2337–2342.
- [19] A.M. Abdel-Mohsen, A.S. Aly, R. Hrdina, A.T. El-Aref, A novel method for the preparation of silver/chitosan-O-methoxy polyethylene glycol core shell nanoparticles, *J. Polym. Environ.* 20 (2) (2011) 459–468.
- [20] A.M. Abdel-Mohsen, R.M. Abdel-Rahman, R. Hrdina, A. Imramovský, L. Burgert, A.S. Aly, Antibacterial cotton fabrics treated with core-shell nanoparticles, *Int. J. Biol. Macromol.* 50 (5) (2012) 1245–1253.
- [21] M.E. El-Naggar, T.I. Shaheen, M.M.G. Fouda, A.A. Hebeish, Eco-friendly microwave-assisted green and rapid synthesis of well-stabilized gold and core-shell silver-gold nanoparticles, *Carbohydr. Polym.* 136 (2016) 1128–1136.
- [22] T. Tokatlian, C. Cam, T. Segura, Porous hyaluronic acid hydrogels for localized nonviral DNA delivery in a diabetic wound healing model, *Adv. Healthc. Mater.* 4 (7) (2015) 1084–1091.
- [23] N. Ievdokimova, [Hyaluronic acid, receptor CD44, and their role in diabetic complications], *Ukrains'kyi biokhimichnyi zhurnal* 80 (5) (2008) 5–44.
- [24] J. Voigt, V.R. Driver, Hyaluronic acid derivatives and their healing effect on burns, epithelial surgical wounds, and chronic wounds: a systematic review and meta-analysis of randomized controlled trials, *Wound Repair Regen.* 20 (3) (2012) 317–331.
- [25] G. Weindl, M. Schaller, M. Schafer-Korting, H.C. Korting, Hyaluronic acid in the treatment and prevention of skin diseases: molecular biological, pharmaceutical and clinical aspects, *Skin Pharmacol. Physiol.* 17 (5) (2004) 207–213.

- [26] A. D'Agostino, A. Stellavato, T. Busico, A. Papa, V. Tirino, G. Papaccio, A. La Gatta, M. De Rosa, C. Schiraldi, In vitro analysis of the effects on wound healing of high- and low-molecular weight chains of hyaluronan and their hybrid H-HA/L-HA complexes, *BMC Cell Biol.* 16 (1) (2015) 1–15.
- [27] I. Siebenschuh, F. Rosken, M. Koschnick, H. Rakers, K.E. Arfors, W. Mutschler, M.D. Menger, [Local administration of hyaluronic acid for improving wound healing in diabetes], *Langenbecks Arch. Chir. Suppl. Kongressbd.* 115 (Suppl. I) (1998) 467–468.
- [28] B.S. Anisha, R. Biswas, K.P. Chennazhi, R. Jayakumar, Chitosan-hyaluronic acid/nano silver composite sponges for drug resistant bacteria infected diabetic wounds, *Int. J. Biol. Macromol.* 62 (2013) 310–320.
- [29] J.F. Kirk, G. Ritter, I. Finger, D. Sankar, J.D. Reddy, J.D. Talton, C. Nataraj, S. Narisawa, J.L. Millan, R.R. Cobb, Mechanical and biocompatible characterization of a cross-linked collagen-hyaluronic acid wound dressing, *Biomater* 3 (4) (2013) 29.
- [30] H.J. You, S.K. Han, J.W. Rhie, Randomised controlled clinical trial for autologous fibroblast-hyaluronic acid complex in treating diabetic foot ulcers, *J. Wound Care* 23 (11) (2014) 521–522.
- [31] I. Eroglu, E.H. Gokce, N. Tsapis, S.T. Tanriverdi, G. Gokce, E. Fattal, O. Ozer, Evaluation of characteristics and in vitro antioxidant properties of RSV loaded hyaluronic acid-DPPC microparticles as a wound healing system, *Colloids Surf. B Biointerfaces* 126 (2015) 50–57.
- [32] A.M. Abdel-Mohsen, R. Hrdina, L. Burgert, G. Krylová, R.M. Abdel-Rahman, A. Krejčová, M. Steinhart, L. Beneš, Green synthesis of hyaluronan fibers with silver nanoparticles, *Carbohydr. Polym.* 89 (2) (2012) 411–422.
- [33] A.M. Abdel-Mohsen, R. Hrdina, L. Burgert, R.M. Abdel-Rahman, M. Hašová, D. Šmejkalová, M. Kolář, M. Pekar, A.S. Aly, Antibacterial activity and cell viability of hyaluronan fiber with silver nanoparticles, *Carbohydr. Polym.* 2 (2013) 1177–1187.
- [34] A. Schwentker, Y. Vodovotz, R. Weller, T.R. Billiar, Nitric oxide and wound repair: role of cytokines? *Nitric Oxide* 7 (1) (2002) 1–10.
- [35] A.M. Abdelgawad, S.M. Hudson, O.J. Rojas, Antimicrobial wound dressing nanofiber mats from multicomponent (chitosan/silver-NPs/polyvinyl alcohol) systems, *Carbohydr. Polym.* 100 (2014) 166–178.
- [36] H. Ebaid, Promotion of immune and glycaemic functions in streptozotocin-induced diabetic rats treated with un-denatured camel milk whey proteins, *Nutr. Metab.* 11 (31) (2014) 1743–1755.
- [37] Z. Wang, Y. Qian, L. Li, L. Pan, L.W. Njunge, L. Dong, L. Yang, Evaluation of emulsion electrospun polycaprolactone/hyaluronan/epidermal growth factor nanofibrous scaffolds for wound healing, *J. Biomater. Appl.* 26 (2015), 0885328215586907.
- [38] M. Galeano, F. Polito, A. Bitto, N. Irrera, G.M. Campo, A. Avenoso, M. Calo, P. Lo Cascio, L. Minutoli, M. Barone, F. Squadrito, D. Altavilla, Systemic administration of high-molecular weight hyaluronan stimulates wound healing in genetically diabetic mice, *Biochim. Biophys. Acta* 7 (2011) 752–759.
- [39] S. Kondo, H. Niiyama, A. Yu, Y. Kuroyanagi, Evaluation of a wound dressing composed of hyaluronic acid and collagen sponge containing epidermal growth factor in diabetic mice, *J. Biomater. Sci. Polym. Ed.* 23 (13) (2012) 1729–1740.
- [40] A.M. Abdel-Mohsen, R.M. Abdel-Rahman, M.M.G. Fouda, L. Vojtova, L. Uhrova, A.F. Hassan, S.S. Al-Deyab, I.E. El-Shamy, J. Jancar, Preparation, characterization and cytotoxicity of schizophyllan/silver nanoparticle composite, *Carbohydr. Polym.* 102 (1) (2014) 238–245.
- [41] A.C. Maritim, R.A. Sanders, J.B. Watkins 3rd., Diabetes, oxidative stress, and antioxidants: a review, *J. Biochem. Mol. Toxicol.* 17 (1) (2003) 24–38.
- [42] T.V. Fiorentino, A. Priolella, P. Zuo, F. Folli, Hyperglycemia-induced oxidative stress and its role in diabetes mellitus related cardiovascular diseases, *Curr. Pharm. Des.* 19 (32) (2013) 5695–5703.
- [43] M.M. Alam, D. Meerza, I. Naseem, Protective effect of quercetin on hyperglycemia, oxidative stress and DNA damage in alloxan induced type 2 diabetic mice, *Life Sci.* 109 (1) (2014) 8–14.
- [44] D. Meerza, I. Naseem, J. Ahmed, Effect of 1, 25(OH)(2) vitamin D(3) on glucose homeostasis and DNA damage in type 2 diabetic mice, *J. Diabet. Complications* 26 (5) (2012) 363–368.
- [45] I. Hassan, S. Chibber, I. Naseem, Ameliorative effect of riboflavin on the cisplatin induced nephrotoxicity and hepatotoxicity under photoillumination, *Food Chem. Toxicol.* 48 (8–9) (2010) 2052–2058.
- [46] I. Hassan, S. Chibber, I. Naseem, Vitamin B(2): a promising adjuvant in cisplatin based chemoradiotherapy by cellular redox management, *Food Chem. Toxicol.* 59 (2013) 715–723.
- [47] C.N. Jenne, P. Kubes, Immune surveillance by the liver, *Nat. Immunol.* 14 (10) (2013) 996–1006.
- [48] V. Racanelli, B. Rehermann, The liver as an immunological organ, *Hepatology* 43 (2 Suppl. 1) (2006) S54–62.
- [49] C. Ke, L. Sun, D. Qiao, D. Wang, X. Zeng, Antioxidant activity of low molecular weight hyaluronic acid, *Food Chem. Toxicol.* 49 (10) (2011) 2670–2675.
- [50] G.M. Campo, A. Avenoso, S. Campo, A.M. Ferlazzo, A. Calatroni, Administration of hyaluronic acid and chondroitin-4-sulfate limits endogenous antioxidant depletion and reduces cell damage in experimental acute pancreatitis, *Pancreas* 28 (2) (2004) E45–53.
- [51] M. Prosdoci, C. Bevilacqua, Impaired wound healing in diabetes: the rationale for clinical use of hyaluronic acid plus silver sulfadiazine, *Minerva Med.* 103 (6) (2012) 533–539.
- [52] R. Cortivo, V. Vindigni, L. Iacobellis, G. Abatangelo, P. Pinton, B. Zavan, Nanoscale particle therapies for wounds and ulcers, *Nanomedicine* 5 (4) (2010) 641–656.
- [53] L. Ge, Q. Li, M. Wang, J. Ouyang, X. Li, M.M.Q. Xing, Nanosilver particles in medical applications: synthesis, performance, and toxicity, *Int. J. Nanomed.* 9 (2014) 2399–2407.