

Hend M. Alharbi
Nadir Babay
Hamad Alzoman
Sumaya Basudan
Sukumaran Anil
John A. Jansen

Bone morphology changes around two types of bone-level implants installed in fresh extraction sockets – a histomorphometric study in Beagle dogs

Authors' affiliations:

Hend M. Alharbi, Nadir Babay, Hamad Alzoman, Sukumaran Anil, Department of Periodontics and Community Dentistry, College of Dentistry, King Saud University, Riyadh, Saudi Arabia
Sumaya Basudan, Endodontics Division, Restorative Dental Department, College of Dentistry, King Saud University, Riyadh, Saudi Arabia

John A. Jansen, Department of Biomaterials, Radboud University Medical Center, Nijmegen, The Netherlands

John A. Jansen, Dental Implant and Osseointegration Research Chair (DIORC), College of Dentistry, King Saud University, Riyadh, Saudi Arabia

Corresponding author:

John A. Jansen, DDS, PhD
Radboudumc, Department of Biomaterials (309)
PO Box 9101, 6500 HB Nijmegen
The Netherlands
Tel.: +31 24 3667305
Fax: +31 24 3614657
e-mail: John.Jansen@radboudumc.nl

Key words: bone level, bone preservation, implant design, microgap

Abstract

Background: Minimizing crestal bone loss following immediate implant placement is considered the most challenging aspect in implant therapy. Implant surface topography and chemical modifications have been shown to influence the success of Osseointegration. The Straumann® Bone Level implant, featuring SLActive surface, has been introduced with the aim of enhancing bone apposition. Similarly, the OsseoSpeed™ implants from Astra Tech claim to have an enhanced osseointegration. Because of the specific features in the implant design, both companies claim that crestal resorption is minimal with these implants.

Objective: To evaluate the osseointegration and crestal bone level following immediate placement of Straumann® Bone Level implant and OsseoSpeed™ implants in fresh extraction sockets in Beagle dogs.

Method: The distal roots of the second, third and fourth premolars were extracted in both sides of the mandible. The distal roots were removed using a dental elevator. A total of 60 fixtures were installed in 10 Beagle dogs. Two types of implants were used: Straumann® Bone-Level implants, which were 8 × 3.3 mm in size, and Astra Tech OsseoSpeed™ 3.5 S MicroThread™ implants, which were 8 × 3.5 mm in size. The histomorphometrical evaluation was performed at the end of 4- and 12-week healing. The implant–bone contact and bone volume percentage were assessed.

Results: The bone-to-implant contact (BIC) and the bone volume did not show any significant changes for both types of implants. The OsseoSpeed™ implants showed 67.4% and 65.3% BIC, respectively, at 4 and 12 weeks compared with 71.7 and 73.1 for the Straumann® Bone-Level implants. The bone volume around both types of implants did not differ significantly at both time periods. The crestal bone resorption was observed for both types of implants. The first BIC at buccal side and lingual side of the implants also did not differ significantly for both implant systems.

Conclusions: This study showed that Straumann® Bone Level and OsseoSpeed™ implants induced similar bone response after immediate implantation at 4 and 12 weeks. The immediate implant placement resulted in peri-implant crestal bone-level changes for both types of implants.

Bone loss after tooth extraction remains an important issue in dentistry (Carlsson et al. 1967). It is well documented that tooth extraction is associated with dimensional changes in the alveolar ridge. Studies have reported that nearly two-thirds of the alveolar bone resorption occurs within the first 3 months following tooth extraction (Araujo & Lindhe 2005; Araujo et al. 2006; Nevins et al. 2006). Minimizing crestal bone loss following immediate implant placement is considered to be the most challenging aspect in implant therapy. The level of crestal bone loss is also considered as one of the criteria to assess implant osseointegration (Abrahamsson & Berglundh 2009).

Immediate implant placement after tooth extraction seems to offer several advantages when compared to the traditional approaches (Quirynen et al. 2007). Immediate placement of dental implants after tooth extraction showed reduction in the alveolar bone resorption particularly on the buccal aspect of the alveolar process (Lazzara 1989; Araujo et al. 2005; Vignoletti et al. 2009; Covani et al. 2011). However, controversial results have also been reported. Experimental models have shown that the placement of an immediate implant in a fresh extraction site does not prevent post-extraction alveolar bone resorption (Araujo et al. 2005; Blanco et al. 2008; Al-Shabeeb et al. 2012; Hammerle et al. 2012).

Date:

Accepted 5 March 2014

To cite this article:

Alharbi HM, Babay N, Alzoman H, Basudan S, Anil S, Jansen JA. Bone morphology changes around two types of bone-level implants installed in fresh extraction sockets – a histomorphometric study in Beagle dogs. *Clin. Oral Impl. Res.* 26, 2015, 1106–1112
doi: 10.1111/clr.12388

Early osseointegration events are positively affected by implant surface topography and chemical modifications. Studies reported that moderately rough implant surfaces result in higher bone-to-implant contact (BIC) compared with machined surfaces (Buser et al. 1999; Cochran et al. 2002). Surface roughness has a positive influence on cell migration and proliferation, which in turn leads to better BIC, suggesting that the microstructure of the implant influences biomaterial–tissue interaction (Matsuo et al. 1999; Novaes et al. 2002). Implant systems with modified surface topographies have been introduced in the market during the last two decades. Straumann® Bone Level implant featuring SLActive surface has shown enhanced bone apposition (Buser et al. 2004; Zhao et al. 2005; Bornstein et al. 2008). The SLActive surface is created by coarse grit blasting, followed by acid etching. Short-term animal studies have shown better bone-to-implant contact with these types of implants (Ellingsen et al. 2004; Cooper et al. 2006; Berglundh et al. 2007; Abrahamsson et al. 2008). OsseoSpeed™ implants by Astra Tech also revealed a faster bone-healing response and increased BIC (Berglundh et al. 2007; Abrahamsson et al. 2008; Heitz-Mayfield et al. 2013).

In addition to the effect of implant surface microstructure on the final implant–bone response, studies have shown that biomechanical implant design features such as topography, surface features, stability of the implant and the abutment microgap influence the marginal bone changes (Mertens & Steveling 2011; Heitz-Mayfield et al. 2013). For example, specific features, such as microthreads in the crestal implant surface area, distribute the peak stress along the implant and have shown to preserve peri-implant bone (Hudieb et al. 2011).

Available data regarding the short-term and long-term healing and crestal bone changes in these modified implants are still limited. Hence, the objective of the study was to evaluate the osseointegration and crestal bone-level changes following immediate placement of Straumann® Bone Level and Astra Tech OsseoSpeed™ implants in fresh extraction sockets.

Material and methods

Animal model and surgical procedures

The animal study protocol was approved by the animal ethical committee of King Saud University, College of Dentistry, Riyadh, Saudi Arabia, and the national guidelines for care and use of laboratory animals were fol-

lowed. Ten healthy adult beagle dogs about 1–2 years of age were used for the study.

Root canal treatment

The dogs were premedicated using atropine 0.5 mg/kg to prevent excessive salivation and vomiting. Ketamine HCL Injection (Parke-Davis, Morris Plains, NJ, USA) (Ketamine 10% 8–10 mg/kg) intramuscularly (IM) and 1–3 mg/kg IM Rompun xylazine 2% (2 mg/kg) were used for general anesthesia. For local anesthesia, xylocaine® (30 mg of 2% lidocaine with 1 : 80,000 epinephrine) was injected at the site of the teeth to be extracted. Duphaphen strep B.P® (Pfizer SL, Alcobendas, Spain) (injectable preparation of streptomycin, 2 ml/kg) was given during the surgery and post-operatively.

The teeth in each quadrant were anesthetized with 1.8 ml of local anesthesia (2% xylocaine HCL with 1 : 80,000 epinephrine) (Xylocaine; Dentsply Pharmaceutical, York, PA, USA) using an infiltration technique, to reduce bleeding and to induce post-operative analgesia. For each dog, the mesial roots of the second, third and fourth premolars were treated endodontically on right and left sides of the mandible. The coronal pulp chambers were sealed with Light Cured Glass Ionomer Cement (GC Fuji II LC Capsule; GC Corporation, Tokyo, Japan). Post-operative radiographs were taken to assess the root canal sealing.

The distal roots of the second, third and fourth premolars were extracted in both sides of the mandible. These teeth were hemi-sectioned using a high-speed hand piece with a tungsten carbide bur (Caulk super bur, Dentsply, Milford, DE, USA) to separate the mesial and distal roots. The distal roots were removed using a dental elevator. Lower root dental extraction forceps were placed carefully on the crown to rotate the tooth and remove it from the alveolus.

Implant installation

A total of 60 fixtures were installed in 10 beagle dogs. Two types of implants were used: Straumann® Bone-Level implants, which were 8 × 3.3 mm in size, featuring

SLActive® surface with uniform thread design (The Straumann® Dental Implant System, Basel, Switzerland), Astra Tech OsseoSpeed™ 3.5 S MicroThread™ implants, which were 8 × 3.5 mm in size with microthread design at the coronal top of the implant (Astra Tech AB, Mölndal, Sweden).

Each dog received six dental implants; three fixtures of one implant system were placed in each side of the mandible. The two implant types were alternatingly installed in the left or right side of the mandible (Table 1). Fixture placement was performed under sterile conditions, using copious irrigation with sterile saline throughout the procedure. The surgical implant preparations of the Straumann® Bone Level and Astra Tech OsseoSpeed™ implants were performed according to the manufacturer's guidelines. All of the implants were placed at the level of the buccal bone crest. A cover screw was placed, and the cover screw was kept exposed above the gingival margin (Fig. 1). Periapical radiographs were taken for all of the implants after placement to check the implant position.

Following the surgery, a broad-spectrum antibiotic (clindamycin 4 mg/kg body weight) and ibuprofen 600 mg (three times a day) were administered intramuscularly for 7 days. The dogs were kept on a soft diet during the study period. The dogs were examined every week, to evaluate the healing of the surgical site and monitor any weight changes. None of the implants in the study were loaded. After 1 week, the animals were sedated for the second post-operative treatment. The surgical areas were swabbed with 0.12% chlorhexidine gluconate mouthwash, and sutures were removed. Radiographs were taken to assess the position of the implants.

Of the 10 dogs, five were euthanized after 4 weeks of healing and the remaining after 12 weeks. After the completion of the healing period, each animal was premedicated with a combination of Haloperidol (Haldol®; Janssen Pharmaceutica, Beerse, Belgium) and Fentanyl (Sublimaze®; Janssen Pharmaceuticals, Titusville, NJ, USA). Later, a lethal dose of

Table 1. Distribution implants in 10 dogs used in the study (three implants on each side)

Dog no.	Left side	Right side
1	Straumann® Bone Level	Astra Tech OsseoSpeed™
2	Straumann® Bone Level	Astra Tech OsseoSpeed™
3	Astra Tech OsseoSpeed™	Straumann® Bone Level
4	Straumann® Bone Level	Astra Tech OsseoSpeed™
5	Astra Tech OsseoSpeed™	Straumann® Bone Level
6	Astra Tech OsseoSpeed™	Straumann® Bone Level
7	Straumann® Bone Level	Astra Tech OsseoSpeed™
8	Astra Tech OsseoSpeed™	Straumann® Bone Level
9	Straumann® Bone Level	Astra Tech OsseoSpeed™
10	Astra Tech OsseoSpeed™	Straumann® Bone Level

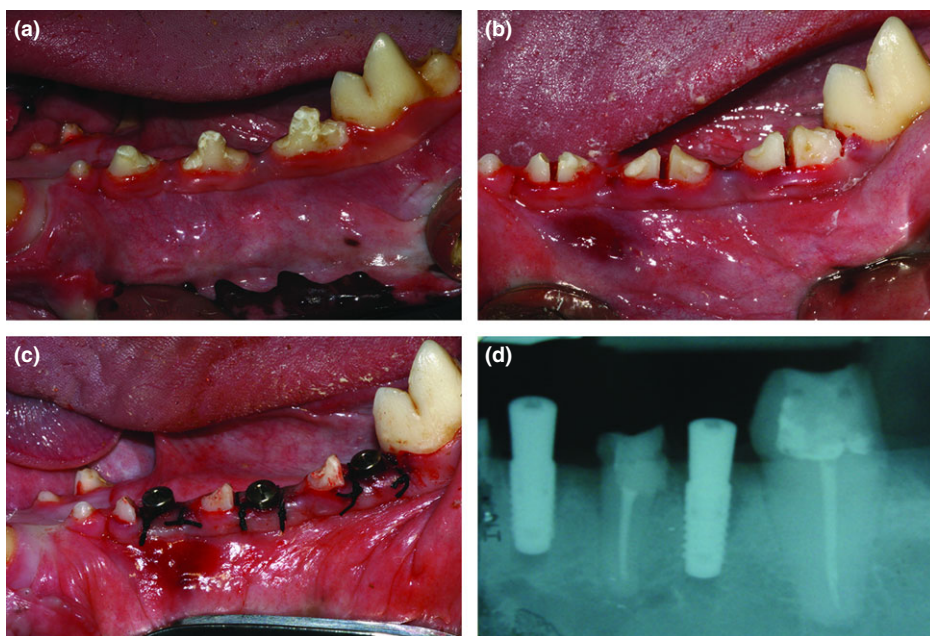


Fig. 1. The surgical procedure. (a) After root canal restoration. (b) Splitting of the tooth before extraction. (c) Implant installation. (d) Radiograph showing the implant in position.

Thiopental (Pentothal®, Pharmacia & Upjohn, Gurgaon, India) was injected intravenously under general anesthesia. The vascular system was perfused with physiologic saline, followed by 4% neutral formaldehyde as a fixative.

Histological preparation

After euthanasia, the mandibles were removed and put into fixative of 10% neutral buffered formalin solution. Radiographs were made in bucco-lingual direction to identify the exact implant position. All specimens were dehydrated in a graded series of ethanol (70–100%) and eventually embedded in methyl methacrylate (MMA). The sections (10–15 μm) were made in a bucco-lingual direction. All sections were stained with basic fuchsin and methylene blue and examined with a light microscope (Zeiss – Axio Imager Z1 automated microscope with AxioCam MRc5 digital camera and AxioVision V6.3.2. acquisition software, Göttingen, Germany).

Histological and histomorphometrical analysis

Histomorphometry was performed using digital image analysis software (Leica Qwin Pro-image; Leica Imaging Systems, Cambridge, UK).

Two quantitative parameters were assessed:
 a. Percentage of bone-to-implant contact (BIC%). Measurements were performed along the entire length of the implant. The amount of bone contact was defined as the percentage of implant length at which there is direct BIC without intervening soft tissue layers.

b. Percentage of the peri-implant bone area (BA%). The bone mass around the implant was analyzed in a rectangular region of interest (ROI-1000 μm).
 c. The linear distance from middle of the top of the implant to the first BIC was measured (in mm) for each implant. This was carried out on the buccal side and lingual side of the implant.

Statistical analysis

All measurements were statistically evaluated using GraphPad InStat, version 3.10 (GraphPad Software Inc. San Diego, CA,

USA). Mean values and standard deviations (SD) were calculated. The method of Kolmogorov and Smirnov was used to confirm that the data were sampled from populations that follow Gaussian distributions. For comparison of data, repeated measurements of one-way analysis of variance (ANOVA) were used with a Tukey's *post hoc* test. Additionally, unpaired *t*-tests were performed for each experimental group to determine differences between the two implantation periods (4 and 12 weeks). Differences were considered statistically significant at $P < 0.05$.

Results

General observations

All animals remained in good health during the experimental period and did not show any post-operative wound-healing complications. Radiographs taken after implant installation revealed the presence of a crestal microgap between the implant surface and the alveolar bone wall (Fig. 1). The soft tissues around the implants after 4 and 12 weeks did not show any sign of inflammation or adverse tissue reactions. Of the 60 implants placed, 55 implants were retrieved. Three Straumann® Bone Level and two OsseoSpeed™ dental implants were lost during the healing period.

Descriptive histological evaluation

Light microscopic examination demonstrated that generally all sections showed bone apposition and ingrowth of newly formed bone into the gap around the implants without any intervening layer of fibrous tissue (Fig. 2). Analysis of the histological sections




Fig. 2. First bone-to-implant contact at lingual and buccal areas.

after 4 weeks revealed an intimate contact between implant and surrounding bone (Fig. 2) for both experimental groups. The histological sections showed a noticeable difference in bone response and crestal bone loss pattern at buccal and lingual surfaces (Table 2). After 12 weeks, evidently bone ingrowth had increased for all implants compared with 4 weeks of implantation and compact lamellar bone filled most of the gap area (Figs 3 and 4). Bone ingrowth had also proceeded into close proximity of all the implant surfaces. Crestal bone loss was found around most of the implants in both groups.

Bone-to-implant contact

The BIC contact percentage is depicted in Fig. 5. The OsseoSpeed™ implants showed a BIC percentage of 67.4 ± 27.1 at 4 weeks and 65.3 ± 20.9 at 12-week healing, whereas the Straumann® Bone-Level implants had a BIC percentage of 71.7 ± 26.9 at 4 weeks and 73.1 ± 17.5 at 12 weeks. Even though the BIC of the Straumann® Bone-Level implants seemed higher than that of the OsseoSpeed™ implants, the difference was not statistically significant.

First bone-to-implant contact at buccal and lingual sides

The first BIC on the buccal and lingual sides was independently assessed at both sides of the histological sections. The measurements are shown in Table 2. There was no significant variation in the first BIC at both buccal and lingual of the two types of implants at both time intervals.

Bone volume percentage (BV)

The bone volume percentage for both implants in 4- and 12-week healing is shown in Fig. 6. Even though the bone volume showed an increase at 12 weeks of implantation, this difference was not statistically significant. There was also no significant difference in bone volume percentage between OsseoSpeed™ and Straumann® Bone-Level implants.

Discussion

The objective of the present study was to evaluate and compare the crestal bone-level

changes and the osseointegration of the Straumann® Bone Level and OsseoSpeed™ dental implant after 4 and 12 weeks of implantation. The evaluation was based on histological and histomorphometrical assessment. The implants used differed in wettability, surface chemistry and microthread configuration in the coronal region of the implant. All these surface characteristics can influence the final bone response (Junker et al. 2009). Further, it has to be noticed that in the current study, no negative control group (i.e., crestal bone alteration following tooth extraction without immediate implant installation) was included. This was done by purpose, as bone alterations following tooth extraction has been the topic of earlier investigation by another group at King Saud University (Al-Askar et al. 2013). A similar comment has to be made about the lack of a positive control (crestal bone alteration after immediate implant installation). This aspect of dental implant placement in dogs has already been reported by others (Kim et al. 2007; Al-Marshood et al. 2011). In addition, a comparison of all different effects of tissue-level implants on bone alterations is beyond the scope of this study and would require the use of a too high number of experimental animals.

The survival rate of implants in the current study was affected by the early failures of three Straumann® Bone Level (SLActive®) implants and two OsseoSpeed™ dental implants. Failures may be due to lack of primary stability, as it was noticed that the failed implants were already mobile at 4 weeks of implantation. It can be hypothesized that this loss of implants is due to the presence of a microgap (see radiograph as depicted in Fig. 1) as exists after immediate implant installation between the implant surface and the inner wall of the alveolar bone. As Beagle dogs are a very inbred type of animal, the anatomical differences between the various dogs are very limited. As a consequence, the width of the microgap had about the same dimensions for all installed implants. Therefore, we decided not to quantify the width of the microgap. Nevertheless, we cannot exclude that its presence in combination with bone damage due to root

extraction and implant drilling resulted in preliminary loss of implants.

The histological sections revealed significant loss of crestal bone around both types of implants following immediate implant installation. This is in agreement with earlier studies, which showed also marked bone alteration following immediate implant placement in fresh extraction site (Araujo et al. 2005; Blanco et al. 2011; Bonfante et al. 2013). Covani et al. (2011) demonstrated that immediate placement of dental implants into fresh extraction sockets helps reduce the rate of buccal bone resorption after tooth extraction. The results of this study contradict the findings of the current experiment. In the present study, the crestal bone level is found to be more at the buccal side than the lingual side. This is in agreement with several experimental and clinical studies that showed higher amounts of buccal bone resorption compared with resorption of the lingual bone plate following immediate implant placement in fresh extraction site (Araujo et al. 2005, 2006; Blanco et al. 2011; Bonfante et al. 2013).

Bone remodeling is a complex process in which old bone is removed by the process of resorption and is replaced by new bone. It has been suggested that, after tooth extraction, the blood vessels to the bone walls are severed, thereby causing bundle bone resorption (Araujo & Lindhe 2005). In the present study, marked hard tissue alterations occurred following tooth extraction and immediate implant placement at lingual and buccal bone crests. Araujo et al. (2005) and Blanco et al. (2011) reported that the placement of an implant in the fresh extraction site does not prevent alveolar bone remodeling that occurred in the walls of the sockets. Araujo et al. (2005) reported 2.5 mm of buccal bone resorption after 3 months of healing of immediately placed implants. The same observation was reported by Blanco et al. (2011) where the crestal bone resorption was more pronounced at the buccal aspect. Bonfante et al. (2013) compared buccal and lingual crestal bone alterations to implants with four type of surface treatment (anodized, discrete crystalline deposition, SLActive and microblasted) following immediate implantation. They observed more buccal bone loss between 2 and 4 weeks following implant placement with no significant difference in the mean crestal bone resorption between four implant systems. This observation is in agreement with the current study. The variation observed in the buccal crestal bone resorption between OsseoSpeed™ and

Table 2. The first BIC on the buccal and lingual sides of the implants at 4 and 12 weeks

Implant type	First BIC – buccal		First BIC – lingual	
	4 weeks	12 weeks	4 weeks	12 weeks
Astra Tech OsseoSpeed™	1.87 ± 1.43	1.25 ± 1.00	1.83 ± 1.46	1.54 ± 0.83
Straumann® Bone Level	1.02 ± 0.74	1.39 ± 1.01	1.84 ± 1.24	1.66 ± 0.79

BIC, bone-to-implant contact.

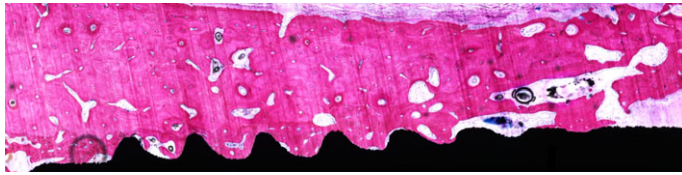


Fig. 3. Histological section of the Straumann® Bone Level implant. Note the dense bone around the implant. Bone loss at the crestal area can be seen (Objective 10×).

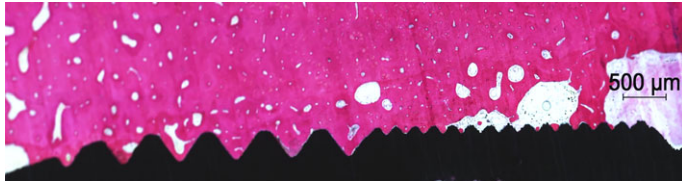


Fig. 4. Histological section of the OsseoSpeed™ implant. Dense bone is surrounding the implant. Note the bone loss at the crestal area (Objective 10×).

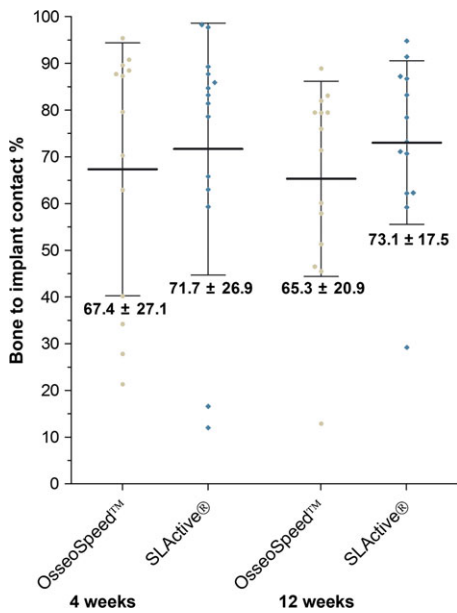


Fig. 5. The BIC percentage of both implants at 4-week healing and 12-week healing. BIC, Bone-to-implant contact.

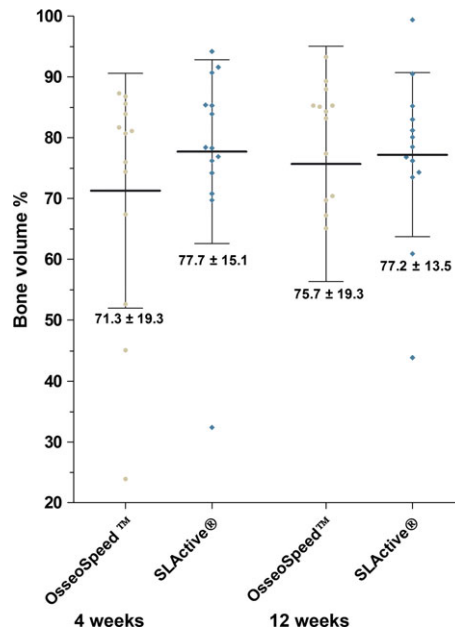


Fig. 6. The bone volume percentage of both implants at 4- and 12-week healing.

Straumann® Bone-Level implants at 4 weeks could be explained by the difference in the implant diameter (3.3 vs. 3.5 mm). The implant diameter and the socket size play a role in the marked crestal bone-level alterations (Botticelli et al. 2004; Vignoletti et al. 2009; Ferrus et al. 2010). Vignoletti et al. (2009) showed that with a 3.25 mm diameter implant, the amount of buccal bone resorption was significantly higher in the third premolar area in comparison with fourth premolar area. Moreover, Araujo et al. (2006), in a similar model using two different socket sizes, found more bone resorption in the socket of reduced diameter in comparison

with the larger one. The larger the horizontal gap, the greater the amount of newly formed bone (Botticelli et al. 2004; Ferrus et al. 2010).

This present investigation demonstrated that buccal crestal bone resorption is more pronounced around OsseoSpeed™ implants when compared to Straumann® Bone Level (SLActive®) implants at 4 weeks after immediate implantation. This could be attributed to the chemically modified SLA surface Straumann® Bone Level implant, which has an enhanced stabilization property of the blood clot (Schwarz et al. 2007, 2010), thereby stimulating the cellular processes of

the wound-healing cascade. We observed more crestal bone resorption at the lingual side than at the buccal crest for the OsseoSpeed™ and Straumann® Bone Level (SLActive®) implants at 12 weeks. The difference between the two implants was not statistically significant. SA similar finding was reported by Calvo-Guirado et al. (2010), where the amount of the buccal bone resorption was less pronounced than resorption of the lingual aspect. However, this observation regarding the lingual crestal bone resorption contradicts the findings of several other studies (Araujo & Lindhe 2005; Araujo et al. 2006; Blanco et al. 2011). Al-Shabeeb et al. (2012) reported that crestal bone remodeling is significantly more extensive around immediate implants placed in multiple tooth extraction sites compared with immediate implants placed in single tooth extraction sites. Emphasizing the importance of interdental blood supply to the buccal alveolar bone crest, this blood supply will be diminished in case of multiple contiguous teeth extractions. In the present study, the surgical protocol was similar to the procedure by Calvo-Guirado et al. (2010). The remaining mesial roots were preserved by elective root canal treatment, which might help to keep the interdental blood supply to the buccal bone crest.

Araujo et al. (2006) reported that the thinner the bone wall and closer the implant placed to this wall, the higher the risk of compromised healing and occurrence of bone dehiscence. This finding is in agreement with the present study. Also, it must be emphasized that the surgical trauma subsequent to the extraction plays important role in crestal bone resorption (Al-Shabeeb et al. 2012). The separation of the periosteum and its disconnection from the underlying bone surface will cause vascular damage and an acute inflammatory response, which in turn will mediate the resorption of the exposed bone surface (Wilderman 1963; Staffileno et al. 1966; Wood et al. 1972).

Histological examination of the 4-week histological sections showed that evidently both implant types stimulated coagulum formation between the gap as left between the implant surface and fresh extraction socket. Crestal bone resorption was evident at both healing periods with the two types of implants studied. Marginal gaps in the premolar areas between the implant and the socket walls, which were present at the time of implantation, disappeared as a result of newly formed bone filling. A study involving an immunohistochemical

analysis of the initial angiogenesis revealed that the organization of blood clots seemed to have been initiated within 24 h after implant placement (Schwarz et al. 2007). After a month, this coagulum had been replaced by newly formed, immature bone, which also made contact with the rough surface of the implant in the marginal gap region. This observation is in agreement with previously reported find-

ings (Berglundh et al. 2003; Araujo et al. 2005).

Evaluation of the BIC percentages demonstrated no significant difference between Straumann Bone level and OsseoSpeed™ implants at both healing periods. The amount of measured bone contact agrees with several other studies in which similar implant systems were used (Junker et al. 2009; Bonfante et al. 2013).

Conclusions

Within the limitations of this study, it can be concluded that both Straumann Bone Level and OsseoSpeed implants showed crestal bone loss after immediate implant placement in fresh extraction site in a dog model. Similar healing pattern was observed with both types of implants at 4- and 12-week healing.

References

- Abrahamsson, I., Albouy, J.P. & Berglundh, T. (2008) Healing at fluoride-modified implants placed in wide marginal defects: an experimental study in dogs. *Clinical Oral Implants Research* **19**: 153–159.
- Abrahamsson, I. & Berglundh, T. (2009) Effects of different implant surfaces and designs on marginal bone-level alterations: a review. *Clinical Oral Implants Research* **20**(Suppl. 4): 207–215.
- Al-Askar, M., O'Neill, R., Stark, P.C., Griffin, T., Javed, F. & Al-Hezaimi, K. (2013) Effect of single and contiguous teeth extractions on alveolar bone remodeling: a study in dogs. *Clinical Implant Dentistry & Related Research* **15**: 569–575.
- Al-Marshood, M. M., Junker, R., Al-Rasheed, A., Al Farraj Aldosari, A., Jansen, J. A. & Anil, S. (2011) Study of the osseointegration of dental implants placed with an adapted surgical technique. *Clinical Oral Implants Research* **22**: 753–759.
- Al-Shabeeb, M.S., Al-Askar, M., Al-Rasheed, A., Babay, N., Javed, F., Wang, H.L. & Al-Hezaimi, K. (2012) Alveolar bone remodeling around immediate implants placed in accordance with the extraction socket classification: a three-dimensional microcomputed tomography analysis. *Journal of Periodontology* **83**: 981–987.
- Araujo, M.G. & Lindhe, J. (2005) Dimensional ridge alterations following tooth extraction. An experimental study in the dog. *Journal of Clinical Periodontology* **32**: 212–218.
- Araujo, M.G., Sukekava, F., Wennstrom, J.L. & Lindhe, J. (2005) Ridge alterations following implant placement in fresh extraction sockets: an experimental study in the dog. *Journal of Clinical Periodontology* **32**: 645–652.
- Araujo, M.G., Wennstrom, J.L. & Lindhe, J. (2006) Modeling of the buccal and lingual bone walls of fresh extraction sites following implant installation. *Clinical Oral Implants Research* **17**: 606–614.
- Berglundh, T., Abrahamsson, I., Albouy, J.P. & Lindhe, J. (2007) Bone healing at implants with a fluoride-modified surface: an experimental study in dogs. *Clinical Oral Implants Research* **18**: 147–152.
- Berglundh, T., Abrahamsson, I., Lang, N.P. & Lindhe, J. (2003) De novo alveolar bone formation adjacent to endosseous implants. *Clinical Oral Implants Research* **14**: 251–262.
- Blanco, J., Linares, A., Perez, J. & Munoz, F. (2011) Ridge alterations following flapless immediate implant placement with or without immediate loading. Part II: a histometric study in the Beagle dog. *Journal of Clinical Periodontology* **38**: 762–770.
- Blanco, J., Nunez, V., Aracil, L., Munoz, F. & Ramos, I. (2008) Ridge alterations following immediate implant placement in the dog: flap versus flapless surgery. *Journal of Clinical Periodontology* **35**: 640–648.
- Bonfante, E.A., Janal, M.N., Granato, R., Marin, C., Suzuki, M., Tovar, N. & Coelho, P.G. (2013) Buccal and lingual bone level alterations after immediate implantation of four implant surfaces: a study in dogs. *Clinical Oral Implants Research* **24**: 1375–1380.
- Bornstein, M.M., Halbritter, S., Harnisch, H., Weber, H.P. & Buser, D. (2008) A retrospective analysis of patients referred for implant placement to a specialty clinic: indications, surgical procedures, and early failures. *The International Journal of Oral & Maxillofacial Implants* **23**: 1109–1116.
- Botticelli, D., Berglundh, T. & Lindhe, J. (2004) Hard-tissue alterations following immediate implant placement in extraction sites. *Journal of Clinical Periodontology* **31**: 820–828.
- Buser, D., Brogini, N., Wieland, M., Schenk, R.K., Denzer, A.J., Cochran, D.L., Hoffmann, B., Lussi, A. & Steinemann, S.G. (2004) Enhanced bone apposition to a chemically modified SLA titanium surface. *Journal of Dental Research* **83**: 529–533.
- Buser, D., Mericske-Stern, R., Dula, K. & Lang, N.P. (1999) Clinical experience with one-stage, non-submerged dental implants. *Advances in Dental Research* **13**: 153–161.
- Calvo-Guirado, J.L., Ortiz-Ruiz, A.J., Negri, B., Lopez-Mari, L., Rodriguez-Barba, C. & Schlottig, F. (2010) Histological and histomorphometric evaluation of immediate implant placement on a dog model with a new implant surface treatment. *Clinical Oral Implants Research* **21**: 308–315.
- Carlsson, G.E., Bergman, B. & Hedegard, B. (1967) Changes in contour of the maxillary alveolar process under immediate dentures. A longitudinal clinical and x-ray cephalometric study covering 5 years. *Acta odontologica Scandinavica* **25**: 45–75.
- Cochran, D.L., Buser, D., ten Bruggenkate, C.M., Weingart, D., Taylor, T.M., Bernard, J.P., Peters, F. & Simpson, J.P. (2002) The use of reduced healing times on ITI implants with a sandblasted and acid-etched (SLA) surface: early results from clinical trials on ITI SLA implants. *Clinical Oral Implants Research* **13**: 144–153.
- Cooper, L.F., Zhou, Y., Takebe, J., Guo, J., Abron, A., Holmen, A. & Ellingsen, J.E. (2006) Fluoride modification effects on osteoblast behavior and bone formation at TiO₂ grit-blasted c.p. titanium endosseous implants. *Biomaterials* **27**: 926–936.
- Covani, U., Ricci, M., Bozzolo, G., Mangano, F., Zini, A. & Barone, A. (2011) Analysis of the pattern of the alveolar ridge remodelling following single tooth extraction. *Clinical Oral Implants Research* **22**: 820–825.
- Ellingsen, J.E., Johansson, C.B., Wennerberg, A. & Holmen, A. (2004) Improved retention and bone-to-implant contact with fluoride-modified titanium implants. *The International Journal of Oral & Maxillofacial Implants* **19**: 659–666.
- Ferrus, J., Cecchinato, D., Pjetursson, E.B., Lang, N.P., Sanz, M. & Lindhe, J. (2010) Factors influencing ridge alterations following immediate implant placement into extraction sockets. *Clinical Oral Implants Research* **21**: 22–29.
- Hammerle, C.H., Araujo, M.G., Simion, M. & Osteology Consensus, G. (2012) Evidence-based knowledge on the biology and treatment of extraction sockets. *Clinical Oral Implants Research* **23**(Suppl. 5): 80–82.
- Heitz-Mayfield, L.J., Darby, I., Heitz, F. & Chen, S. (2013) Preservation of crestal bone by implant design. A comparative study in minipigs. *Clinical Oral Implants Research* **24**: 243–249.
- Hudieb, M.I., Wakabayashi, N. & Kasugai, S. (2011) Magnitude and direction of mechanical stress at the osseointegrated interface of the microthread implant. *Journal of Periodontology* **82**: 1061–1070.
- Junker, R., Dimakis, A., Thoneick, M. & Jansen, J.A. (2009) Effects of implant surface coatings and composition on bone integration: a systematic review. *Clinical Oral Implants Research* **20**(Suppl. 4): 185–206.
- Kim, J. H., Han, T. S., Cho, K., Kang, S. S., Kim, G. & Choi, S. H. (2007) Comparison of immediate and delayed implantation using the square-threaded and resorbable-blasted-media-treated surface implant system. *In vivo (Athens, Greece)* **21**: 55–59.
- Lazzara, R.J. (1989) Immediate implant placement into extraction sites: surgical and restorative

- advantages. *The International Journal of Periodontics & Restorative Dentistry* 9: 332–343.
- Matsuo, M., Nakamura, T., Kishi, Y. & Takahashi, K. (1999) Microvascular changes after placement of titanium implants: scanning electron microscopy observations of machined and titanium plasma-sprayed implants in dogs. *Journal of Periodontology* 70: 1330–1338.
- Mertens, C. & Steveling, H.G. (2011) Early and immediate loading of titanium implants with fluoride-modified surfaces: results of 5-year prospective study. *Clinical Oral Implants Research* 22: 1354–1360.
- Nevens, M., Camelo, M., De Paoli, S., Friedland, B., Schenk, R.K., Parma-Benfenati, S., Simion, M., Tinti, C. & Wagenberg, B. (2006) A study of the fate of the buccal wall of extraction sockets of teeth with prominent roots. *The International Journal of Periodontics & Restorative Dentistry* 26: 19–29.
- Novaes, A.B., Jr, Souza, S.L., de Oliveira, P.T. & Souza, A.M. (2002) Histomorphometric analysis of the bone-implant contact obtained with 4 different implant surface treatments placed side by side in the dog mandible. *The International Journal of Oral & Maxillofacial Implants* 17: 377–383.
- Quirynen, M., Van Assche, N., Botticelli, D. & Berglundh, T. (2007) How does the timing of implant placement to extraction affect outcome? *The International Journal of Oral & Maxillofacial Implants* 22(Suppl.): 203–223.
- Schwarz, F., Herten, M., Sager, M., Wieland, M., Dard, M. & Becker, J. (2007) Bone regeneration in dehiscence-type defects at chemically modified (SLActive) and conventional SLA titanium implants: a pilot study in dogs. *Journal of Clinical Periodontology* 34: 78–86.
- Schwarz, F., Sager, M., Kadelka, I., Ferrari, D. & Becker, J. (2010) Influence of titanium implant surface characteristics on bone regeneration in dehiscence-type defects: an experimental study in dogs. *Journal of Clinical Periodontology* 37: 466–473.
- Staffileno, H., Levy, S. & Gargiulo, A. (1966) Histologic study of cellular mobilization and repair following a periosteal retention operation via split thickness mucogingival flap surgery. *Journal of Periodontology* 37: 117–131.
- Vignoletti, F., de Sanctis, M., Berglundh, T., Abrahamsson, I. & Sanz, M. (2009) Early healing of implants placed into fresh extraction sockets: an experimental study in the beagle dog. II: ridge alterations. *Journal of Clinical Periodontology* 36: 688–697.
- Wilderman, M. (1963) Repair after a periosteal retention procedure. *Journal of Periodontology* 34: 487–503.
- Wood, D.L., Hoag, P.M., Donnenfeld, O.W. & Rosenfeld, L.D. (1972) Alveolar crest reduction following full and partial thickness flaps. *Journal of Periodontology* 43: 141–144.
- Zhao, G., Schwartz, Z., Wieland, M., Rupp, F., Geis-Gerstorfer, J., Cochran, D.L. & Boyan, B.D. (2005) High surface energy enhances cell response to titanium substrate microstructure. *Journal of Biomedical Materials Research. Part A* 74: 49–58.