

# Revised, Computed Tomography–Based Lekholm and Zarb Jawbone Quality Classification

Asma'a A. Al-Ekrish, BDS, MDS, Cert Diag Sci<sup>1</sup>/Gerlig Widmann, MD, EBIR<sup>2</sup>/  
Sara A. Alfadda, BDS, MSc, PhD, FRCD(C)<sup>3</sup>

**Purpose:** To propose a revised Lekholm and Zarb classification that takes into account all possible combinations of compact and trabecular bone and to provide guidelines for increased reproducibility of the classification. **Materials and Methods:** Three new classes were added to the previous classification. The new classes have been designated as subclasses of bone types 2 and 3, as follows: Type 2b: Thick layer of compact bone surrounding a core of medium-density trabecular bone; Type 2c: Thick layer of compact bone surrounding a core of low-density trabecular bone; and Type 3b: Thin layer of compact bone surrounding a core of medium-density trabecular bone. Three interpretation guidelines were recommended to increase the reproducibility of the revised classification. Three experienced examiners were trained using the revised classification and provided with computed tomography (CT) sectional images of edentulous jawbones for classification. Each examiner classified the images twice with at least a 1-week interval. The intra-observer agreement was measured. **Results:** The kappa statistic for the intra-observer agreement of the examiners ranged from 0.835 to 0.919 ( $P < .001$ ). **Conclusion:** The high reproducibility of the proposed revised CT-based Lekholm and Zarb classification obtained in the current study suggests its efficacy in distinguishing between the various combinations of compact and trabecular bone. *Int J Prosthodont* 2018;31:342–345. doi: 10.11607/ijp.5714

The Lekholm and Zarb (L&Z) radiographic bone quality and quantity classification<sup>1</sup> is often used for the preliminary assessment of potential dental implant host sites.<sup>2</sup> Bone density is commonly classified into the following four types on the basis of the amount of cortical and trabecular bone assessed radiographically:

- Type 1: Entirely homogenous compact bone
- Type 2: Thick layer of compact bone surrounding a core of dense trabecular bone
- Type 3: Thin layer of compact bone surrounding a core of dense trabecular bone
- Type 4: Thin layer of compact bone surrounding a core of low-density trabecular bone

Bone quality assessed by tactile sensation on the basis of the L&Z classification during osteotomies for the placement of dental implants was shown to be reproducible<sup>3,4</sup> and significantly correlated with bone mineral density (BMD),<sup>3</sup> early implant treatment failure,<sup>5</sup> and primary stability of dental implants when types 1 and 2 are combined together.<sup>6,7</sup> Furthermore, a significant correlation has been found between the subjective drilling resistance assessment and the L&Z classification, as assessed tomographically.<sup>2,8,9</sup> A recent systematic review<sup>10</sup> and numerous clinical trials<sup>11–13</sup> have confirmed that the placement of dental implants in bone sites of poorer qualities and/or lacking adequate bone volume according to the L&Z classification may significantly increase failure rates.

However, other researchers have reported lack of precision in the current classification system.<sup>4</sup> This is so because bone types 1 and 4 may be distinguishable from one another, but bone types 2 and 3 may be indistinguishable. Moreover, a wide range of computed tomography (CT) values (Hounsfield Units [HU]) may be observed within each category.<sup>4,14</sup> Furthermore, the inevitable overlapping of the cone beam computed tomography (CBCT) density values in each group of the classification makes it almost impossible to precisely identify a particular bone quality.<sup>15</sup> In addition, low interexaminer reliability has been reported in the subjective assessment of bone quality using the L&Z classification from CT images.<sup>16</sup>

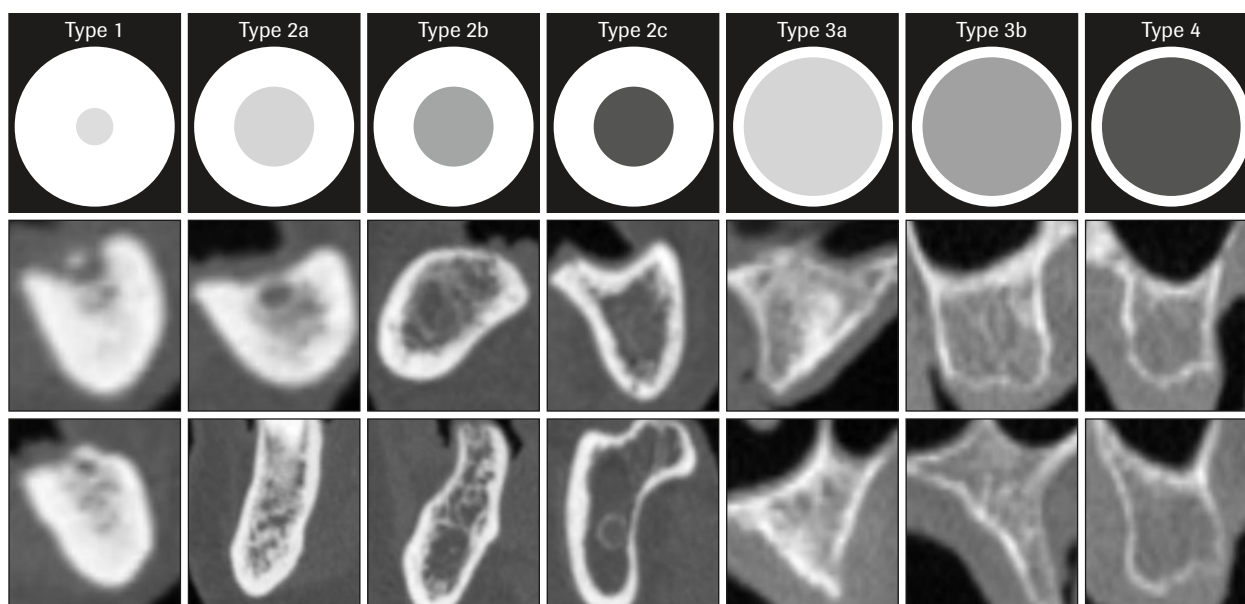
<sup>1</sup>Associate Professor, King Saud University, Department of Oral Medicine and Diagnostic Sciences, College of Dentistry, Riyadh, Saudi Arabia.

<sup>2</sup>Privatdozent, Medical University of Innsbruck, Department of Radiology, Innsbruck, Austria.

<sup>3</sup>Associate Professor, King Saud University, Department of Prosthetic Dental Sciences, College of Dentistry, Riyadh, Saudi Arabia.

**Correspondence to:** Dr Asma'a A. Al-Ekrish, Associate Professor, King Saud University, Department of Oral Medicine and Diagnostic Sciences, College of Dentistry, P.O. Box 60169, Riyadh 11545, Saudi Arabia. Fax: ++ 00 966 11 4695892. Email: aalekrish@ksu.edu.sa; asma.alekrish@gmail.com

©2018 by Quintessence Publishing Co Inc.



**Fig 1** Diagram of the cortical bone thicknesses and trabecular bone densities of the bone types in the revised classification, with examples of computed tomography (CT) transverse cross-sectional images of the jawbones for each bone type (all CT images were acquired with identical standard exposure and reconstruction parameters and displayed with identical settings) (bone window, window width: 4,500, window level: 850).

With CT imaging, various combinations of compact and trabecular bone are frequently encountered in the jawbone. The variable thickness and density of compact and trabecular bone within a single site may lead to variability in the subjective classification. The broad definition of bone tissue characteristics may lead to the lack of a standardized classification by different studies and, as such, the results of different studies may be difficult to compare and extrapolate to clinical situations.<sup>17</sup>

Given the limitations of bone type classifications in the current literature, this study aims to propose a revised L&Z classification that takes into account all possible combinations of compact and trabecular bone and to provide more reliable guidelines for increased utilization and reproducibility of the classification.

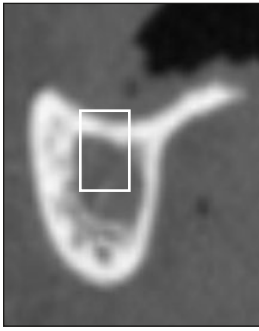
## Materials and Methods

The revised classification categorizes cortical bone according to thickness (thick or thin) and trabecular bone according to density (dense, medium density, or low density). To take into account all possible combinations of compact and trabecular bone, three new classes (type 2b, type 2c, and type 3b) have been added to the previous classification. The new classes have been designated as subclasses of bone types 2 and 3, as follows (Fig 1):

- Type 1: Entirely homogenous compact bone
- Type 2a: Thick layer of compact bone surrounding a core of dense trabecular bone
- Type 2b: Thick layer of compact bone surrounding a core of medium-density trabecular bone
- Type 2c: Thick layer of compact bone surrounding a core of low-density trabecular bone
- Type 3a: Thin layer of compact bone surrounding a core of dense trabecular bone
- Type 3b: Thin layer of compact bone surrounding a core of medium-density trabecular bone
- Type 4: Thin layer of compact bone surrounding a core of low-density trabecular bone

To increase the reproducibility of the revised classification, the following guidelines are recommended:

- When a site has areas of both thin and thick layers of compact bone, it should be considered to have a thick layer of compact bone.
- When a site has mixed-density trabecular bone, the predominant appearance should be considered. However, if the two densities are similar in area, then the area where an implant would be placed should be considered (Fig 2).
- To consistently differentiate between type 1 and type 2 bone, a site should be classified as type 1 if there is no clear and continuous endosteal border



**Fig 2** Transverse computed tomography cross-section of mandibular site demonstrating mixed-density trabecular bone. There is a wide area of high-density bone buccally and inferiorly and also a wide area of low-density bone in the center of the ridge. The classification of the trabecular density should be determined by the area where a proposed dental implant is expected to be placed (*marked by white rectangle*). Therefore, the trabecular bone at this site would be classified as low density.

for the cortical boundary. If a continuous clear endosteal boundary is identifiable, then the bone should be classified as type 2 (Fig 1).

Three experienced examiners—a prosthodontist with 14 years of experience (S.A.) and two oral and maxillofacial radiologists with 17 and 13 years of experience in interpretation of CT images—were recruited to test the intra-observer agreement using the proposed classification. The examiners were introduced to the revised classification with a written description of each bone type (as described above) and a diagrammatic representation of each bone type with sample images (Fig 1). The examiners were then provided with 47 CT sections of the jawbones as separate still images in Portable Network Graphics (PNG) format and viewed them on their individual laptop computers using Adobe Photoshop software (Versions CC 2017.1.1, Elements 8.0, and CS5.1, respectively), applying the above classification. The examiners were provided with the same images 1 week later in a different order and with different code numbers. They were asked to apply the classification to the same images. The intra-observer agreement for each examiner was then calculated as a kappa statistic. Statistical analysis was performed using Statistical Package for the Social Sciences (SPSS) version 24 (IBM).

Afterwards, the examiners were further calibrated using the above guidelines and by reviewing additional CT images demonstrating different densities of trabecular bone. Then, the same procedure for viewing the 47 images was repeated by each examiner twice with an interval of 1 week between examinations, and the intra-observer agreement was calculated again.

## Results

The intra-observer agreement for each examiner when the revised CT-based L&Z classification was applied to the 47 images without the guidelines was substantial, with the kappa statistic for the three

examiners being 0.749 (prosthodontist) and 0.738 and 0.747 for the two oral and maxillofacial radiologists. After further calibration with the suggested guidelines, the intra-observer agreement increased to almost perfect; the kappa statistic increased to 0.835 for the prosthodontist and 0.898 and 0.919 for the two oral and maxillofacial radiologists, respectively.<sup>18</sup> The *P* value for all the kappa values was < .001.

## Discussion

Poor bone quantity and quality have been consistently reported as among the main risk factors for implant failures as a consequence of impaired bone healing processes and excessive resorption.<sup>12,19</sup> Consequently, pretreatment diagnostic evaluation of potential implant sites is crucial for a favorable treatment prognosis.

The high reproducibility of the proposed revised L&Z classification guidelines obtained in the current study suggests its efficacy in distinguishing between the various combinations of compact and trabecular bone. The high intra-observer reproducibility obtained with the proposed classification suggests that it may improve the reliability of the tests, relating implant prognosis to bone type. The high reproducibility of the present classification may also improve communication between researchers and clinicians, as the bone types are clearly distinguished on the basis of cortical and trabecular bone and are also easily distinguishable from one another.

Nonetheless, prospective clinical trials are required to investigate the correlation between bone type as assessed using the revised classification and tactile sensation during osteotomies, BMD, early implant failure, primary stability of dental implants, and drilling resistance assessment. Moreover, further studies are also required to investigate the prevalence of the bone types in the various regions of the jaws using the proposed classification, as well as to investigate the CT numbers/HUs within each bone type.

## Acknowledgments

The authors thank Dr Dania Al-Tamimi, Oral and Maxillofacial Radiology Consultant and Dr Wafa Alfaleh, Associate Professor of Oral and Maxillofacial Radiology, for acting as examiners to test the reproducibility of the classification. The authors extend their appreciation to the Deanship of Scientific Research at King Saud University for funding this work through research group number RGP-1438-037. The authors report no conflicts of interest.

## References

- Lekholm U, Zarb GA. Patient selection and preparation. In: Brånemark PI, Zarb GA, Albrektsson T. *Tissue-Integrated Prostheses: Osseointegration in Clinical Dentistry*. Chicago: Quintessence Publishing Company, 1985:199–209.
- Lee S, Gantes B, Riggs M, Crigger M. Bone density assessments of dental implant sites: 3. Bone quality evaluation during osteotomy and implant placement. *Int J Oral Maxillofac Implants* 2007;22:208–212.
- Horner K, Devlin H. The relationships between two indices of mandibular bone quality and bone mineral density measured by dual energy x-ray absorptiometry. *Dentomaxillofac Radiol* 1998;27:17–21.
- Shahlaie M, Gantes B, Schulz E, Riggs M, Crigger M. Bone density assessments of dental implant sites: 1. Quantitative computed tomography. *Int J Oral Maxillofac Implants* 2003;18:224–231.
- Nedir R, Bischof M, Szmukler-Moncler S, Bernard JP, Samson J. Predicting osseointegration by means of implant primary stability. *Clin Oral Implants Res* 2004;15:520–528.
- Gómez-Polo M, Ortega R, Gómez-Polo C, Martín C, Celemín A, Del Río J. Does length, diameter, or bone quality affect primary and secondary stability in self-tapping dental implants? *J Oral Maxillofac Surg* 2016;74:1344–1353.
- Linck GK, Ferreira GM, De Oliveira RC, Lindh C, Leles CR, Ribeiro-Rotta RF. The influence of tactile perception on classification of bone tissue at dental implant insertion. *Clin Implant Dent Relat Res* 2016;18:601–608.
- Rokn A, Rasouli Ghahroudi AA, Daneshmonfared M, Menasheof R, Shamshiri AR. Tactile sense of the surgeon in determining bone density when placing dental implant. *Implant Dent* 2014;23:697–703.
- Filho LC, Cirano FR, Hayashi F, et al. Assessment of the correlation between insertion torque and resonance frequency analysis of implants placed in bone tissue of different densities. *J Oral Implantol* 2014;40:259–262.
- Chrcanovic BR, Albrektsson T, Wennerberg A. Bone quality and quantity and dental implant failure: A systematic review and meta-analysis. *Int J Prosthodont* 2017;30:219–237.
- Chrcanovic BR, Albrektsson T, Wennerberg A. Reasons for failures of oral implants. *J Oral Rehabil* 2014;41:443–476.
- Jaffin RA, Berman CL. The excessive loss of Branemark fixtures in type IV bone: A 5-year analysis. *J Periodontol* 1991;62:2–4.
- Friberg B, Jemt T, Lekholm U. Early failures in 4,641 consecutively placed Brånemark dental implants: A study from stage 1 surgery to the connection of completed prostheses. *Int J Oral Maxillofac Implants* 1991;6:142–146.
- Norton MR, Gamble C. Bone classification: An objective scale of bone density using the computerized tomography scan. *Clin Oral Implants Res* 2001;12:79–84.
- Hohlweg-Majert B, Pautke C, Deppe H, Metzger MC, Wagner K, Schulze D. Qualitative and quantitative evaluation of bony structures based on DICOM dataset. *J Oral Maxillofac Surg* 2011;69:2763–2770.
- Shapurian T, Damoulis PD, Reiser GM, Griffin TJ, Rand WM. Quantitative evaluation of bone density using the Hounsfield index. *Int J Oral Maxillofac Implants* 2006;21:290–297.
- Ribeiro-Rotta RF, Lindh C, Pereira AC, Rohlin M. Ambiguity in bone tissue characteristics as presented in studies on dental implant planning and placement: A systematic review. *Clin Oral Implants Res* 2011;22:789–801.
- Landis JR, Koch GG. The measurement of observer agreement for categorical data. *Biometrics* 1977;33:159–174.
- Herrmann I, Lekholm U, Holm S, Kultje C. Evaluation of patient and implant characteristics as potential prognostic factors for oral implant failures. *Int J Oral Maxillofac Implants* 2005;20:220–230.

### Literature Abstract

#### Occlusal Onlays as a Modern Treatment Concept for the Reconstruction of Severely Worn Occlusal Surfaces

According to the Fifth German Oral Health Study, the caries experience in the German population is declining sharply. The number of teeth still present at an advanced age has also increased significantly in recent decades. These findings show a clear trend toward long-term tooth preservation, possibly with fixed dental prostheses, which is further supported by the possibility of placing implants to increase the number of abutments. The pronounced decline in caries experience has given Germany a leading international position in terms of dental health, but there is increasing evidence of risks associated with dental hard tissue damage because of erosion/biocorrosion, attrition, and abrasion. The defect morphology of these wear-related lesions is different from that of caries lesions, as occlusal surfaces are more often affected in the posterior region. Against this background, restorative treatment concepts have become significantly more differentiated in recent decades. Predominantly subtractive concepts to provide mechanical retention for the restoration using traditional cements are now replaced by less invasive, primarily defect-oriented procedures whenever feasible. In the case of pronounced dental hard tissue loss, additive approaches also allow restorations that restore function. In addition, there are modifications to traditional procedures, such as defining the treatment goal in the lead-up to the treatment itself with the aid of a diagnostic wax-up. The wax-up provides orientation for the subsequent tooth preparation and allows a particularly economical approach to the removal of healthy dental hard tissue. Furthermore, the introduction of new preparation designs has contributed significantly to the preservation of dental hard tissue on the teeth to be restored. This article describes the principles of minimally invasive treatment using occlusal onlays for the reconstruction of severely worn occlusal surfaces.

**Edelhoff D, Ahlers MO.** *Quintessence Int* 2018;49:521–533. **References:** 60. **Reprints:** Daniel Edelhoff, daniel.edelhoff@med.uni-muenchen.de —Steven Sadowsky, USA