

# Bilateral myopic photorefractive keratectomy in a 14-year-old boy

Italo Giuffrè

Department of Ophthalmology  
University of Rome Tor Vergata Medical School, Rome, Italy.

**Citation:** Giuffrè I. Bilateral myopic photorefractive keratectomy in a 14-year-old boy. *North Am J Med Sci* 2010; 1: 36-38.

**Availability:** www.najms.org

**ISSN:** 1947 – 2714

## Abstract

**Context:** Refractive surgery has been performed for more than 10 years. Laser-assisted intrastromal keratomileusis (LASIK) and photorefractive keratectomy (PRK) may be used in accommodative esotropia either in adolescent or in adult patients. Some authors have shown that LASIK is safe, effective, and stable at 10 years follow-up post-surgery. **Case report:** A 14-year-old boy was admitted to our outpatient department on 08-01-2008. Together with his parents he asked for both eyes to be operated on by myopic PRK. On September 5<sup>th</sup> 2008 a myopic PRK was performed on his right eye and on September 12<sup>th</sup> 2008 on his left eye. A Bausch & Lomb Z172 excimer laser was used to perform a Planoscan procedure on both eyes. Uncorrected visual acuity was 1.0 after both procedures. The patient did not suffer pain, haze or glare in postoperative follow-up. **Conclusion:** Apart from the surgical technique, the author raises questions about the ethics of this procedure in a young boy.

**Keywords:** Ethics, myopia, paediatrics, PRK.

**Correspondence to:** Italo Giuffrè MD, PhD, Via Seneca, 34 – 00136 Roma, Italy. Tel./Fax: +390635341166, Email: italogiuffre@libero.it

## Introduction

Refractive surgery has been performed for more than 10 years. The first cases of paediatric photorefractive keratectomy (PRK) date back to 1995. Laser-assisted intrastromal keratomileusis (LASIK) was introduced a few years later in 1999. In this moment it is a crucial matter for refractive surgeon, if R.L. Lindstrom wrote an Editorial perspective on the 2009 October issue of Ocular Surgery News [1]. In the same issue, a cover story raises questions about refractive surgery (PRK, the use of mitomycin C, LASIK, LASEK or phakic IOLs) in paediatric patients [2]. Good vision correction results have also been shown with surgically implanted intraocular lenses, also called phakic IOLs [3]. A femtosecond laser enhances safety and efficacy in refractive surgery [4]. Some authors have shown that paediatric LASIK is safe, effective and stable at 10 years follow-up [5]. LASIK and PRK may be used in refractive accommodative esotropia [6-12] either in

adolescent or in adult patients. Refractive surgery may be an alternative to contact lens wear and may reduce long-term costs. However, paediatric eyes may still be developing, and there is a theoretical risk of rapid myopic progression and shift in patients performing tasks that require near vision, such as schoolwork. Another risk is to operate on eyes with unrecognized keratoconus.

The aim of this report is to describe a case of a 14-year-old boy, operated on with PRK on both eyes, and to evaluate this procedure both on surgical technique and on its ethical implications.

## Case Report

On August 1<sup>st</sup> 2008, a 14 years old boy was admitted to the outpatient department. Systemic and ophthalmological anamnesis was negative. On his ophthalmological

assessment, RE UCVA 0.5 BCVA – 1.50 sf 1.0 P1 and LE UCVA 0.5 BCVA – 1.50 sf 1.0 P1 were found. Both anterior and posterior segments were within normal limits. Intraocular pressure was normal. Cycloplegic refraction was exactly the same as the subjective refraction.

On September 5<sup>th</sup> 2008, Orbscan examination on both eyes was performed. The boy's corneal central pachymetry was 476 µm (right eye) and 492 µm (left eye). Both astigmatism and keratometric indexes were within normal limits (Fig. 1 - 3).

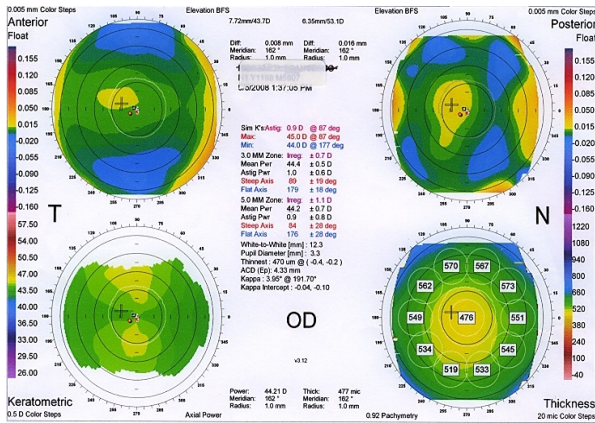


Fig. 1 Orbscan in right eye

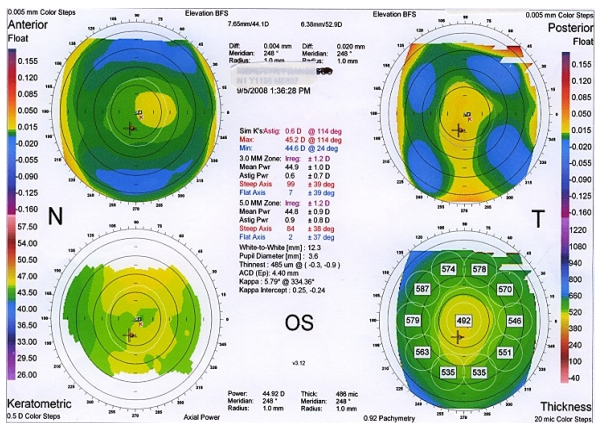


Fig. 2 Orbscan in left eye

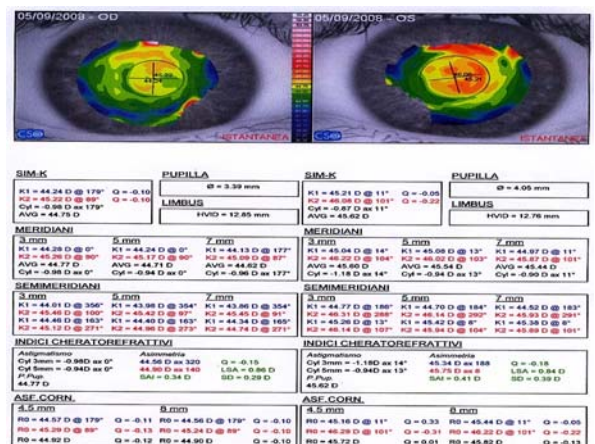


Fig. 3 Keratometric indexes in both eyes

A myopic PRK was performed with Planoscan. In the right eye, the optical zone diameter was 7.0 mm. A 42 µm

ablation of the corneal stroma by 1157 pulses was performed using a Bausch & Lomb Z172 excimer laser. The limit of 400 µm of corneal stroma depth was kept. After topical anaesthesia by lidocaine in the right eye, a corneal epithelium abrasion was performed by a smooth spatula. The number of pulses was administered as long as four surgical terms. The whole procedure was as long as one minute. The patient did not have any pain, haze or glare, and received topical 1% omatropine, 0.3% of loxacin and NSAID drops as postoperative therapy. A protective corneal shield was used for seven days post-operation. An ophthalmological assessment was performed at days 1, 7, 14, 21, 30, 180 and 360 post-operation. After 14 days, mydriatic drops were discontinued. Lachrymal substitutes were used up to one year after surgery.

One week after the procedure on the right eye, the same surgical procedure was performed on the left eye. Post-operative medical therapy and follow-up were the same as in the right eye.

Either by subjective or objective criteria, excellent results were obtained. The UCVA was 1.0 on both eyes in the first days post-operation. No local or systemic adverse effects, apart from mydriasis due to 1% omatropine drops, were seen.

## Discussion

This case report raises certain questions. From the surgical technique point of view, a skilled refractive surgeon is able to perform such a procedure. Results were quite excellent both from a subjective and objective point of view. From the ethical point of view, we must ask if, even after written informed consent and central corneal thickness data, the chance of an increase in myopic shift during the next years of life indicates that this type of laser procedure should be performed. Data from international literature stress that paediatric LASIK is safe, effective and stable at 10 years post-procedure [5]. Some authors [9-11] stress that paediatric refractive surgery is useful in high unilateral myopia and/or anisometropic amblyopia.

In any case I agree with Lindstrom's thought that we need a carefully planned clinical trial, approved by an institutional review board (1). It is essential to know if the written informed consent, signed by both parents, will be sufficient for the surgeon in case of surgical failure.

## References

1. Lindstrom RL. Corneal refractive surgery in children still in beginning stages. Ocular Surgery News 2009; 20: 3.
2. Brown SM, Kim T, O'Keeffe M, Paysse EA, Tychsens L. Should refractive surgery be used to correct visual errors in paediatric patients? Ocular Surgery News 2009; 20: 10-13.

3. Lesuer LC. Best treatment plan available for pediatric refractive surgery. *Ocular Surgery News* 2009; 20: 32-33.
4. Balestrazzi E, Mosca L. Femtosecond laser enhances safety and efficacy of keratoplasty procedures. *Eurotimes* 2009; 14: 18.
5. Ibrahim O. Study: pediatric LASIK safe, effective, stable at 10 years. *Ocular Surgery News* 2008; 19: 1-4.
6. Stahl E. Laser refractive surgery may be an effective alternative in pediatric patients. *Ocular Surgery News* 2009; 20: 18.
7. Sabetti L, Spadea L, D'Alessandri L, Balestrazzi E. Photorefractive keratectomy and laser in situ keratomileusis in refractive accommodative esotropia. *J Cataract Refract Surg* 2005; 31: 1899-1903.
8. Nucci P, Serafino M, Hutchinson AK. Photorefractive keratectomy for the treatment of purely refractive accommodative esotropia. *J Cataract Refract Surg* 2003; 29: 889-894.
9. Nucci P, Drack AV. Refractive surgery for unilateral high myopia in children. *J AAPOS* 2001; 5: 348-351.
10. Nucci P, Serafino M, Hutchinson AK. Photorefractive keratectomy for anisometropic amblyopia in children. *Trans Am Ophthalmol Soc* 2004; 102: 341-371.
11. Singh D. Photorefractive keratectomy in pediatric patients. *J Cataract Refract Surg*. 1995; 21: 630-632.
12. Tychsen L, Pachwood E, Berdy G. Correction of large amblyopiogenic refractive errors in children using the excimer laser. *J AAPOS* 2005; 9: 224-233.