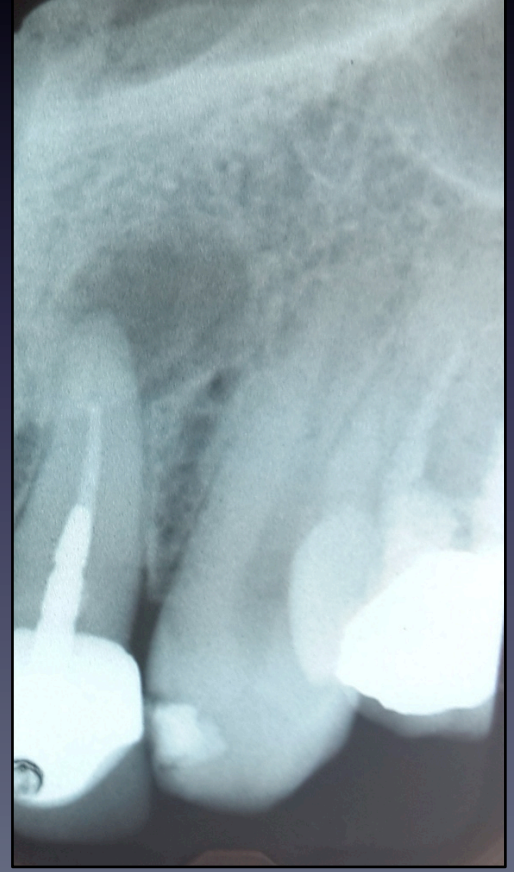
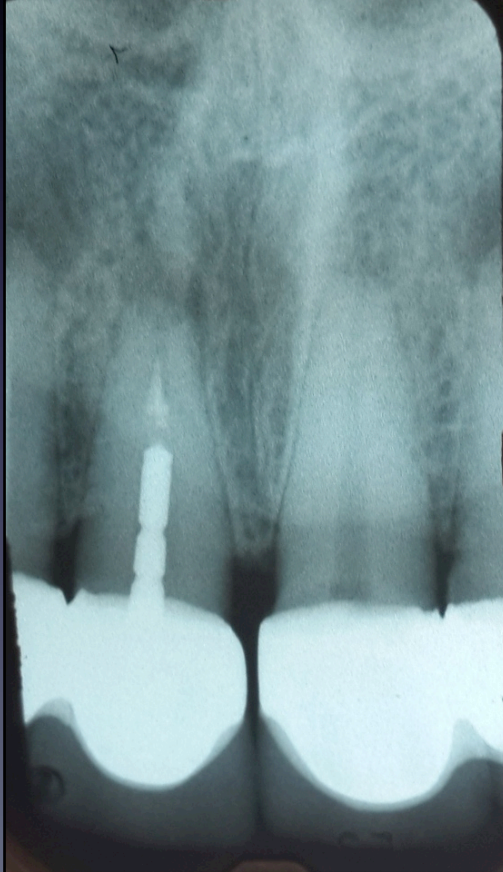
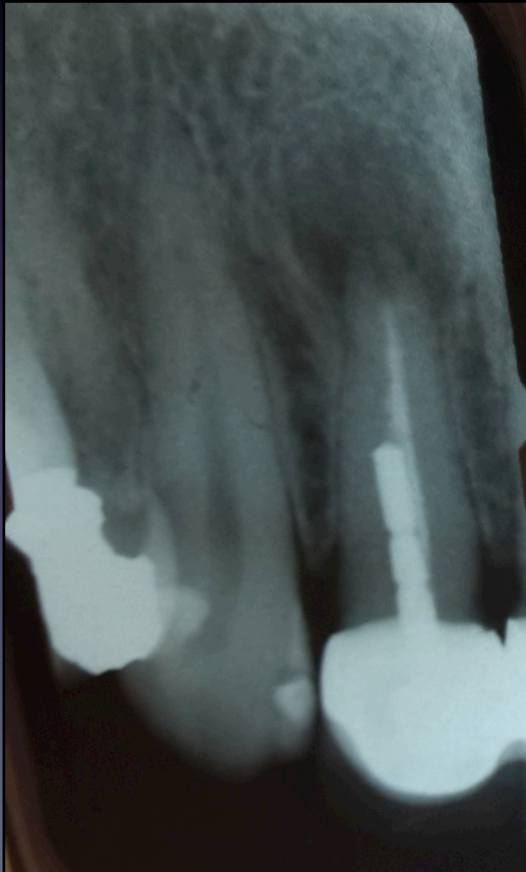
Learning Objectives of CBL2

- ◆ The ability to ***Plan and Prepare*** the case for Endo. Surgery.
- ◆ The ability to ***Differentiate and Compare*** between the different retro-filling materials
- ◆ The ability to ***Review and Evaluate*** articles findings relevant to presented case.
- ◆ The ability to ***Evaluate*** the outcome of Endodontic Surgery

Chief Complaint

- 45 years old female patient.
- Referred from prosthodontist for possible conventional Re-tx. and assessment of tooth #21

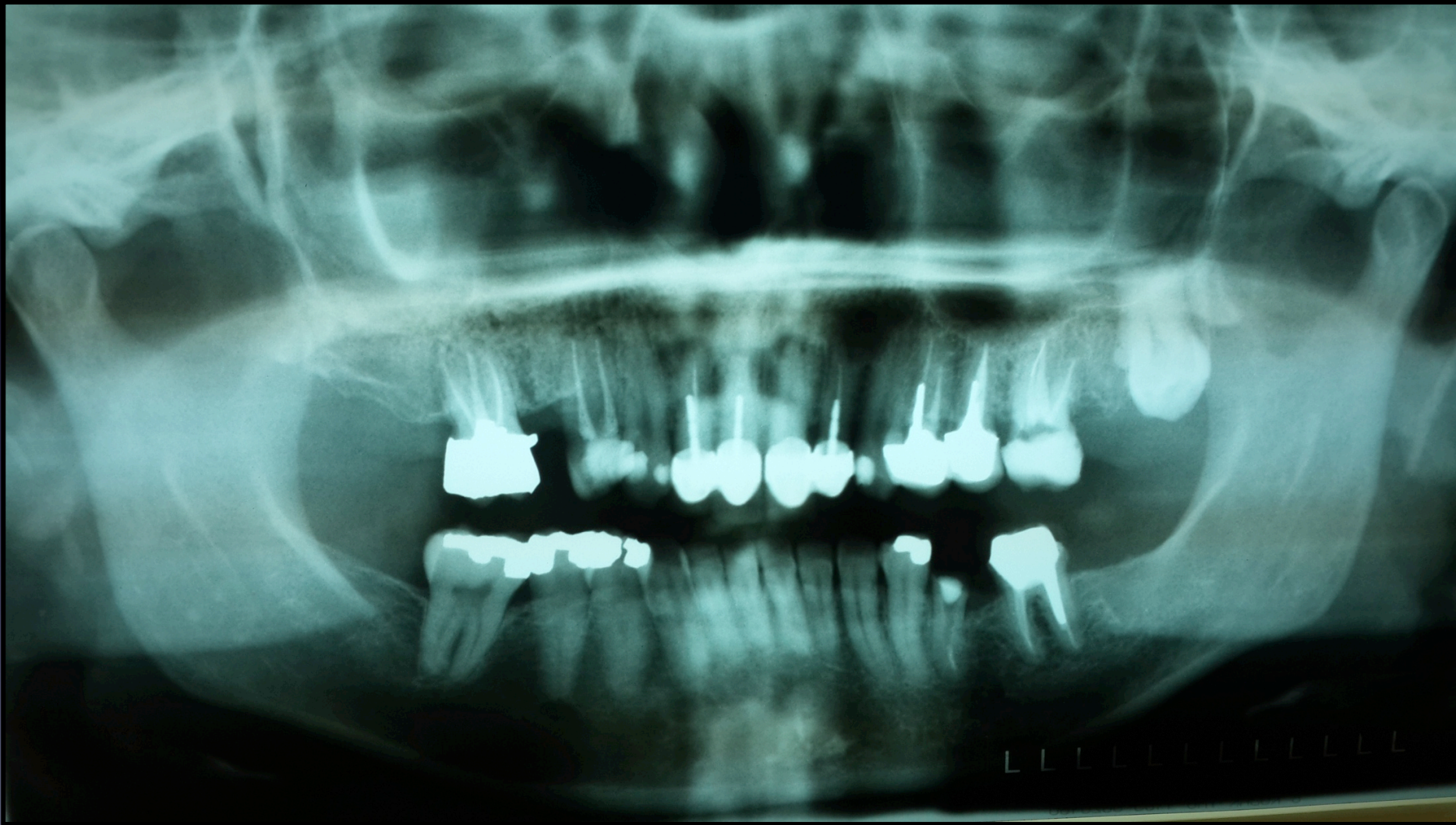

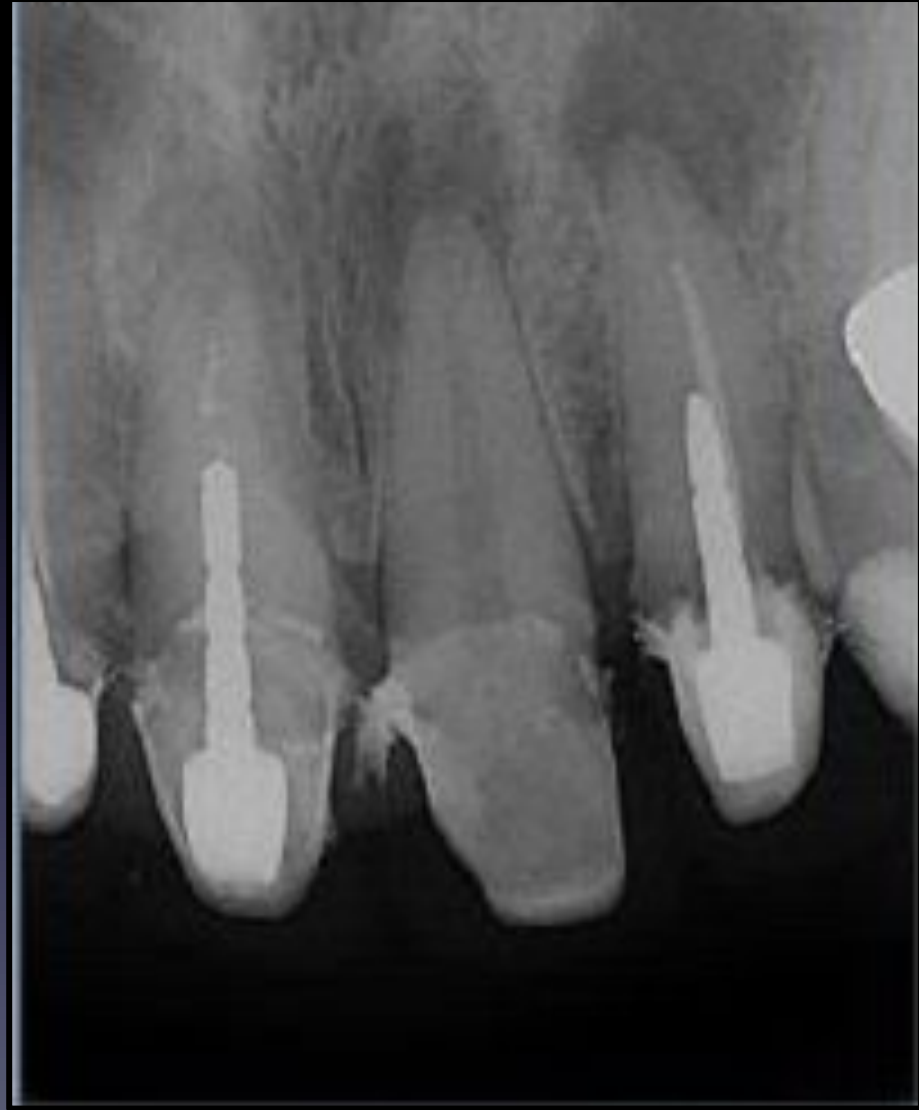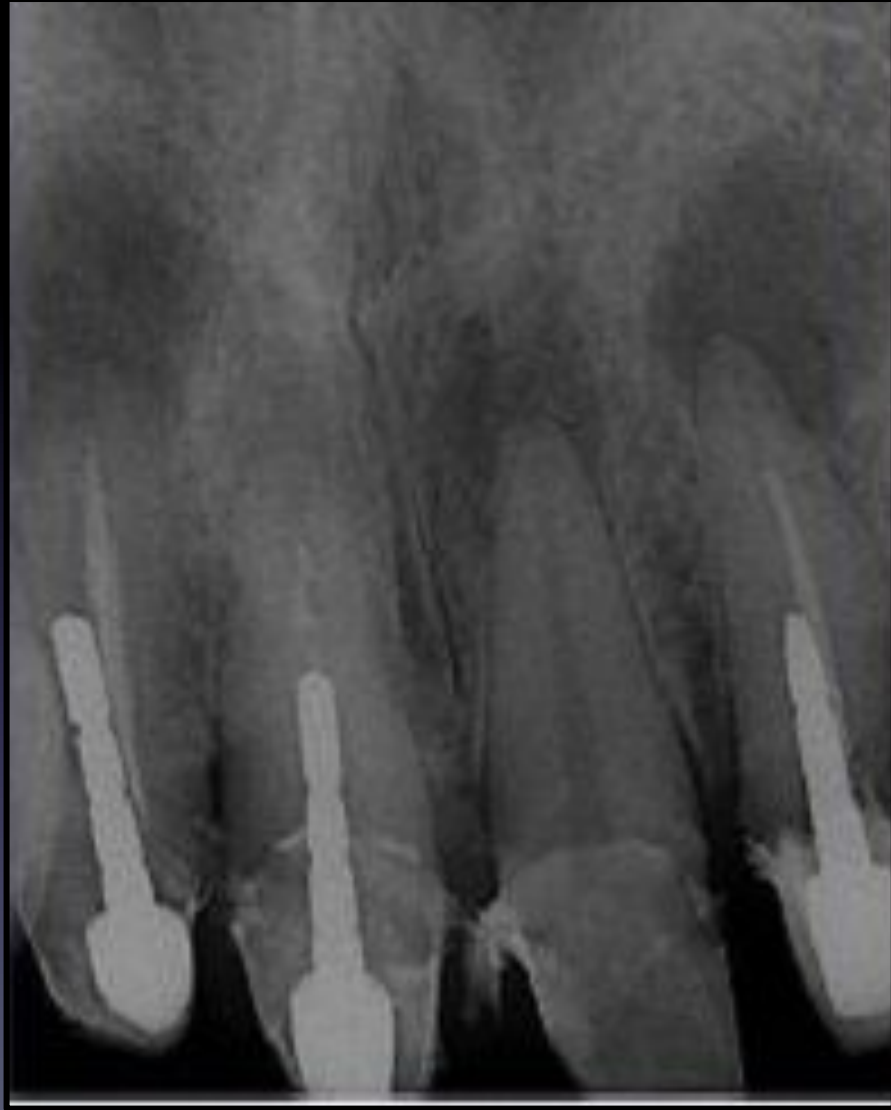Dental History

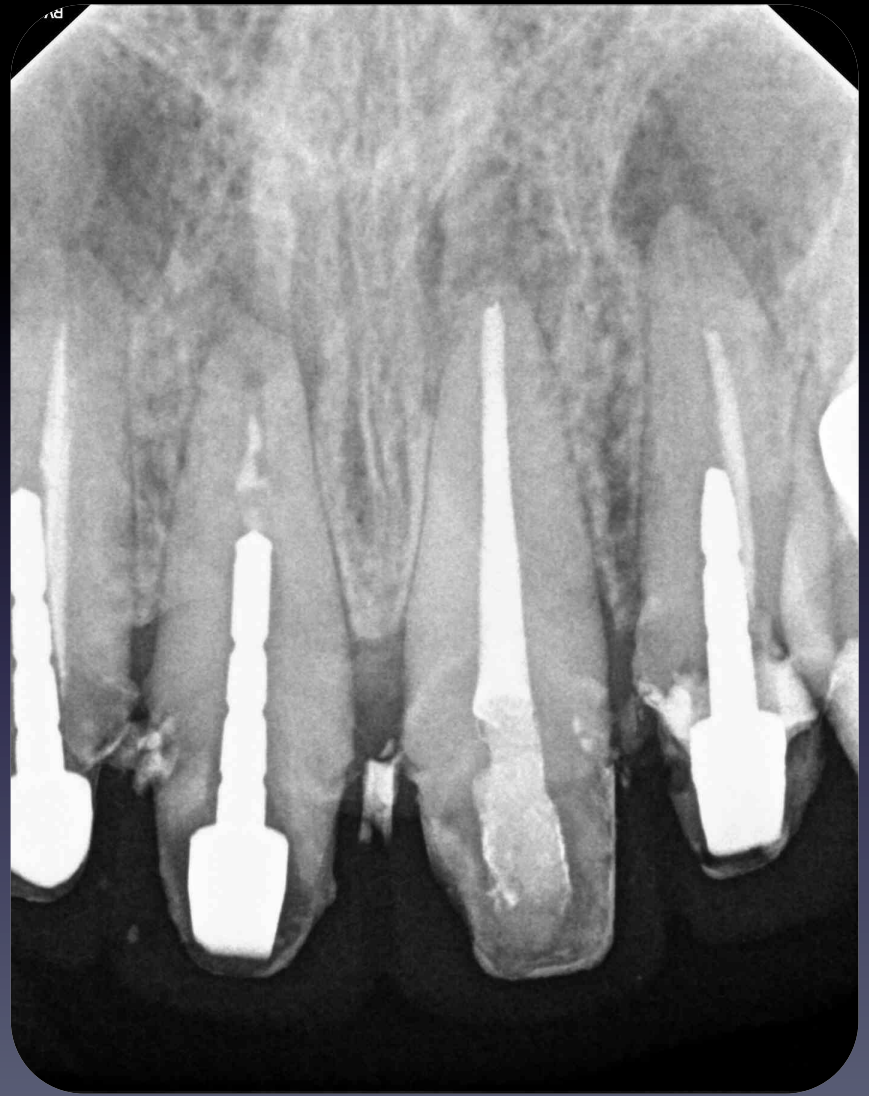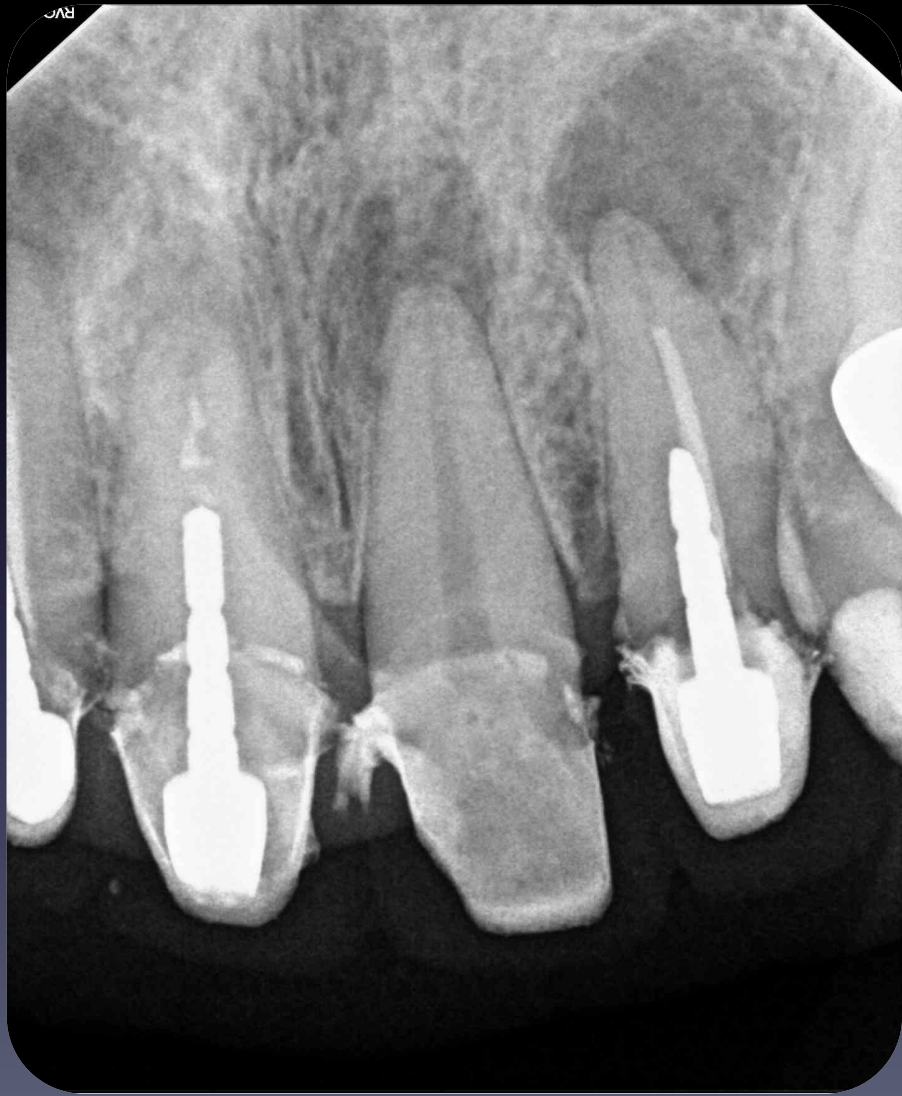- Root Canal treatment performed on Teeth # 11, #21, and # 22 >10 yrs
- Those teeth were a symptomatic and restored with post and core & crown.
- Patient is not happy from the esthetic appearance of the crowns.

- ***Medical History*** :ASA I
- ***Clinical Examination***: crown on the upper anterior teeth with poor contour and esthetic.
- The teeth were a symptomatic , tender to percussion but not palpation.
- Tooth #21 didn't respond the cold test and was tender to percussion but not palpation.
- Periodontal exams confirmed normal probing depth (i.e., < 3 mm) all around the tooth and normal physiologic mobility.

Radiographic Examination







Surgery





