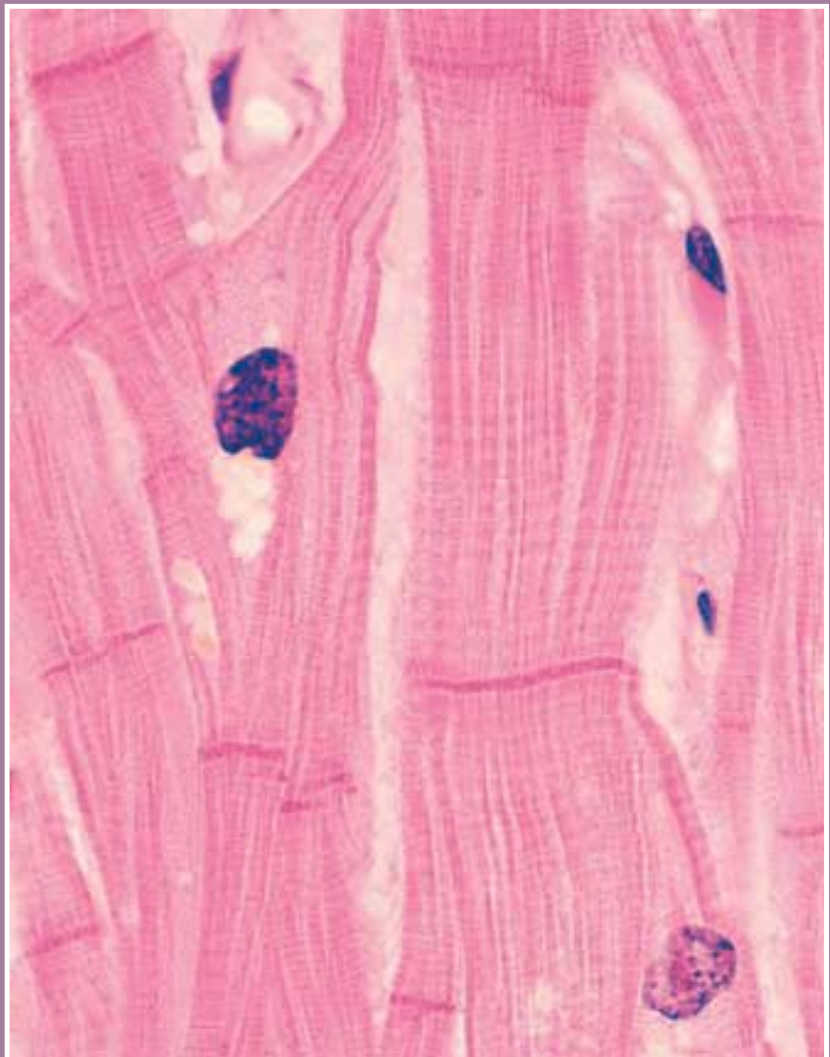


C H A P T E R

3

Human Muscular Anatomy



Cardiac Muscle (Longitudinal Section)

66 CHAPTER 3

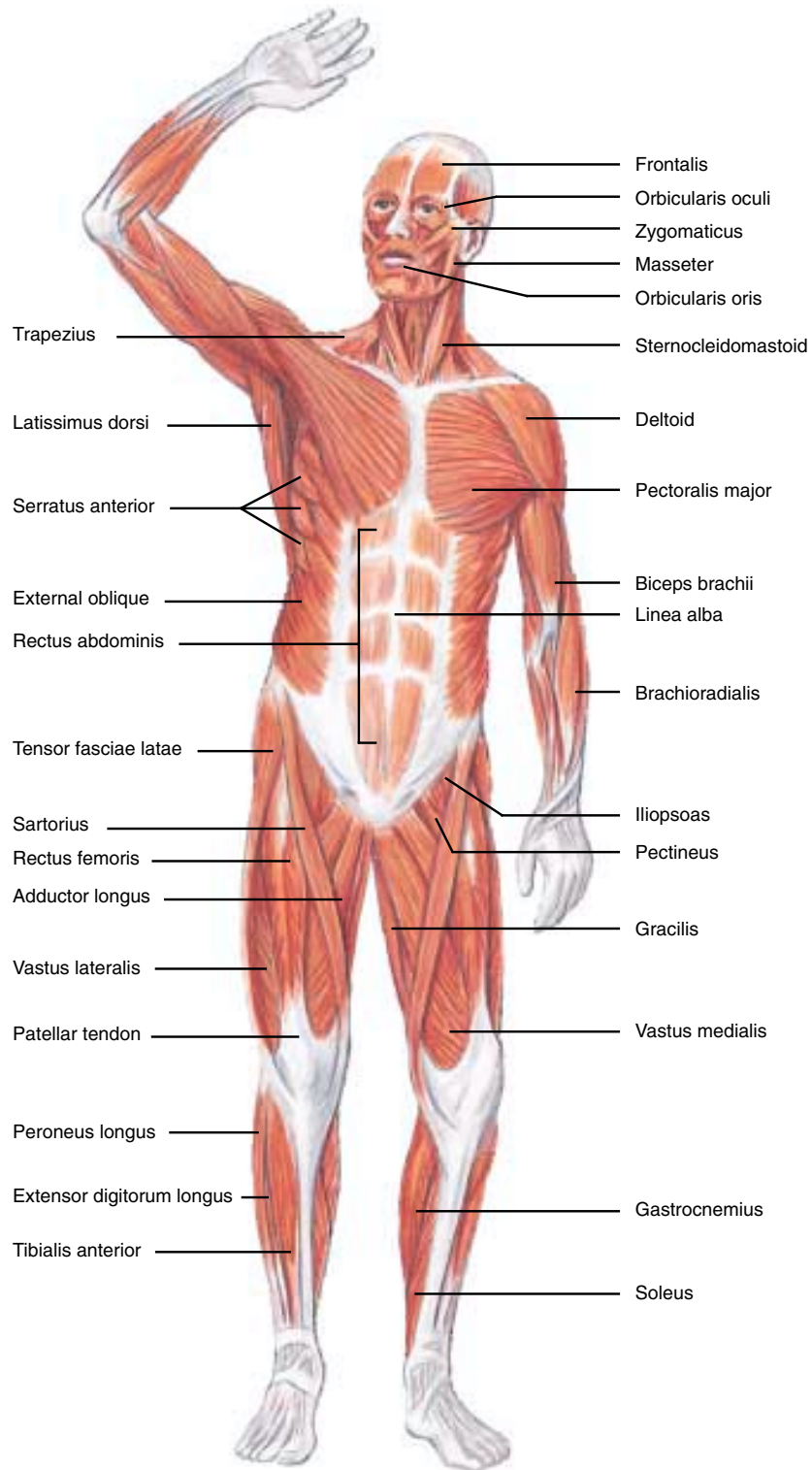


Figure 3-1
Superficial Skeletal Muscles
A. Anterior view.

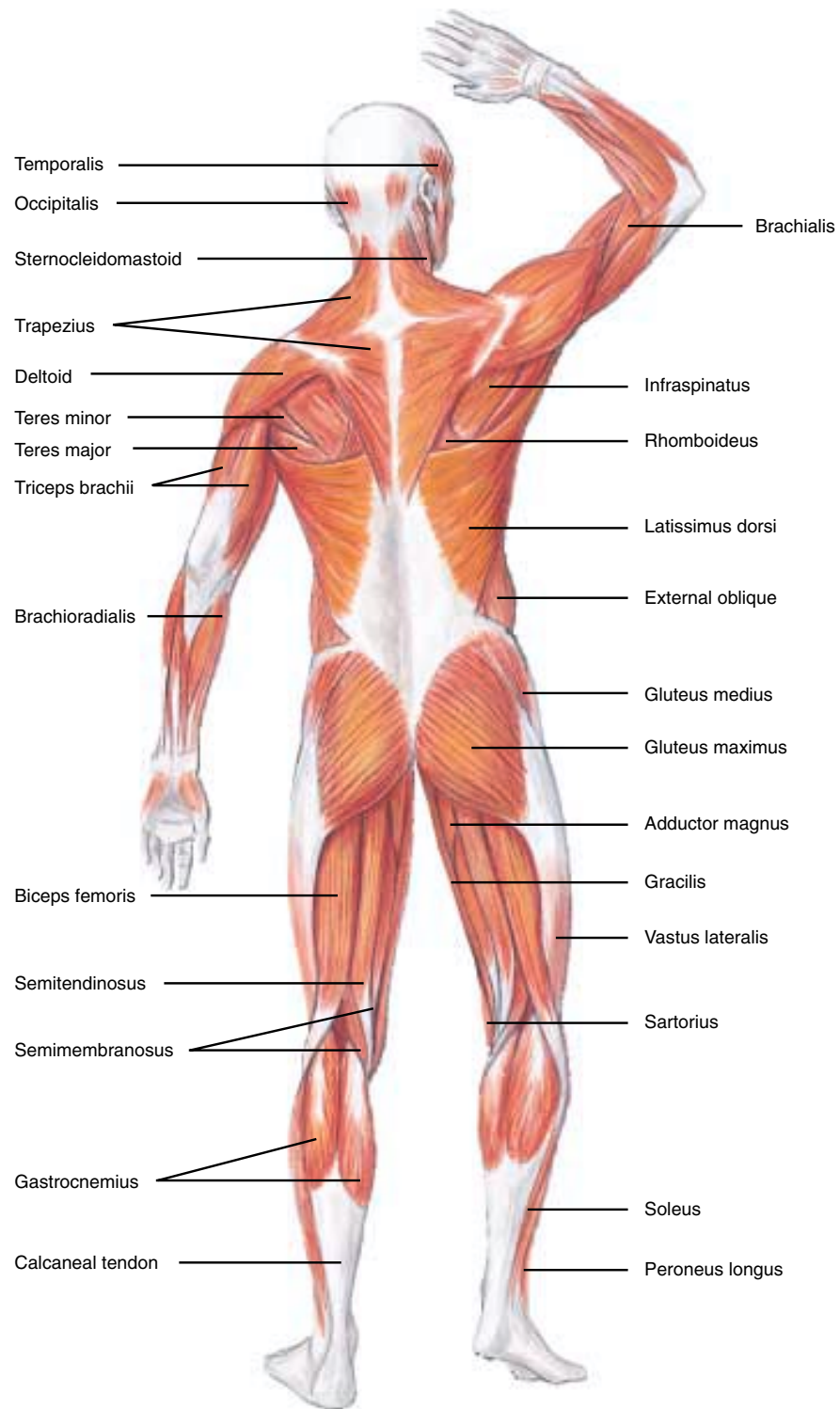


Figure 3-1—cont'd.
B. Posterior view.

68 CHAPTER 3

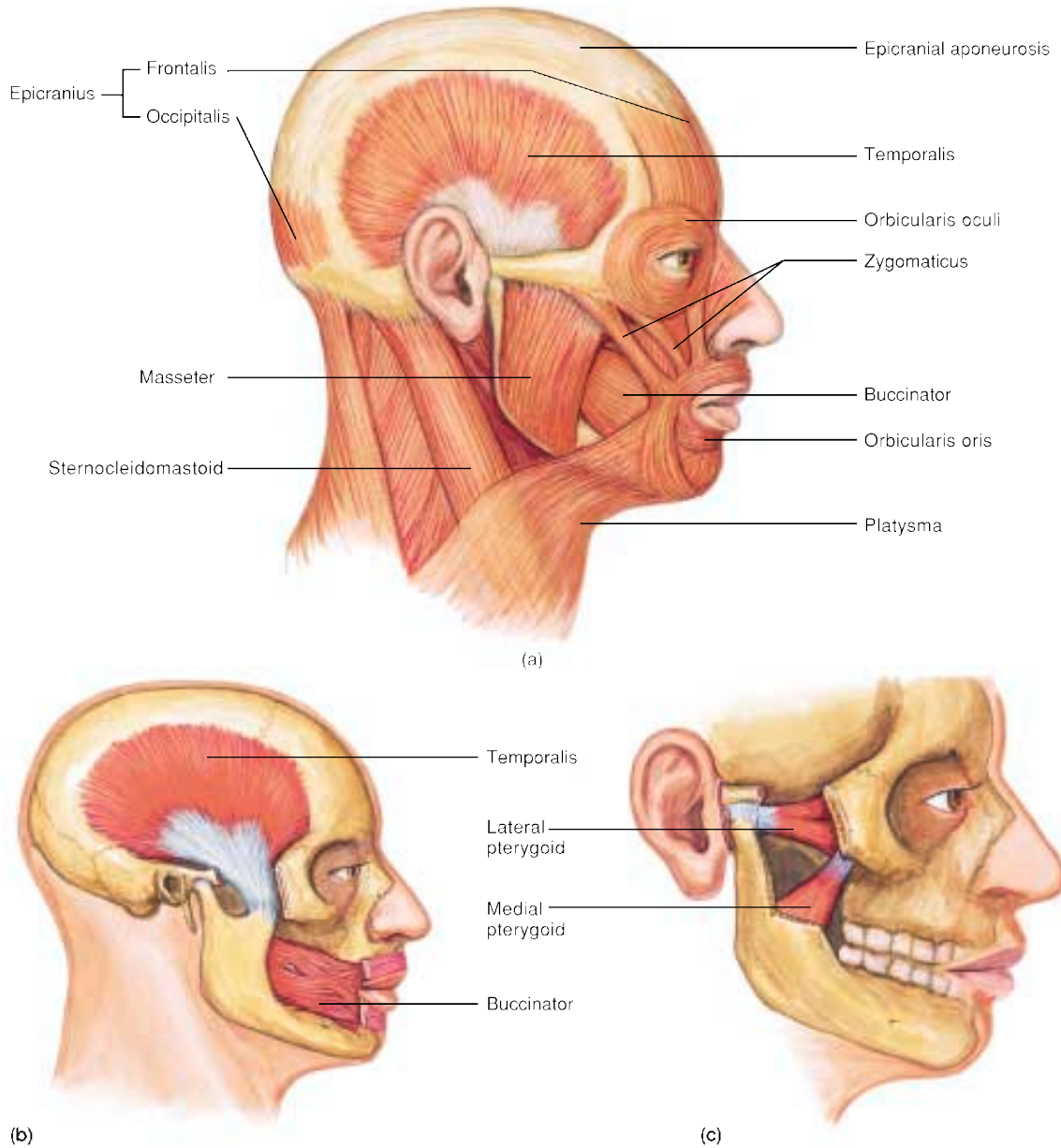


Figure 3-2
(a) Muscles of facial expression and mastication; isolated views of (b) the temporalis and buccinator muscles and (c) the lateral medial pterygoid muscles.

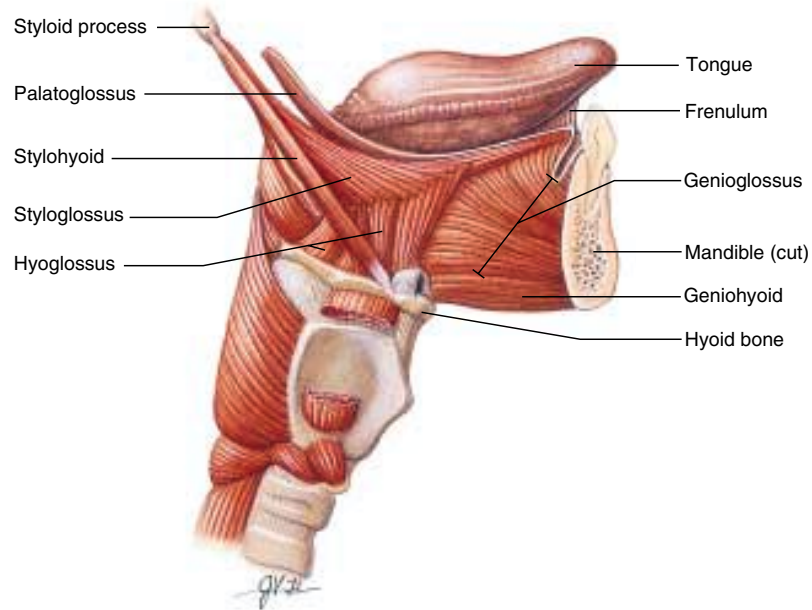


Figure 3-3

Muscles of the tongue, right lateral view.

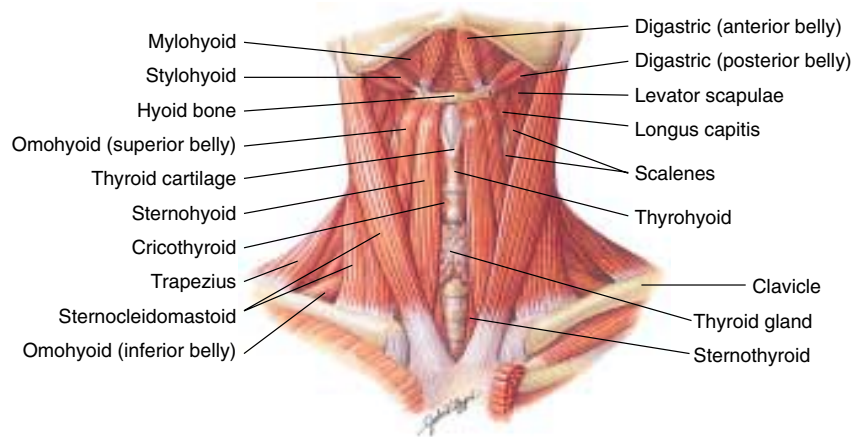


Figure 3-4

Muscles of the anterior neck, superficial view.

70 CHAPTER 3

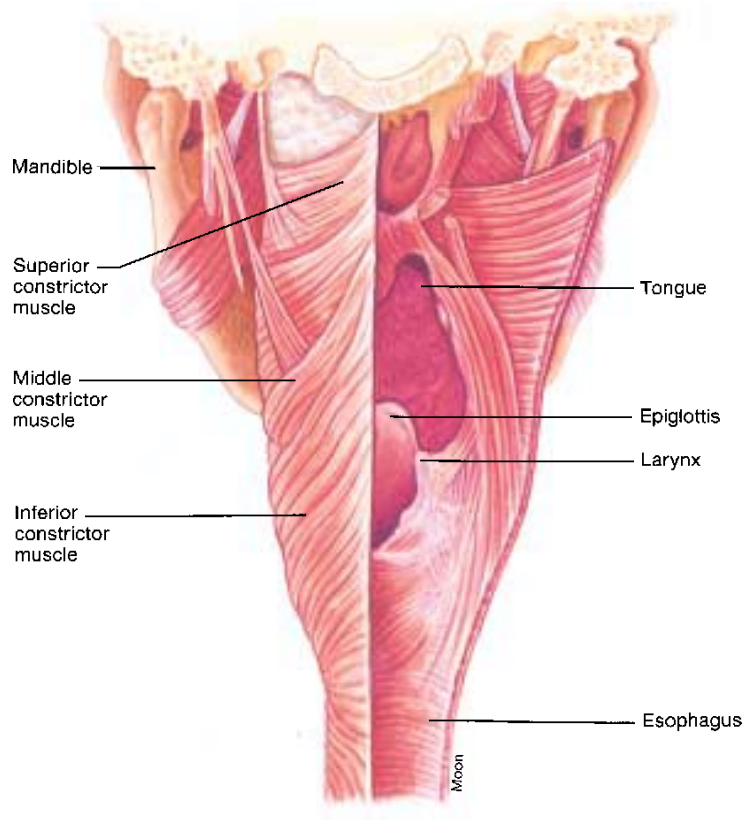


Figure 3-5

Posterior view of the constrictor muscles of the pharynx. Right side has been cut away to illustrate the interior structures in the pharynx.

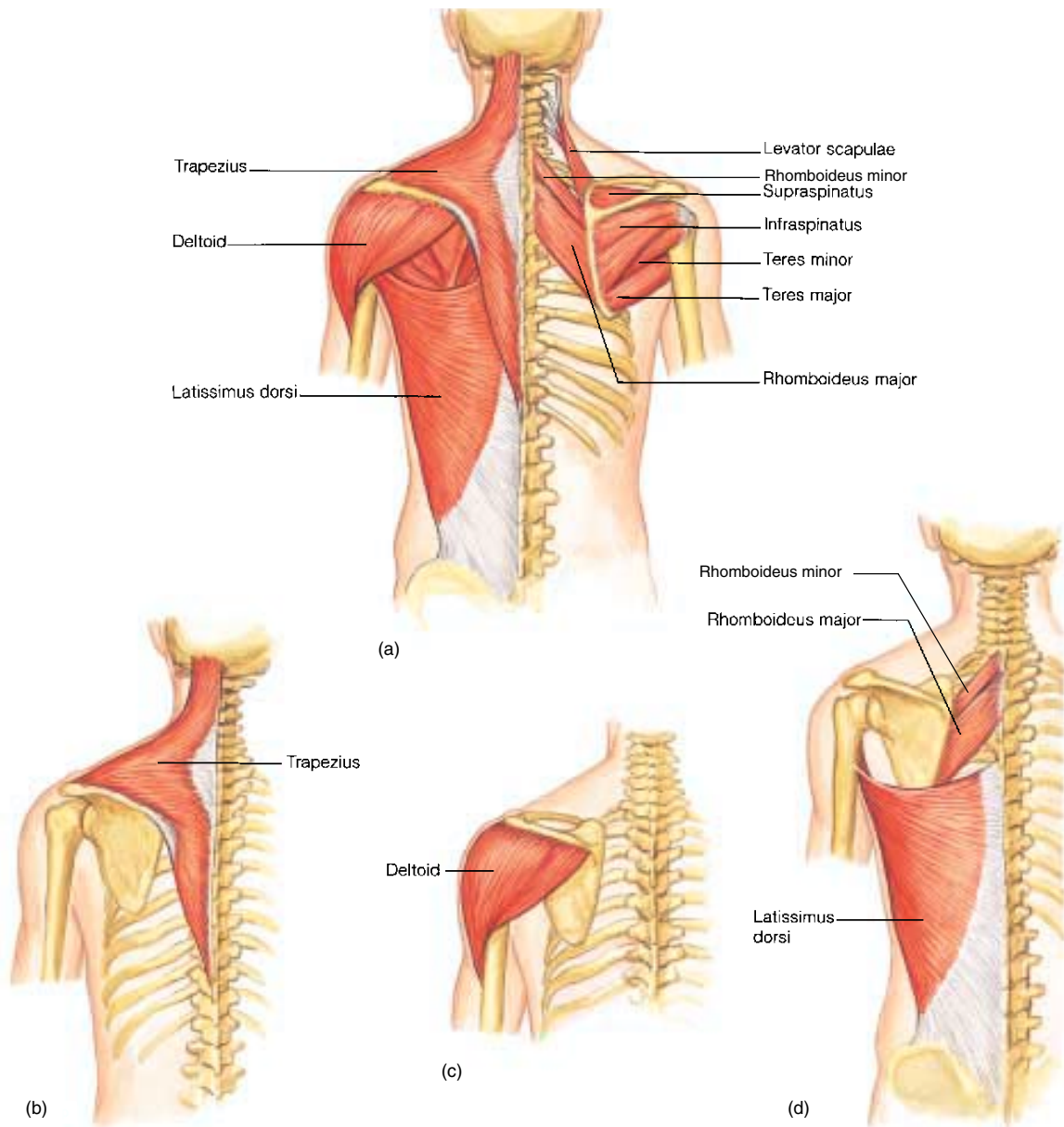


Figure 3-6

(a) Muscles of the posterior shoulder. The right trapezius is removed to show underlying muscles. Isolated views of (b) trapezius, (c) deltoid, and (d) rhomboideus and latissimus dorsi muscles.

72 CHAPTER 3

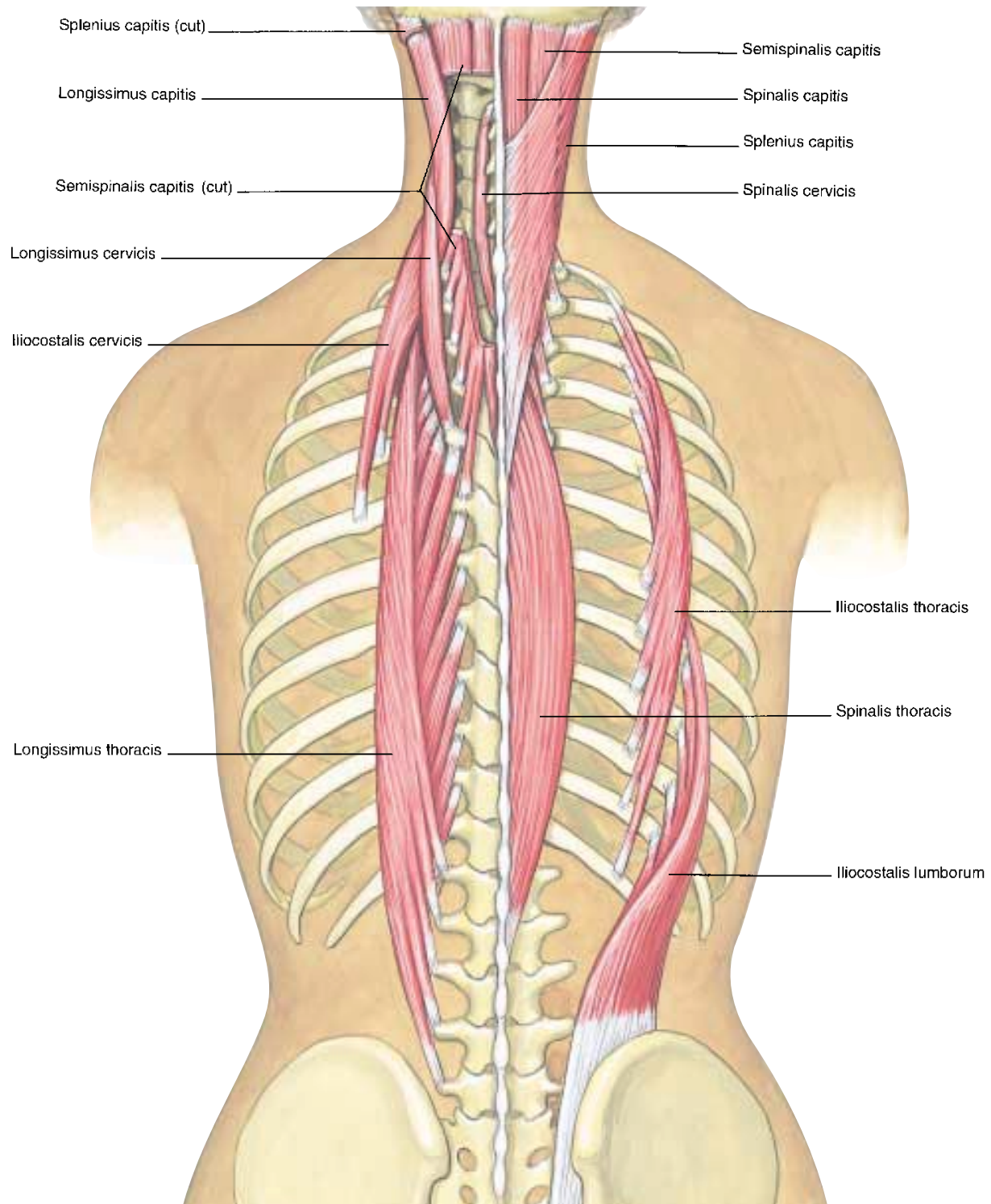


Figure 3-7

Deep muscles of the back and the neck help move the head (posterior view) and hold the torso erect. The splenius capitis and semispinalis capitis are removed on the left to show underlying muscles.

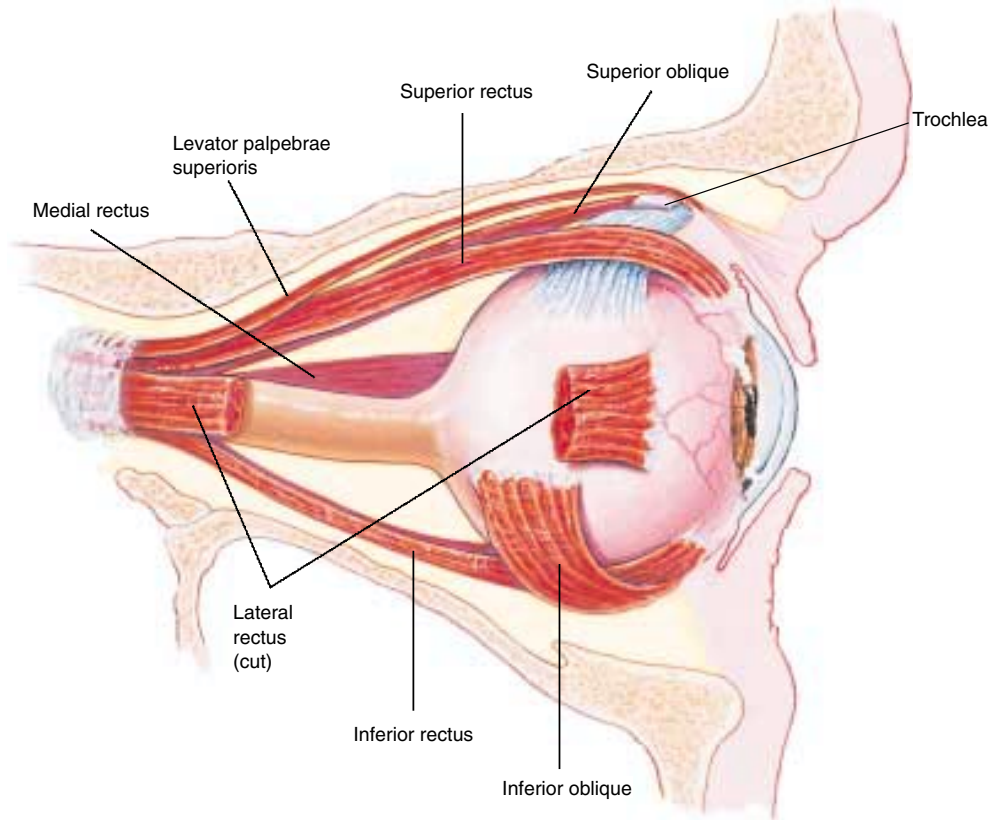


Figure 3-8
Extrinsic muscles of the right eye, lateral view.

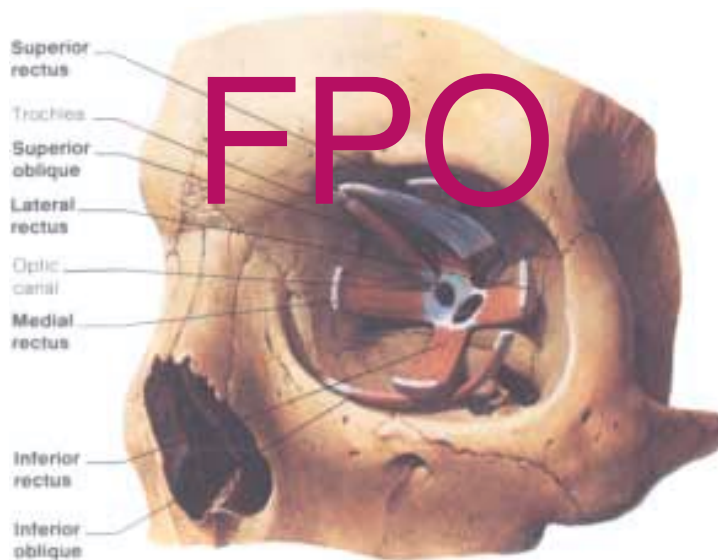


Figure 3-9
Extrinsic muscles of the left eye, anterior view.

74 CHAPTER 3

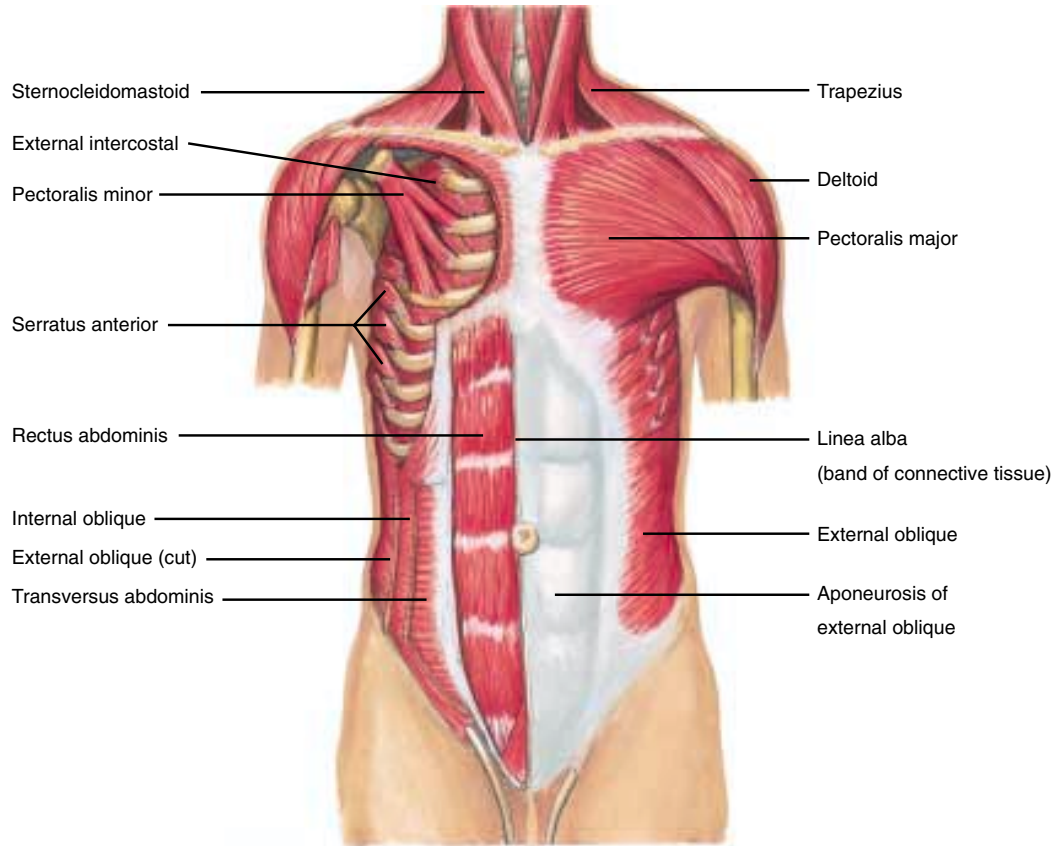


Figure 3-10

Muscles of the anterior chest and abdominal wall. The right pectoralis major is removed to show the pectoralis minor.

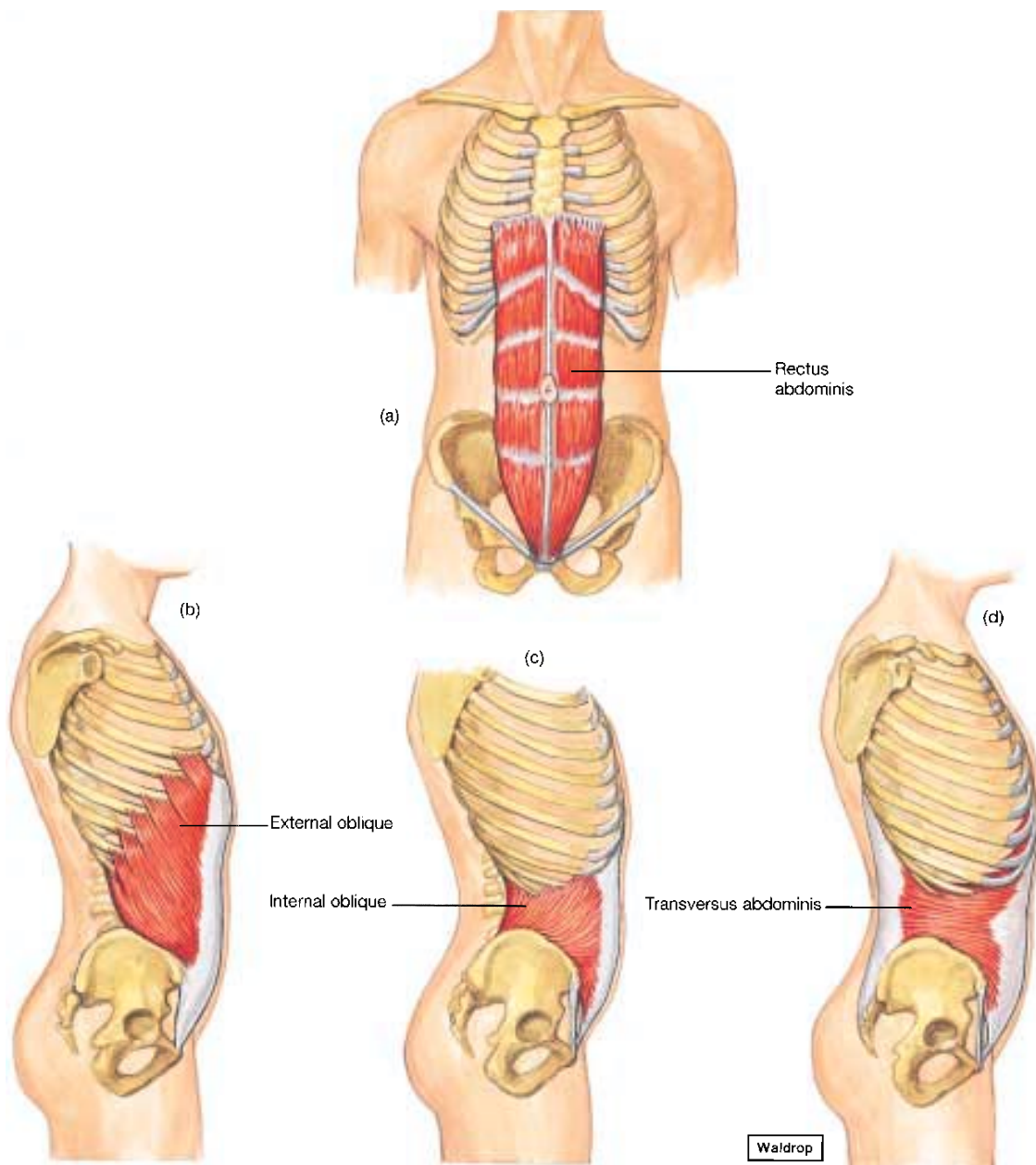


Figure 3-11
(a–d) Isolated muscles of the abdominal wall.

76 CHAPTER 3

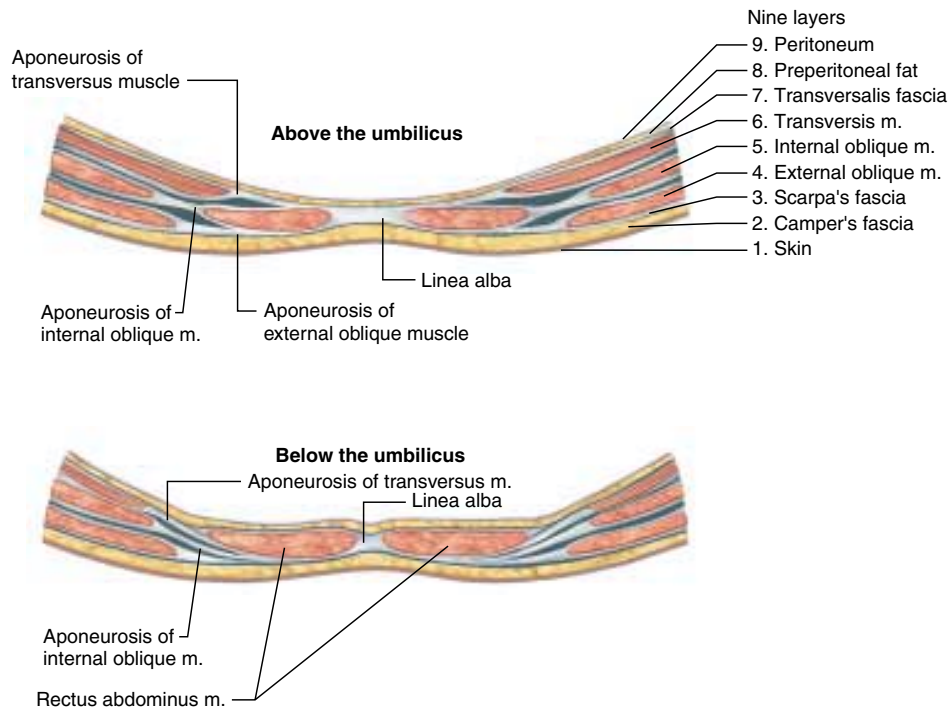


Figure 3-12
Muscles of the anterior abdominal wall, cross-sectional
view above the umbilicus.

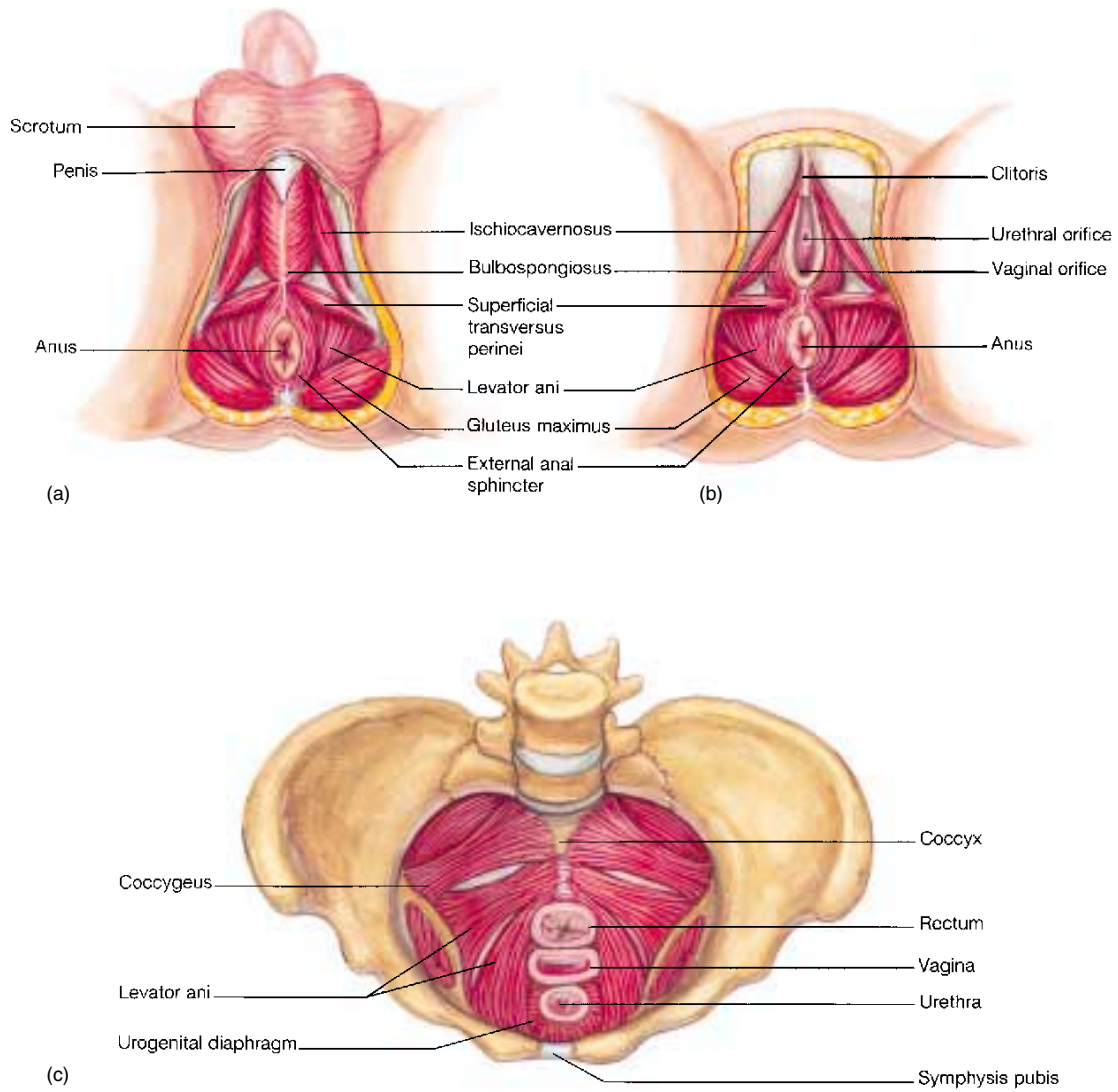


Figure 3-13

External view of muscles of (a) the male pelvic outlet, and (b) the female pelvic outlet. (c) Internal view of female pelvic and urogenital diaphragms.

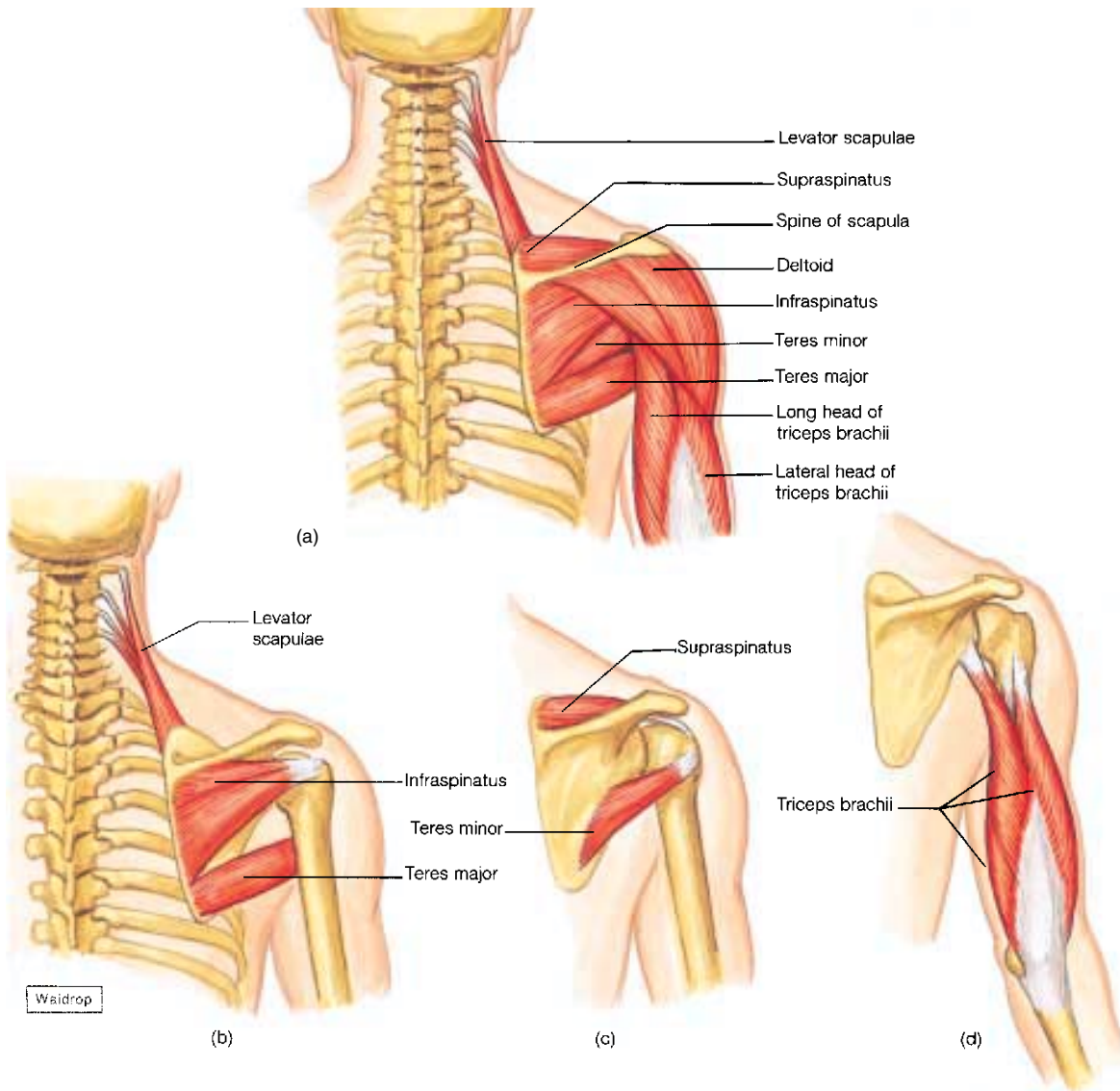


Figure 3-14

(a) Muscles of the posterior surface of the scapula and the arm; (b and c) muscles associated with the scapula. (d) Isolated view of the triceps brachii.

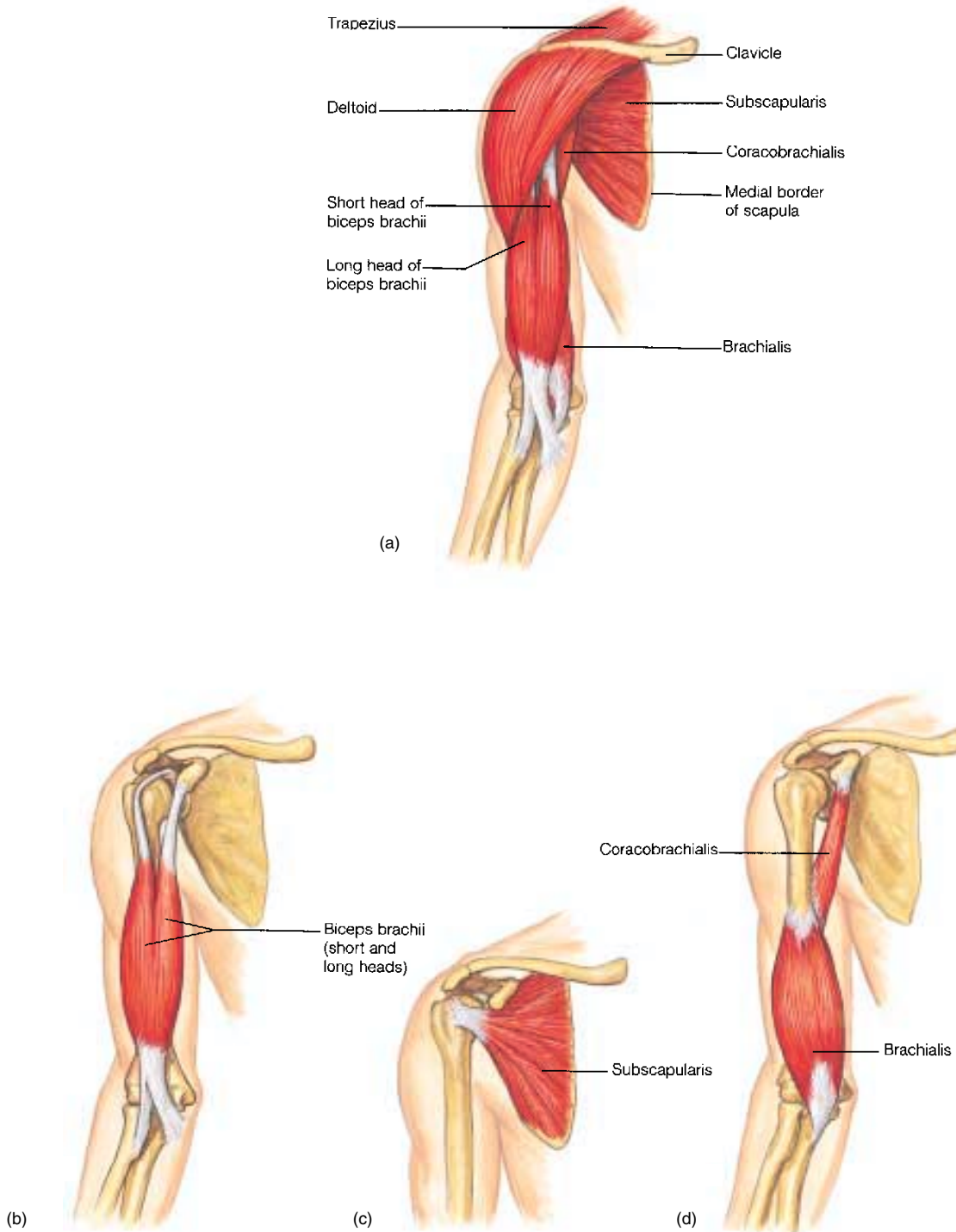


Figure 3-15

(a) Muscles of the anterior shoulder and the arm, with the rib cage removed. (b, c, and d) Isolated views of muscles associated with the arm.

80 CHAPTER 3

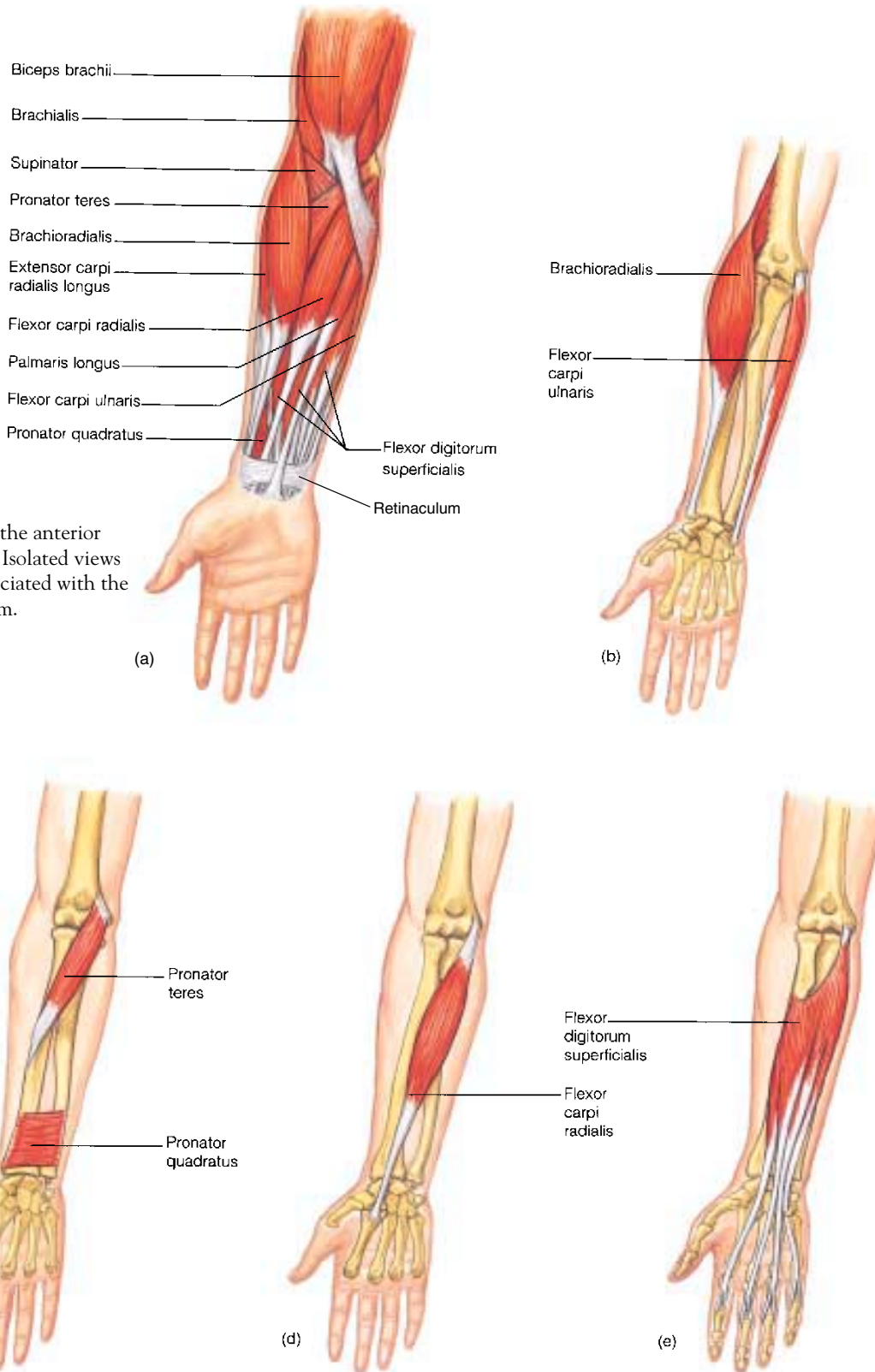


Figure 3-16
(a) Muscles of the anterior forearm. (b–e) Isolated views of muscles associated with the anterior forearm.

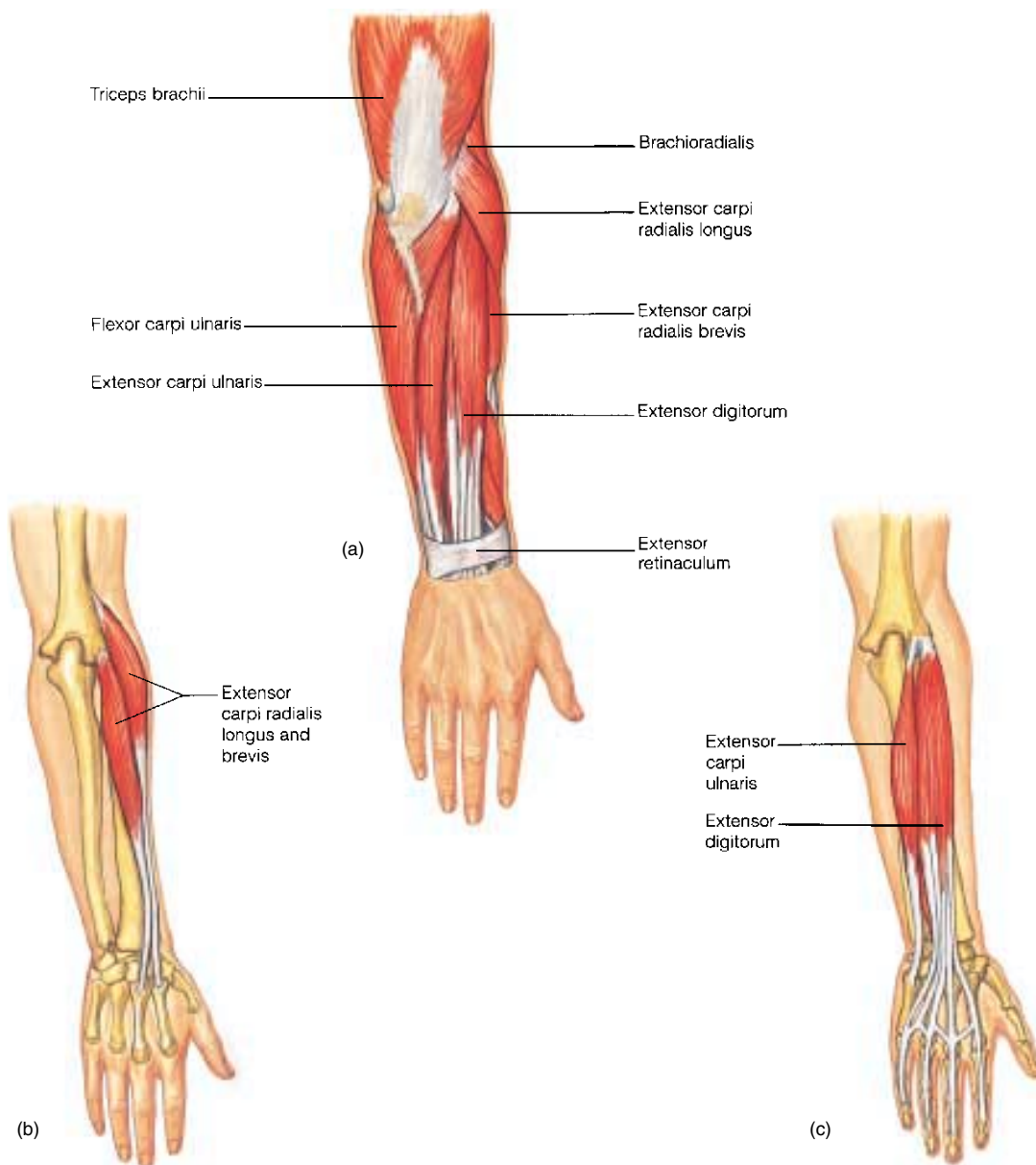


Figure 3-17

(a) Muscles of the posterior forearm. (b and c) Isolated views of muscles associated with the posterior forearm.

82 CHAPTER 3

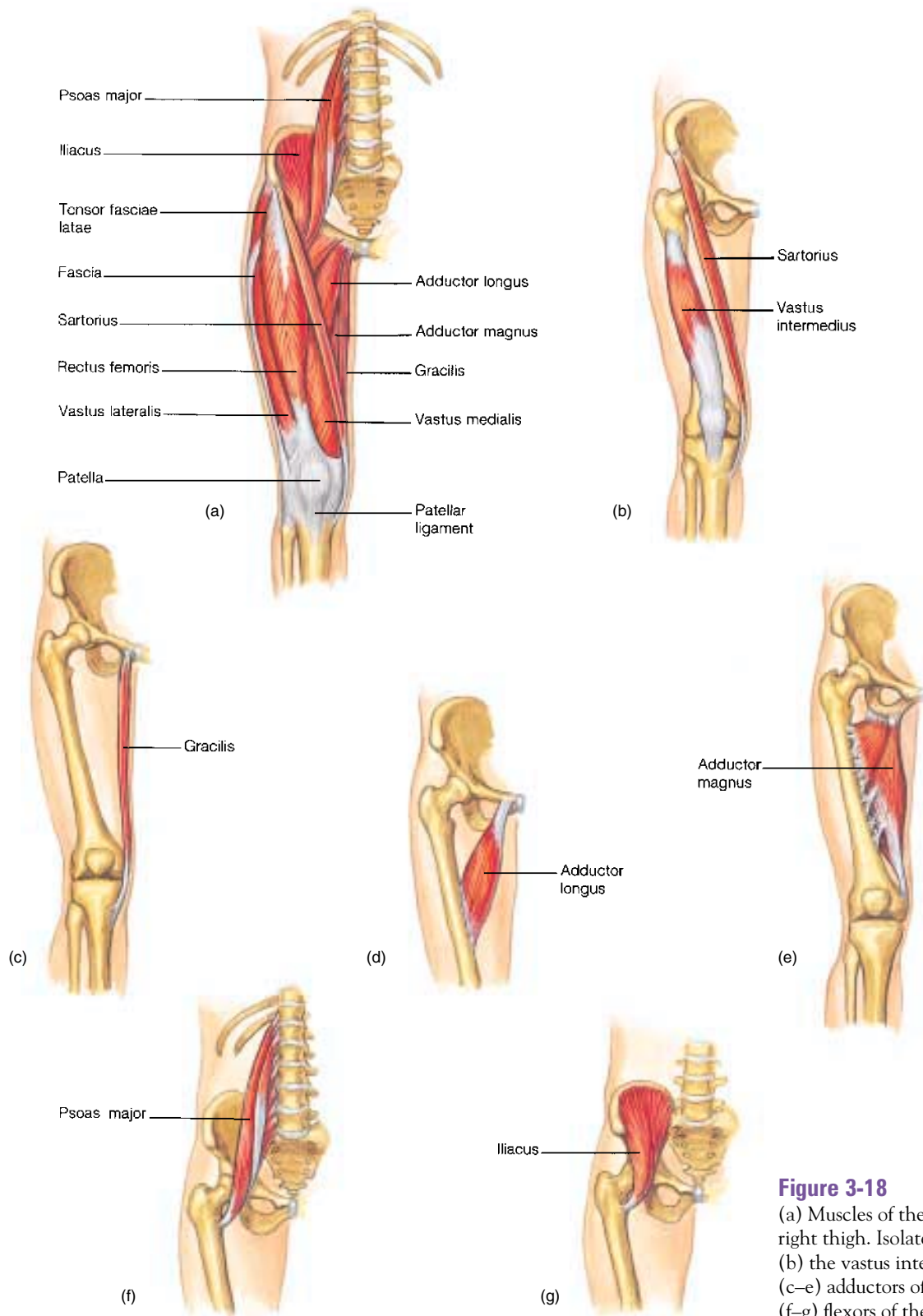


Figure 3-18
(a) Muscles of the anterior right thigh. Isolated views of (b) the vastus intermedius; (c–e) adductors of the thigh; (f–g) flexors of the thigh.

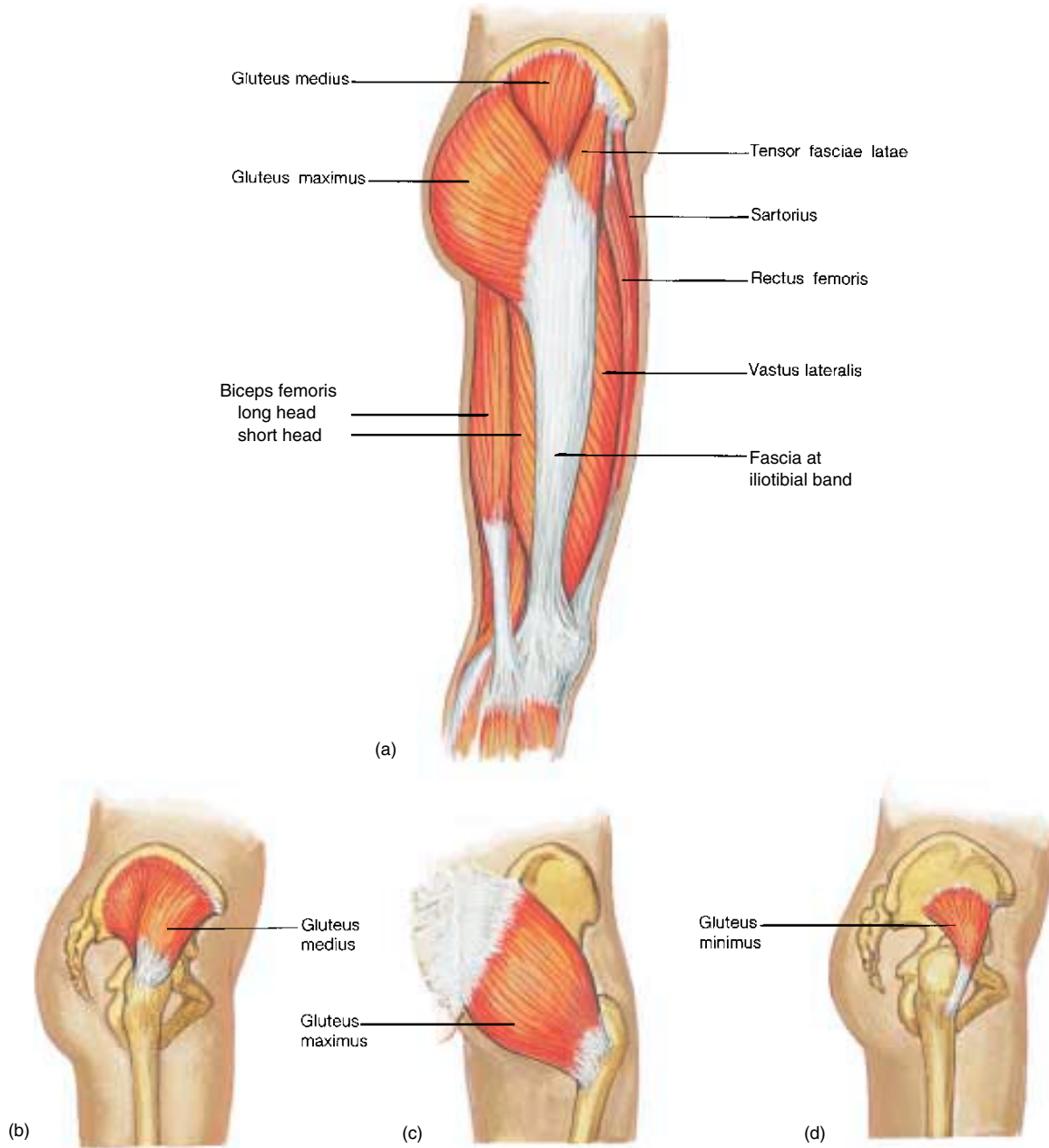


Figure 3-19

(a) Muscles of the lateral right thigh. (b–d) Isolated views of the gluteal muscles.

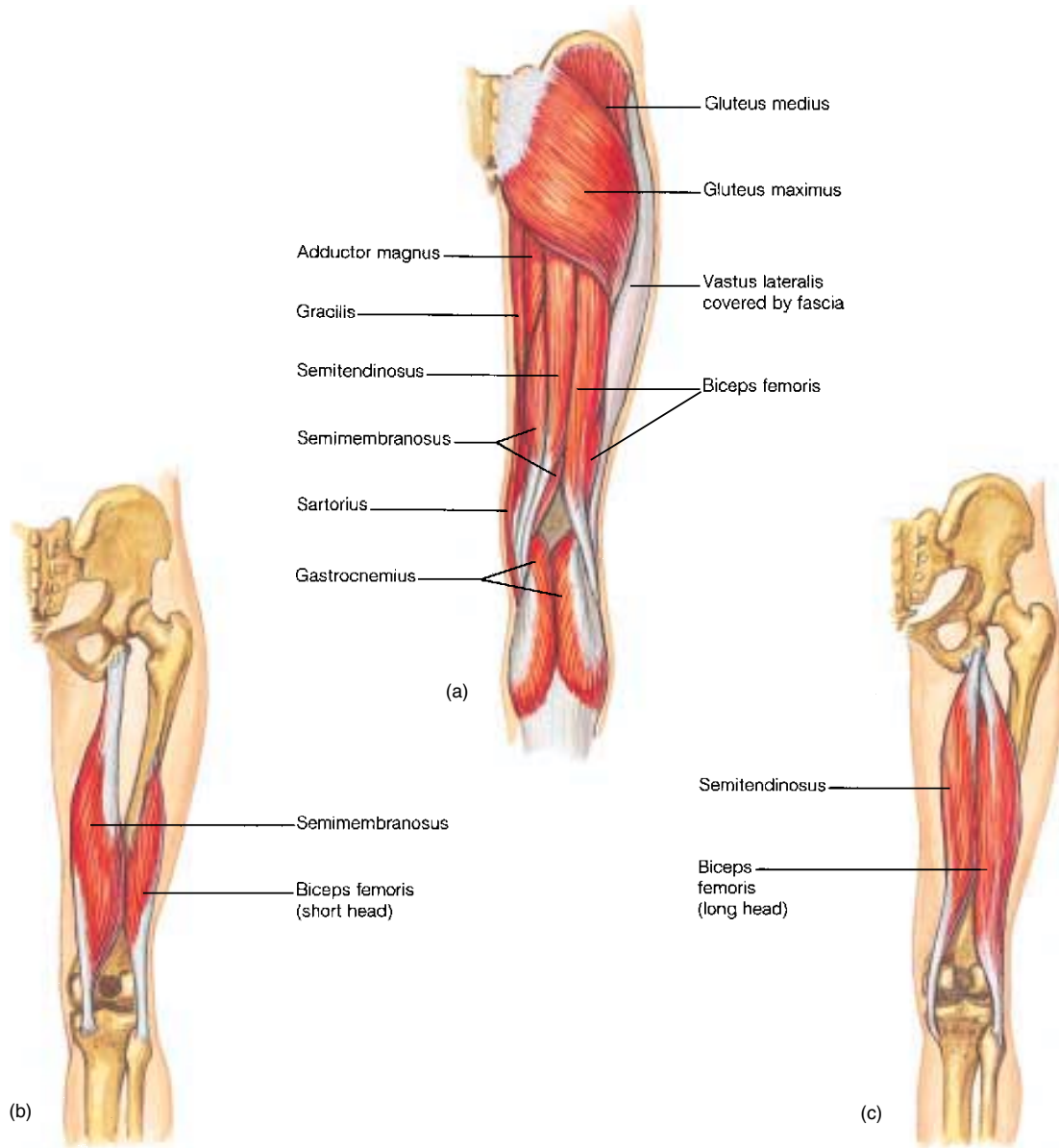


Figure 3-20

(a) Muscles of the posterior right thigh. (b and c) Isolated views of muscles that flex the leg at the knee.

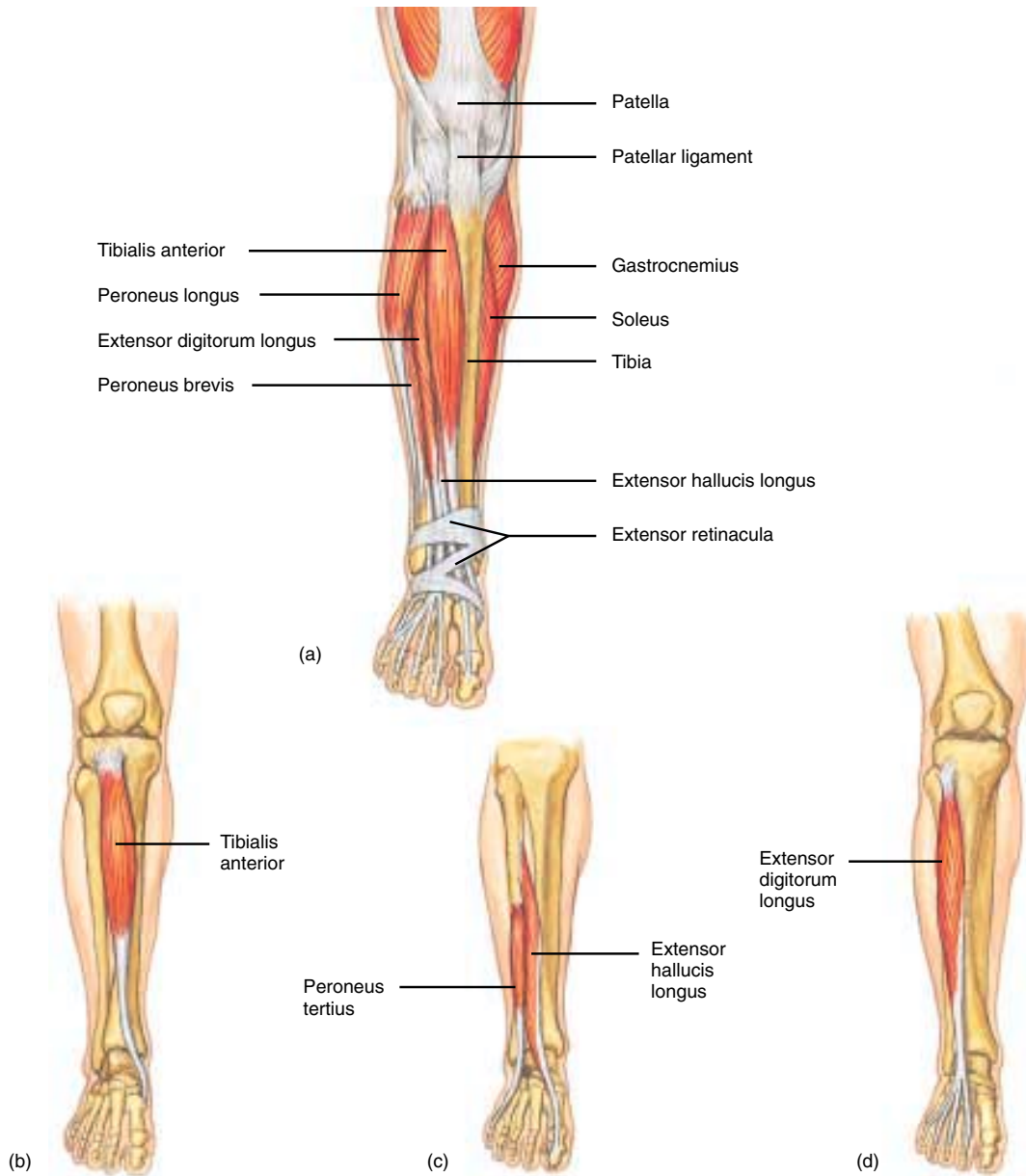


Figure 3-21

(a) Muscles of the anterior right leg. (b–d) Isolated views of muscles associated with the anterior leg.

86 CHAPTER 3

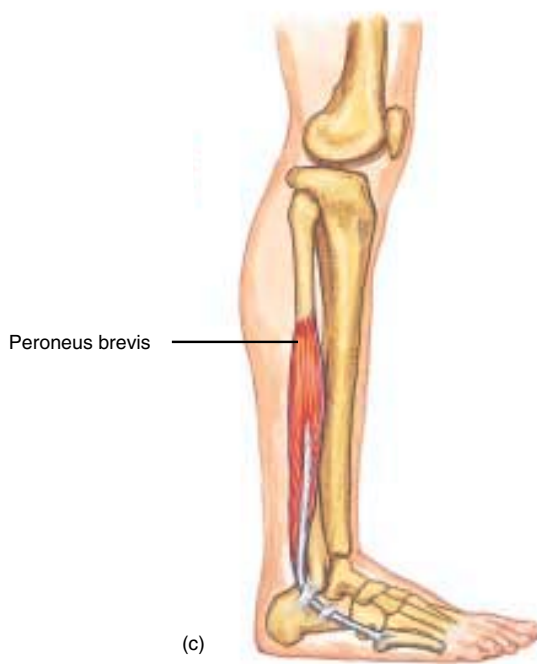
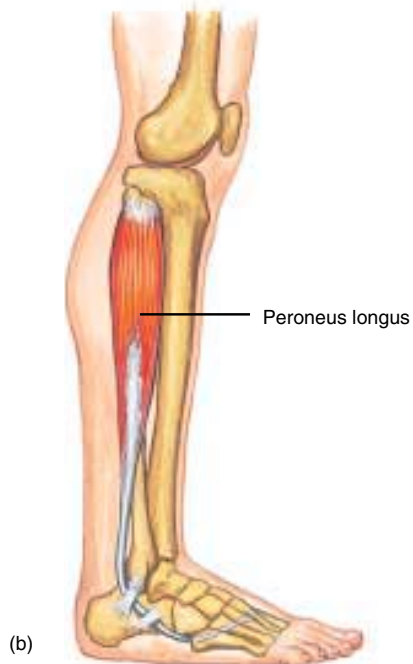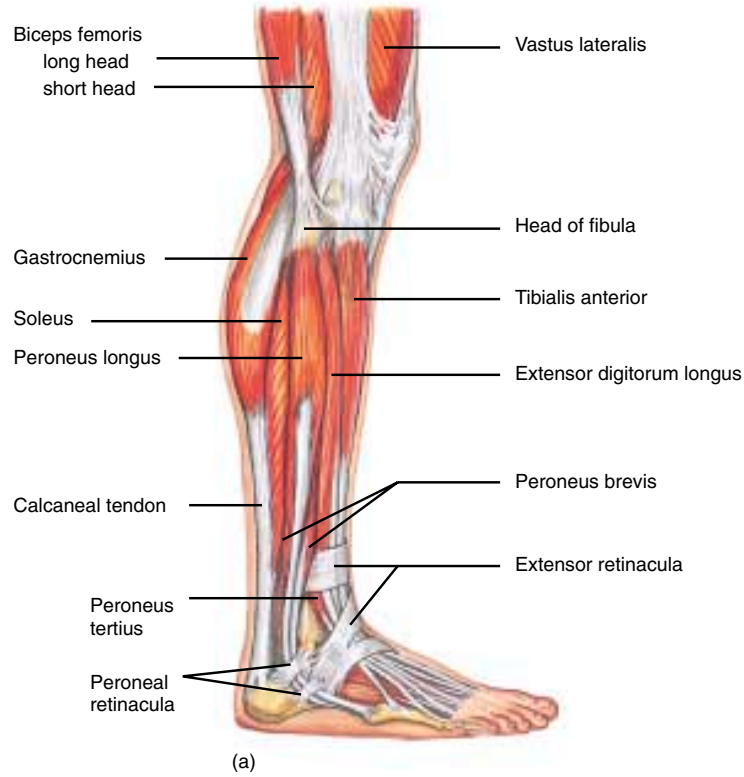


Figure 3-22

(a) Muscles of the lateral right leg. Isolated views of (b) peroneus longus and (c) peroneus brevis.

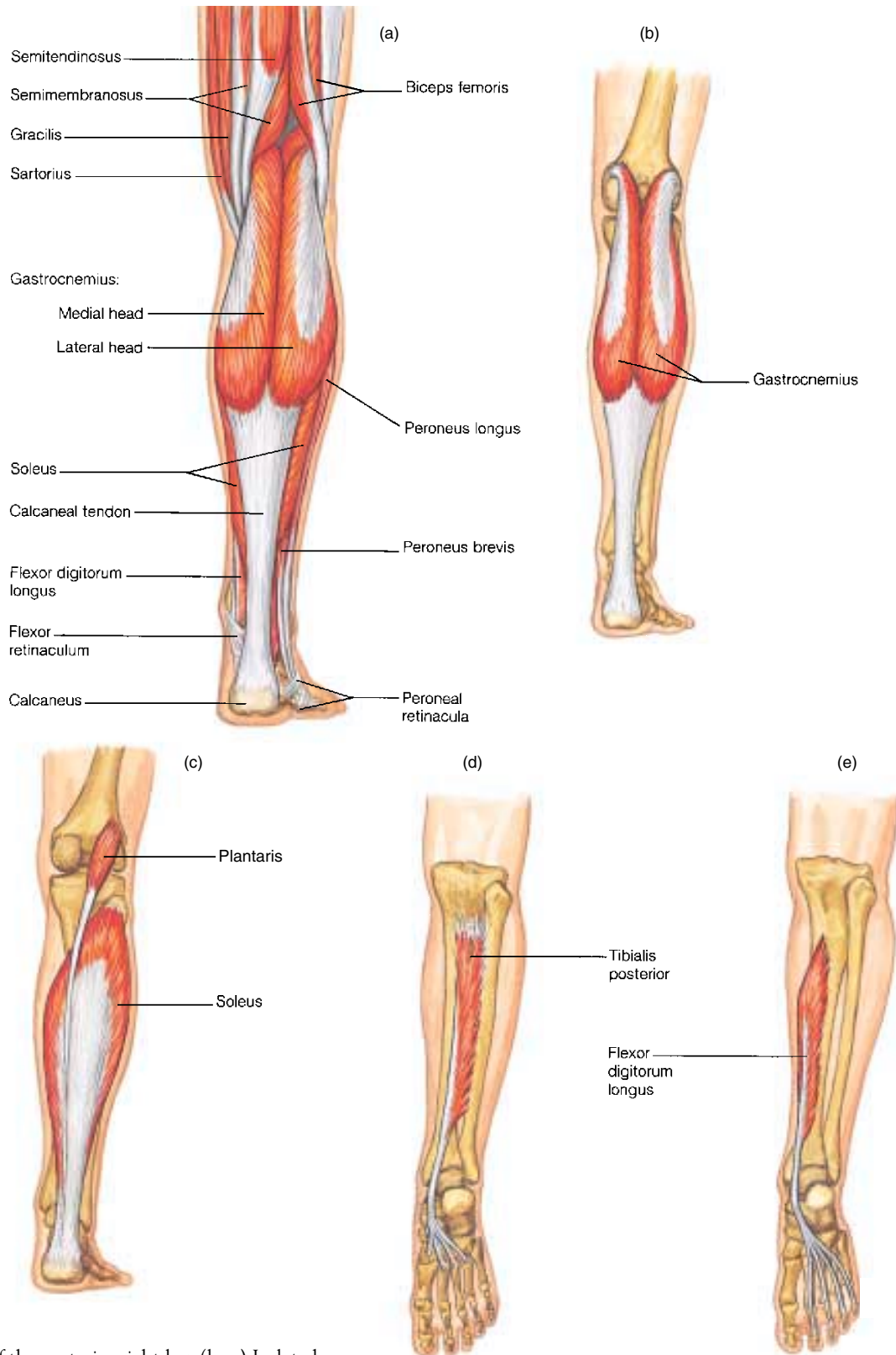


Figure 3-23
(a) Muscles of the posterior right leg. (b–e) Isolated views of muscles associated with the posterior right leg.

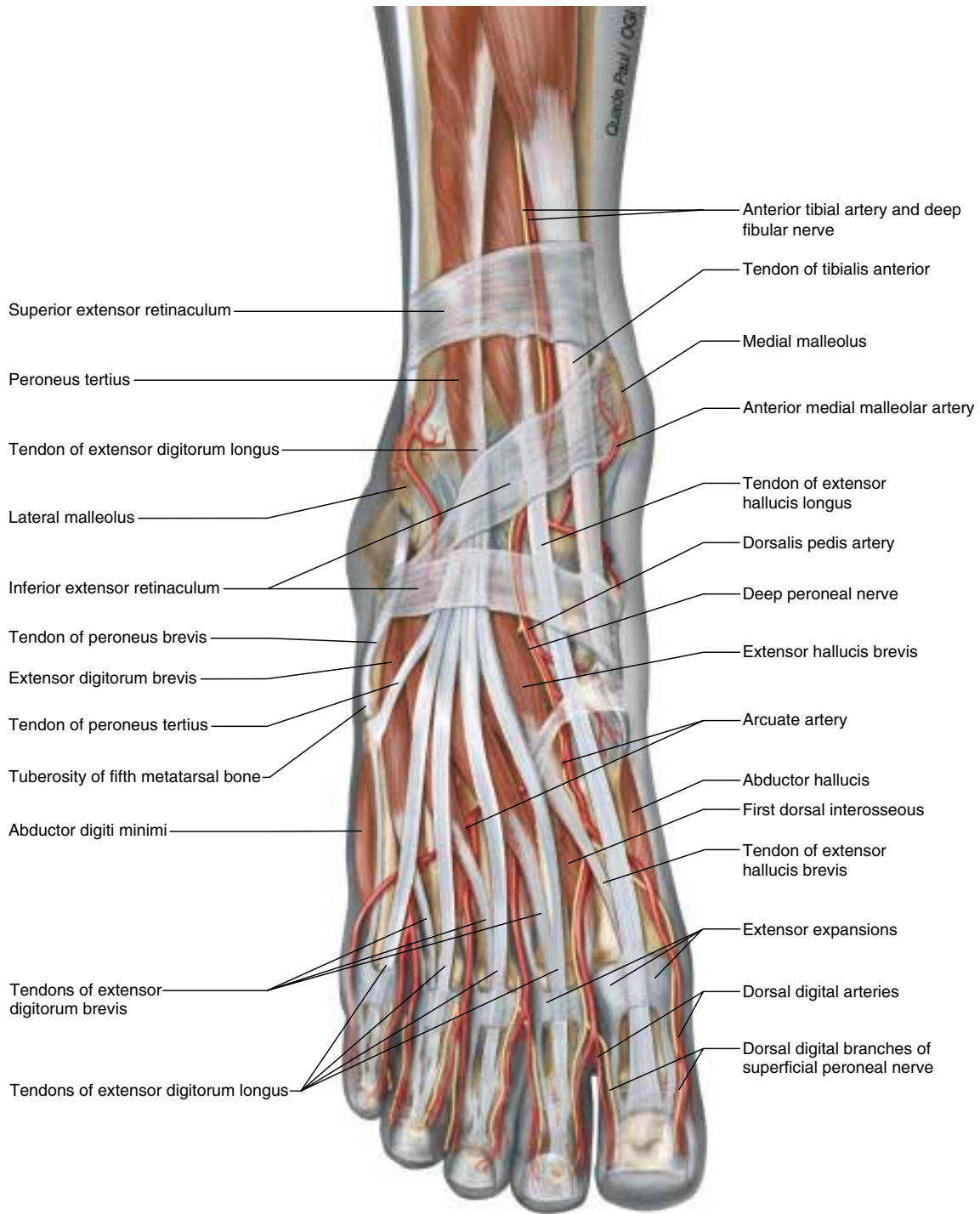


Figure 3-24
Dorsum of the foot, anterior view.