

Original Article

Percutaneous nephrolithotomy in children: A preliminary report

Ahmad A. Elderwy, Mohamed Gadelmoula, Mohamed A. Elgammal, Ehab Osama, Hamdan Al-Hazmi¹, H. Hammouda, Esam Osman, Medhat A. Abdullah, Khalid Fouda Neel¹

Department of Urology, Division of Pediatric Urology, Assiut University Hospitals, Assiut, Egypt, ¹Department of Surgery, Division of Urology, College of Medicine, King Saud University, Saudi Arabia

Abstract

Objectives: The recurrence of pediatric nephrolithiasis, the morbidity of repeated open surgical treatment as well as our experience in percutaneous nephrolithotomy (PNL) in adult patients, all derived us to shift to PNL for managing renal stones > 1.5 cm in pediatric patients. Our aim of this study is to evaluate the safety and efficacy of PNL in pediatric patients.

Materials and Methods: During the period of the month between May 2011 and April 2013, 38 children (47 renal units) underwent PNL for renal stones 1.5-5 cm in length. Patient demographics, stone characteristics, and clinical outcome were prospectively studied. Data of those who underwent conventional and tubeless PNL were compared. Median follow-up period was 12 months (range: 6-24).

Results: The median age at presentation was 8-year (range: 3-12). The operative time ranged from 30 to 120 min (median 90). Overall stone clearance rate was 91.5% after single PNL. The median hospital stay was 3 days. Auxiliary procedures were successful for the remaining 4 patients (nephroscopic clearance in one and shockwave lithotripsy in 3). Tubeless PNL was performed in 17 renal units with a comparable outcome to conventional ones. The perioperative complications were noted in 5/47 (10.6%) of all procedures (Clavien Grade II in 4 and Clavien Grade IIIa in 1) and were managed conservatively.

Conclusions: Percutaneous nephrolithotomy for renal stones in pediatric patients is safe and feasible if performed by a well-experienced endourologist. Tubeless PNL is a better choice for children.

Key Words: Nephrolithiasis, pediatric urolithiasis, percutaneous nephrolithotomy, tubeless percutaneous nephrolithotomy

Address for correspondence:

Dr. Ahmad A. Elderwy, Department of Urology, Division of Pediatric Urology, Assiut University Hospitals, Assiut 71515, Egypt. E-mail: ahmad.elderwy@gmail.com
Received: 24.04.2014, Accepted: 27.04.2014

INTRODUCTION

Pediatric nephrolithiasis is increasing globally and is endemic in developing countries. It is usually associated with urinary

tract infection (UTI), anatomical and metabolic abnormalities, together with climate and dietary factors. Therefore, nephrolithiasis in children has a high rate of recurrence; with an overall 5-year recurrence rate of 55% (95% confidence interval: 38-70%).^[1,2]

The treatment options for pediatric stones are shock wave lithotripsy (SWL), retrograde intrarenal surgery (RIRS), percutaneous nephrolithotomy (PNL) and open/laparoscopic stone surgery. The ideal treatment modality is that with high stone clearance rate and low morbidity. In view of this, SWL is generally preferred for renal stone <1 cm and PNL offers

Access this article online	
Quick Response Code:	Website: www.urologyannals.com
	DOI: 10.4103/0974-7796.134255

high stone clearance with low morbidity for upper urinary tract stones >1.5 cm.^[1,3]

Woodside *et al.* were the first to report successful PNL in a 14-year-old child in 1985. Afterwards, the procedure became more popular and was enforced by wider experience in adult PNL and miniaturization of the equipment. Nowadays, PNL has become the standard treatment for renal stones >1.5 cm in preschool-aged patients.^[3] Furthermore, a "mini-perc"/tubeless PNL technique has been introduced to reduce the morbidity of the standard PNL with comparable stone clearance.^[1,4] Herein, we introduce our early experience with PNL in managing pediatric stones and demonstrate the outcome of tubeless PNL in comparison to the standard one.

MATERIALS AND METHODS

The study was reviewed and approved by our institutional ethical review boards and informed consent was obtained from the family of each child. Between May 2011 and April 2013, a total of 38 children underwent PNL for renal stones in our hospitals. Nine patients had bilateral renal stones with a total of 47 PNL procedures performed. Patient, stone(s) and upper tract-related factors were recorded in a prospective database. Inclusion criteria included: Stone burden >1.5 cm with functioning renal unit, no UTI, no anatomical renal abnormalities and a minimum of 6 months follow-up postoperatively. Three patients had percutaneous nephrostomy tube (NT) inserted initially to drain infected hydronephrosis. Those with documented UTI underwent surgery 1-week after clearance of infection. For cases with bilateral stones, asynchronous procedures were performed.

Preoperative investigations in the form of urinalysis, renal function tests, complete blood count, coagulation profile, random blood sugar, abdominal ultrasonography (US), plain abdominal X-ray (kidneys, ureters, bladder [KUB]), noncontrast computerized tomography (NCCT) were done in all patients. Fifteen patients already had intravenous urography done outside our hospitals. Renal scan using ^{99m}technetium dimercapto-succinic acid (DMSA) was indicated for those with severe hydronephrosis and cortical thinning.

The procedure was started under general anesthesia (GA), with administration of intravenous broad-spectrum antibiotic 1 h before induction of GA. With the child in lithotomy position, an 8.5-French pediatric Storz cystoscopy was initially performed to place an ipsilateral 4- or 5-French ureteral catheter (UC). Later, the patient was placed in the prone position. Iodinated contrast media was injected through UC and the renal access was performed under fluoroscopic guidance. Tract dilatation was performed using graded dilators up to a 24-French and then an Amplatz sheath 20- or 24-French was introduced (according to surgeon

preference). A 17-French Wolf rigid nephroscope was used for all cases and a flexible 15-French nephroscope was available when indicated. Stones were fragmented with a pneumatic lithotripter and extracted by grasper. Number and location of access points, blood loss, hospitalization time, stone burden, stone clearance, and complications (according to the modified Clavien classification) were recorded.^[5] Success was defined if stones are totally removed without the need for an auxiliary procedure.

After confirmation of stone clearance fluoroscopically, UC was left in all cases. According to surgeon choice, a 14-French NT was left in the renal pelvis (conventional PNL) or not (tubeless PNL). For unreachable significant fragments (≥ 4 mm), the UC was replaced by double-J stent prior to SWL.

On postoperative day 1, documentation KUB (for radio-opaque stones) and US were performed. When the urine was clear, NT was to be removed by the 1st or 2nd postoperative day followed by UC removal 1-2 days later in case there was no leakage or fever. In tubeless PNL, UC was removed once the urine was clear with no leakage or fever. Stone analysis was performed for all cases. All patients were advised to take plenty of oral fluids and low-salt diet. For cystine stones, patients were maintained on potassium sodium hydrogen citrate 1 mEq/kg/day in 2-3 divided doses. For struvite/matrix stones, stone and urine cultures were done and patients were maintained on the appropriate antibiotics for 3 consecutive months. The follow-up visits were scheduled at 1, 3, 6, 12, 18 and 24 months postoperatively; where urinalysis and US were performed for all patients. Further management was individualized.

Statistical analysis was performed using inter-cooled STATA[®], version 9.2, Texas, USA. Analysis included; the Chi-square test or Fisher's exact test for comparison of the categorical data, and the Mann-Whitney U-test (values expressed as median, inter-quartile range) compare the noncategorical data.

RESULTS

A total of 25 boys and 13 girls, aged ranges between 3 and 12 years (median 8), underwent 47 PNL procedures. Right sided PNL was done for 21 cases. Previous ipsilateral open renal surgery for stones was recorded in 7 children. UTI (42%), hematuria (37%), and abdominal pain (21%) were the common presenting symptoms. Three units had already a NT access to drain an infected kidney. Radiolucent renal stones were detected in 10 patients. Stones were single in 42.5% (pelvic in 34%, in calyceal in 8.5%), multiple (pelvic and calyceal) in 49% and staghorn in 8.5%. HN was noted in 35 renal units, with severe HN detected in 6 (split renal function ranged from 10% to 24% in DMSA scan). No associated metabolic abnormalities were noted in any of the patients.

Stone length ranged from 1.5 to 5 cm (median 2.3). Only one subcostal access was established in each procedure using 20-Fr Amplatz in 13 patients and 24-Fr Amplatz in the rest. Access was gained through the lower posterior calyx in 39 units and through the middle calyx in 8. After completion of PNL, 17 procedures passed tubeless and the rest (30/47 patients) had a 14-French NT left in the renal pelvis [comparison between conventional and tubeless PNL is shown in Table 1]. The operative time ranged from 30 to 120 min (median 90). The median hospital stay was 3 days (range: 2-15).

As regards the stone clearance; 43 units were clear after the first session PNL. Nephroscopic clearance under GA through the same access tract was performed for one patient 2 days postoperatively. Single session SWL under GA was performed for 3 patients with unreachable fragments after 3-4 weeks in the presence of double-J stent. Accordingly, our initial stone-free rate (SFR) was 91.5% and cumulative SFR after auxiliary procedures was 100% at 3 months follow-up visit [Figures 1 and 2].

Overall complications were noted in 5/47 (10.6%) of patients; Clavien Grade II in 4 patients and Grade IIIa in 1 patient. Tubeless PNL was not associated with more complications/

auxiliary procedures than conventional PNL [Table 1]. There was no significant bleeding that necessitates transfusion in any except one case with staghorn stone. No case required open conversion. Two cases, with previously infected kidney and NT, suffered from postoperative high grade fever for 24 h in spite of absence of significant growth in urine culture from the NTs prior to PNL and they were managed conservatively. One case, with severe HN preoperatively, developed leakage of urine after removal of the UC (with no stone on postoperative NCCT) and resolved spontaneously by the 6th postoperative day. An 11-year-old girl had recurrent hematuria for 5 days after PNL, for which renal angiography was done and revealed no abnormalities. The patient was then treated conservatively.

Stone analysis was available for 42 procedures and revealed calcium oxalate in 15 (31.9%), uric acid in 7 (14.9%), struvite in 6 (12.7%), matrix in 3 (6.4%), cystine in 3 (6.4%) and mixed in the rest (27.7%). After a median follow-up period of 12 months (range: 6-24), all patients were stone-free; no recurrence or hydronephrosis was encountered.

DISCUSSION

Pediatric urolithiasis is usually associated with metabolic disturbances or UTI, which leads to multiple recurrences or with obstructive anomalies that necessitate reconstruction along with removal of the stone, hence the validity of PNL in treating such stones.^[1]

Percutaneous nephrolithotomy for pediatric renal stones >2 cm is associated with less hospital stay, less blood transfusion and less JJ stent implantation, compared with open surgery. Both techniques had comparable outcome.^[6] Moreover, pediatric PNL has higher stone-free and lower re-treatment rates for 1-2 cm renal stones, compared with SWL.^[7] When comparing PNL to RIRS for renal stones 1-3 cm, both have similar SFR and complication rate, although RIRS is associated with shorter operative time and hospital stay as well as no blood transfusion required.^[8] Further studies are still needed to confirm such benefits of RIRS. Our results are comparable to pediatric PNL in the literature; Table 2.^[9-17] Clinical Research Office

Table 1: Comparison of conventional versus tubeless PNL

Variable	Conventional PNL (n=30) %	Tubeless PNL (n=17) %	P
Age at presentation (years)	8 (6, 11)	8 (6, 9)	0.929
Sex: male	76.7	47.1	0.057
Laterality of stone (s): Right	40	52.9	0.391
Location of stone (s): Pelvic	40	23.5	0.449
Opacity of stone (s): Opaque	80	76.5	0.776
Stone (s) length (mm)	21 (18, 29)	25 (20, 27)	0.190
Ipsilateral previous open renal surgery	13.3	17.7	0.692
Preoperative urine cultures: Infected	30	58.8	0.069
Operative time (min)	90 (66, 108)	90 (75, 100)	0.938
Hospital stay (days)	4 (3, 4)	3 (2, 4)	0.067
SFR after first PNL	90	94.1	0.627
Overall complications			0.397
Clavien Grade II	6.7	11.8	
Clavien Grade IIIa	0	5.9	
Follow-up (months)	11 (8, 18)	14 (6, 18)	0.955

PNL: Percutaneous nephrolithotomy, SFR: Stone-free rate

Table 2: Outcomes of pediatric PNL in the literature

Report	Number of procedures	Mean age (years)	Mean stone burden (cm ²)/length (cm)	SFR after first PNL %	Complication rate %	Mean hospital stay (days)
Onal et al. ^[9]	1205	8.8	4.09	81.6	27.7	5.1
Samad et al. ^[10]	188	8.2	2.72	59.3	54.3	4.5
Holman et al. ^[11]	138	8.9	5.07	98.2	16.7	4.8
Güven et al. ^[12]	107	7.1	2.72	70.1	14	-
Bhageria et al. ^[13]	102	11.95	>2	83	23	-
Shokeir et al. ^[7]	82	6.6	1.44	95	4.9	3
Rizvi et al. ^[14]	62	-	4.7	67.7	59.6	4
Badawy et al. ^[15]	60	6	>1.5	83.3	18.3	3.9
Raza et al. ^[16]	43	6.4	4	79	32.6	-
Present study	47	7.9	2.4	91.5	10.6	3.9

PNL: Percutaneous nephrolithotomy, SFR: Stone-free rate

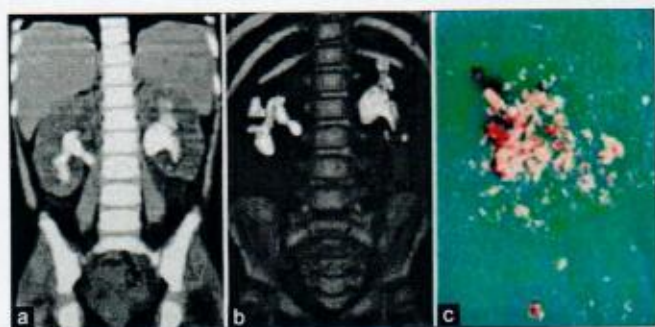


Figure 1: Non-contrast computerized tomography (a and b) and matrix calculi specimen after percutaneous nephrolithotomy (PNL) (c) of a 3-year-old girl with recurrent bilateral staghorn renal stones 3.8 cm on the right side and 4.5 cm on the left. She underwent successful eventless asynchronous bilateral tubeless PNL (1 month apart). Stone culture showed proteus mirabilis infection. The patient received prophylactic trimethoprim/sulfamethoxazole at dose of 2/10 mg/kg at bedtime for 3 months. No recurrence was noticed after 18 months of follow-up

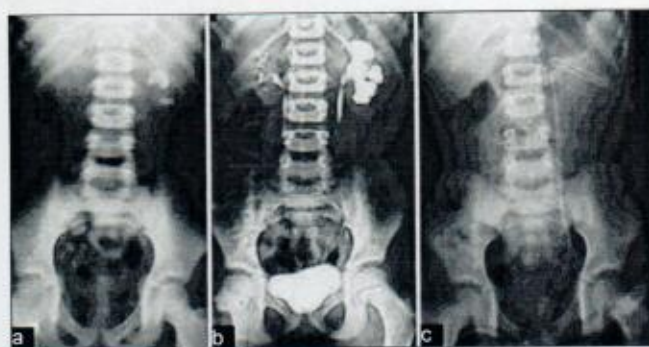


Figure 2: Kidneys, ureters, bladder (a), IVU after 30 min (b) and postoperative KUB (c) of a 12-year-old boy showing a 2.5-cm left renal pelvis stone and 7, 6 mm lower calyceal calculi. Non-contrast computerized tomography scan showed no retrorenal colon. Conventional percutaneous nephrolithotomy through the lower calyx was successfully done with smooth postoperative recovery. He was discharged from the hospital after 4 days

of the Endourological Society PNL Global Study showed that pediatric PNL has similar success and complication rates to those in adults in presence of appropriate evaluation, equipments and experience.^[12] Extended indications of PNL in children were addressed by Samad *et al.* to include those with anatomically abnormal kidneys, impaired renal function and synchronous bilateral PNL.^[10]

Regarding the age of the child at interference, many series stated the safety and efficacy of PNL in all pediatric age groups including infants.^[17] Although we routinely used NCCT, for preoperative evaluation of PNL for surgical planning and to exclude retrorenal colon (up to 4.4% in normally situated kidneys), some authors suggest that intravenous urography may be enough for those with no anatomical renal abnormalities or previous ipsilateral renal surgery.^[18] To minimize children exposure to radiation, we did postoperative NCCT in one case only with persistent urine leak after NT removal to exclude any migrating ureteral stones, otherwise KUB and US were used to define our SFR.

In our practice, we limited fluoroscopy time to the minimum. Alternatively, ultrasound guidance of pediatric PNL provides less radiation exposure, no adjacent organ injury, and equivalent outcome as fluoroscopic guidance.^[19] A single subcostal puncture was used in all of our cases. It was shown that supracostal PNL in children is similar to the subcostal ones, however the complication rate in the former (15-50%) is relatively higher.^[13,20]

Percutaneous nephrolithotomy in pediatric population was reported using either the adult-size or pediatric instruments with no significant difference in the clinical outcome.^[17,20] Although the smallest adult-size instrument (17-Fr rigid nephroscope) had been used in the current study with reasonable outcome, we recommend using the pediatric

instruments to minimize the potential impact on such growing kidneys, and to decrease the blood loss and painful incisions. Moreover, the operative time is not significantly longer with the use of pediatric nephroscopes. Ultra-mini-PNL using a novel 6-Fr mininephroscope through an 11-13 Fr metal sheath together with holmium: YAG laser lithotripsy is an interesting alternative for renal stones <2 cm.^[21] The nephrostomy-less and the totally tubeless PNL are increasingly practiced in the literature and reported to be safe and effective procedures for both adults and children; with a significant reduction of hospital stay and analgesic requirement.^[17,20,22] In our study, the outcomes of the nephrostomy-less and conventional PNL were comparable and hence tubeless PNL can be done safely for children.

Second-look PNL is getting more popularity among the endourologists, especially in adults where it is usually done under local anesthesia. On the contrary, it has to be done under GA in children.^[23] In our study, both SWL and nephroscopic clearance for residual stones were comparable, so decision for such cases should be individualized as both will be done under GA. Flexible ureteroscope (which was temporarily unavailable during our study period) and/or multiple puncture PNL can improve SFR and minimize auxiliary procedures.^[13,9]

As regards the complication of PNL in the pediatric population, many series stated that it is comparable to those in adults.^[12] In our study we had 10.6% with minor complications that were managed conservatively, which is acceptable as our early experience. According to the largest pediatric PNL study; a longer operative time, larger sheath size, mid calyceal puncture and partial staghorn stones were the predictors of complicated PNL on multivariate logistic regression analysis.^[9]

We did not notice any recurrence after our short follow-up (median 12 months) probably because of our

patients' adherence to the instructions and follow-up visits. The reported stone recurrence rate after pediatric PNL was 2.4-31.2% within a follow-up period of 0.5-11 years. This was usually related to re-growth of residual stone fragments, duration of follow-up and cystine stones.^[7,10,24]

CONCLUSION

We presented our initial experience of pediatric PNL. In our hands (after many years of practicing adult PNL), the procedure is quite safe and effective. With accumulating experience, we will be able to do tubeless PNL with earlier hospital discharge of our patients. Limitations of our study include the relatively small number of cases, lack of randomization and the short-term follow-up.

REFERENCES

1. Smaidone MC, Docimo SG, Ost MC. Contemporary surgical management of pediatric urolithiasis. *Urol Clin North Am* 2010;37:253-67.
2. Lao M, Kogan BA, White MD, Feustel PJ. High recurrence rate at 5-year followup in children after upper urinary tract stone surgery. *J Urol* 2014;191:440-4.
3. Jackman SV, Hedican SP, Peters CA, Docimo SG. Percutaneous nephrolithotomy in infants and preschool age children: Experience with a new technique. *Urology* 1998;52:697-701.
4. Helal M, Black T, Lockhart J, Figueroa TE. The Hickman peel-away sheath: Alternative for pediatric percutaneous nephrolithotomy. *J Endourol* 1997;11:171-2.
5. Ozden E, Mercimek MN, Yakupoglu YK, Ozkaya O, Sarikaya S. Modified Clavien classification in percutaneous nephrolithotomy: Assessment of complications in children. *J Urol* 2011;185:264-8.
6. Bayrak O, Seckiner I, Erturhan S, Duzgun I, Yagci F. Comparative analyses of percutaneous nephrolithotomy versus open surgery in pediatric urinary stone disease. *Pediatr Surg Int* 2012;28:1025-9.
7. Shokeir AA, Sheir KZ, El-Nahas AR, El-Assmy AM, Eassa W, El-Kappany HA. Treatment of renal stones in children: A comparison between percutaneous nephrolithotomy and shock wave lithotripsy. *J Urol* 2006;176:706-10.
8. Resorlu B, Unsal A, Tepeler A, Atis G, Tokatli Z, Oztuna D, et al. Comparison of retrograde intrarenal surgery and mini-percutaneous nephrolithotomy in children with moderate-size kidney stones: Results of multi-institutional analysis. *Urology* 2012;80:519-23.
9. Onal B, Dogan HS, Satar N, Bilen CY, Günes A, Ozden E, et al. Factors affecting complication rates of percutaneous nephrolithotomy in children: Results of a multi-institutional retrospective analysis by the Turkish pediatric urology society. *J Urol* 2014;191:777-82.
10. Samad L, Aquil S, Zaidi Z. Paediatric percutaneous nephrolithotomy: Setting new frontiers. *BJU Int* 2006;97:359-63.
11. Holman E, Khan AM, Flasko T, Toth C, Salah MA. Endoscopic management of pediatric urolithiasis in a developing country. *Urology* 2004;63:159-62.
12. Guven S, Frattini A, Onal B, Desai M, Montanari E, Kums J, et al. Percutaneous nephrolithotomy in children in different age groups: Data from the Clinical Research Office of the Endourological Society (CROES) Percutaneous Nephrolithotomy Global Study. *BJU Int* 2013;111:148-56.
13. Bhageria A, Nayak B, Seth A, Dogra PN, Kumar R. Paediatric percutaneous nephrolithotomy: Single-centre 10-year experience. *J Pediatr Urol* 2013;9:472-5.
14. Rizvi SA, Naqvi SA, Hussain Z, Hashmi A, Hussain M, Zafar MN, et al. Management of pediatric urolithiasis in Pakistan: Experience with 1,440 children. *J Urol* 2003;169:634-7.
15. Badawy H, Salama A, Eissa M, Kotb E, Moro H, Shoukri I. Percutaneous management of renal calculi: Experience with percutaneous nephrolithotomy in 60 children. *J Urol* 1999;162:1710-3.
16. Raza A, Turna B, Smith G, Moussa S, Tolley DA. Pediatric urolithiasis: 15 years of local experience with minimally invasive endourological management of pediatric calculi. *J Urol* 2005;174:682-5.
17. Bilen CY, Gunay M, Ozden E, Inci K, Sarikaya S, Tekgul S. Tubeless mini percutaneous nephrolithotomy in infants and preschool children: A preliminary report. *J Urol* 2010;184:2498-502.
18. Tepeler A, Sancaktutar AA, Taskiran M, Silay MS, Bodakci MN, Akman T, et al. Preoperative evaluation of pediatric kidney stone prior to percutaneous nephrolithotomy: Is computed tomography really necessary? *Urolithiasis* 2013;41:505-10.
19. Penbegül N, Tepeler A, Sancaktutar AA, Bozkurt Y, Atar M, Yildirim K, et al. Safety and efficacy of ultrasound-guided percutaneous nephrolithotomy for treatment of urinary stone disease in children. *Urology* 2012;79:1015-9.
20. Bilen CY, Koçak B, Kitirci G, Ozkaya O, Sarikaya S. Percutaneous nephrolithotomy in children: Lessons learned in 5 years at a single institution. *J Urol* 2007;177:1867-71.
21. Desai J, Zeng G, Zhao Z, Zhong W, Chen W, Wu W. A novel technique of ultra-mini-percutaneous nephrolithotomy: Introduction and an initial experience for treatment of upper urinary calculi less than 2 cm. *Biomed Res Int* 2013;2013:490793.
22. Istanbuluoglu MO, Cicek T, Ozturk B, Gonen M, Ozkardes H. Percutaneous nephrolithotomy: Nephrostomy or tubeless or totally tubeless? *Urology* 2010;75:1043-6.
23. Roth CC, Donovan BO, Adams JM, Kibar Y, Frimberger D, Kropp BP. Use of second look nephroscopy in children undergoing percutaneous nephrolithotomy. *J Urol* 2009;181:796-800.
24. Onal B, Dogan C, Citgez S, Argun B, Onder AU, Sever L, et al. Percutaneous nephrolithotomy in children with cystine stone: Long-term outcomes from a single institution. *J Urol* 2013;190:234-7.

How to cite this article: Elderwy AA, Gademoula M, Elgammal MA, Osama E, Al-Hazmi H, Hammouda H, et al. Percutaneous nephrolithotomy in children: A preliminary report. *Urol Ann* 2014;6:187-91.

Source of Support: Nil. **Conflict of Interest:** None.