

***Andrographis paniculata* Aqueous Extract Shows Anti-Ulcerogenic Effects in Rats Via Modulation of Anti-Oxidant System**

Badr A. Al-Dahmash*

Department of Zoology, College of Science, King Saud University, Riyadh 11451, P.O. Box 2457, Kingdom of Saudi Arabia

Abstract.- Despite the manifold health benefits of *Andrographis paniculata*, less information available on its anti-ulcer potential. This study reports an evaluation of *in vivo* anti-ulcerogenic and anti-oxidant potential of aqueous extract of *A. paniculata* (APA) in experimental gastric ulcer rats. Male Wistar rats pretreated with (500 and 1000 mg/kg bw) of APA were separately exposed to ethanol (EtOH) (80%), saline (NaCl) (25%) and indomethacin (IM) (30 mg/kg bw). The effects of APA on gastric tissues were analyzed in terms of ulcer score (US), malondialdehyde (MDA), total proteins, non-protein sulfhydryl (NP-SH) estimation and histological changes. Oral administration of APA both at its lower (500 mg/kg bw) and higher (1000 mg/kg bw) doses significantly ameliorated the concentration of MDA, total proteins and NP-SH in EtOH, IM and NaCl-induced ulcers. Ulcers in EtOH and NaCl treated groups were significantly reduced to 1.8 and 4.1-fold after APA (1000 mg/kg bw) pretreatment. Histological analysis reaffirmed the protective effect of APA by showing mild congestion and mucosa damage in APA pretreated rats, as compared to severe tissue damages in three ulcer models. The protective effect of APA on EtOH and NaCl induced ulcer was probably due to modulation of antioxidant activity. This might be due to the presence of flavonoids, diterpine and andrographolides in APA.

Keywords: *Andrographis paniculata*, anti-ulcerogenic, gastric ulcer, malondialdehyde, non-protein sulfhydryl.

INTRODUCTION

Andrographis paniculata (Burm. f. Nees Syn: Kalmegh, Acanthaceae) is abundantly found in Asian countries (China, Thailand, India, Sri Lanka and Pakistan) (Huidrom and Deka, 2012). *A. paniculata*, has been extensively used as a herbal remedy for the treatment of several diseases like malaria, anti-inflammation, diarrhoea, hepatoprotection, diabetes, anti-HIV and cancer (Najib *et al.*, 1999; Shen *et al.*, 2002; Gupta *et al.*, 1990; Handa and Sharma, 1990; Pekthong *et al.*, 2009; Syahrin *et al.*, 2006; Calabrese *et al.*, 2000; Zhou *et al.*, 2006). These health benefits have been attributed to the presence of excellent chemicals constituents (diterpenedimers, flavonoids and xanthenes) in *A. paniculata* (Koteswara *et al.*, 2004; Dua *et al.*, 2004). Nonetheless, the main constituents of *A. paniculata* includes andrographolide and 14-deoxy11, 12-didehydroandrographolide (Koteswara *et al.*, 2004; Suebsasana *et al.*, 2009). More than twenty different

types of other constituents are also reported from *A. paniculata* (Shen *et al.*, 2006). Studies revealed that *A. paniculata* stimulates both antigen-specific and non-specific immune responses (Puri *et al.*, 1993). In addition, *A. paniculata* plant extract exhibited its anti-cancer properties in clinical trials (See *et al.*, 2002). In comparison with standard antibiotics, *A. paniculata* showed significant antibacterial and antifungal activities (Singha *et al.*, 2003).

In vitro data suggested that andrographolide might lower plasma glucose by increasing glucose uptake in cultured myoblast cells via the phospholipase C/protein kinase C pathway (Hsu *et al.*, 2004). *A. paniculata* was also found to possess antipyretic activity in *in vivo* test models (Handa and Sharma, 1990; Rana and Avadhoot, 1991; Mandal *et al.*, 2001). It might be good combination with nonsteroidal anti-inflammatory drugs (NSAIDs) since this plant possess anti-inflammatory activity through a mechanism that is very different from NSAIDs ones. *A. paniculata* may involve promoting ACTH production and enhancing adrenal function (Amroyan *et al.*, 1999). This raises the chance of using this plant alone or in combination with NSAIDs in treatment of inflammatory disorders.

Reactive oxygen species (ROS) play a crucial

* Corresponding author: baldhmash@ksu.edu.sa
0030-9923/2015/0005-1475 \$ 8.00/0
Copyright 2015 Zoological Society of Pakistan

role in triggering the pathogenesis of different human diseases including gastric ulcer diseases (Handa and Sharma, 1990; Pekthong *et al.*, 2009). Several studies have demonstrated that the endogenous anti-oxidant defense enzymes play a vital role in scavenging ROS and other free radicals produced from the action of factors that damage the stomach (Nartey *et al.*, 2012). Beside the inhibition of gastric H⁺, K⁺-ATPase and the elimination of *H. pylori* using antibiotics, scavenging of ROS and the stimulation of the endogenous anti-oxidant enzymes in the stomach has gained considerable interest (Nartey *et al.*, 2012). Though studies supported the use of *A. paniculata* in treatment of many disorders, however, there is no study available to elucidate the gastric safety of this product when taken orally in its natural form (aqueous extract) particularly in patients suffering from gastritis or gastric ulcers (especially those induced by using analgesics in treatment of inflammatory disorders). Therefore, this study is designed to investigate the effect of aqueous extract of *A. paniculata* on rats normal and stomach exposed to analgesics (indomethacin), irritant substances such as concentrated salt solution or necrotizing agent (ethanol).

MATERIALS AND METHODS

Solvents and reagents

Formaline and ethanol were purchased from Fluka[®] (Germany). Omeprazole 40 mg (Operazol[®]) and indomethacin 20 mg (Indocid[®]) were purchased from local pharmacy of Riyadh, KSA. Bovine serum albumin, copper sulphate and Folin-Ciocalteu reagent solutions were purchased from Crescent[®] Diagnostic, Jeddah, Saudi Arabia.

Plant extract and drug preparation

A. paniculata was purchased from local market of Riyadh, KSA and authenticated by the Department of Botany, College of Science, KSU. Aerial parts of the plant were dried, powdered, macerated in cold water (200 gm/600 ml water), filtered, and stored in a cool place. *A. paniculata* aqueous extract (APA) 500 mg/kg bw as low dose and 1000 mg/kg as high dose was used for pretreating the animals. Omeprazole (OP) and

Indomethacin (IM) were suspended in carboxymethyl cellulose (1%) to yield final concentration of 10 mg/ml. Sodium chloride (NaCl) solution was prepared by solubilizing 25 g crystalline NaCl in 100 ml distilled water to yield 25% NaCl solution. Ethanol (95%) was diluted to 80% in distilled water and used for the experiments.

Treatment of animals

Male Wistar rats weighing 200 ± 25 g were procured from the animal care center (College of Pharmacy, King Saud University, Riyadh). All animals were fed on Purina Chow diet as normal diet and water *ad libitum*. The animals were maintained under controlled temperature, humidity and automated light cycles (12 h light, 12 h dark). All experiments on animals were carried out according to the guidelines of the Animal Care and Use Committee of College of Science, King Saud University.

Animal exposure to narcotizing agents (EtOH and NaCl)

Rats were exposed to EtOH to induce lesions following the method of Morimoto *et al.* (1991), whereas NaCl-induced-lesions were produced following Rafatullah *et al.* (1995). In brief, a total 24 rats were randomly divided into 4 groups, each with 6 rats. Before the start of experiment, all animals were fasted for 24 h with free access to water and pretreated with 500 and 1000 mg/kg bw of APA for 1 h. Ethanol (80%) (2 ml) and 25% NaCl (2 ml), were orally administered to the animals, which had been previously treated orally with the APA, and separately treated with OP (40 mg/kg bw), as drug control. After 1h of EtOH and NaCl treatment, all animals were killed by cervical dislocation in the anesthetic stage, and the stomach were removed and cleaned from attached tissues. For histological investigation, stomach was stored in 10% formalin solution. For scoring the lesions, stomach were cut longitudinally through the greater curvature and the extent of the lesions were measured. The lesions index was expressed as the sum of all lesions. Results were expressed as an ulcerative index (UI) as described by Szelenyi and Thiemer (1978).

IM induced ulcer

A total of 24 rats, divided randomly into 3 groups each with 8 rats were fasted for 24 h before the start of experiment, with free access to water only. All animals were pretreated with 500 and 1000 mg/kg bw of APA for 1h followed by oral exposure of rats with single dose (30 mg/kg bw) of IM (Bhargava *et al.*, 1973). OP (40 mg/kg body wt) was used to separately treat the animals as standard drug control. After 6 h of IM administration, all animals were killed, stomachs were removed and cleaned from attached tissues. For histological investigation the stomach was fixed in 10% formalin. Longitudinal sections were cut through the greater curvature, and the lesions were measured and scored as discussed above.

Estimation of MDA

MDA level was estimated according to the method reported by Utley *et al.* (1967). In brief, the stomach tissues were removed and homogenized in 0.15 M KCl (at 4°C) using Potter-Elvehjem^R type C homogenizer to give a 10% w/v homogenate. Aliquots of homogenate (1 ml) were incubated at 37°C for 3 h in a shaker. Then 1 ml of 10% aqueous trichloroacetic acid (TCA) was added and mixed. The mixture was then centrifuged at 3000 rpm for 10 min. One ml of the supernatant was removed and mixed with 1 ml of 0.67% thiobarbituric acid in water and placed in a boiling water bath for 10 min. The mixture was cooled and diluted with 1 ml distilled water. The absorbance of the solution was then read at 535 nm. The content of MDA (nmole/g stomach wet tissue weight) was then calculated, by reference to a standard curve of malondialdehyde solution.

Estimation of total proteins

Total of protein was measured following the method of Lowry *et al.* (1951).

Estimation of non-protein sulfhydryl (NP-SH)

Non-protein sulfhydryl's of stomach wet tissue) was measured according to the method of Sedlak and Lindsay (1968). Briefly, the stomach was homogenized in ice-cold 0.02 mmol/L EDTA solution. Aliquots of 5 ml of the homogenates were mixed in 15 ml test tubes with 4 ml of distilled

water and 1 ml of 50% TCA. The tubes were shaken intermittently for 10 min and centrifuged at 3000 rpm. Supernatant (2 ml) was mixed with 4 ml of 0.4 mol/L Tris buffer (pH 8.9). 5, 5'-dithio-bis (2-nitrobenzoic acid) (DTNB) (0.1 ml) was added and the sample was mixed properly. The absorbance was measured within 5 min of addition of DTNB at 412 nm against a reagent blank.

Histological study

Formalin-fixed stomach samples were processed for histological studies. Tissue sections (6-8 µm thick) were stained with Giemsa stain and investigated under microscope for tracing any morphological changes.

Statistical analysis

The results were presented as mean ± standard deviation (S.D). Statistical differences were analyzed using ANOVA with Tukey's test, with $p < 0.05$ was considered statistically significant (Daniel, 1995).

RESULTS

Effect of APA on normal gastric mucosa

None of the animals showed the gastric ulcer with both doses (500 and 1000 mg/kg bw) of APA treatment. In addition, the NP-SH, MDA and total protein levels in APA treated rats were also found similar to those of control rats (Table I). The histological analysis of the APA treated animals further validated the no effect APA treatments in gastric mucosa (Fig. 1).

Effect of APA on EtOH induced gastric ulcer

Compared to the EtOH control, the highest concentration of APA (1000 mg/kg bw) treated rats showed 1.8-fold reduction in gastric ulcer count (Table II). Relative to the enhanced MDA level in EtOH treated groups, MDA level in both APA (500 and 1000 mg/kg bw) treated groups were significantly declined to 1.3 and 2.6-fold, respectively. Furthermore, APA treatment (1000 mg/kg bw) also resulted in 1.6 and 2.2-folds greater level of total protein and NP-SH in EtOH treated rats (Table II). Tissue sections of EtOH treated groups showed severe ulceration with marked

Table I.- Effect of APA on ulcer count, MDA, protein and NP-SH of normal gastric mucosa of rats.

Treatment	Dose (mg/kg bw)	Ulcer count	MDA (nmol/g)	Protein (g/l)	NP-SH (nmol/g)
Control	0	N.D	2.61±0.27	92.36±6.50	0.71±0.13
APA	500	N.D	2.72±0.16	84.07±5.80	0.77±0.15
APA	1000	N.D	2.67±0.33	93.57±8.69	0.76±0.12

Values are mean ± SD of 6 animals. $P>0.05$ vs control. Statistical significance was determined by ANOVA (Tukey's post hoc t test), N.D; Not detected.

Table II.- Effect of APA pretreated rats on EtOH- NaCl- induced and IM- induced ulcers and biochemical parameters.

Treatment	Dose (mg/kg bw)	Ulcer count	MDA (nmol/g)	Protein (g/l)	NP-SH (nmol/g)
EtOH induced					
EtOH (80%)	2 ml/rat	7.4±0.4	4.01±0.45	31.27±5.91	1.86±0.40
Omperazole	40	2.33±1.03	0.41±0.08***	97.80±3.23***	4.14±0.23***
APA	500	4.83±1.08	2.94±0.21*	33.15±3.77	3.40±0.31*
APA	1000	4.00±0.97	1.51±0.18**	52.63±4.20*	4.24±0.37***
NaCl induced					
NaCl (25%)	2 ml/rat	4.83±0.87	8.64±1.518	34.76±4.82	1.35±0.30
Omperazole	40	2.83±1.08	0.76±0.13***	104.6±3.79***	4.59±0.36***
APA	500	3.67±0.61	4.33±0.37**	54.17±3.13	2.89±0.24**
APA	1000	1.17±0.98**	2.29±0.19**	74.22±5.75***	3.03±0.28**
IM induced					
IM	30	4.0±0.37	5.70±0.97	30.74±4.57	1.89±0.35
Omperazole	40	N.D	0.34±0.08***	97.80±4.34***	3.14±0.25***
APA	500	4.67±0.72	3.24±0.58*	48.21±4.30*	2.66±0.46*
APA	1000	4.17±0.54	1.18±0.28***	69.02±6.54***	3.67±0.46*

* $P<0.05$, ** $P<0.01$, *** $P<0.001$ compared to EtOH control by ANOVA (Tukey's post hoc t test). Values are mean ± SD of 6 animals.

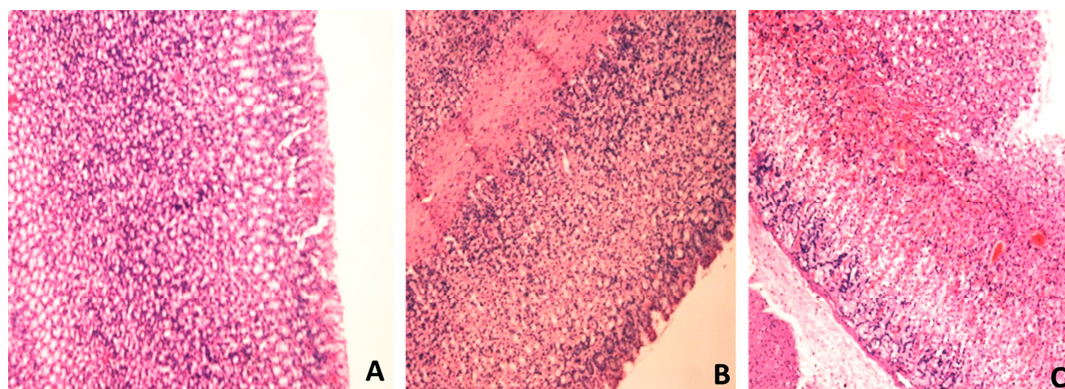


Fig. 1. Effect of APA on the histology of untreated rat stomach. In the acute toxicity study, and compared to the Normal mucosa (A), no deaths or toxic symptoms were observed during the test period in both group of rats treated with APA 500 mg/kg bw (B) and treated with APA 1000 mg/kg bw (C).

degenerative changes of the villi and hemorrhage (Fig. 2 B). While, APA low dose treatment of 500 mg/kg bw ameliorated the EtOH induced damage to

starting degenerative changes in the superficial mucosa (Fig. 2C). Furthermore, the higher dose of APA treatment (1000 mg/kg bw) restricted the

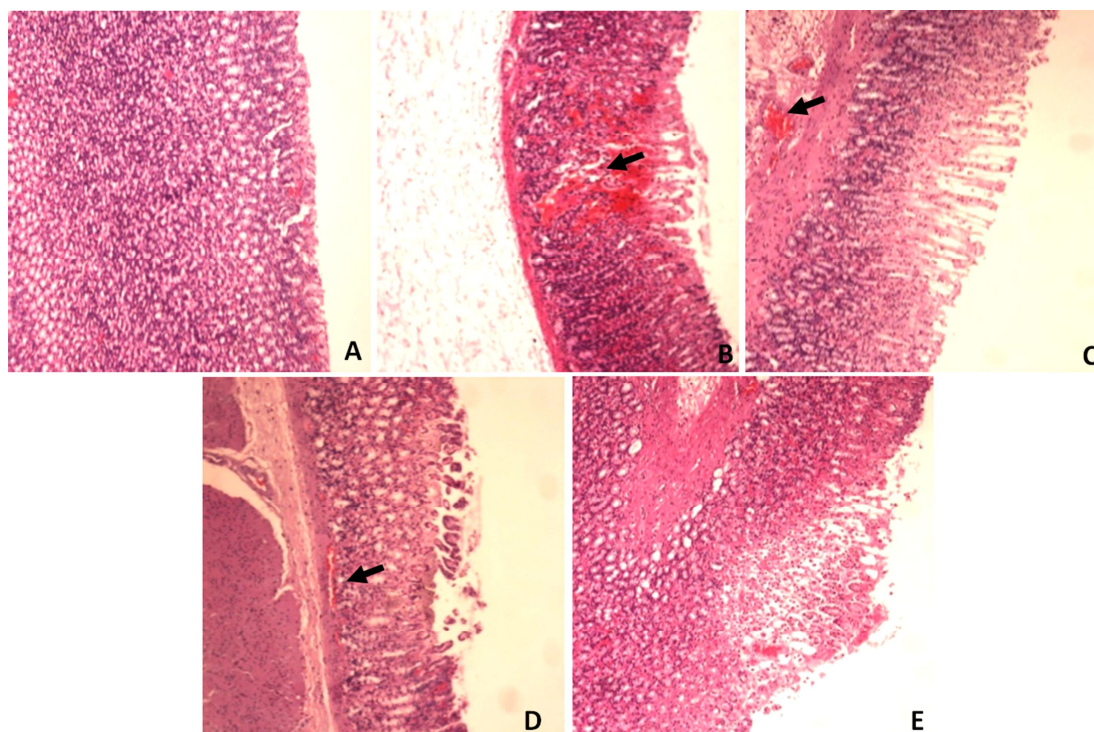


Fig. 2. Effect of APA treatments on the histology of EtOH treated rats. (A) Untreated control of a normal stomach, (B) The group treated with EtOH (80%), there were severe injuries in the gastric mucosa including haemorrhagic necrosis of the gastric mucosa (arrowhead), (C) Stomach of rats that were pretreated with APA 500 mg/kg bw + EtOH demonstrate moderate injuries in the gastric mucosa (arrowhead), (D) stomach of rats that were pretreated with APA 1000 mg/kg bw + EtOH shows minor damage restricted to the degeneration of the gastric mucosa only (arrowhead), (E) Stomach of rats that were pretreated with EtOH + Omeprazole (40 mg/kg bw), and no injury was observed in the gastric mucosa.

EtOH damage to produced degeneration of the mucosa only (Fig. 2D). Morphological analysis of stomach also revealed the hemorrhage with EtOH treatment and subsequent reduction in injury by APA exposure (Fig. 3).

Effect of APA on NaCl induced ulcers in rats

Table II also shows the effect of oral administration of APA on gastric mucosa of NaCl treated rats. The highest dose of APA (1000 mg/kg bw) significantly decreased the ulcer score by 4.1-fold in NaCl treated animals. Comparative to MDA level in NaCl treatment group, APA at the highest dose significantly decreased the MDA levels by 3.7-fold. In addition, the total protein and NP-SH levels were found enhanced 2.1 and 2.3-fold at 1000 mg/kg bw of APA (Table II), whereas the lowest dose of APA did not produce any significant effect

on ulcer score.

Histological analysis of NaCl treated rats revealed severe congestion and degeneration of the mucosa with marked mucosal ulceration and detachment (Fig. 4 B). NaCl treatment showed no effect on mucosa after low dose APA treatment. On the other hand, NaCl only produced hemorrhagic necrosis of the mucosa when it is administered after the higher dose of the APA extract (Fig. 4C, D). Morphological analysis of stomach of NaCl treated rats also revealed the hemorrhages and reduction in ulcers by APA exposure (Fig. 3).

Effect of APA on IM induced ulcers in rats

Relative to enhanced MDA level in IM control, APA treatment (500 and 1000 mg/kg bw) significantly reduced the MDA level to 1.7 and 4.8-fold (Table II). At the highest concentration of 1000

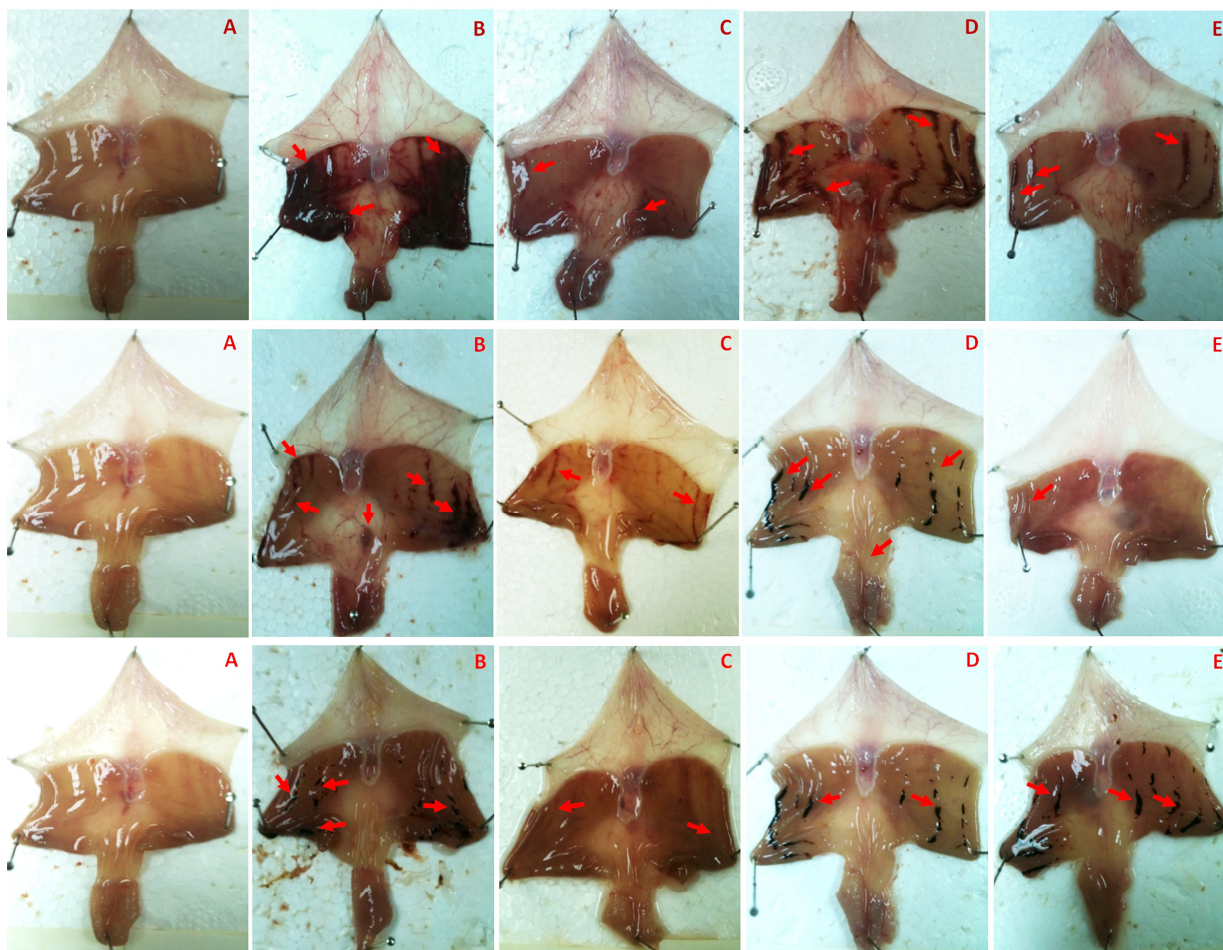


Fig. 3. APA induced amelioration of gastric ulcers and hemorrhage in EtOH- (top) NaCl- (middle) and IM- (bottom) treated rats. (A) Untreated control, (B) Top: EtOH (80%), middle: NaCl (25%); bottom: IM (30 mg/kg bw, IM (C) Top: EtOH + Omperazol, middle: NaCl + Omperazol; Bottom: IM + Omperazol (D) Top: APA 500 mg/kg bw + EtOH, middle: APA 500 mg/kg bw + NaCl; Bottom: APA 500 mg/kg bw + MI (E) Top: APA 1000 mg/kg bw + EtOH, middle APA 100 mg/kg bw NaCl; bottom: APA 1000 mg/kg bw + IM.

mg/kg bw the total protein and NP-SH level in IM treated rats were enhanced to 2.2 and 2.0-fold (Table II). Despite the significant improvement of gastric MDA, proteins and NP-SH levels, APA extract at both treatment concentrations did not produce significant alteration to the ulcer score of the IM induced ulcer in rats. Rats treated with IM showed the signs of big ulcerative necrosis of the mucosa (Fig. 5 B), which was found reduced after the administration of both 500 and 1000 mg/kg bw doses of APA (Fig. 5C, D). The gross structure analysis of IM treated stomach and effect of APA is shown in Figure 3.

DISCUSSION

It has been estimated that around 14.5 million people were affected with gastric ulcer diseases, and accounts for the mortality of nearly 4.08 million ulcer patients worldwide (Srikanta *et al.*, 2007). Being a multi-factorial disease, gastric ulcer is promoted by the generation of free radicals and oxidative stress (Repetto and Llesuy, 2002). Gastric ulcers are primarily treated with anticholinergics, proton pump inhibitors, antacids and H₂-receptor antagonists. However, the potential drawback with such treatment results in excessive development of

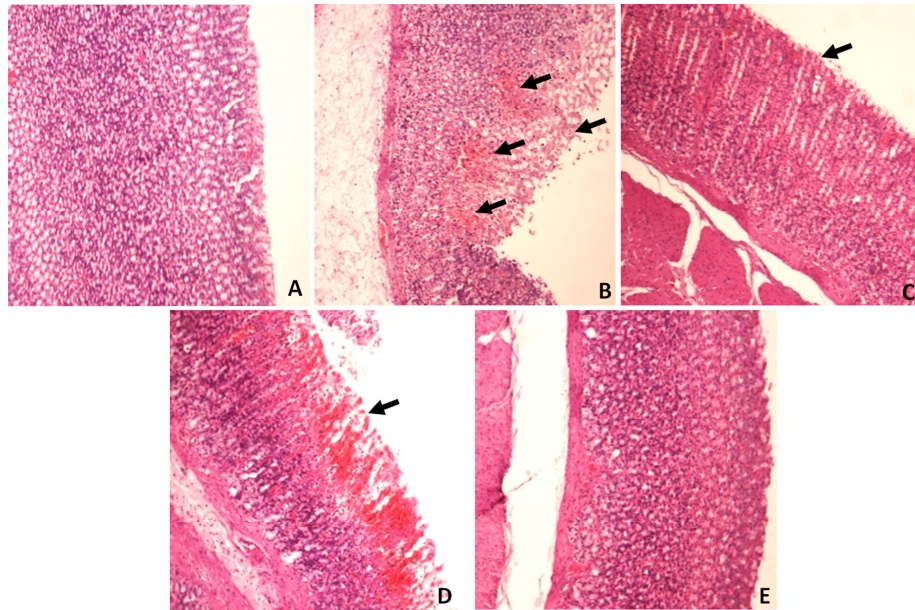


Fig. 4. Effect APA treatments on the histology of NaCl (25%) treated rats. (A) Untreated control, (B) NaCl (25%) treated rats' revealed severe congestion and degeneration of the mucosa with marked mucosal ulceration and haemorrhages (arrowheads), (C) NaCl treatment after low dose of APA (APA 500 mg/kg bw + NaCl) showed no effect on the mucosa (arrowhead), (D) NaCl treatment after high dose of APA (APA 1000 mg/kg bw + NaCl) produced hemorrhagic necrosis of the mucosa (arrowhead), (E) NaCl + Omeprazole.

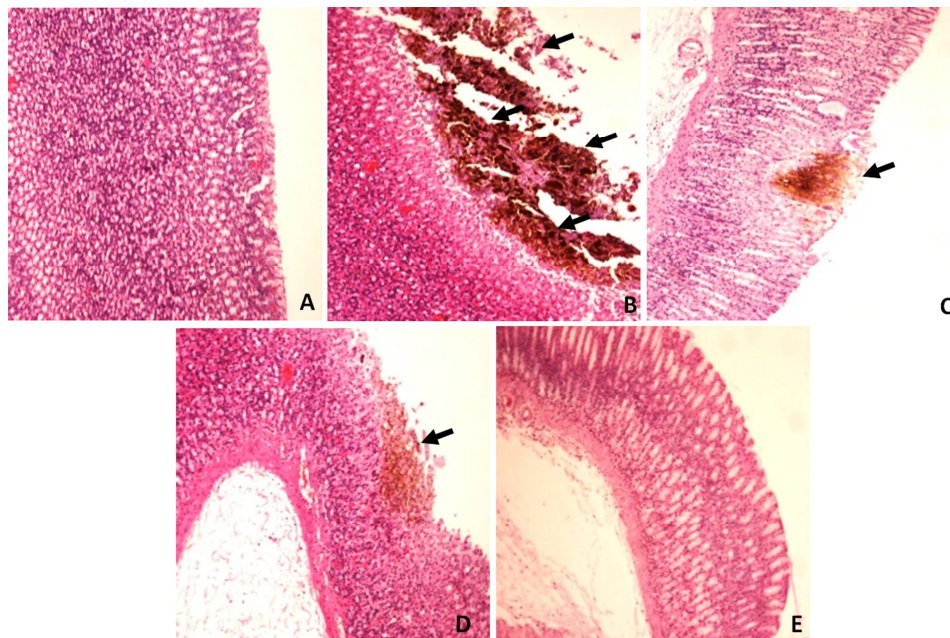


Fig. 5. Effect APA treatments on the histology of IM treated rats. (A) Untreated control, (B) Rats treated with IM (30 mg/kg bw) showed the signs of big ulcerative necrosis of the mucosa (arrowheads), (C) The treatment with APA 500 mg/kg bw + MI has reduced the big ulcerative necrosis of the mucosa (arrowhead), (D) The treatment with higher dose of APA 1000 mg/kg bw + MI give rise to a very minor ulcerative necrosis of the mucosa (arrowhead), (E) IM+ Omeprazole.

breasts in males, intolerance, cardiac arrhythmia, hematological disorders and erectile dysfunction. Consequently, ulcer treatments via alternative therapy using plant extracts are most promising (Jainu and Devi, 2005; Bonacorsi *et al.*, 2009). In this line, *A. paniculata* is the most popular medicinal plant used by the people as complementary medicine for the remedy of gastric problems (Shoab *et al.*, 2014). In addition, *Glycyrrhiza glabra* (Liquorice) root has been used since antiquity owing to its medicinal effects on peptic ulcers (Armanini *et al.*, 2002; Shibata, 2000). Therefore, the primary aim of current study is to assess the less studied antiulcer activity of aqueous extract of *A. paniculata* in rats treated with EtOH, NaCl and IM.

Earlier studies have demonstrated that EtOH, NaCl, acid, base solutions and other chemicals have the tendency to induce severe acute mucosal lesions in the rat stomach within minutes (Szabo, 1984, 1991; Mozsik *et al.*, 1983; Kusterer *et al.*, 1987; Nagy *et al.*, 1997). However, NaCl is dissolved by the gastric juice, becoming ionized to Na^+ and Cl^- and this ionization may directly damage the mucosa barrier. High concentrations of Na^+ , H^+ and/or Cl^- may cause movement of the mucus layer due to the potential difference in gastric mucosa and difference in concentration (Hoshino and Kishi, 1994). In the rat stomach, 25% and 23.5% of NaCl solution were reported to have a direct irritant effect (Takeuchi *et al.*, 1986; Robert *et al.*, 1979). In the present study, we examined the gastroprotective activities of APA against EtOH, NaCl and IM-induced stomach ulceration. In the histological analysis, we found that APA significantly reduces ulcer count only in the NaCl treated rats, thus exhibited significant gastroprotective effects. The antiulcerogenic potential of APA strongly suggests that the flavonoids and xanthenes present in the APA extract demonstrated their antioxidant potential against NaCl mediated oxidative injury (Koteswara *et al.*, 2004; Dua *et al.*, 2004; Velloso *et al.*, 2006). The antiulcerogenic activity of our study is supported by the earlier reports on the gastroprotective effects of *A. paniculata* and *T. officinale* in *in vitro* and *in vivo* test models (Zhang *et al.*, 2008; Shoab *et al.*, 2014). Moreover, *A. paniculata* organic extracts and andrographolide enhances the glutathione S-transferase

expression, which is another supporting evidence for reducing ability enhancement (Chang *et al.*, 2008).

Interaction of ROS with the cell membrane results in lipid peroxidation, which subsequently produces highly reactive lipid-derived free radicals such as MDA to cause oxidative gastric damage (Kwiecien *et al.*, 2002). In our study, all three-ulcer inducers (EtOH, NaCl, IM) significantly increased the MDA level of the stomach homogenate. The TBRAS assay revealed that APA significantly lowered the enhanced level of MDA indicating the free radicals scavenging activity. Our data is in accordance with the chemopreventive potential of *T. officinale* by extending the lag phase of lipid oxidation in RAW264.7 cells (Hu and Kitts, 2005). Thus, it could be said that the ability of APA in reducing the MDA level might contribute to its gastroprotective effect by inhibiting oxidative gastric damage by EtOH, NaCl and IM. Endogenous NP-SH compounds are known to protect the gastric mucosa from various chemicals by regulating the production and nature of mucus (Chen *et al.*, 2005; Salim, 1992). It is known that EtOH exerts its aggressive effects on gastric mucosa through diminishing endogenous NP-SH content (Loguercio *et al.*, 1993). We found that APA pretreatment effectively elevated the gastric NP-SH content not only in EtOH, but also in NaCl and IM treated rats, when compared to the ulcer control group. Our data on the APA mediated recovery of biochemical factors are in line with the recent report of Shoab *et al.* (2014), which has also demonstrated the improvement of antioxidant enzymes in IM exposed rats, when pretreated with 50% hydro-methanolic extract of *A. paniculata*. Therefore, it could be suggested that the replenishment of the endogenous NP-SH might contribute in the gastroprotective action of APA. As the relatively high concentration of NP-SH, which is mostly, reduced glutathione (GSH, γ -glutamyl-cysteinyl glycine) besides cysteine (CSH), coenzyme A and other thiols in the gastric mucosa also indicates their possible implications for gastroprotection (Miller *et al.*, 1985).

CONCLUSIONS

In this study, *A. paniculata* aqueous extract

(APA) significantly inhibited the EtOH and NaCl induced ulcers in rats at a dose of 1000 mg/kg bw. These effects may be due to the regeneration of reducing power and/or protein protection along with decreasing proinflammatory mediator's release. Our findings could justify, at least in part, that APA can be used as ethnomedicinal source for the management of gastric disorders. Overall, this study showed that *A. paniculata* aqueous extract is safe on the gastric mucosa when taken orally. It might be of potential use in reducing gastric mucosal irritation if taken in doses not less than 1000 mg/kg bw in rats.

ACKNOWLEDGMENTS

This project is supported by a grant from King Abdulaziz City for Science and Technology number (ص-60-14 م). The researchers acknowledge KACST for supporting the project.

REFERENCES

- AMROYAN, E., GABRIELIAN, E., PANSOSSIAN, A., WIKMAN, G. AND WAGNER, H., 1999. Inhibitory effect of andrographolide from *Andrographis paniculata* on PAF-induced platelet aggregation. *Phytomedicine*, **6**: 27-31.
- ARMANINI, D., FIORE, C., MATTARELLO, M. J., BIELENBERG, J. AND PALERMO, M., 2002. History of the endocrine effects of licorice. *Exp. Clin. Endocrinol. Diabetes*, **110**: 257-261.
- BHARGAVA, K. P., GUPTA, M. B. AND TANGARI, K. K., 1973. Mechanism of ulcerogenic activity of indomethacin and oxyphenbutazone. *Eur. J. Pharmacol.*, **22**:191-195.
- BONACORSI, C., RADDI, M. S. G., CARLOS, I. Z., SANNOOMIYA, M. AND VILEGAS, W., 2009. Anti-Helicobacter pylori activity and immunostimulatory effect of extracts from *Byrsonima crassa* Nied. (Malpighiaceae). *BMC Complement. Altern. Med.*, **9**: 1-7.
- CALABRESE, C., BERMAN, S. H., BABISH, J. G., MA, X., SHINTO, L., DORM, M., WELLS, K., WENNER, C. A. AND STANDISH, L. J., 2000. A phase I trial of andrographolide in HIV-positive patients and normal volunteers. *Phytother. Res.*, **14**: 333-338.
- CHANG, K. T., LII, C. K., TSAI, C.W., YANG, A. J. AND CHEN, H.W., 2008. Modulation of the expression of the π class of glutathione S-transferase by *Andrographis paniculata* extracts and andrographolide. *Fd. Chem. Toxicol.*, **46**:1079-1088.
- CHEN, S. H., LIANG, Y. C., CHAO, J. C., TSAI, L. H., CHANG, C. C., WANG, C. C. AND PAN, S., 2005. Protective effects of Ginkgo biloba extract on the ethanol-induced gastric ulcer in rats. *World J. Gastroenterol.*, **11**: 3746-3750.
- DANIEL, W.W., 1995. *Biostatistics: a foundation for analysis in the health sciences*. 6th ed. Wiley. New York, USA. pp. 273-303.
- DUA, V.K., OJHA, V. P., ROY, R., JOSHI, B. C., VALECHA, N., DEVI, C. U., BHATNAGAR, M.C., SHARMA, V.P. AND SUBBARO, S.K., 2004. Anti-malarial activity of some xanthenes isolated from the roots of *Andrographis paniculata*. *J. Ethnopharmacol.*, **95**: 247-251.
- GUPTA, S., CHOUDARY, M. A., YADAVA, J. N. S., SRIVATSTAVA, V. AND TANDON, J. S., 1990. Antidiarrhoeal activity of diterpenes of *Andrographis paniculata* (Kal Megh) against *Escherichia coli* enterotoxin in *in vivo* models. *Pharma. Biol.*, **28**: 273-283.
- HANDA, S. S. AND SHARMA, A., 1990. Hepatoprotective activity of Andrographolide against galactosamine and paracetamol intoxication in rats. *Indian J. med. Res.*, **92**: 284-292.
- HOSHINO, T. AND KISHI, T., 1994. Acute ulcers induced in canine stomachs by endoscopic compressed air delivery of 25 mg NaCl. *Dig. Endosc.*, **6**: 237-240.
- HSU, J. H., LIOU, S. S., YU, B. C., CHENG, J. T. AND WU, Y. C., 2004. Activation of alpha 1A-adrenoceptor by andrographolide to increase glucose uptake in cultured myoblast C2C12 cells. *Planta Med.*, **70**: 1230-1233.
- HU, C. AND KITTS, D. D., 2005. Dandelion (*Taraxacum officinale*) flower extract suppress both reactive oxygen species and nitric oxide and prevents lipid oxidation *in vitro*. *Phytomedicine*, **12**: 588-597.
- HUIDROM, S. AND DEKA, M., 2012. Determination of antioxidant property of *Andrographis paniculata*. *Indian J. Drugs Dis.*, **1**: 13-18.
- JAINU, M. AND DEVI, C. S. S., 2005. Antiulcerogenic and ulcer healing effects of *Solanum nigrum* (L.) on experimental ulcer models: possible mechanism for the inhibition of acid formation. *J. Ethnopharmacol.*, **104**: 156-163.
- KOTESWARA, R. Y., VIMALAMMA, G., RAO, C. V. AND TZENG, Y. M., 2004. Flavonoids and andrographolide from *Andrographis paniculata*. *Phytochemistry*, **65**: 2317-2321.
- KUSTERER, K., PIHAN, G. AND SZABO, S., 1987. Role of lipid peroxidation in gastric mucosal lesions induced by HCl, NaOH, or ischemia. *Am. J. Physiol.*, **252**: G811-G816.
- KWIECIEN, S., BRZOZOWSKI, T. AND KONTUREK, S.J., 2002. Effects of reactive oxygen species action on gastric mucosa in various models of mucosal injury. *J. Physiol. Pharmacol.*, **53**: 39-50.
- LOGUERCIO, C., TARANTO, D., BENEDEUCE, F., DEL

- VECCHIO, B. C., DE VINCENTIIS, A., NARDI, G. AND ROMANO, M., 1993. Glutathione prevents ethanol induced gastric mucosal damage and depletion of sulfhydryl compounds in humans. *Gut*, **34**: 161-165.
- LOWRY, O. H., ROSEBROUGH, N. J., FARR, A. L. AND RANDALL, R.J., 1951. Protein measurement with the folin phenol reagent. *J. biol. Chem.*, **193**: 265-275.
- MANDAL, S.C., DHARA, A.K. AND MAITI, B.C., 2001. Studies on psychopharmacological activity of *Andrographis paniculata* extract. *Phytother. Res.*, **15**: 253-256.
- MILLER, T. A., LI, D., KUO, Y. J., SCHMDIT, K. L. AND SHANBOUR, L. L., 1985. Nonprotein sulfhydryl compounds in canine gastric mucosa: effects of PGE2 and ethanol. *Am. J. Physiol.*, **249**: G137-G144.
- MORIMOTO, Y., SHMOHARA, K., OSHIMA, S. AND SUKKAMOTO, T., 1991. Effect of the new anti-ulcer agent KB-5492 on experimental gastric mucosal lesions and gastric mucosal defensive factors, as compared to those of terpenone and cimetidine. *Jpn. J. Pharmacol.*, **37**: 495-505.
- MOZSIK, G., MORON, F., FIEGLER, M., JAVOR, T., NAGY, L., PATTY, I. AND TARNOK, F., 1983. Interrelationships between membrane-bound ATP-dependent energy systems, gastric mucosal damage produced by NaOH, hypertonic NaCl, HCl, and alcohol, and prostacyclin-induced gastric cytoprotection in rats. *Prostaglan. Leukot. Med.*, **12**: 423-436.
- NAGY, L., JOHNSON, B. R., HAUSCHAKA, P. AND SZABO, S., 1997. Characterization of proteases and protease inhibitors in the rat stomach. *Am. J. Physiol.*, **272**: G1151-G1158.
- NARTEY, E. T., OFOSUHENE, M. AND AGBALE, C. M., 2012. Anti-ulcerogenic activity of the root bark extract of the African laburnum "*Cassia sieberiana*" and its effect on the anti-oxidant defence system in rats. *BMC Complement. Altern. Med.*, **10**:12:247.
- NAJIB N. A. R. N., FURUTA, T., KOJIMA, S., TAKANE, K. AND ALI, M. M., 1999. Antimalarial activity of extracts of Malaysian medicinal plants. *J. Ethnopharmacol.*, **64**: 249-254.
- PEKTHONG, D., BLANCHARD, N., ABADIE, C., BONET, A., HEYD, B., MANTION, G., BERTHELOT, A., RICHERT, L. AND MARTIN, H., 2009. Effects of *Andrographis paniculata* extract and andrographolide on hepatic cytochrome P450 mRNA expression and monooxygenase activities after *in vivo* administration to rats and *in vitro* in rats and human hepatocyte cultures. *J. Ethnopharmacol.*, **115**: 432-440.
- PURRI, A., SAXENA, R., SAXENA, R. P., SAXENA, K. C., SRIVASTAVA, V. AND TANDON, J. S., 1993. Immunostimulant agents from *Andrographis paniculata*. *J. Nat. Prod.*, **56**: 995-999.
- RAFATULLAH, S., GALAL, A. M., AL-YAHYA, M. A. AND AL-SAID, M. S., 1995. Gastric antiulcer and cytoprotective effects of *Aframomum melegueta* in rats. *Int. J. Pharmacol.*, **33**: 311-316.
- RANA, A.C. AND AVADHOOT, Y., 1991. Hepatoprotective effects of *Andrographis paniculata* against carbon tetrachloride-induced liver damage. *Arch. Pharm. Res.*, **14**: 93-95.
- REPTTO, M. G. AND LLESSUY, S. F., 2002. Antioxidant properties of natural compounds used in popular medicine for gastric ulcers. *Braz. J. Med. Biol. Res.*, **35**: 523-534.
- ROBERT, A., NEZAMIS, J.E., LANCASTER, C. AND HANCHAR, A.J., 1979. Cytoprotection by prostaglandins in rats. Prevention of gastric necrosis produced by alcohol, HCl, NaOH, hypertonic NaCl, and thermal injury. *Gastroenterology*, **77**: 433-443.
- SALIM, A. S., 1992. Sulphydryl-containing agents: a new approach to the problem of refractory peptic ulceration. *Pharmacology*, **45**: 301-306.
- SEDLAK, J. AND LINDASY, R. H., 1968. Estimation of total protein bound and nonprotein Sulfhydryl group in tissue with Ellman s reagents. *Anal. Biochem.*, **25**:192-205.
- SEE, D., MASON, S. AND ROSHAN, R., 2002. Increased tumor necrosis factor alpha (TNF-alpha) and natural killer cell (NK) function using an integrative approach in late stage cancers. *Immunol. Invest.*, **31**: 137-153.
- SHEN, Y.C., CHEN, C.F. AND CHIOU, W. F., 2002. Andrographolide prevents oxygen radical production by human neutrophils:possible mechanism(s) involved in its anti-nflamatory effect. *Br. J. Pharmacol.*, **135**: 399-406.
- SHEN, Y.H., LI, R.T., XIAO, W.L., XU, G., LIN, Z.W., ZHAO, Q.S. AND SUN, H.D., 2006. Ent Labdane diterpenoids from *Andrographis paniculata*. *J. Nat. Prod.*, **69**: 319-322.
- SHIBATA, S., 2000. A drug over the millennium: pharmacognosy, chemistry, and pharmacology of licorice. *Yakugaku Zasshi*, **120**: 849- 862.
- SHOAIB, A., TARIQUE, M., KHUSHTAR, M. AND SIDDIQUI, H. H., 2014. Antiulcerogenic activity of hydromethanolic extract of *Andrographis paniculata*, Indomethacin and Indomethacin plus pylorus ligation induced gastric ulcer in rats. *Asian J. Biomed. Pharma. Sci.*, **4**: 8-15.
- SINGHA, P.K., ROY, S. AND DEY, S., 2003. Antimicrobial activity of *Andrographis paniculata*. *Fitoterapia*, **74**: 692-694.
- SRIKANTA, B. M., SIDDARAJU, M. N. AND DHARMESH, S. M., 2007. A novel phenol-bound pectic polysaccharide from *Decalepis hamiltonii* with multi-step ulcer preventive activity. *World J. Gastroenterol.*, **13**: 5196-5207.
- SUEBSASANA, S., PONGNARATORN, P., SATTAYASAI, J., ARKARAVICHIE, T., TIAMKO, S. AND AROMDEE, C., 2009. Analgesic, antipyretic, anti-inflammatory and toxic effects of andro grapholide

- derivatives in experimental animal. *Arch. Pharm. Res.*, **32**:1191-1200.
- SYAHRIN, A., AMRAH, S., CHAN, K., LIM, B., HASENAN, N., HASNAN, J. AND MOHSIN, S., 2006. Effect of spray dried ethanolic extract of *Andrographis paniculata* (Burms F.) Nees on streptozotocin induced Diabetic Rats. *Int. J. Diabetes Develop. Count.*, **26**: 163-168.
- SZABO, S., 1984. Role of sulfhydryls and early vascular lesions in gastric mucosal injury. *Acta Physiol. Hung.*, **64**: 203-214.
- SZABO, S., 1991. Mechanisms of gastric mucosal injury and protection. *J. Clin. Gastroenterol.*, **13**: S21-S34.
- SZLENYI, I. AND THIEMER, K., 1978. Distention ulcer as a model for testing of drugs for ulcerogenic side effects. *Arch. Toxicol.*, **4**: 99-105.
- TAKEUCHI, K., YAMAKUNI, H., NOBUHARA, Y. AND OKABE, S., 1986. Functional and morphological alterations in the rat stomach following exposure to hypertonic NaCl solution. *Jpn. J. Pharmacol.*, **42**: 549-560.
- UTLEY, H. G., BERNHEIM, F. AND HOCHSTEIN, P., 1967. Effect of sulfhydryl reagent on peroxidation in microsomes. *Arch. Biochem. Biophys.*, **118**: 29-32.
- VELLOSA, J. C. R., KHALIL, N. M., FORMENTON, V. A., XIMENES, V. F., FONSECA, L. M., FURLAN, M., BRUNETTI, I. L. AND OLIVEIRA, O.M.M.F., 2006. Antioxidant activity of *Maytenus licifolia* root bark. *Fitoterapia*, **77**: 243-244.
- ZHANG, J., KANG, M. J., KIM, M. J., KIM, M. E., SONG, J. H., LEE, Y. M. AND KIM, J. I., 2008. Pancreatic lipase inhibitory activity of taraxacum officinale *in vitro* and *in vivo*. *Nutr. Res. Pract.*, **2**: 200-203
- ZHOU, J., ZHANG, S., ONG, C. N. AND SHEN, H. M., 2006. Critical role of pro-apoptotic Bcl-2 family members in andrographolide-induced apoptosis in human cancer cells. *Biochem. Pharmacol.*, **72**:132-144.

(Received 9 June 2015, revised 29 July 2015)