

Teratoma of the head and neck

YOUSRY EL-SAYED, F.R.C.S. (Riyadh, Saudi Arabia)

Introduction

Teratomas are congenital tumours which occur rarely in the head and neck. They present almost exclusively in neonates and may cause considerable morbidity or mortality secondary to respiratory obstruction. The purpose of this paper is to present a case of nasopharyngeal teratoma and to review the literature pertaining to head and neck teratomas.

Case report

A full term female was born by uncomplicated spontaneous vaginal delivery at a remote hospital. Immediately following delivery a mass was noted behind the right side of the soft palate which was causing no difficulty with feeding or breathing. Over the following days the mass was noticed to increase in size and

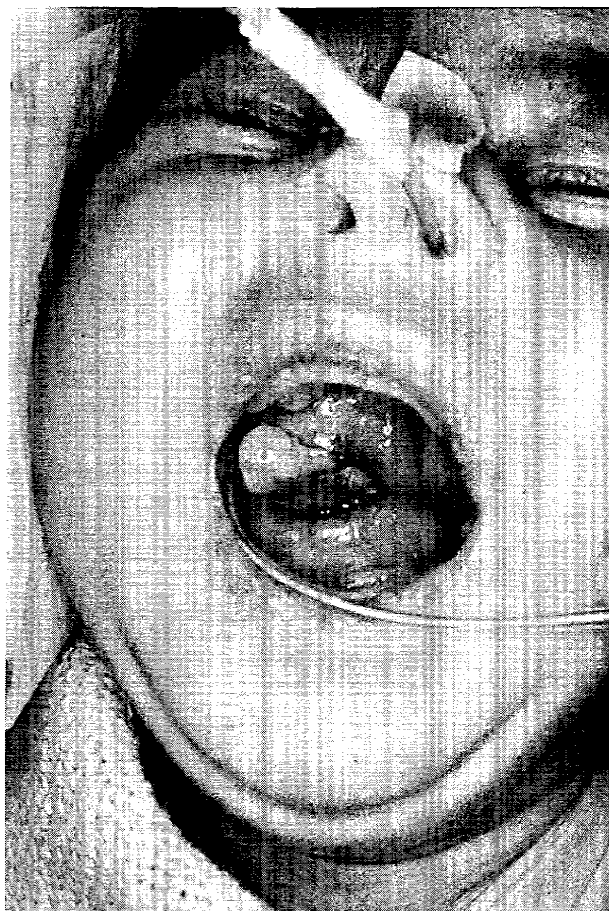


FIG. 1

Photograph of the baby when she was 16 days old just before surgery, showing large mass protruding into the mouth behind right side of the palate. Nasotracheal and oral feeding tubes are seen.

by the sixteenth day, the infant showed severe respiratory distress. A nasotracheal tube and an oral feeding tube were inserted and the baby was then referred to our hospital for consultation. A large reddish firm multilobulated mass was noted behind the right side of the soft palate pushing it downward and to the left (Fig. 1). The mass was not pulsating and did not transilluminate. Aspiration was negative for cerebrospinal fluid. Plain X-ray showed a large soft tissue mass in the nasopharynx and oropharynx with no calcification. A CT scan illustrated a large pharyngeal ill-defined mass of heterogeneous density displacing the naso-tracheal tube toward the left (Fig. 2). There was no sign of bone destruction or intracranial extension.

On the following day, under general anaesthesia, the mass was found to be attached by a narrow stalk to the right superio-lateral wall of the nasopharynx. The mass was removed without difficulty after retraction of the soft palate. Bleeding was minimal and was controlled by gauze swab pressure for seven minutes. Pathological examination of the mass revealed 5 x 4 x 3 cm reddish lobulated solid mass of heterogeneous consistency.

Microscopically, it contained well-differentiated fat lobules, brain tissue, striated muscles, fibrous tissue, focal calcification, bone, cysts, hair follicles, and salivary gland tissue (Fig. 3). There was no evidence of malignancy.

The post-operative course was uneventful. The nasotracheal and the gastric tube removed on the third post-operative day. The patient has been followed up for two years with no evidence of recurrence.

Discussion

A teratoma is a true tumour or neoplasm composed of multiple

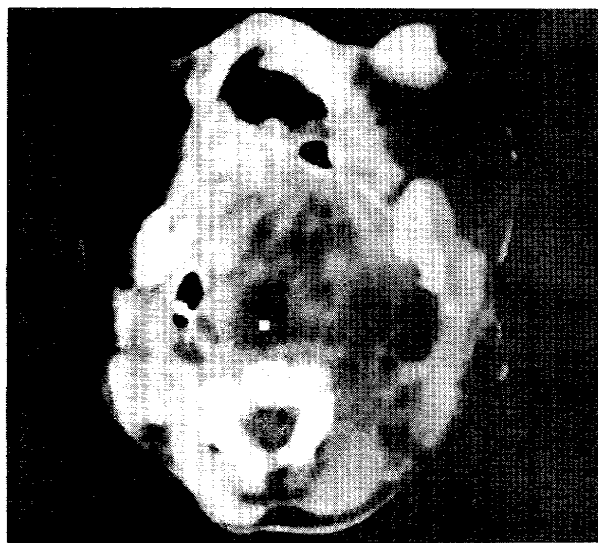


FIG. 2

An axial CT of the baby showing large mass of heterogeneous densities filling the pharynx pushing the nasotracheal tube to extreme left. The feeding tube is seen in front of the mass.

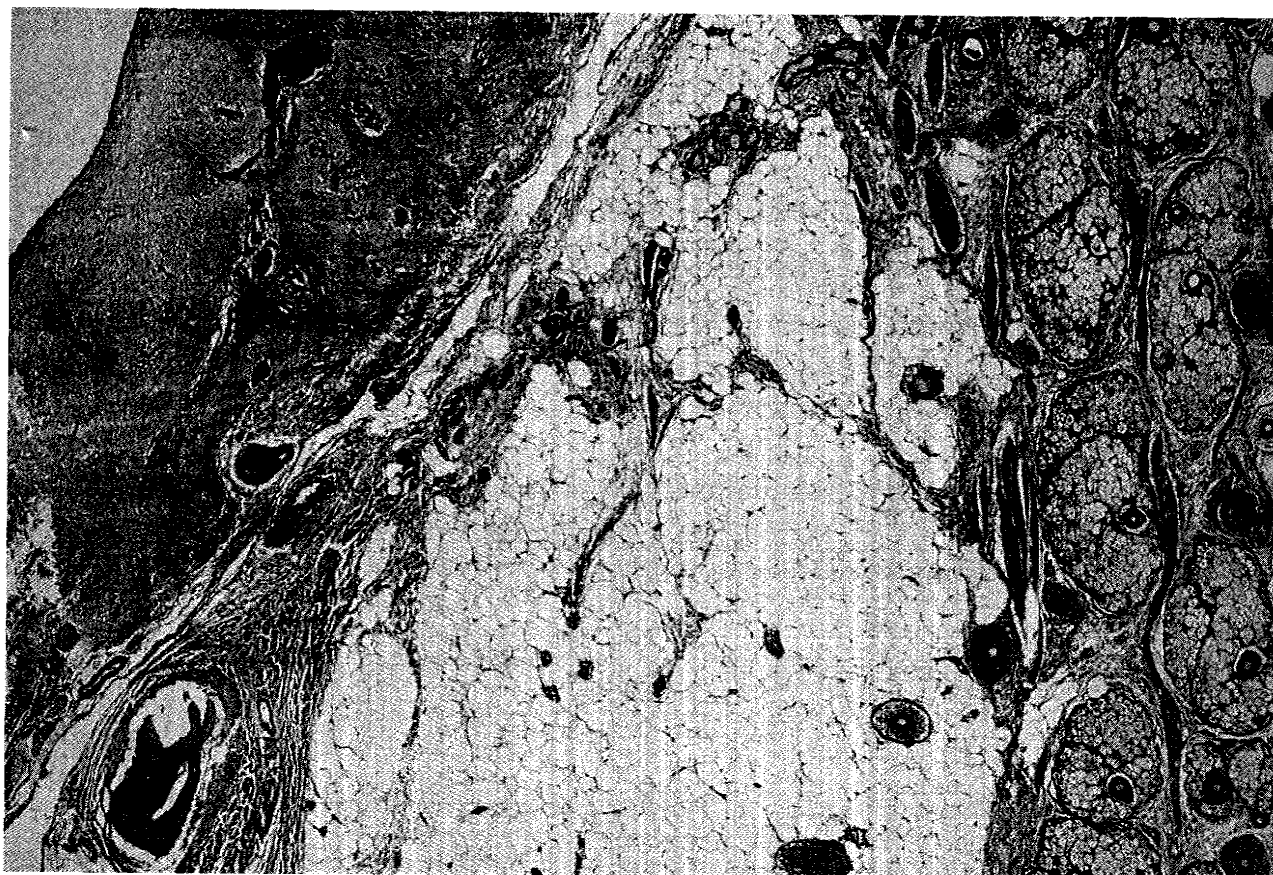


FIG. 3

A section showing brain-tissue, bone, fatty and fibrous tissue, hair follicles, and many sebaceous glands.

tissues of kinds foreign to the part in which it arises: it displays some degree of progressive, uncoordinated growth and is not merely a quiescent malformation (Weaver *et al.*, 1976).

The origin and pathogenesis of teratomas is still unknown. It is now generally accepted that teratomas may arise from both germ cells in their course of migration during embryogenesis, and from non-germ embryonic cells that escaped the influence of embryonic organizer (Ward and April, 1989). The interested reader is referred to the discussion of the histogenesis of these tumours which was presented by Roediger *et al.* (1974).

Teratomas have been classified into four types: dermoids, teratoids, true teratomas, and epignathi (Calcaterra, 1969). The dermoids are composed of only epidermal and mesodermal elements. The teratoids are poorly differentiated tumours containing three germ layers. The true teratomas are well differentiated tumours containing all three germ layers. The epignathi are gross maldevelopment of organs and limbs and are rarely compatible with life.

Microscopic examination shows a variety of tissues from the three germ layers with a wide range of cellular differentiation and variable degree of maturation. Of interest is the 68 per cent incidence of neural tissue (Jordan and Gauderer, 1988). The majority of teratomas are benign tumours. However: approximately 5 per cent of neck teratomas were found to contain malignant elements (Stephenson *et al.*, 1989).

Teratomas most often occur in a para-axial or mid-line location from the brain to the sacral area as well as in the gonads. They occur in approximately 1 in 4,000 births, with less than 10 per cent of these occurring in the head and neck (Holt *et al.*, 1979). The most common location in head and neck is the cervical region followed by the nasopharynx (Alter and Cove 1987). Teratomas also have been reported in the larynx (Canon *et al.*, 1987), the mastoid (Talmi *et al.*, 1988), the tongue (Bras *et al.*, 1969) and the palate (Mudbharka and Kothare, 1966).

Whereas teratomas elsewhere in the body usually show a pre-

dilection for females, those in the head and neck reveal an equal sex distribution (Abemayor *et al.*, 1984). They have been reported in all races. They occur almost exclusively in the newborn and infancy periods (Ward and April, 1989).

Maternal hydramnios has been recorded in about 18 per cent of cervical teratomas; a direct relation was noted between the hydramnios and the teratoma size (Hawkins and Park, 1972). The hydramnios is probably secondary to inability of the foetus to swallow amniotic fluid.

Most neonates with cervical or pharyngeal teratomas have airway obstruction and an obvious mass. Respiratory symptoms vary from total apnoea to mild dyspnoea or coughing with feeding. Airway compression may not be noted at birth, only to progress rapidly over several hours to life-threatening obstruction. Cervical teratomas are usually fairly large at presentation and lie in the mid-line but tend to be more prominent on one side (Ward and April, 1989). Typically teratomas are rapid growing, firm, multilobular masses which are frequently mobile and do not transilluminate. Nasopharyngeal teratomas typically arise from the lateral or superior walls of the nasopharynx with no connection to the intracranial cavity (Handler and Raney, 1981). They are commonly seen protruding into the oropharynx leading to feeding and respiratory difficulty. Large cervical teratomas are associated with premature birth, polyhydramnios and birth difficulties (Jordan and Gauderer, 1988). Teratomas of the nasopharynx are reported to be associated with an increased incidence of palatal defects, hemicrania, and an encephaly (Calcaterra, 1969).

The differential diagnosis of a cervical mass in early infancy includes cystic hygroma, congenital goitre, thyroglossal duct cyst, branchial cleft cyst, lymphangioma, arteriovenous malformation, lipoma and laryngocoele (Ward and April, 1989). The differential diagnosis of nasopharyngeal tumours in infants includes craniopharyngiomas, chordomas, encephalocoeles, hamartomas, rhabdomyomas and gliomas (Snow, 1977).

Radiographic techniques play a major role in the evaluation of teratomas. Soft tissue radiographs may show calcifications or the presence of teeth in the mass. Calcification within the tumour occurs in 16 per cent of cases; the finding is virtually diagnostic when present (Jordan and Gauderer, 1988). CT scans can aid in further delineating the tumour. It also can help in differentiating nasopharyngeal teratomas from encephalocoeles. The latter often display erosion of the skull base, in contrast to teratomas which have no connection to the intracranial cavity and, therefore, there is no evidence of bone destruction (Handler and Raney, 1981). Radioisotope imaging of the thyroid is of value in delineating involvement of the gland. On ultrasonography, teratomas are generally mixed in echogenicity showing areas of semicystic and solid components. Ultrasonography was found to be very useful in prenatal diagnosis of teratomas. This allows prenatal preparation and prompt postnasal surgical care for the airway obstruction that so often occurs (Zerella and Finberg, 1990). Fine needle aspiration biopsy can be used to obtain tissue for diagnosis (Abemayor *et al.*, 1986).

The treatment of these tumours is directed to establish the airway: followed by well planned complete surgical excision. Early surgical intervention is recommended because teratomas are generally rapidly growing tumours and also to avoid the small but present risk of malignant transformation. On reviewing the literature, Gundry *et al.* (1983) found a mortality rate of 80 per cent of 37 patients not operated on during the neonatal period, compared with a 15 per cent mortality rate in 66 patients who underwent early surgical excision of the cervical teratoma. Recurrence is common after incomplete excision but not so following complete excision.

The main management hazard is failure to secure the airway promptly. Obstruction of the airway had caused 49 deaths in 164 newborn with cervical teratomas and five deaths in 24 newborns with oral-pharyngeal teratomas (Zerella and Finberg, 1990).

Surgical mortality as reported by Hawkin and Park (1971) is 9 per cent: of those not treated, all died. No recurrence or malignancies have been reported in infants. Tumour location and size rather than the histological grading are the most significant features affecting the immediate clinical course (Byard *et al.*, 1990).

In summary teratomas are mostly benign congenital tumour which usually present in the neonates. It can cause high mortality, because of respiratory obstruction. Early complete excision is usually followed by cure.

References

- Abemayor, E., Newman, A., Bergstrom, L., Dudley, J., Magidson, J. G., Ljung, B. M. (1984) Teratomas of the head and neck in childhood. *Laryngoscope*, **94**: 1489-1492.
- Alter, A. D., Cove, J. K. (1987) Congenital nasopharyngeal teratoma: report of a case and review of the literature. *Journal of Pediatric Surgery*, **22**: 179-181.
- Bras, G., Butts, D., Hoyle, D. A. (1969) Gliomatous teratoma of the tongue. *Cancer*, **24**: 1045-1050.
- Byard, R. W., Jimenez, C. L., Carpenter, B. F., Smith, C. R. (1990) Congenital teratomas of the neck and nasopharynx: A clinical and pathological study of 18 cases. *Journal of Paediatric Child Health*, **26**: 12-16.
- Calcaterra, T. (1963) Teratomas of the nasopharynx. *Annals of Otolaryngology, Rhinology and Laryngology*, **78**: 165-171.
- Cannon, C. R., Johns, M. E., Fechner, R. E. (1937) Immature teratoma of the larynx. *Otolaryngology—Head and Neck Surgery*, **96**: 366-368.
- Gundry, S. R., Wesley, J. R., Klein, M. D., Barr, M., Covan, A. G. (1983) Cervical teratomas in the newborn. *Journal of Pediatric Surgery*, **18**: 382-386.
- Hawkins, D. B., Park, R. (1972) Teratoma of the pharynx and neck. *Annals of Otolaryngology, Rhinology and Laryngology*, **81**: 848-853.
- Handler, S. D., Raney, R. B. Jr. (1981) Management of neoplasms of the head and neck in children. I. Benign tumours. *Head and Neck Surgery*, **3**: 395-405.
- Holt, G. R., Holt, J. E., Weaver, R. G. (1979) Dermoids and teratomas of the head and neck. *Ear, Nose and Throat Journal*, **58**: 520-531.
- Jordan, R. B., Gauderer, M. W. L. (1988) Cervical teratomas: an analysis. Literature review and proposed classification. *Journal of Pediatric Surgery*, **23**: 583-591.
- Mudbharka, N. S., Kothare, S. N. (1966) Teratoma of the soft palate. *Journal of Postgraduate Medicine*, **12**: 45-47.
- Roediger, W. E., Spitz, L., Schuman, A. (1974) Histogenesis of benign cervical teratomas. *Teratology*, **10**: 11-18.
- Snow, J. B. Jr. (1977) Neoplasms of the nasopharynx in children. *Otolaryngologic Clinics of North America*, **10**: 1-24.
- Stephenson, J. A., Mayland, D. M., Kun, L. E., Etcubanas, E., Thompson, E. L., Gross, C. W. (1989) Malignant germ cell tumour of the head and neck in childhood. *Laryngoscope*, **99**: 732-734.
- Talmi, Y. P., Sadov, R., Dulitzky, F., Finkelstein, Y., Zohar, Y. (1988) Teratoma of the mastoid region in a newborn. *Journal of Laryngology and Otolaryngology*, **102**: 1033-1035.
- Ward, R. F., April, M. (1989) Teratomas of the head and neck. *Otolaryngologic Clinics of North America*, **22**: 621-629.
- Weaver, R. G., Meyerhoff, W. L., Gates, G. A. (1976) Teratomas of the head and neck. *Surgical Forum*, **27**: 539-542.
- Zerella, J. T., Finberg, F. J. (1990) Obstruction of the neonatal airway from teratomas. *Surgery, Gynaecology and Obstetrics*, **170**: 126-131.

Address for correspondence:

Dr Yousry El-Sayed,
Department of ORL,
King Abdul Aziz University Hospital,
P. O. Box 245,
Riyadh 11411,
Saudi Arabia.

Key words: Head and neck neoplasms; Teratoma.