

Fibromatosis of the head and neck

YOUSRY EL-SAYED, F.R.C.S. (Riyadh, Saudi Arabia)

Abstract

The purpose of this paper is to focus attention on this rare disorder. Two cases are reported: one involving the neck and the other the nose and paranasal sinuses. The treatment of choice is wide surgical excision wherever possible.

Introduction

Fibromatosis is an histologically benign but clinically aggressive fibroblastic lesion which arises from the musculoaponeurotic structure throughout the body. The condition is rare and clinicians and even pathologists are not always aware of its existence. As a result it may be easily misdiagnosed and the wrong conclusion regarding its biological behaviour may thus be drawn (Reitamo *et al.*, 1982).

Fibromatoses of the head and neck are particularly serious lesions because of local aggressiveness, with a high rate of recurrence in a relatively restricted anatomical area, which not only compromises the surgical excision, but also brings the tumour dangerously close to vital structures (Wilkins *et al.*, 1975).

The purpose of this paper is to focus attention on this rare disorder by reporting two cases: one involving the neck and the other affecting the nose and paranasal sinuses.

Review of the literature showed that this disorder has been described under several different titles reflecting the great obscurity regarding its histogenesis and pathogenesis. In the light of present knowledge, wide surgical excision is the treatment of choice whenever possible. Radiation and various drug therapies have been described, as adjuvant or alternative to surgery for selected cases.

Case reports

Case 1

A 54-year-old lady had reported to another hospital a year pre-

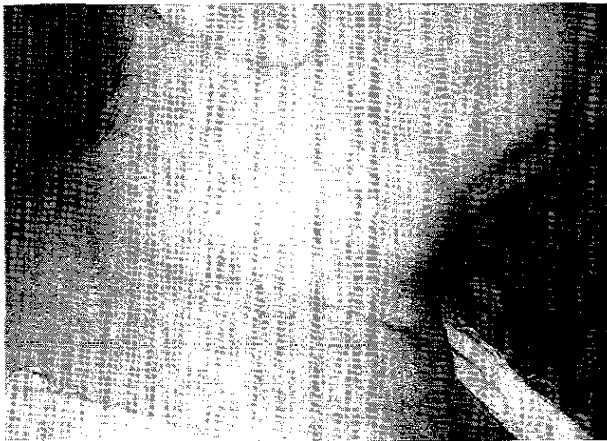

FIG. 1

Lateral view photograph of patient No. 1 showing large mass right side of neck extending from the mandible to the clavicle with the scar of the first biopsy.

viously because of a painless mass of the right side of the neck which had been slowly growing for three months. The mass was excised but the diagnosis was not conclusive even pathologically. Initially she did well, but eight months after the operation the swelling reappeared and grew rapidly. Examination of the neck showed a large stony hard mass tilling the right side of the neck extending from the mandible to the clavicle and from the posterior triangle to the mid-line displacing the larynx and trachea toward the left and restricting her neck movement (Fig. 1). The mass was fixed to the underlying structures but the covering skin was freely mobile. Plain X-ray showed a soft tissue mass displacing the larynx and trachea to the left. A CT scan illus-

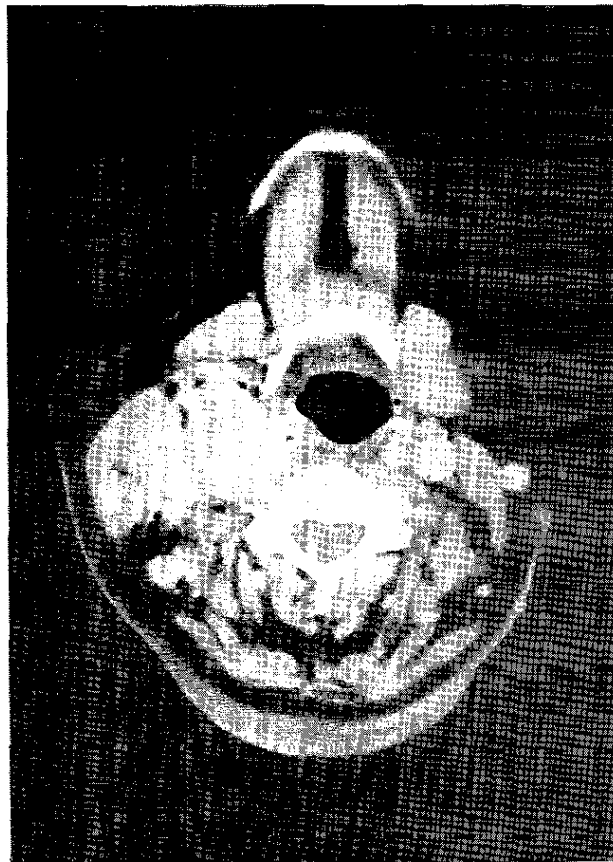


FIG. 2

CT scan of neck, post enhancement, showing a large ill defined mass seen in the right side of the neck. Right jugular vein and carotid artery are not demonstrated.



FIG. 3

Showing interlacing bundles of fibroblasts and collagen

trated a large tumour surrounding the great vessels and extending from the base of skull to the clavicle (Fig. 2). Exploration of the neck revealed a very large tumour adherent to the sternomastoid muscle, thyroid gland, larynx and the trachea. The actual margins of the lesion were unidentifiable. A biopsy was taken and a histological diagnosis of aggressive fibromatosis was made (Fig. 3). Because the tumour was not resectable, the patient received radiation treatment. The patient was last seen six months after treatment. Examination showed moderate diminution in the tumour size with improvement of the neck movement. Subsequently this patient has been lost to follow-up.

Case 2

A 51-year-old man reported complaining of right-sided nasal obstruction for eight months, and a slowly progressive swelling in the right fronto-ethmoid region for four months. Examination showed a nodular greyish swelling in the right middle meatus and an ill-defined 3 × 3 cm hard swelling in the superior and medial orbital wall displacing the eyeball slightly downward and laterally. Plain X-ray and a CT scan showed a large mass with some calcification involving the right nasal cavity, maxillary, ethmoid and frontal sinuses (Fig. 4). There was erosion of the medial wall of maxillary sinus, lateral wall of the ethmoid and the floor of the frontal sinus. A biopsy was taken under local anaesthesia from the middle meatal swelling but reported as scar tissue. The involved sinuses were therefore explored and revealed a large lesion with an ill-defined edge adherent to the globe of the eye and to the dura, after eroding the lateral wall of the ethmoid labyrinth and the posterior wall of the frontal sinus. Incomplete resection of the lesion was carried out and histological examination demonstrated aggressive fibromatosis. The patient then received radiation therapy. Two years post-treatment, he was asymptomatic although there was still radiological evidence of the tumour of reduced size in the frontal and ethmoidal sinuses.

Discussion

Fibromatosis has been described under a variety of synonyms e.g. desmoid tumour, desmoid fibromatosis, non-metastasizing fibrosarcoma etc. The term 'desmoid tumour' or 'desmoid fibromatosis' is applied due to its fundamental similarity to the abdominal desmoid which has tendon (desmoid)-like consistency. However, the term 'desmoid' does not convey the cellular diversity as Batsakis (1971) explained. The term 'non-metastasizing fibrosarcoma' or 'well differentiated fibrosarcoma' has been applied because of its infiltrating and locally destructive characteristics and because it recurs repeatedly over many years. However, recurrence is not necessarily a criterion of malignancy: the use of the word 'sarcoma' should be discouraged because the surgeon when confronted with such a term might

perform a more radical operation, when a wide local block resection would have been adequate for the lesion (Fu and Perzin, 1976). The term 'musculo-aponeurotic fibromatosis' has been applied by Stout and Lattes (1967) and gained the favour of physicians because of its accurate and descriptive nature (Batsakis, 1974; Wilkins *et al.*, 1975).

Fibromatoses are relatively rare tumours. They were reported to represent 0.03 per cent of all tumours (Pack and Ehrlich, 1944). The absolute incidence was found by some authors to be two to four new cases per 10⁶ inhabitant per year (Reitamo *et al.*, 1982). The relative incidence of fibromatosis in the head and neck is difficult to determine. Masson and Soule (1966) cited 12 per cent of 284 cases from all locations of the body while Das Gupta *et al.* (1969) reported an incidence of 11.1 per cent of 72 cases of extra-abdominal fibromatosis. The supraclavicular fossa is the most common site for head and neck fibromatosis (40–85 per cent) followed by the face (about 25 per cent) (Conley *et al.*, 1966; Masson and Soule, 1966). Other sites in the head and neck were reported to be affected by fibromatosis: nasopharyngeal tract (Fu and Perzin, 1976), larynx (Rosenberg *et al.*, 1981), tongue (Schwartz and Ward, 1979) and the orbit (Craig and Studd, 1978).

Fibromatoses were found to be more common in the female with female/male ratio range between 3:2 (Masson and Soule, 1966) and 2:1 (Das Gupta *et al.*, 1969), although both sexes were equally affected in other reports (Conley *et al.*, 1966). The patients' age range from newborn to 70 years (Conley *et al.*, 1966) with most of cases appear in the third and fourth decades (Das Gupta *et al.*, 1969).

The causes of fibromatosis remain unknown with most suggestions focusing on trauma, endocrine or hereditary factors. Trauma has been incriminated because the histological resemblance of fibromatosis to the keloid and because several cases have been reported to follow trauma or surgery (Haeyry *et al.*,

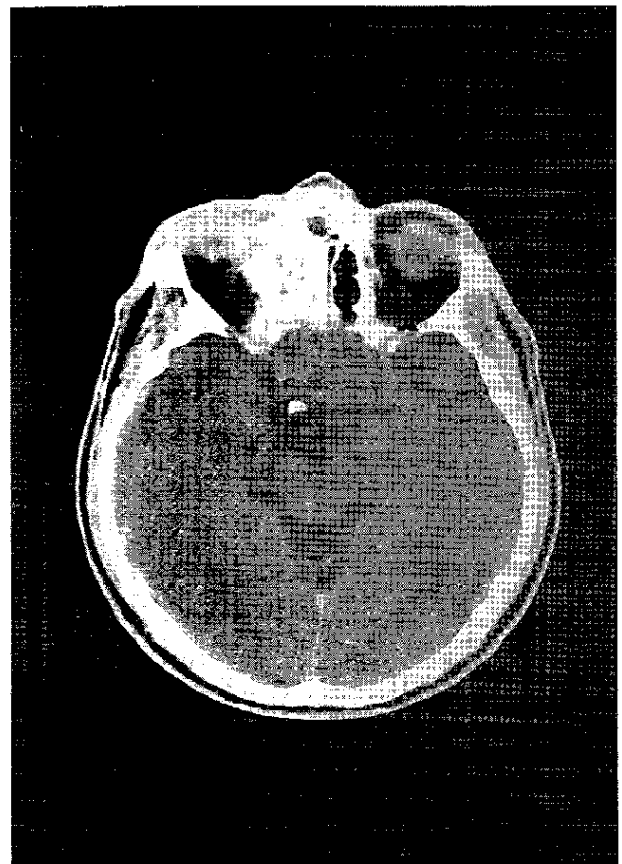


FIG. 4

CT scan of patient 2 demonstrates mass in the right ethmoid sinus with destruction of the ethmoid air cells and extension into the orbit.

,1982). Endocrine disturbance has been suggested as a cause of fibromatosis because some lesions were found to resolve following the menopause or radiation castration (Craig and Studd, 1978) and because small but significant amounts of oestrogen receptors were found in some cases (Haery et al. 1982). Evidence of the hereditary factors come from Haery *et al.* (1982) who found 80 per cent of fibromatosis patients displayed multiple connective tissue anomalies with similar findings in the skeleton of their relatives; the distribution pattern of these anomalies was compatible with an autosomal dominant trait. However, most authors reported that fibromatosis mostly appears sporadically without a recognized antecedent event (Conley *et al.*, 1966; Das Gupta *et al.*, 1969) and most patients have had no evidence of hormonal alteration (Schwartz and Ward, 1979).

The usual presenting symptom of fibromatosis is of a painless swelling that has been present for less than a year (Masson and Soule, 1966). The mass is often fixed to the underlying deep muscles or bony structure but not to the skin. Clinical features related to the anatomical site of fibromatosis may be present e.g. nasal obstruction, epistaxis, facial pain (Fu and Perzin, 1976), dysphonia, stridor (Rosenberg *et al.*, 1981) or proptosis (Craig and Studd, 1978). Vital structures may be encroached upon causing neural, circulatory and inspiratory embarrassment. An erroneous clinical diagnosis of an inflammatory or a malignant process is usually made.

On macroscopic examination, the lesion is greyish white and firm or rubbery in consistency. Its long axis is usually oriented in the direction of the muscle bundle in which it is found. It is not encapsulated and the border is ill-defined due to its tendency to infiltrate the surrounding structures. It can encase vascular and neural structure without apparent invasion, which may account for the lack of pain clinically.

Microscopically, fibromatosis is composed of well differentiated fibrous tissue which is usually highly cellular. Mitosis is rare and typical. The tumour shows microscopic infiltration, into adjacent tissue particularly striated muscle fibres with the formation of multinucleated giant cells, and lymphocytic infiltrate.

Some cases of fibromatosis may show relatively sparse cellularity and produce abundant collagen; a biopsy from the centre of such lesion may be mistaken for scar tissue. Histological diagnosis is most readily made at the margin; in some cases only the behaviour of the lesion (infiltration into adjacent tissue, progressive increase in size *etc.*) may indicate its true nature (Fu and Perzin, 1976).

Errors in histological diagnosis are seen in the literature (Wilkins *et al.*, 1975; Fu and Perzin, 1976). In the series of Das Gupta *et al.* (1969) the correct diagnosis was made in only 50 per cent of those patients with a primary tumour and in only 70 per cent of those patients with a recurrence, after the pattern of this had been established. Histologically, fibromatosis must be differentiated from keloid, fibroma, fibrosarcoma, fibrous dysplasia, ossifying fibroma, myxoma, angiofibroma, subfacial lipoma, dermatofibroma, neurofibroma, rhabdomyosarcoma and haemangioendothelioma. The problems involved in differentiating histologically the fibromatoses with other mesenchymal lesions are discussed in detail by Fu and Perzin (1976).

The primary consideration in the treatment of fibromatosis is the prevention of local recurrence (Das Gupta *et al.*, 1969). Complete three dimension excision of the tumour is considered to be the only effective method of cure by most authors (Conley *et al.*, 1966; Fu and Perzin, 1976). Some clinicians believe that when the lesion is located in the neck, this is best accomplished by a radical neck dissection (Das Gupta *et al.*, 1969). Long term follow-up is necessary because regrowth or recurrence could occur after a long period of stabilization (Das Gupta *et al.*, 1969).

Complete extirpation of the tumour, however, may be difficult or impossible to achieve in the head and neck because of the proximity or involvement of an important structure, or if the potential morbidity of the resection is not acceptable to the patient. For those patients judged technically or medically inoperable, radiation or drug therapy may be considered.

The role of radiation therapy in treatment of fibromatosis is controversial. Some authors have judged radiation to be of limited value in the curative treatment of fibromatosis (Musgrove and McDonald, 1948; Fu and Perzin, 1976). More recently, there have been several reports documenting that complete and long-term regression may be achieved using modern equipment and a dose greater than 50 Gy (Leibel *et al.*, 1983; Keil and Suit, 1981). Regression may be quite slow (longer than two years in some cases), even in successfully treated patients. Radiotherapy may also be considered post-operatively after incomplete resection: although Keil and Suit (1984) recommended careful and frequent follow-up for young patients without macroscopically evident disease but minimally positive or uncertain margins after resection of a primary tumour.

In general, there was and is no accepted consistently successful drug therapy for fibromatosis (Waddel *et al.*, 1983). Anti-oestrogen drugs like testolactone and tamoxifen have been used because they restrict RNA synthesis and inhibit cyclic adenosine monophosphate (AMP) phosphodiesterase (Waddel *et al.*, 1983). Also non-steroidal anti-inflammatory drugs (such as indomethacin and sulindac) and large doses of ascorbic acid have been used in the treatment of fibromatosis because they inhibit prostaglandin synthesis which impairs the proliferative capacity of tumour cells and at the same time stimulate an immunological response (Waddel *et al.*, 1983). Meanwhile anti-cancer chemotherapy has been reported to produce partial or complete regression of fibromatosis (West *et al.*, 1989). Consequently, pre-operative chemotherapy may be considered for patients with such tumours occurring in the head and neck areas.

The high rate of recurrence is one of the most common characteristics among the various types of fibromatoses (West *et al.*, 1989). Patients with head and neck fibromatosis have a higher rate of recurrence (70 per cent) compared with patients with such a tumour in other locations (50 per cent) (Masson and Soule, 1966). Whether this is due to a more aggressive tumour or to a technically more difficult excision in this region, is unclear (West *et al.*, 1989).

Length of time to recurrence varies from two months to eleven years (Fu and Perzin, 1976; Leibel *et al.*, 1983). Recurrent lesions are similar in appearance to the primary tumour, are often multiple and may occur in the operative scar (Reitamo, 1983).

Spontaneous complete regression of fibromatosis has been documented (Fu and Perzin (1976) reported involution of multiple fibromatosis, but the authors stated that these rare cases apparently have markedly different biological properties as compared to ordinary fibromatosis.

Fibromatosis almost never transform into fibrosarcoma. Of the more than 1500 cases of fibromatosis analyzed, a transformation to fibrosarcoma was reported on only two occasions, and one of these cases is dubious as the primary diagnosis was not solidly established (Reitamo, 1983).

The prognosis of fibromatosis depends entirely upon the initial treatment; if this is inadequate, the tumour will recur and progress, but if the lesions can be extirpated almost all patients will be cured (Masson and Soule, 1966; Das Gupta *et al.*, 1969). A five-year cure rate of 79 per cent was reported by Conley *et al.* (1966). A tumour considered inoperable can be fatal, usually by compression of vital structure (Masson and Soule, 1966; Fu and Perzin, 1976).

Acknowledgements

I would like to express my thanks and gratitude to Prof. Siraj M. Zakzouk for permitting me to report his cases. My thanks also to Mrs Tess Reyes for her secretarial work.

References

- Batsakis, J. G. (1974) Fibrous lesions of the head and neck: Benign, malignant and indeterminate. In: *Tumors of Head and Neck*. Williams & Wilkins, Baltimore. pp. 180-184.

- Conley, J., Healey, W. V., Stout, A. P. (1966) Fibromatosis of the head and neck. *American Journal of Surgery*, **112**: 609-614.
- Craig, R. D. P., Studd, D. (1978) Extra-abdominal desmoid of the face involving the orbit. *British Journal of Surgery*, **65**: 131-134.
- Das Gupta, T. K., Brasfield, R. D., O'Hara, J. (1969) Extra-abdominal desmoid: A clinicopathological study. *Annals of Surgery*, **170**: 109-121.
- Fu, Y. S., Perzin, K. H. (1976) Non-epithelial tumors of the nasal cavity, paranasal sinuses and nasopharynx. *Cancer*, **37**: 2912-2928.
- Haery, P., Reitamo, J. J., Totterman, S., Hopfner-Hallikainen, D., Sirula, A. (1982) The desmoid tumor II. Analysis of factors possibly contributing to etiology and growth behaviour. *American Journal of Clinical Pathology*, **77**: 674-680.
- Kiel, K.D., Suit, H. D. (1984) Radiation therapy in the treatment of aggressive fibromatosis. *Cancer*, **54**: 2051-2055.
- Leibel, S. A., Wara, W. M., Hill, D. R., Bovill, E. G. Jr., de Lorimier, A. A., Beckstead, J. H., Phillips, T. L. (1983) Desmoid tumors. Local control and patterns of relapse following radiation therapy. *International Journal of Radiation, Oncology, Biology and Physics*, **9**: 1167-1171.
- Masson, J.K., Soule, E. H. (1966) Desmoid tumors of the head and neck. *American Journal of Surgery*, **112**: 615-622.
- Pack, G.T., Ehrlich, H. E. (1944) Neoplasms of the anterior abdominal wall with special consideration of desmoid tumors: Experience with 391 cases and a collective review of the literature. *International Abstract of Surgery*, **79**: 177.
- Reitamo, J. J. (1983) The desmoid tumor. Choice of treatment, results and complications. *Archives of Surgery*, **118**: 1318-1322.
- Reitamo, J.J., Haery, P., Nykyrin, E., Saxen, E. (1982) The desmoid tumor. I. Incidence, sex, age and anatomical distribution in the Finnish population. *American Journal of Clinical Pathology*, **77**: 665-673.
- Rosenberg, H. S., Vogler, C., Close, L. G., Warshaw, H. E. (1981) Laryngeal fibromatosis in the neonate. *Archives of Otolaryngology*, **107**: 513-517.
- Schwartz, H. E., Ward, P. H. (1979) Aggressive fibromatosis of the tongue. *Annals of Otolaryngology, Rhinology and Laryngology*, **88**: 12-15.
- Stout, A. P., Lattes, R. (1967) Tumors of the soft tissue. In: *Atlas of Tumor Pathology*, 2nd Series Armed Forces Institute of Pathology, Washington, D.C. p. 17-31.
- Waddell, W. R., Gerner, R.E., Reich, M. P. (1983) Nonsteroid anti-inflammatory drugs and tamoxifen for desmoid tumors and carcinoma of the stomach. *Journal of Surgical Oncology*, **22**: 197-211.
- West, C. B., Shagets, F. W., Mansfield, M.J. (1989) Non-surgical treatment of aggressive fibromatosis in the head and neck. *Otolaryngology—Head and Neck Surgery*, **101**: 338-343.
- Wilkins, S. A., Waldron, G. A., Mathews, W. H., Droulias, C. A. (1975) Aggressive fibromatosis of the head and neck. *American Journal of Surgery*, **130**: 412-415.

Address for correspondence:
 Yousry El-Sayed, F.R.C.S.,
 Department of ORL,
 King Abdul Aziz University Hospital,
 P.O. Box 245,
 Riyadh 11411,
 Saudi Arabia.

Key words: Fibromatosis; Head and neck neoplasms