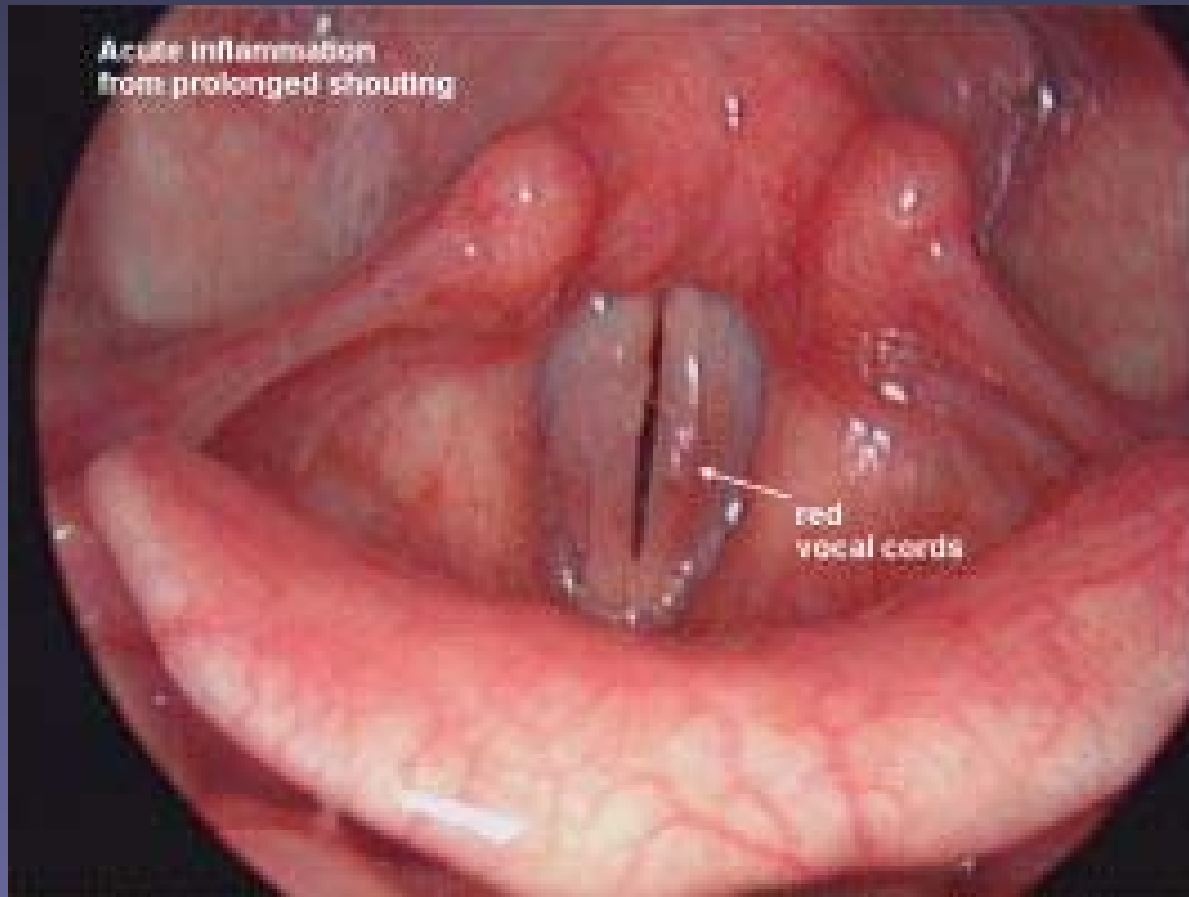
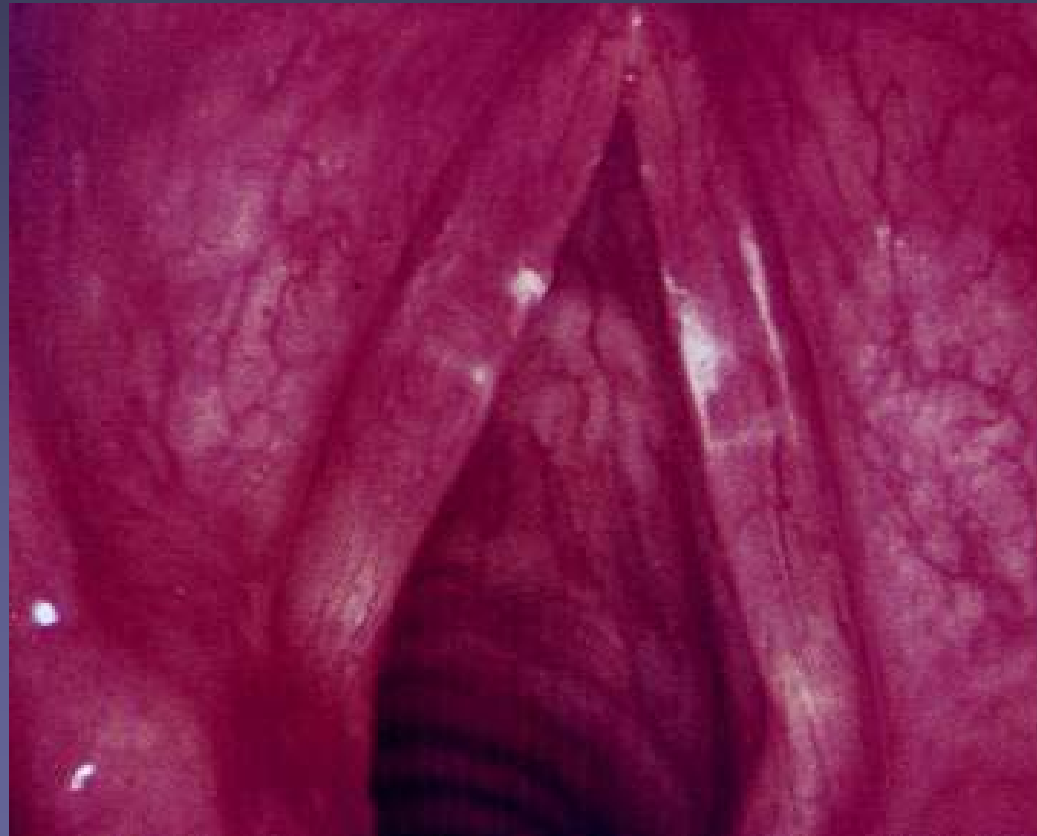


Acute and chronic infections of the larynx

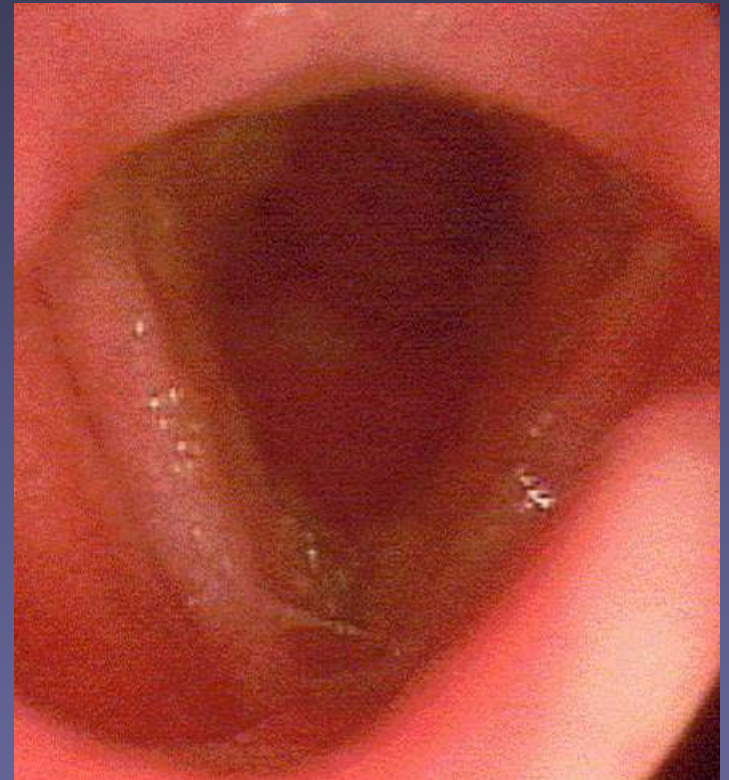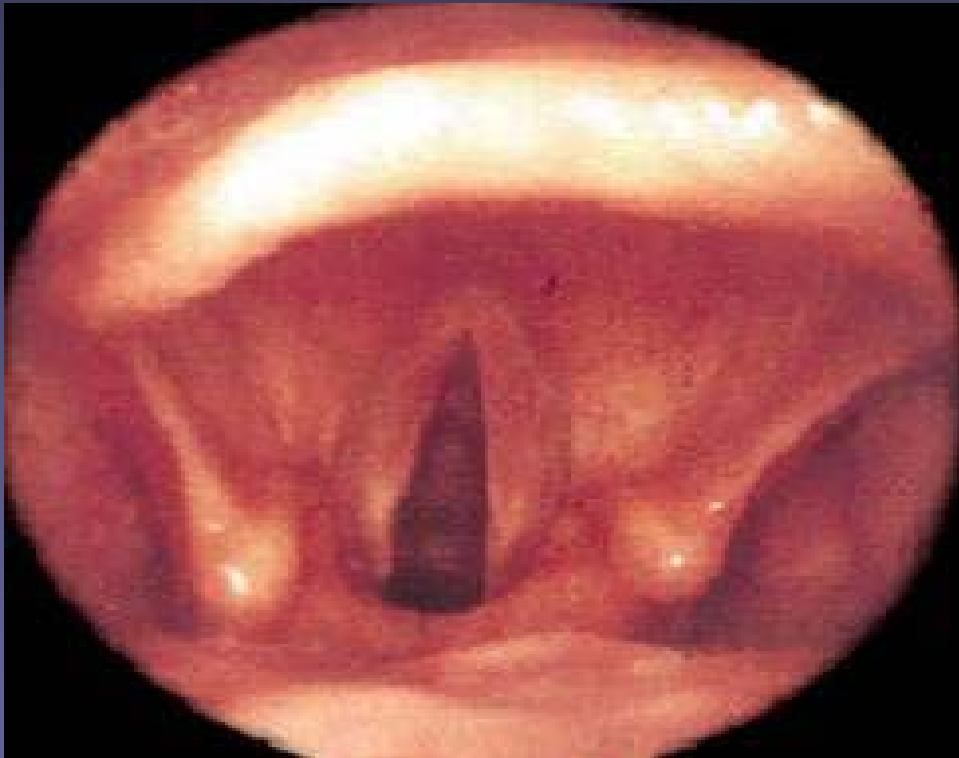
Acute Laryngitis



Acute Laryngitis



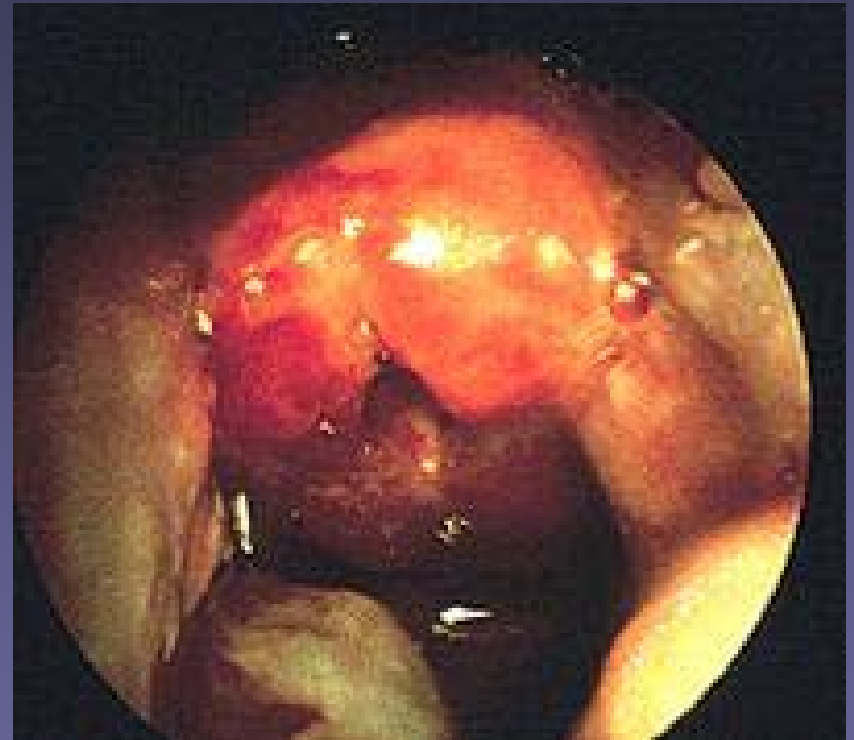
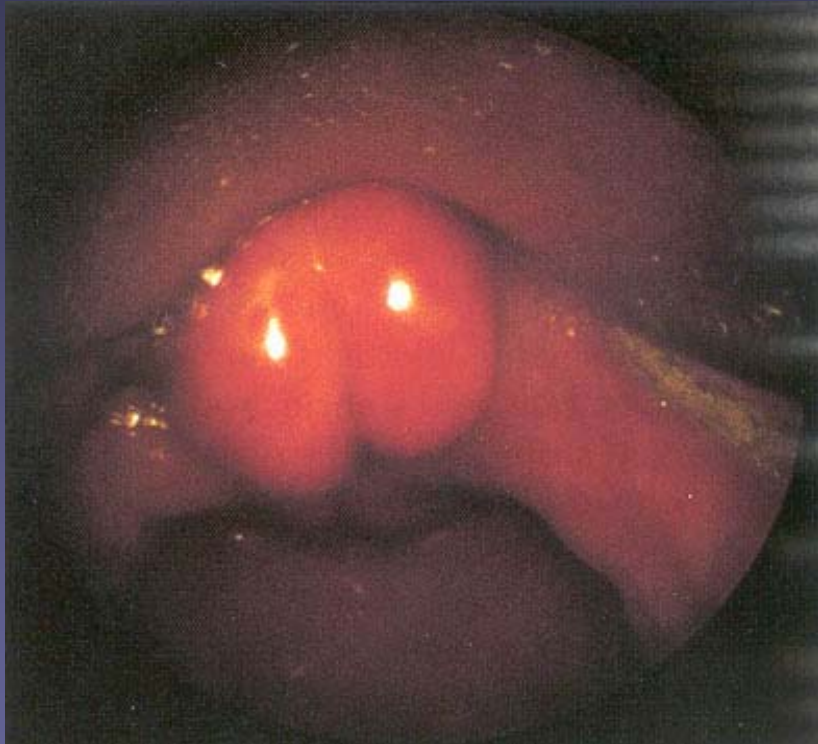
Acute Laryngitis



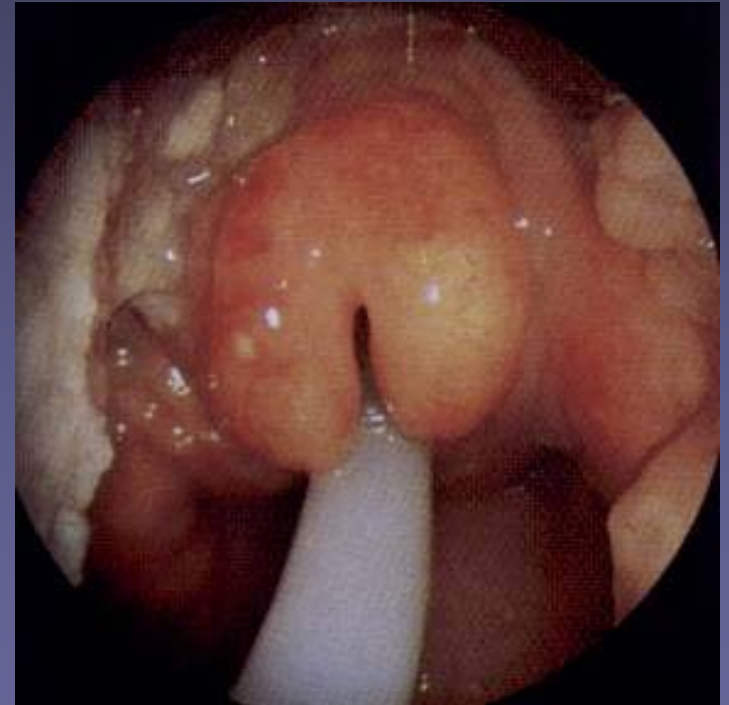
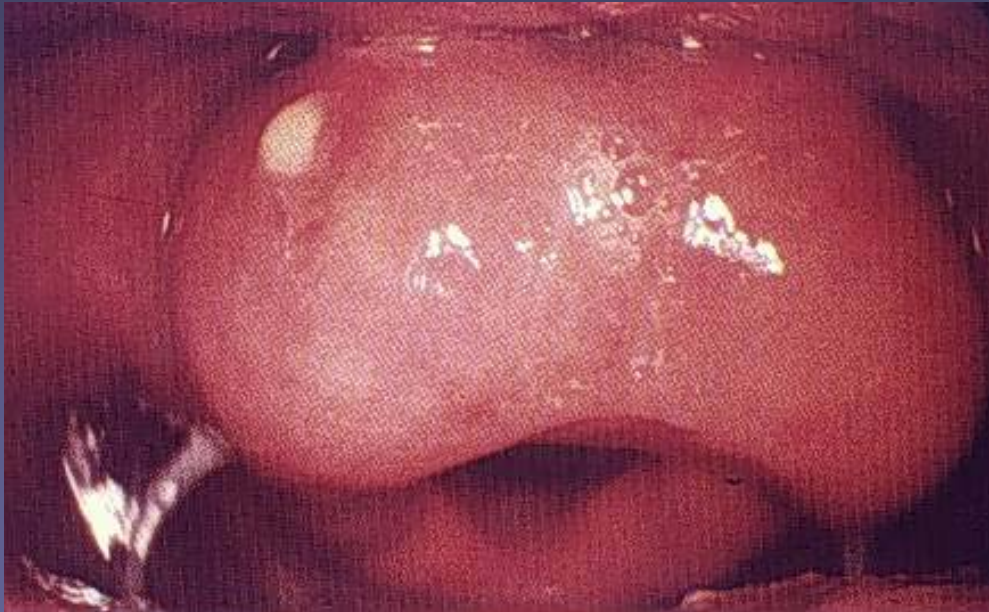Humidification



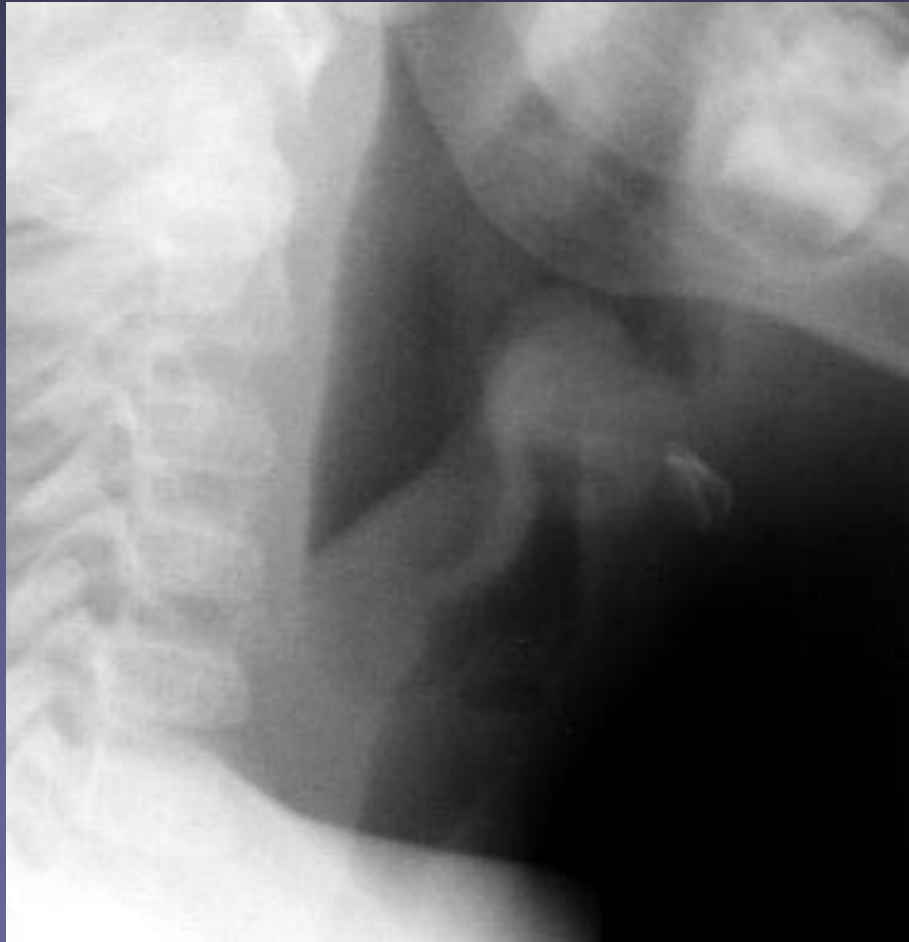Acute Epiglottitis



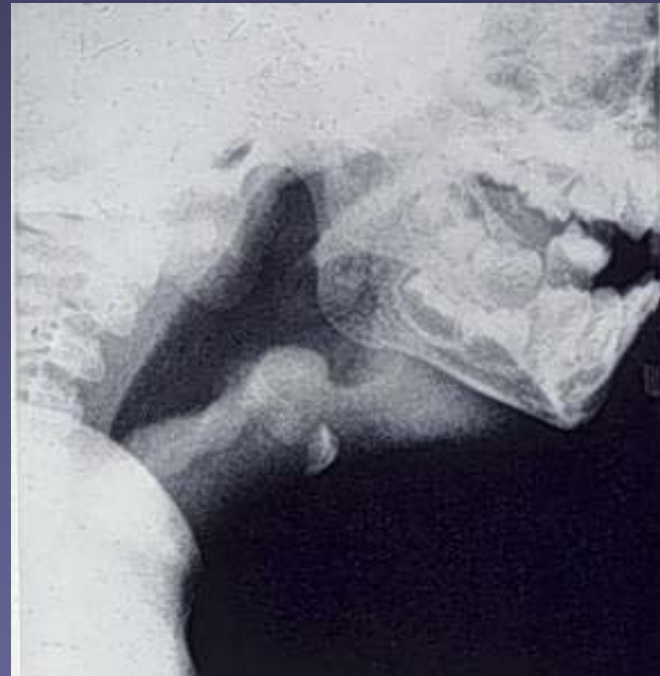
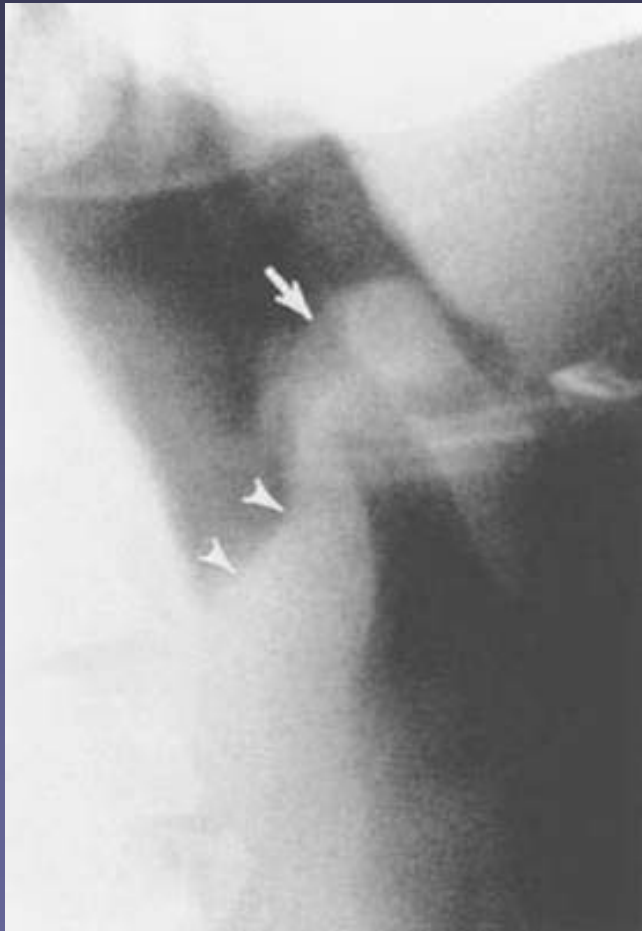
Acute Epiglottitis



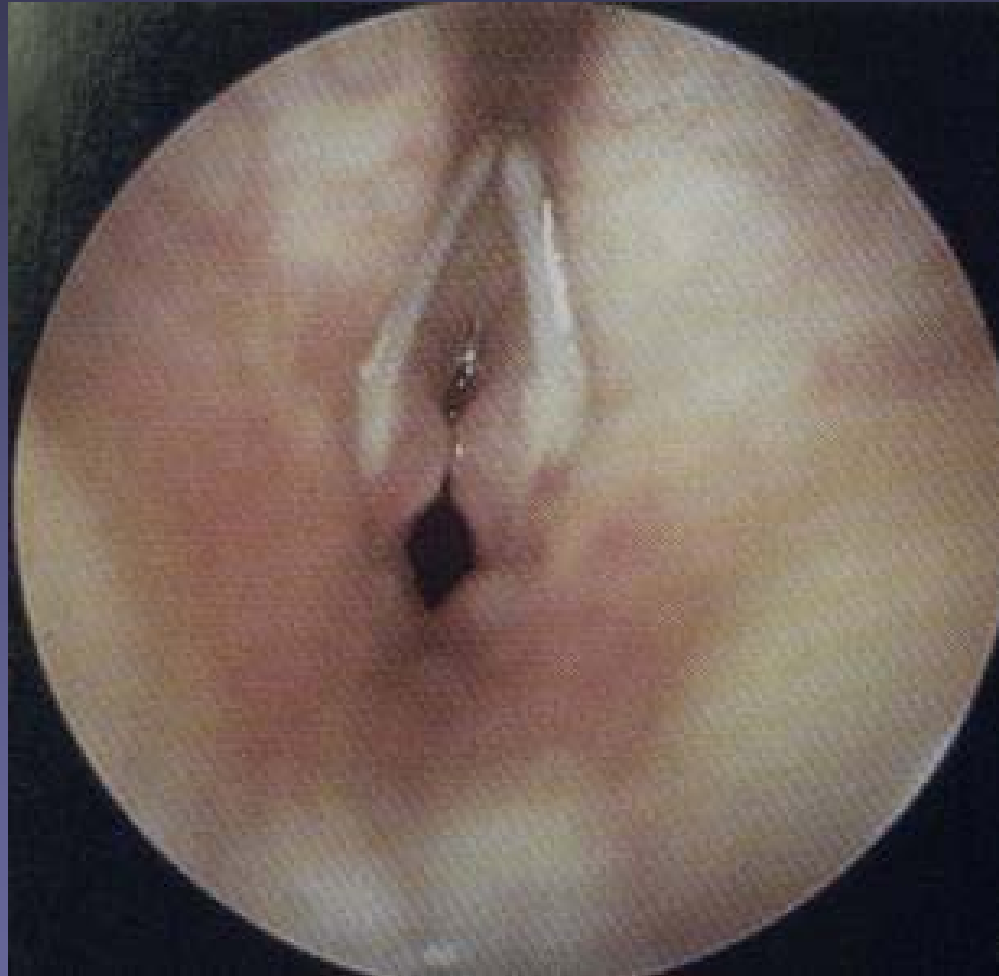Acute Epiglottitis (Thumb Sign)



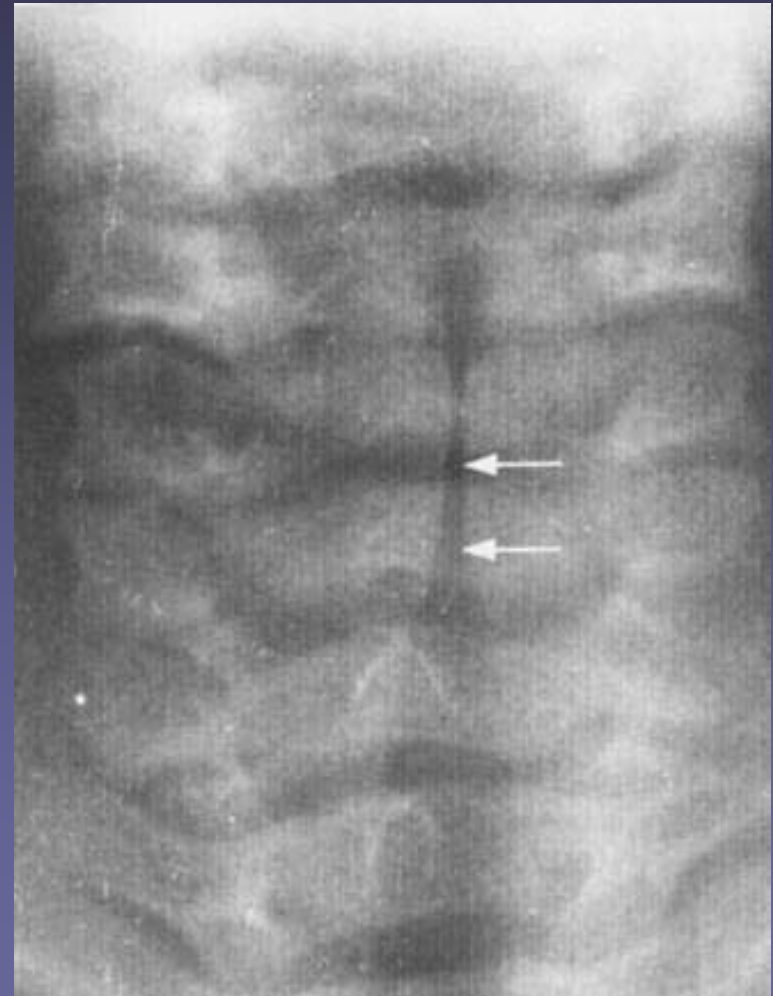
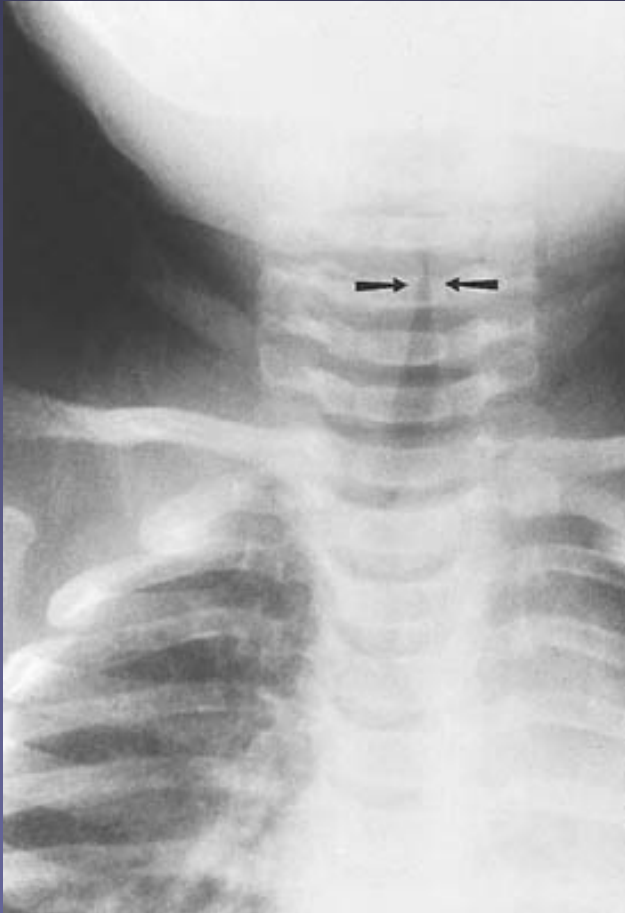
Acute Epiglottitis (Thumb Sign)



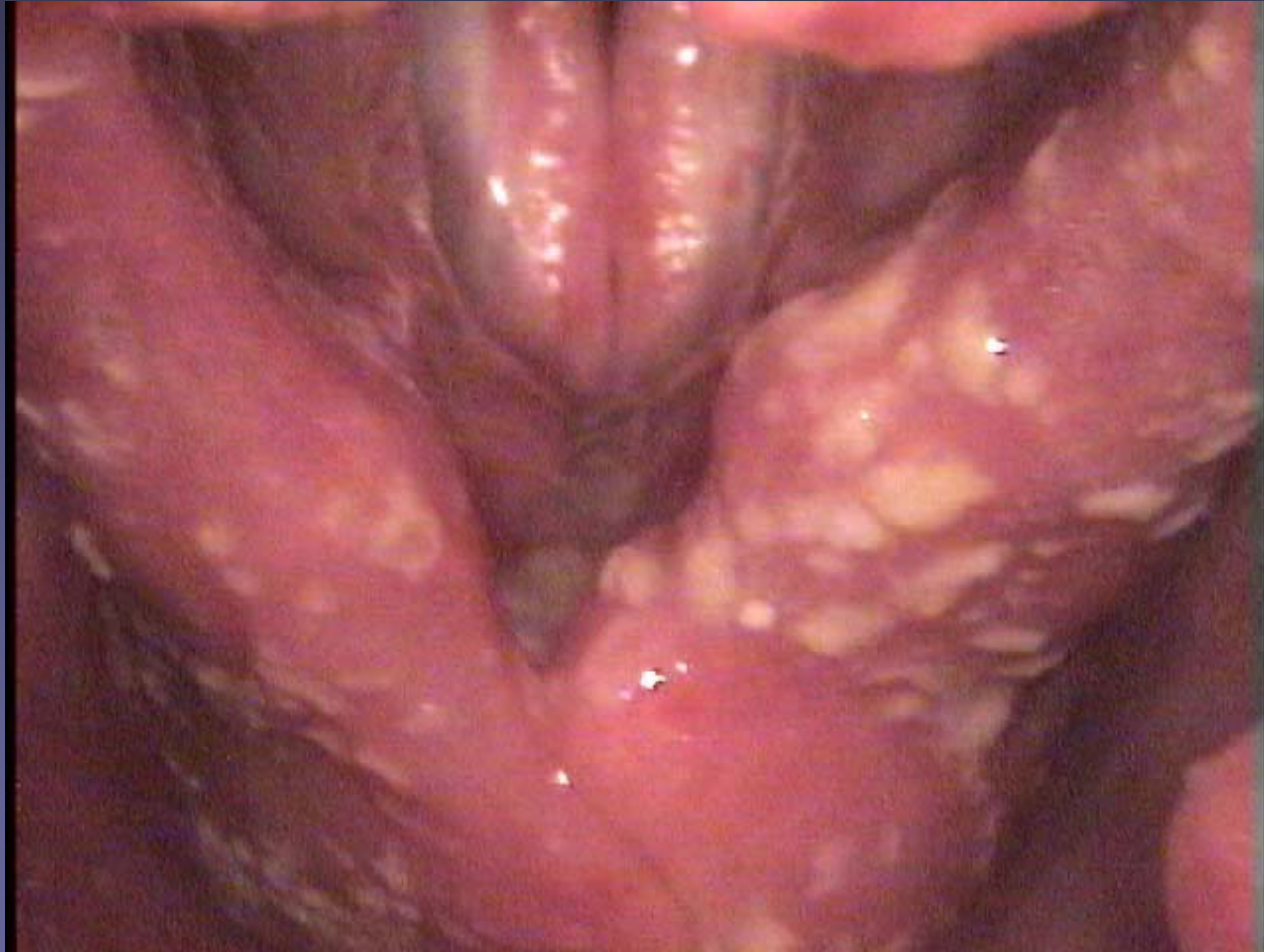Croup



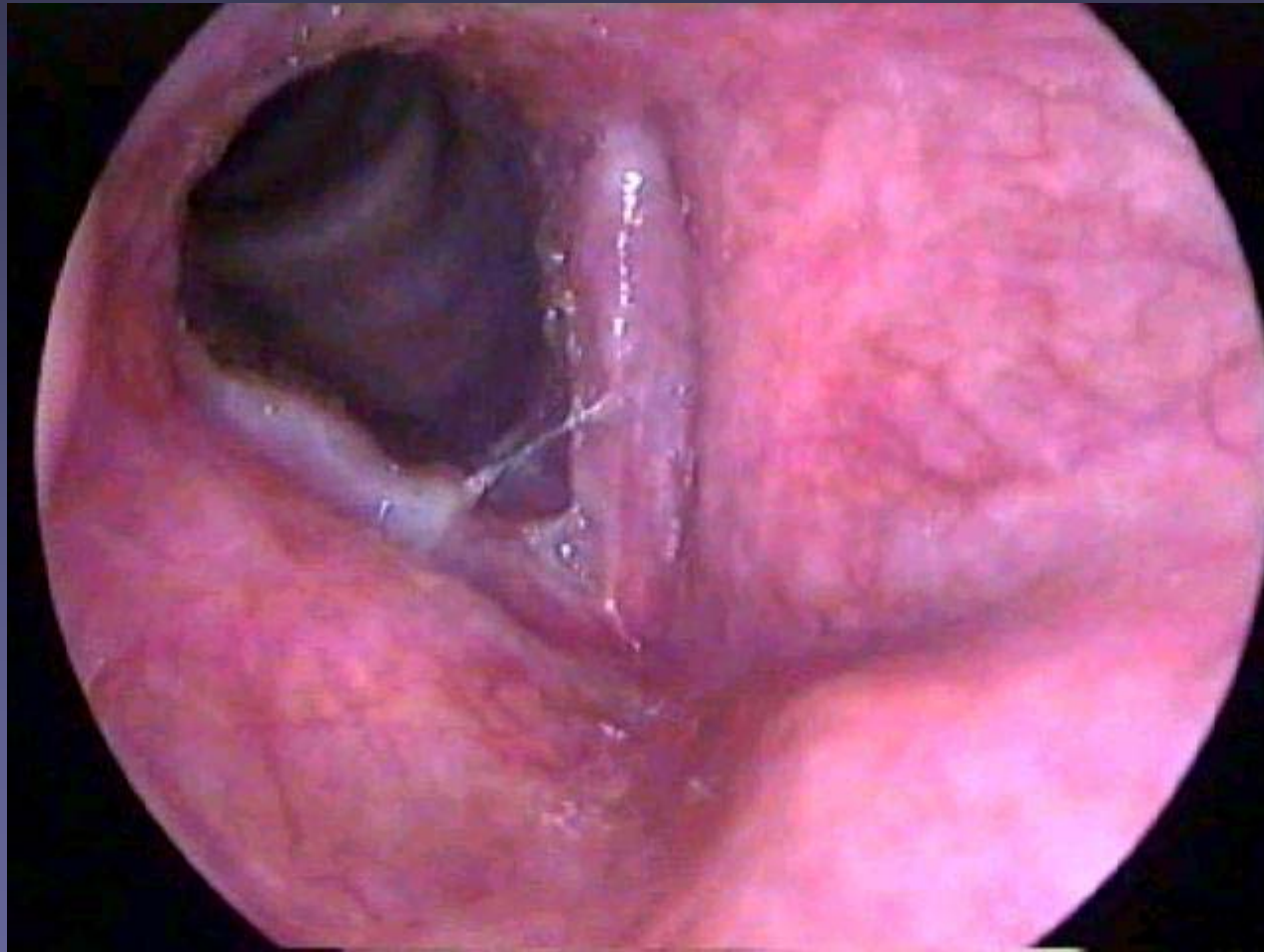
Croup (Steeple sign)



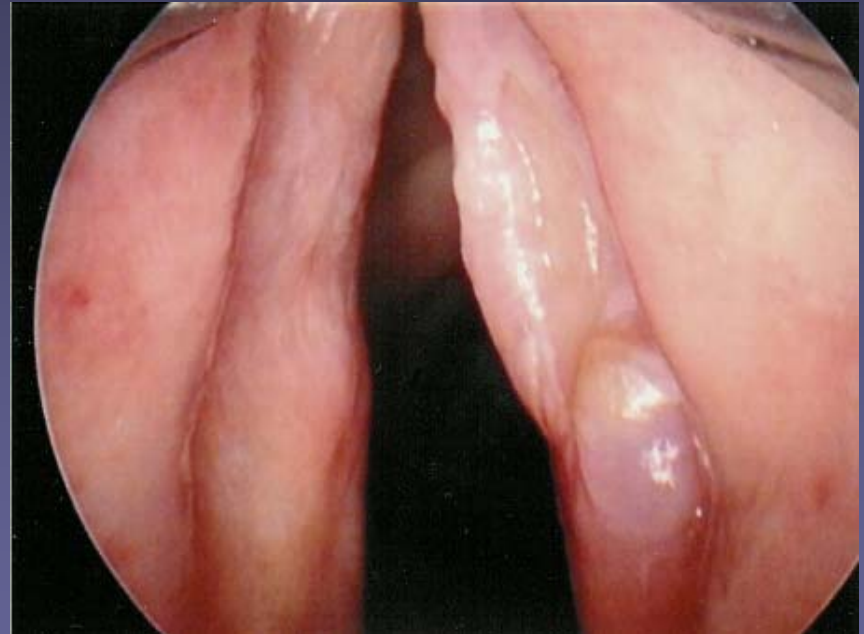
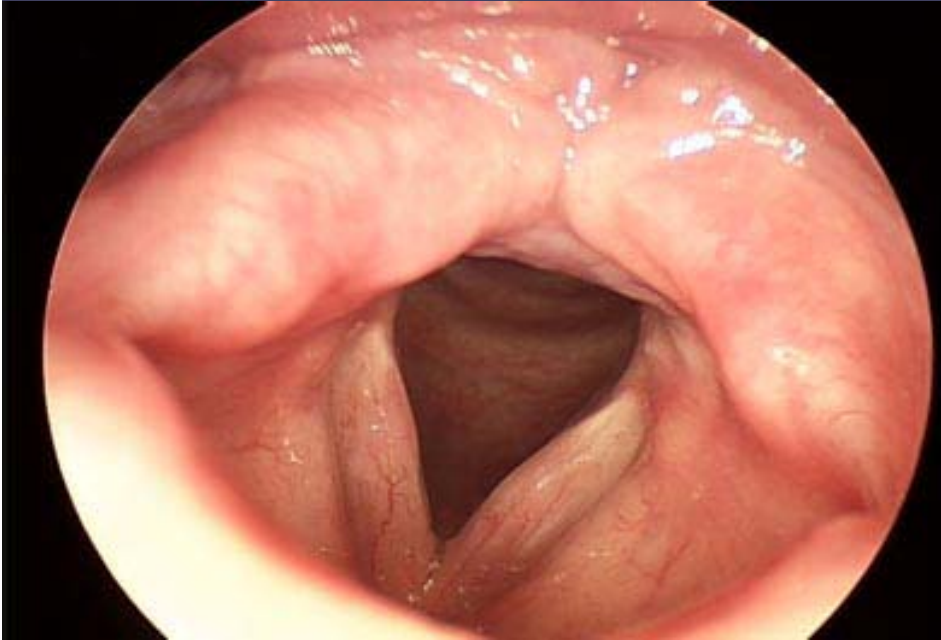
Moniliasis



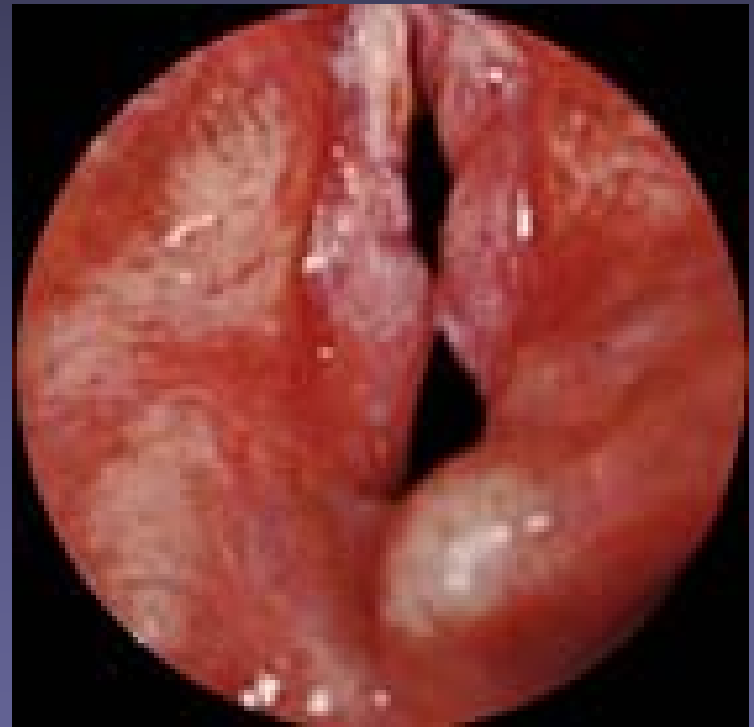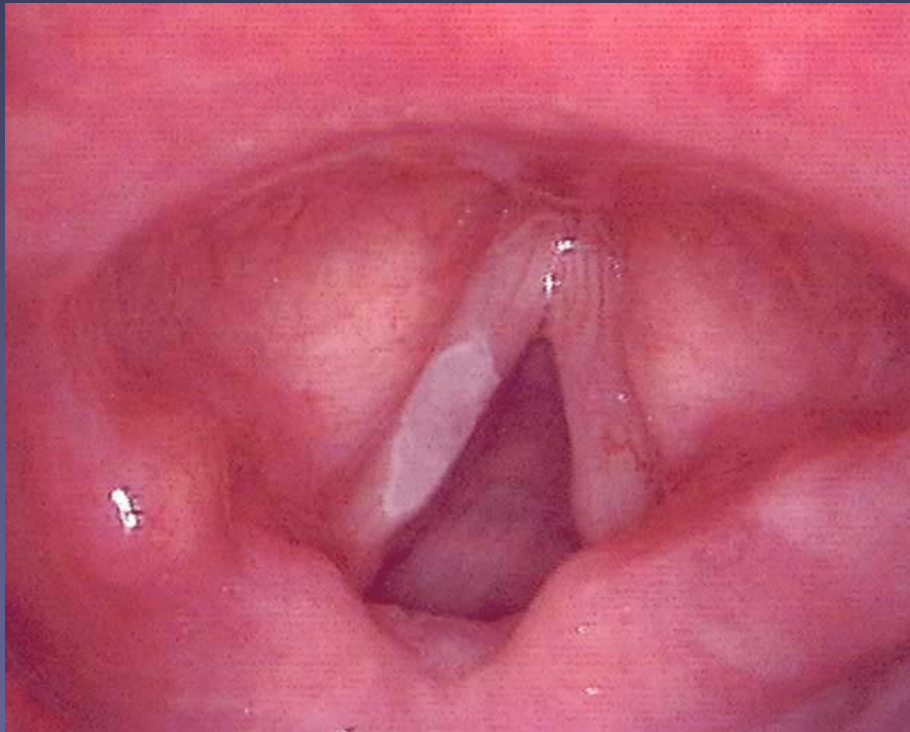
Chronic laryngitis



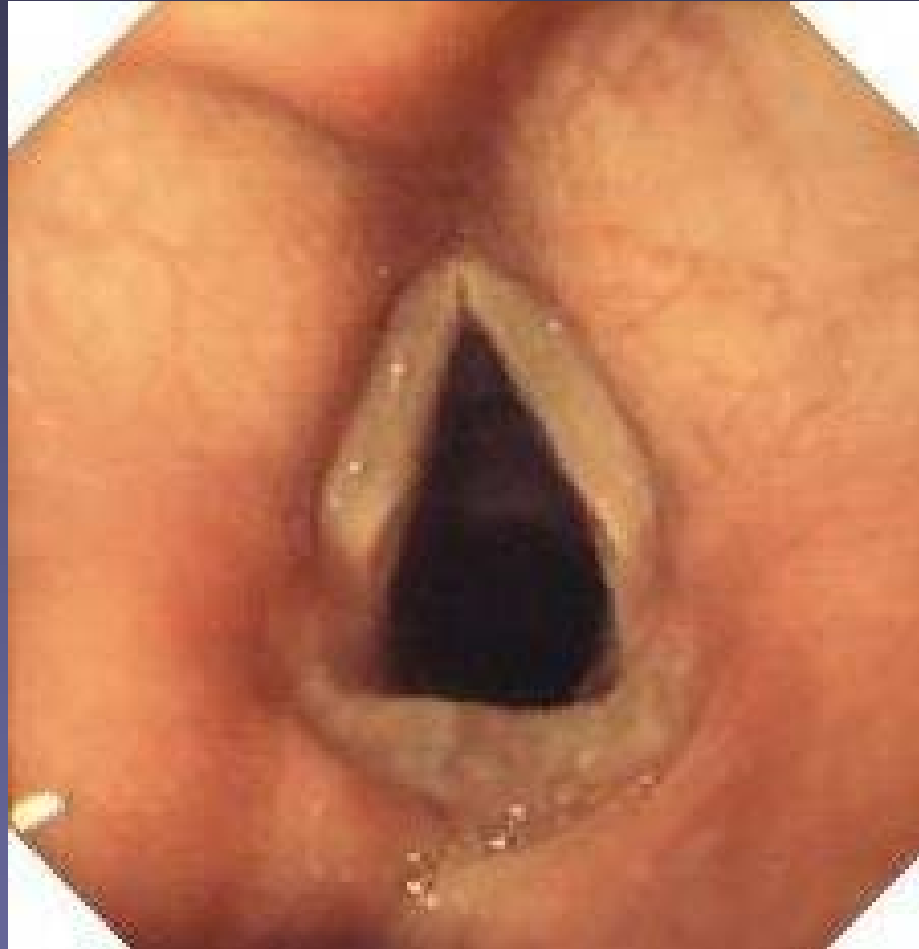Chronic laryngitis



Hyperkeratosis (Leukoplakia)



Chronic reflux laryngitis



Laryngitis sicca

