

Congenital Diseases of the Larynx

Figure 1: Infant, Good First Impression

Healthy infant appears alert
with good muscle tone


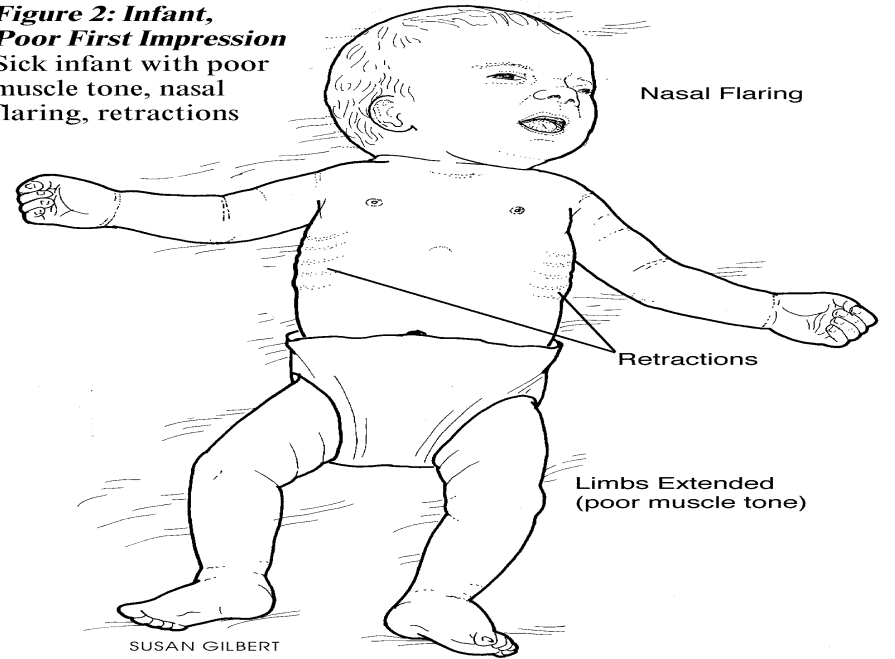
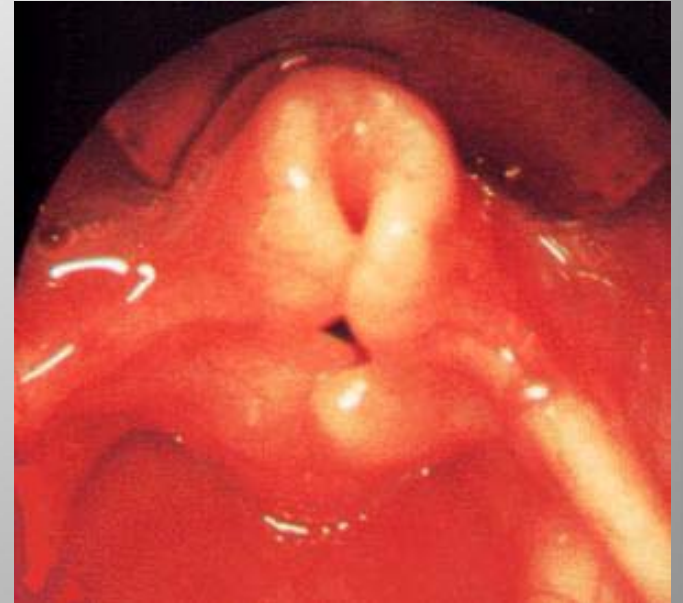
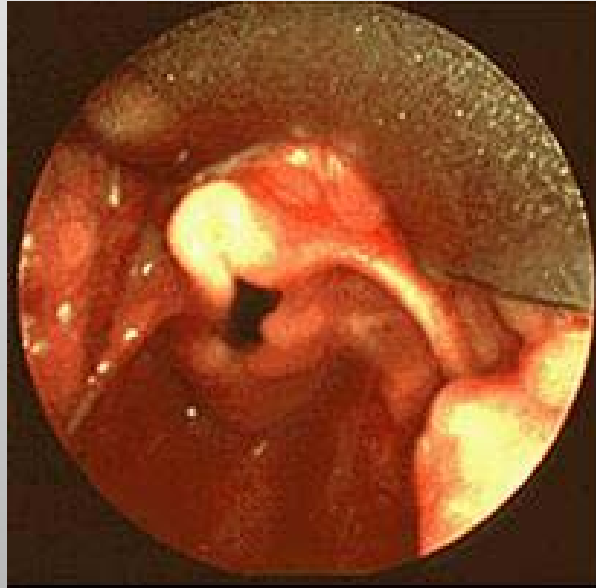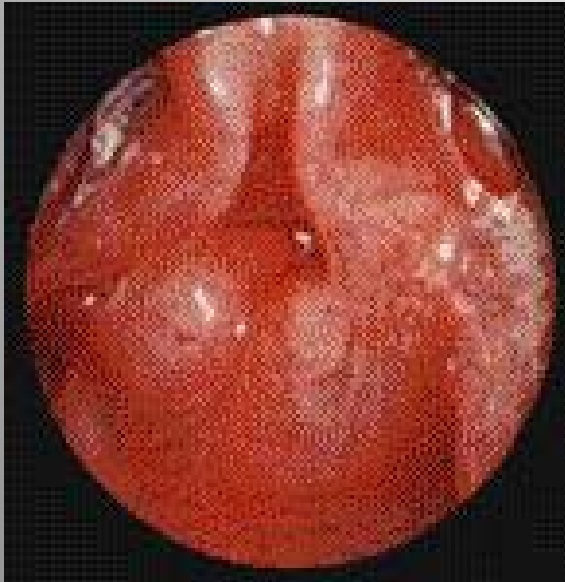


Figure 2: Infant, Poor First Impression

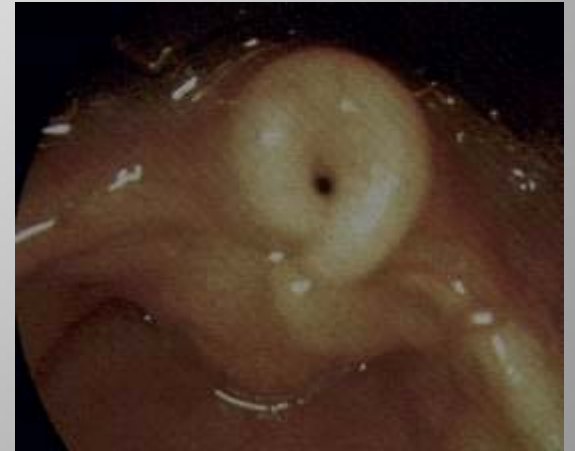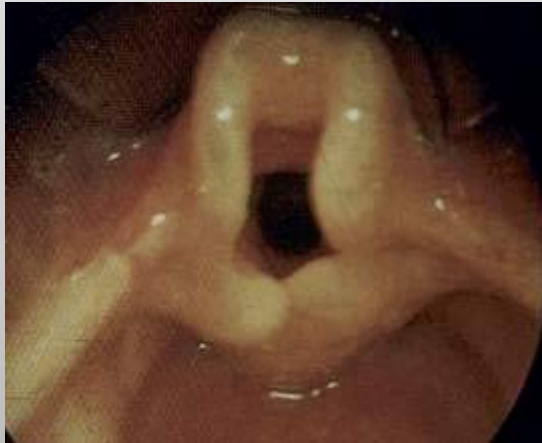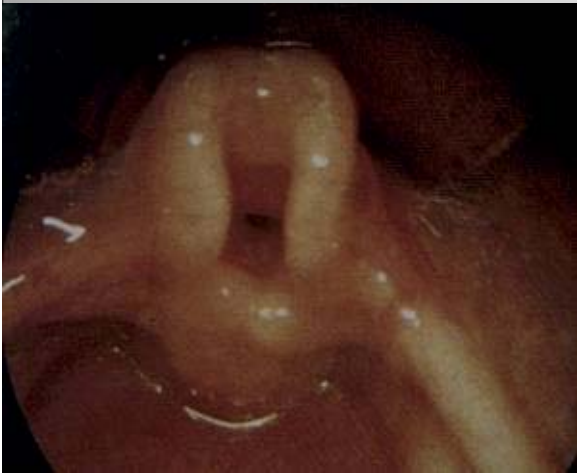Sick infant with poor
muscle tone, nasal
flaring, retractions



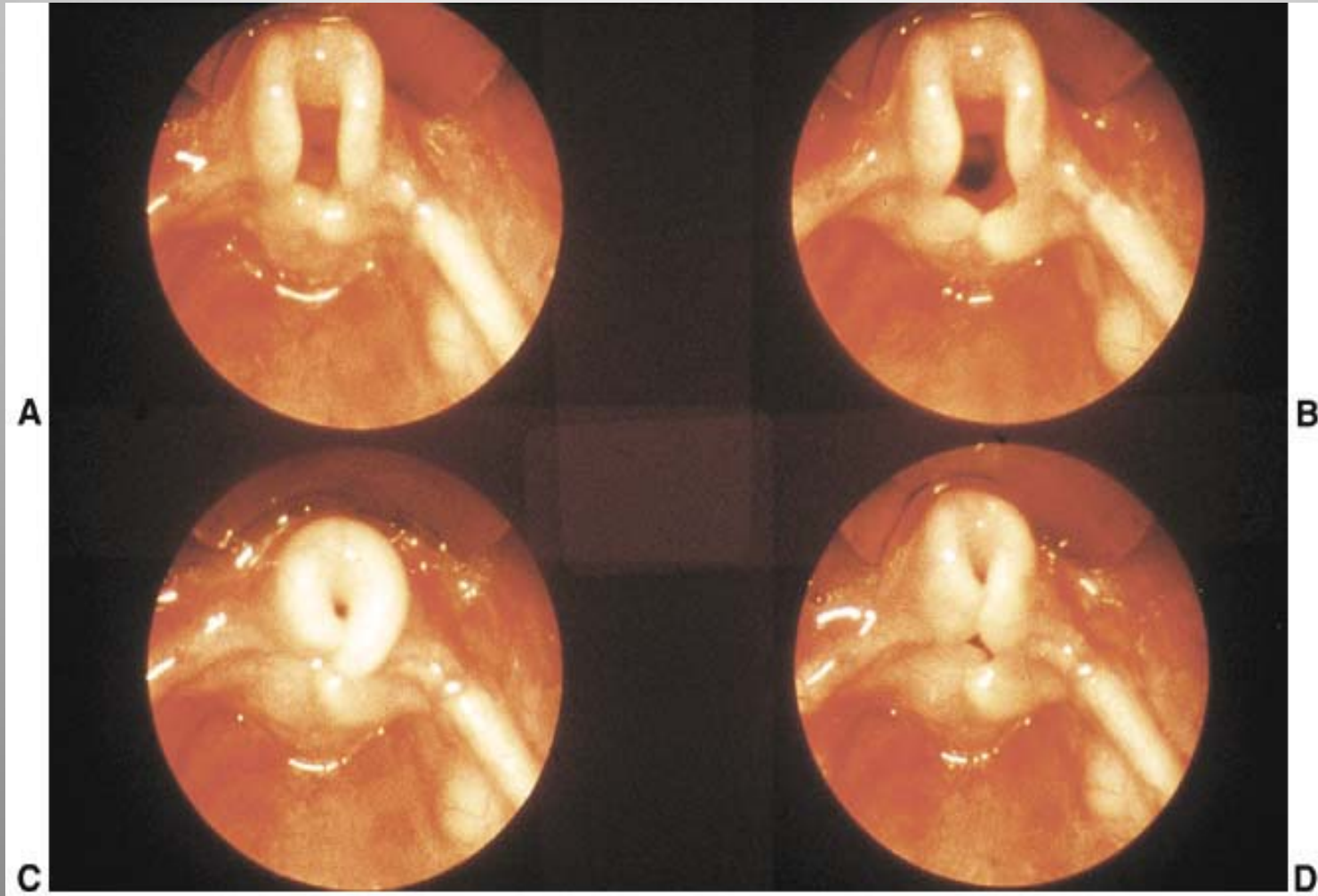
Laryngomalacia



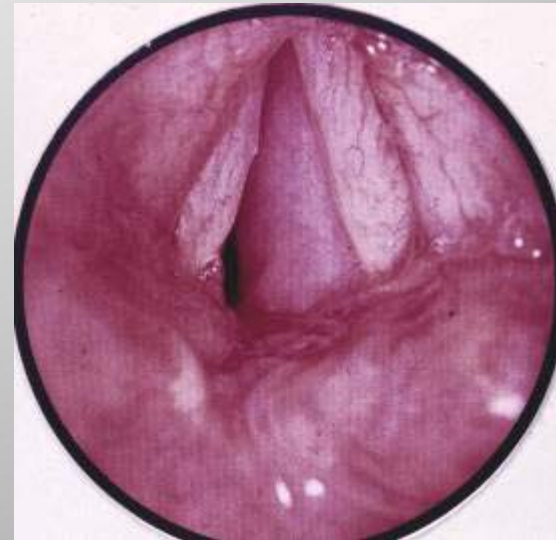
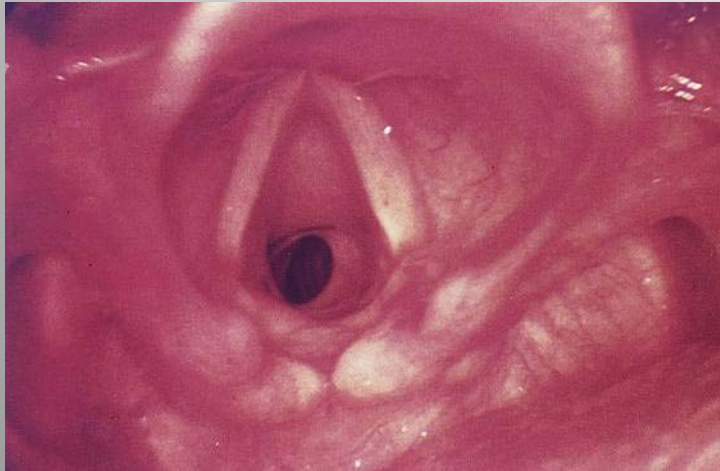
Laryngomalacia



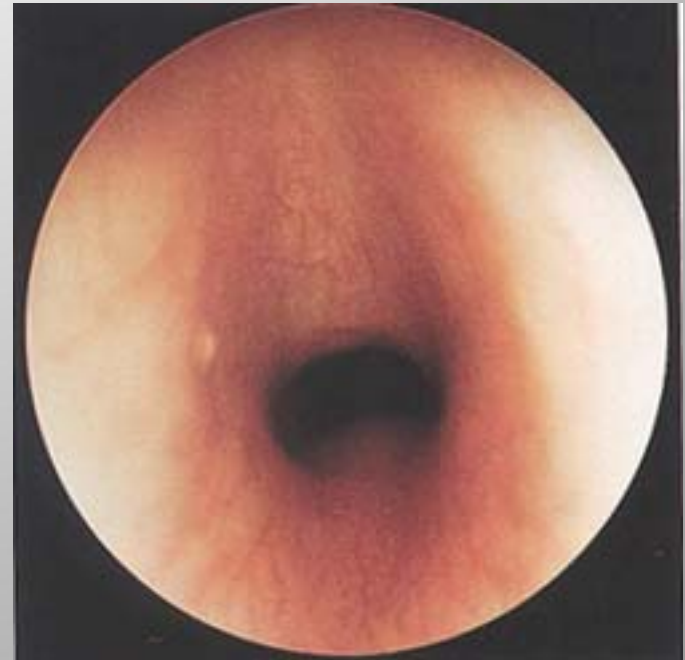
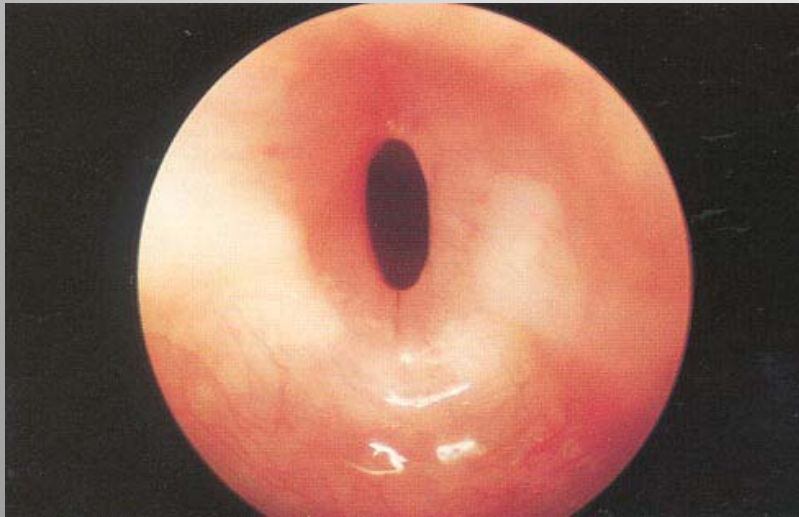
Laryngomalacia



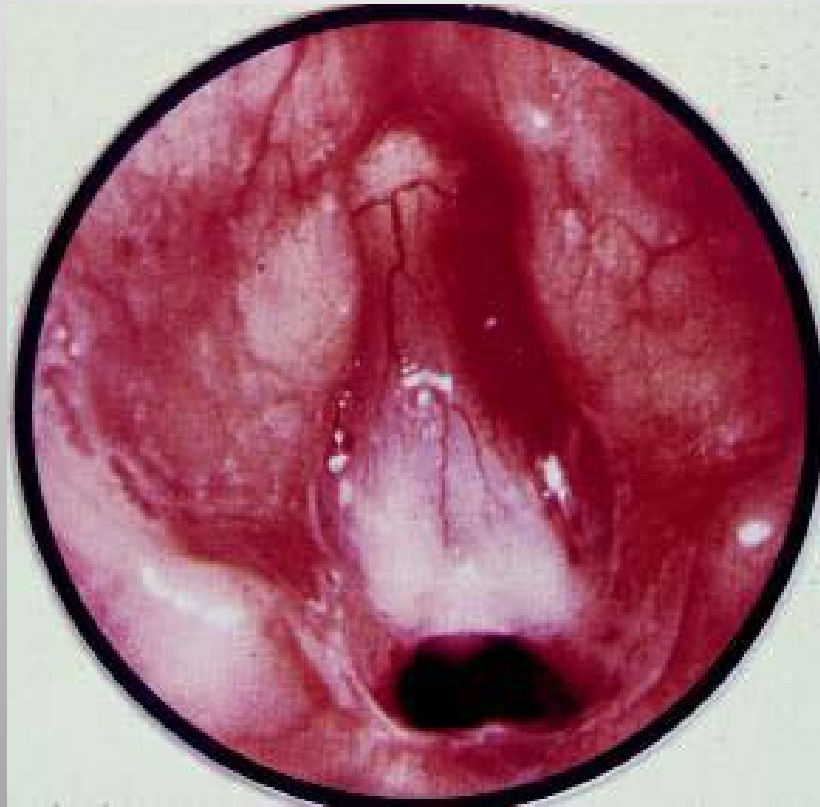Congenital subglottic stenosis



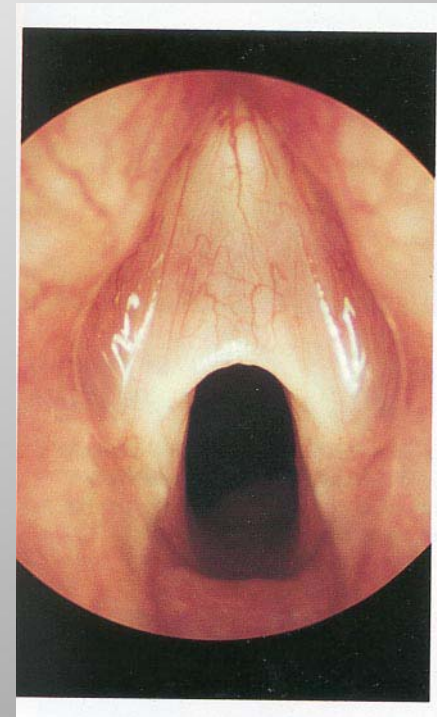
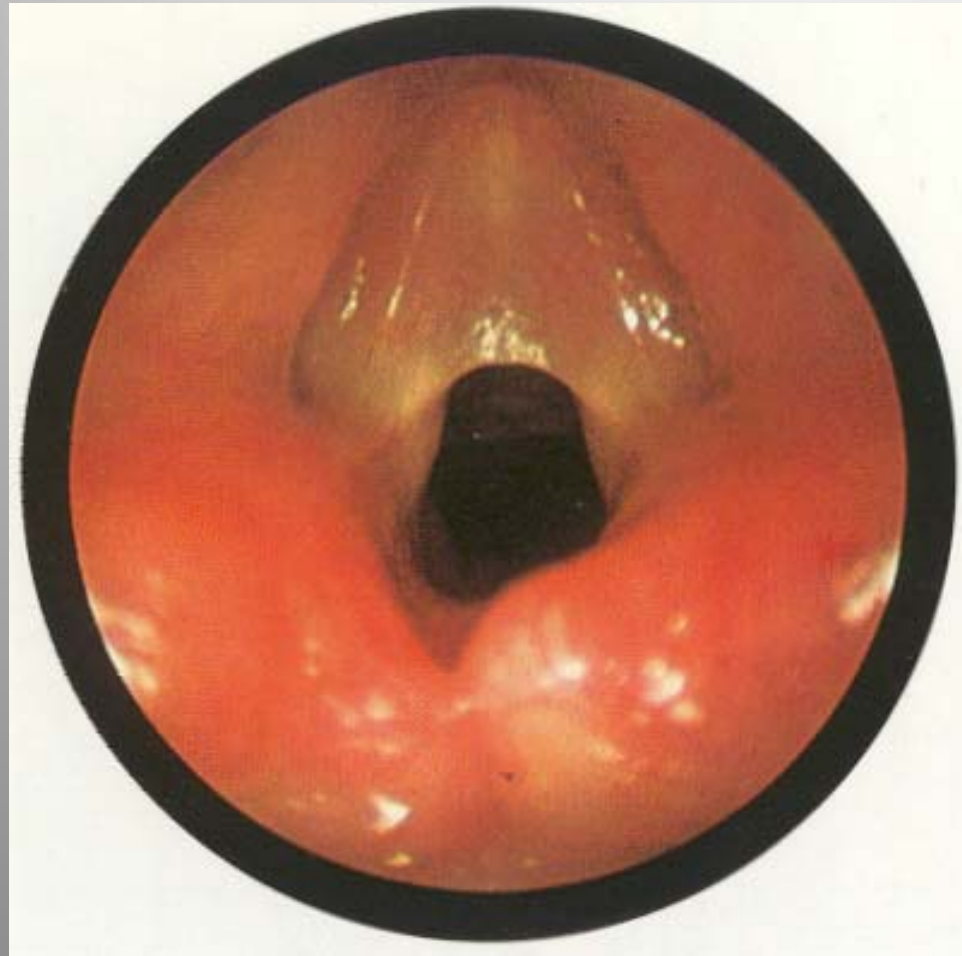
Congenital subglottic stenosis



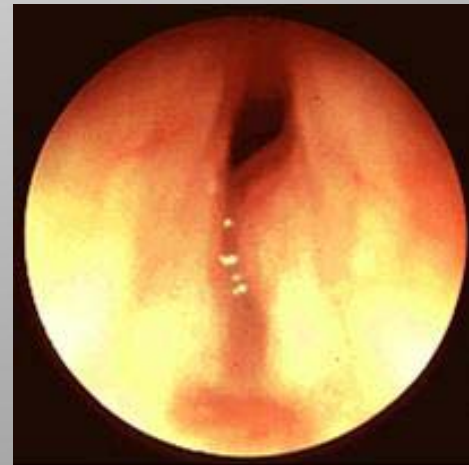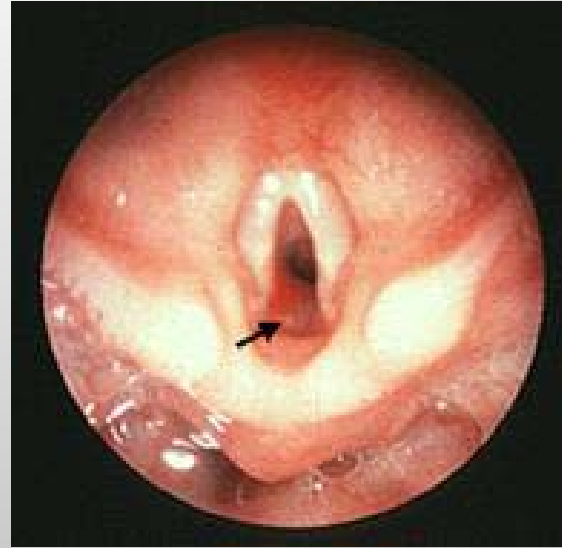
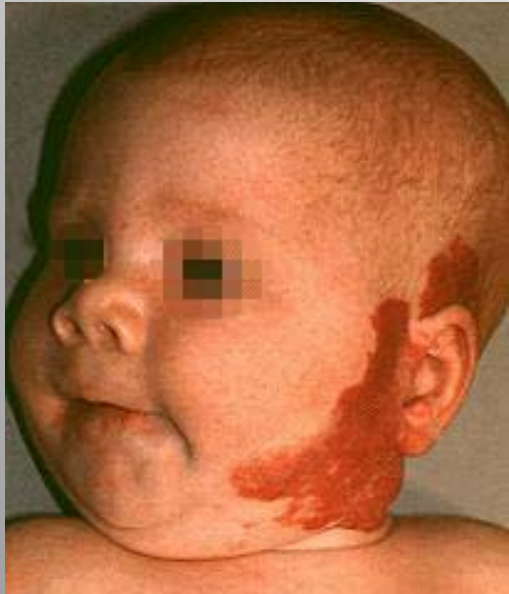Laryngeal webs



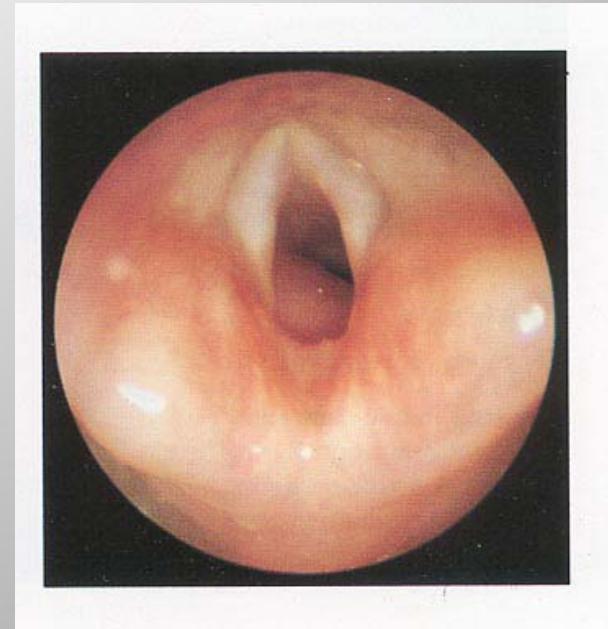
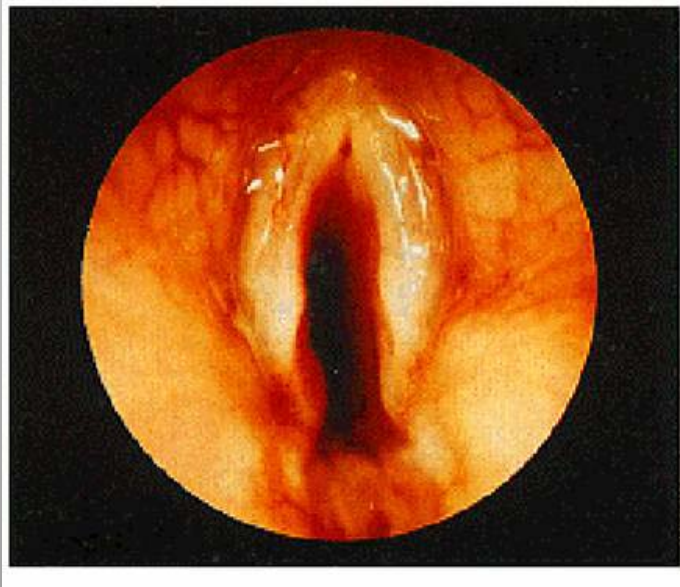Laryngeal webs



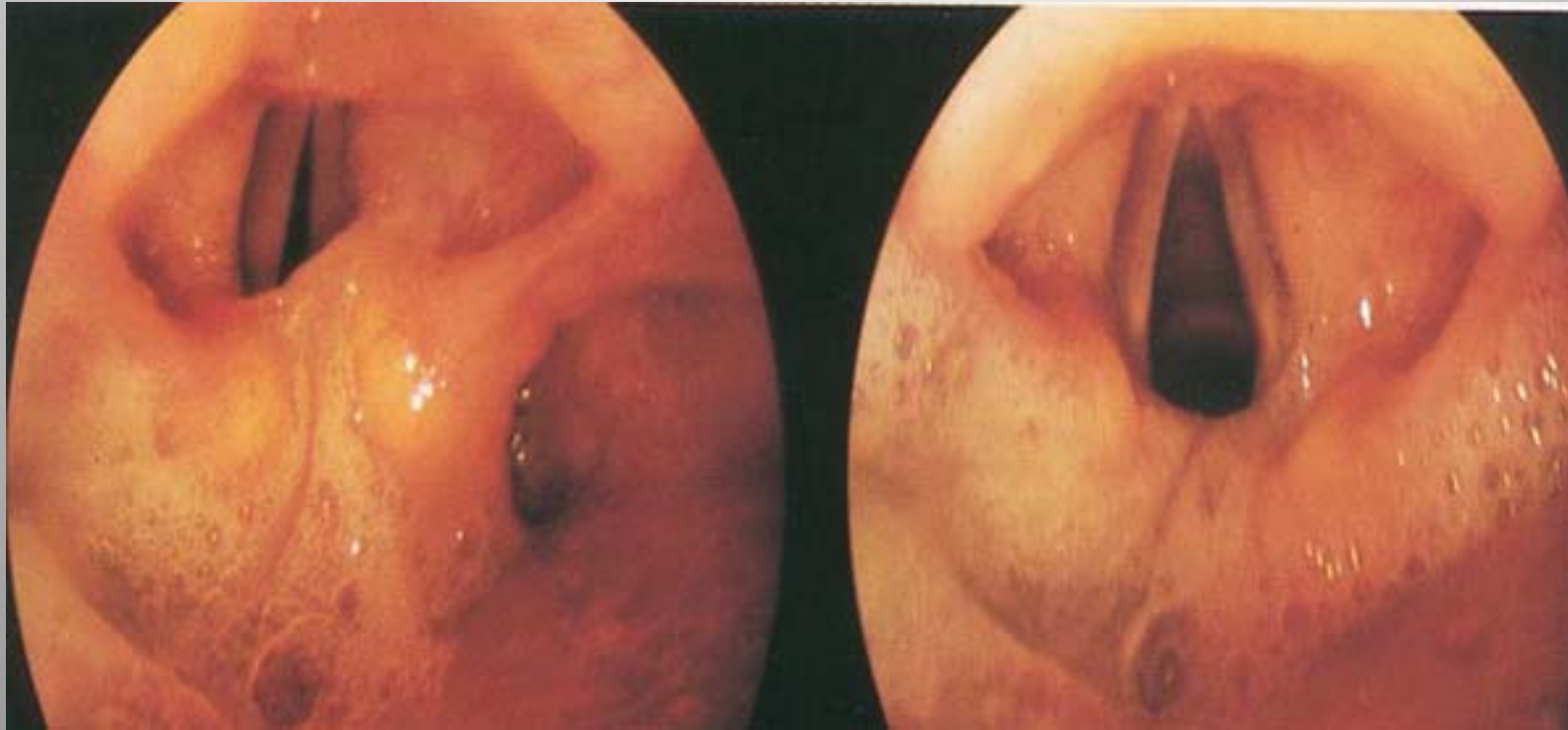Congenital subglottic Hemangioma



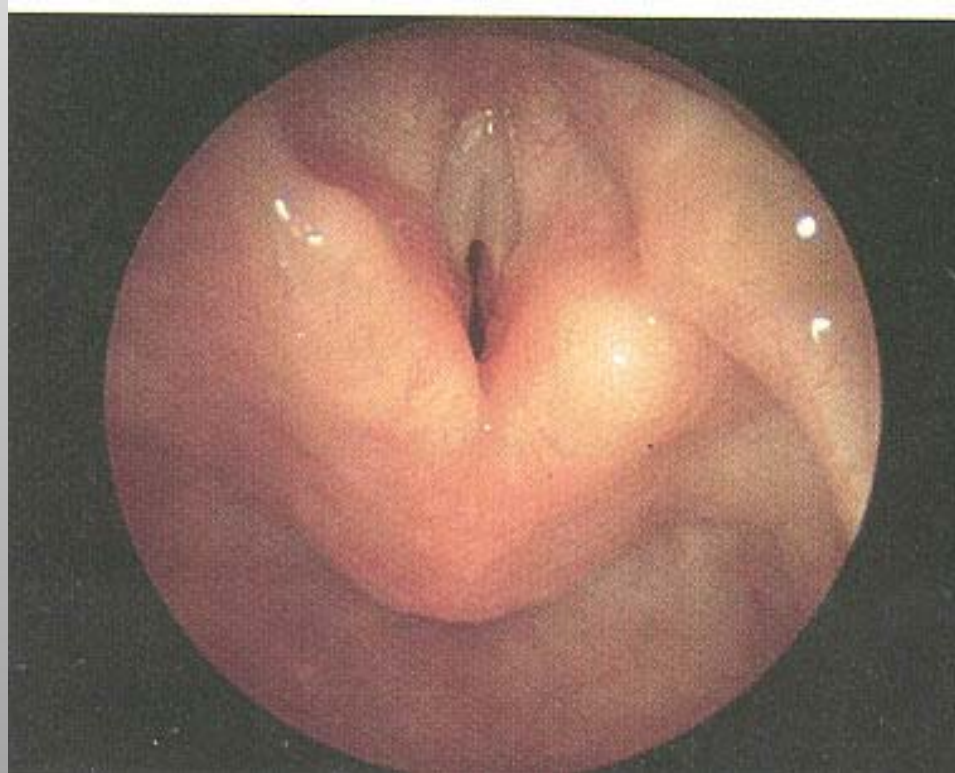
Congenital subglottic Hemangioma



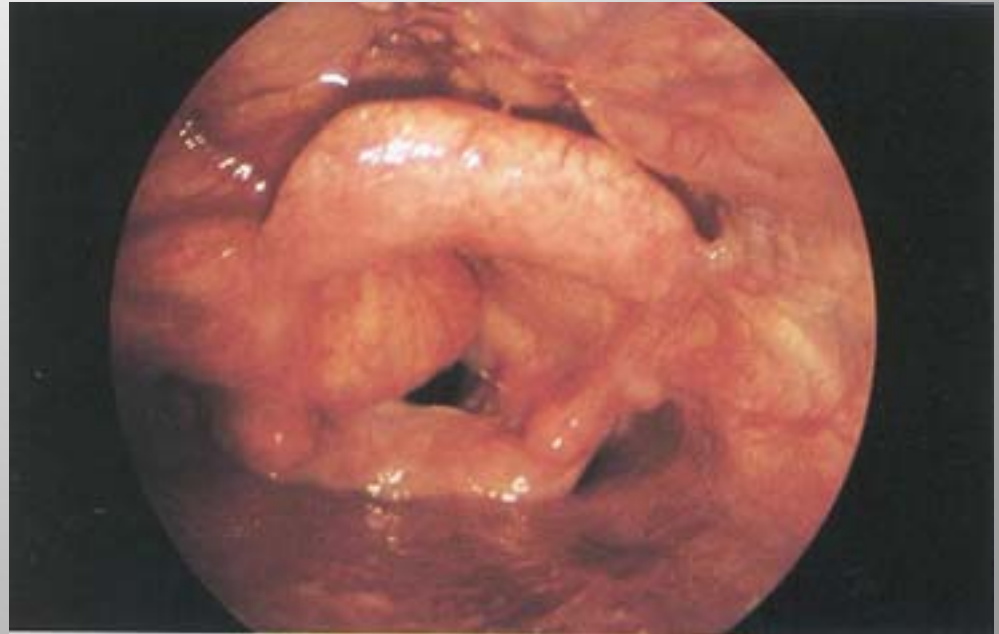
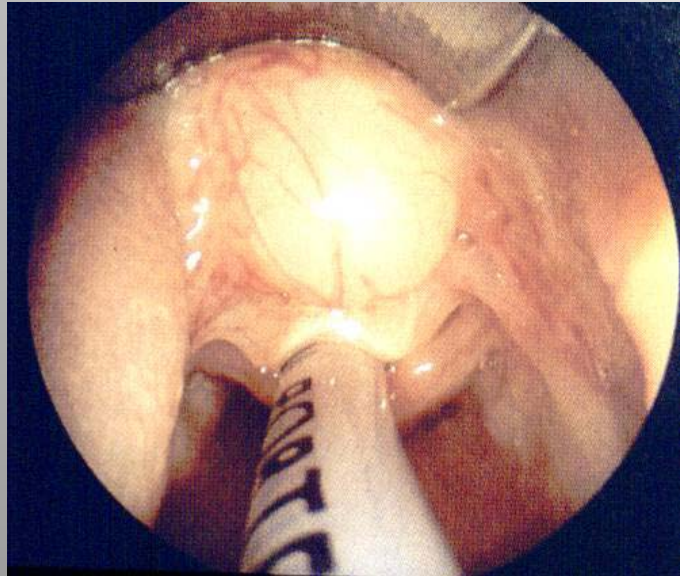
Unilateral vocal fold paralysis



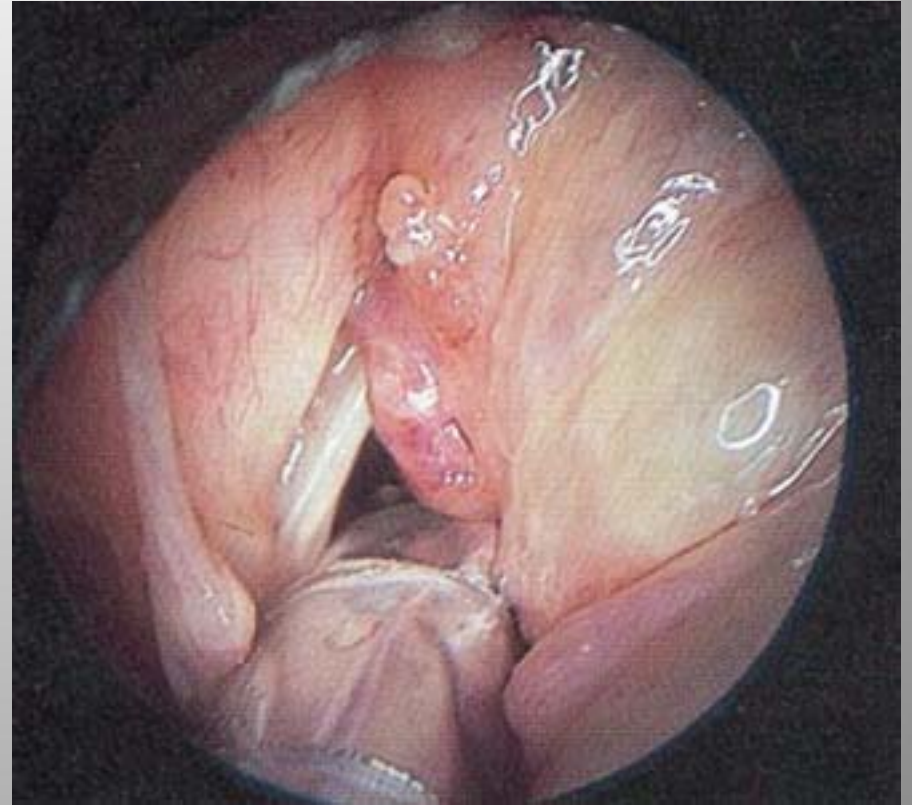
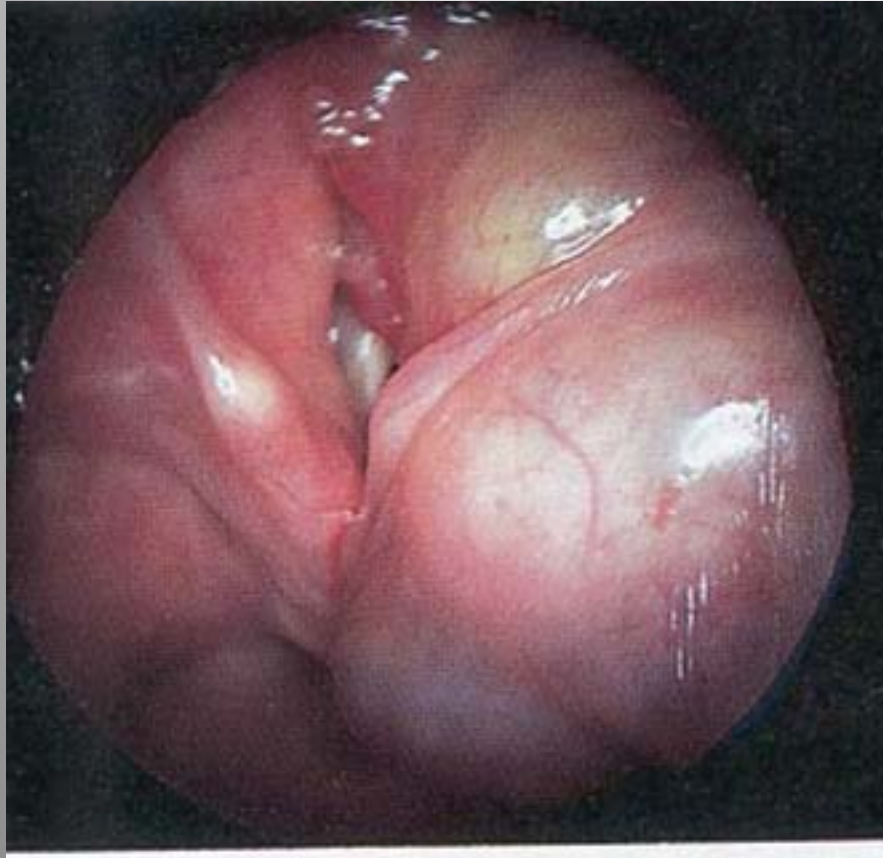
Bilateral vocal fold Paralysis



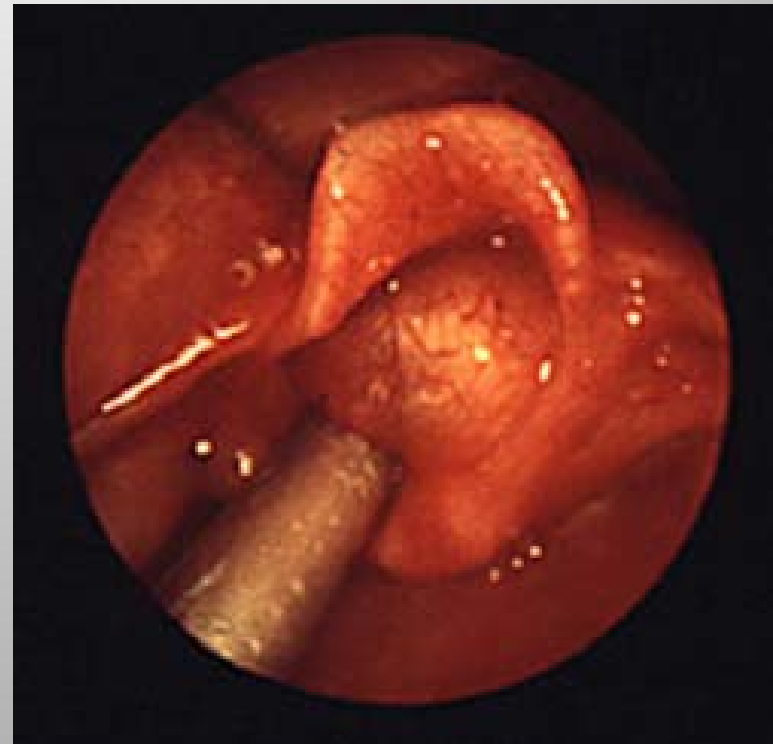
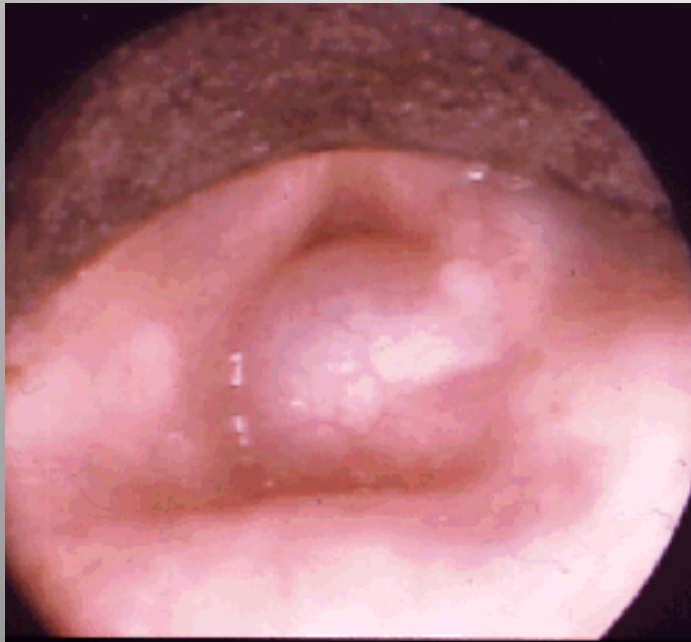
Laryngeal cysts



Laryngeal cysts



Laryngeal cysts



Laryngeal cleft

