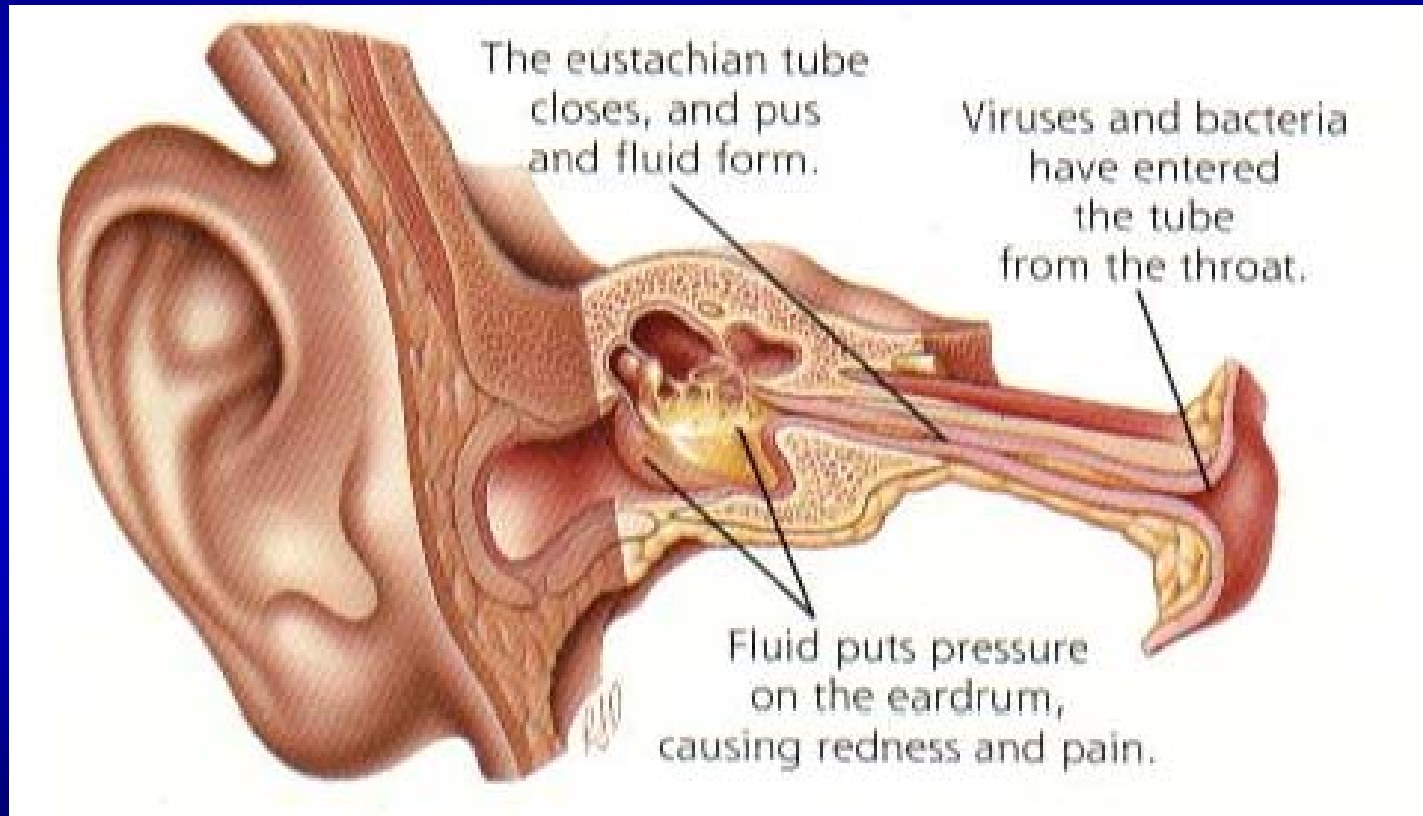
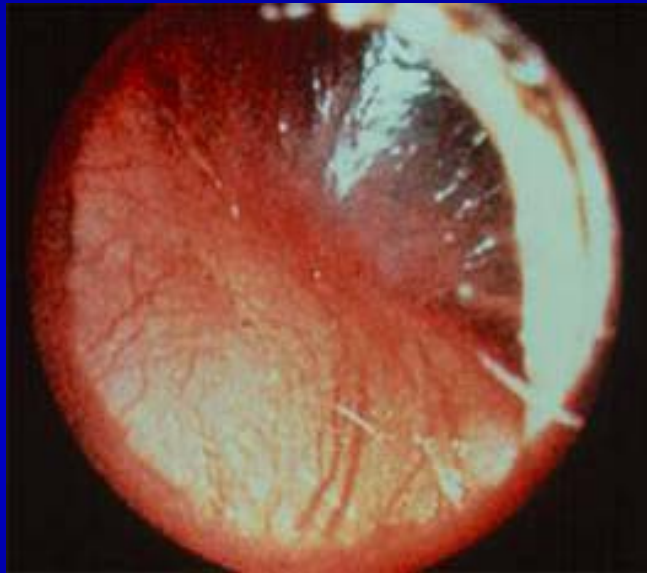


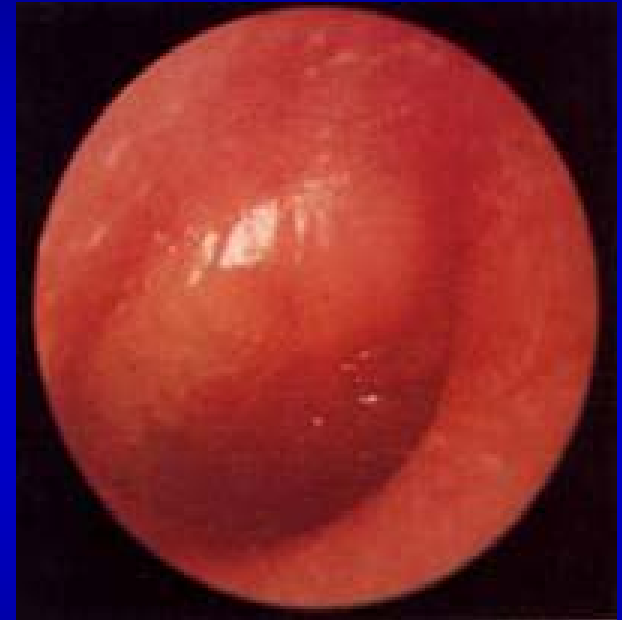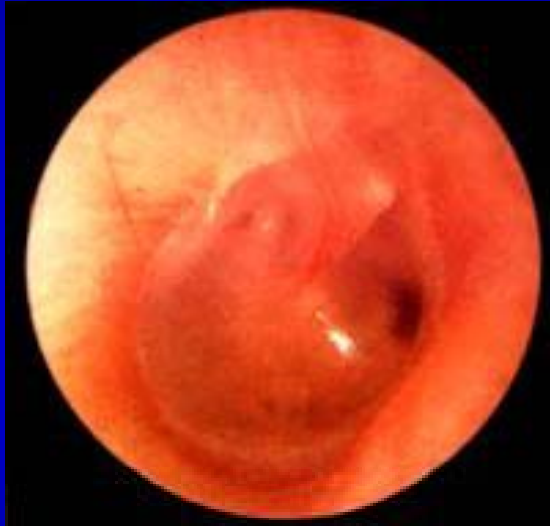PATHOLOGY



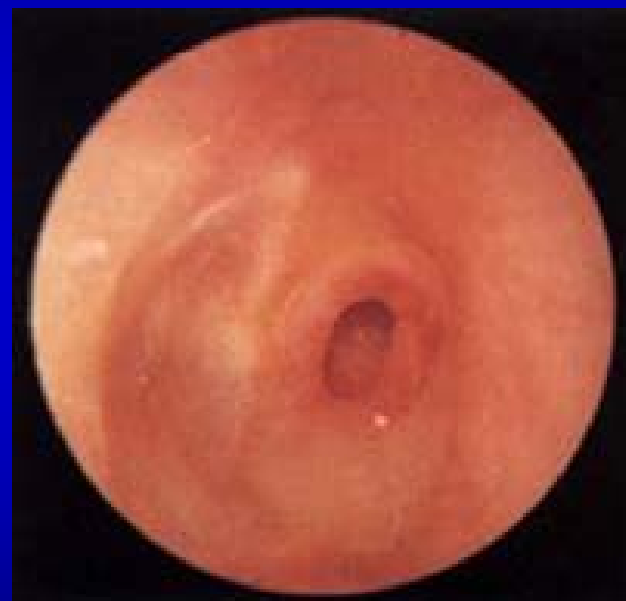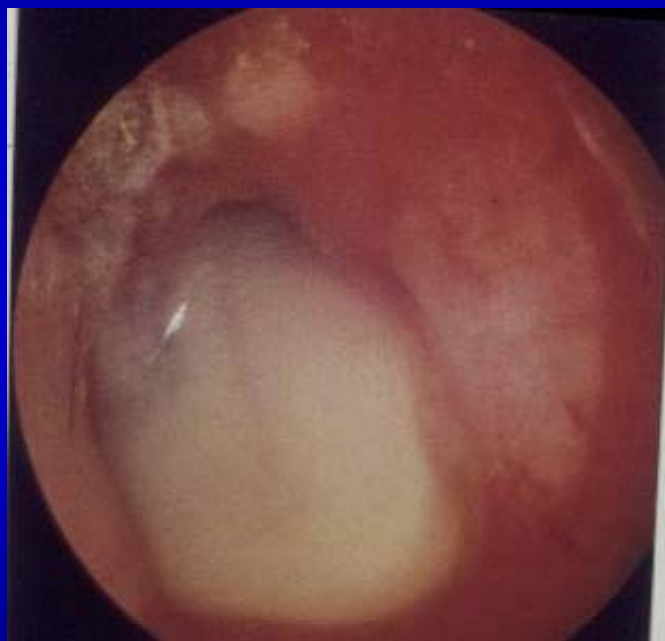AOM (early)

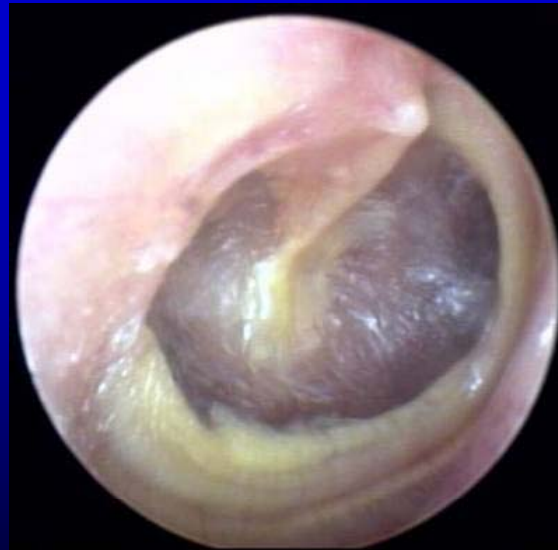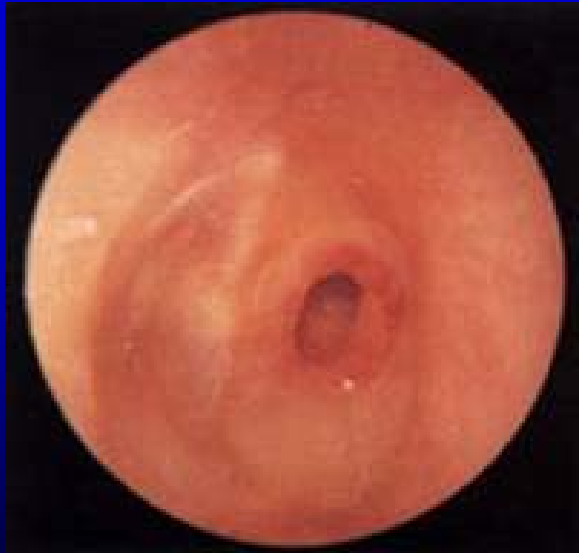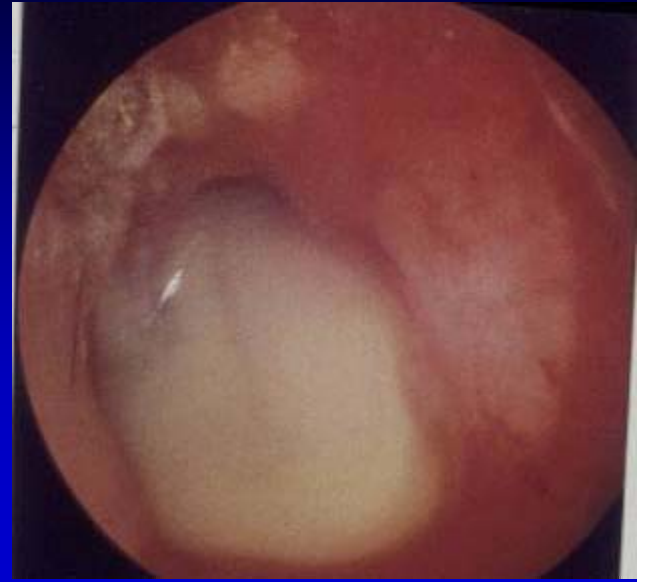
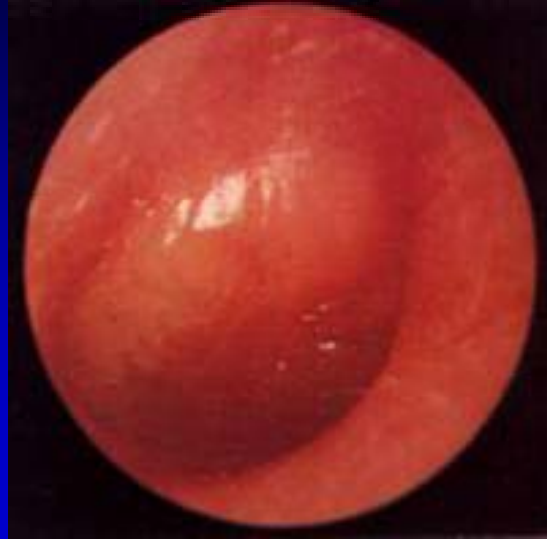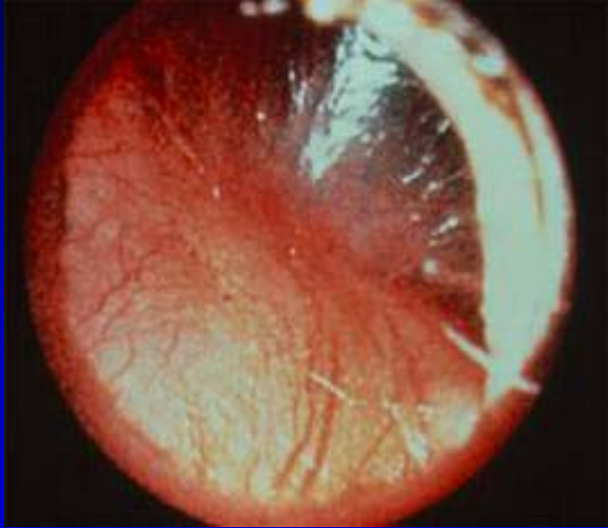


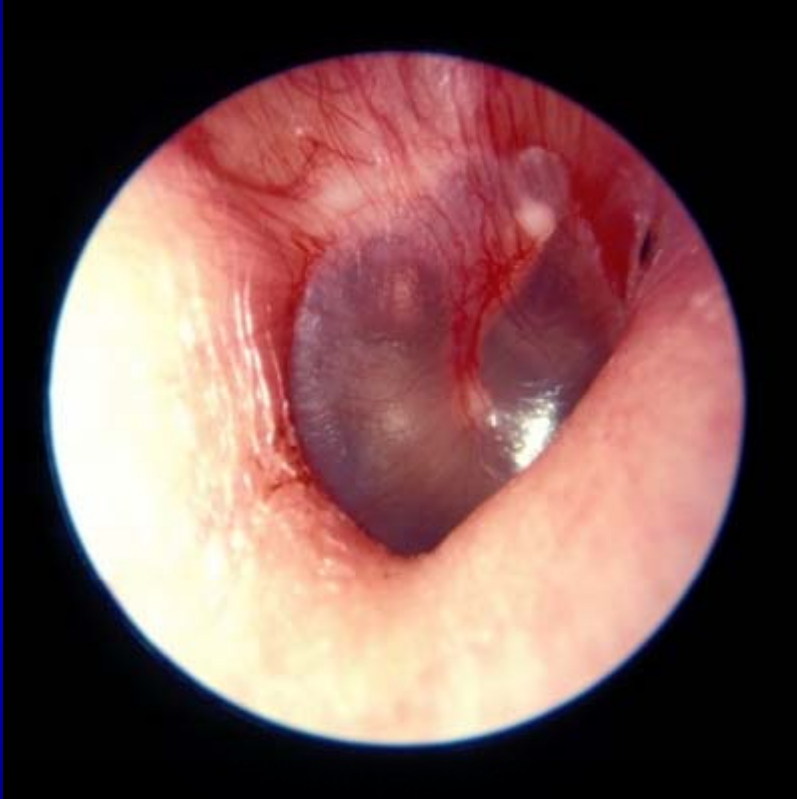AOM

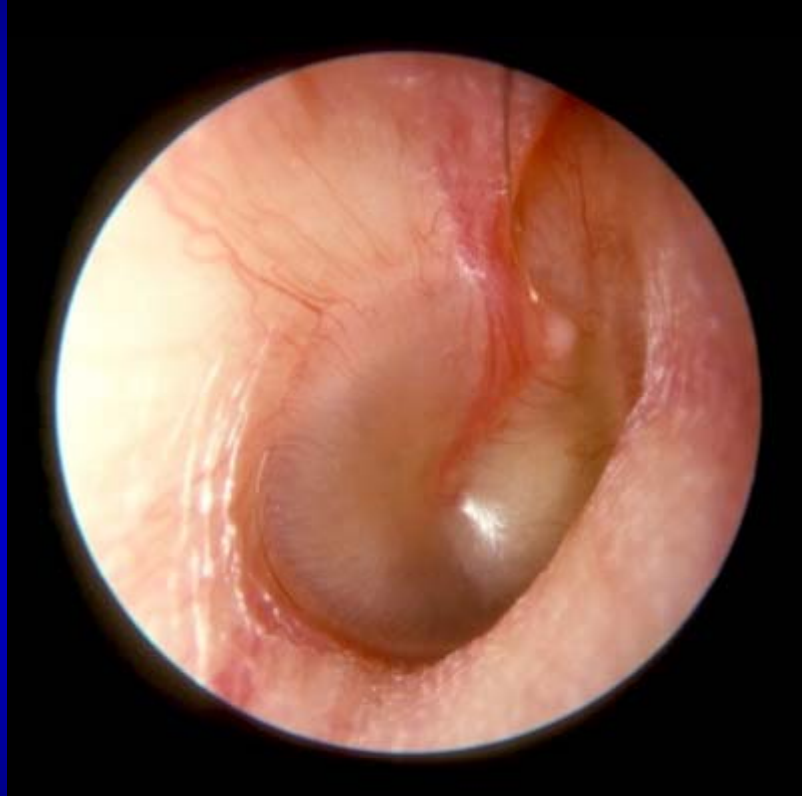

AOM

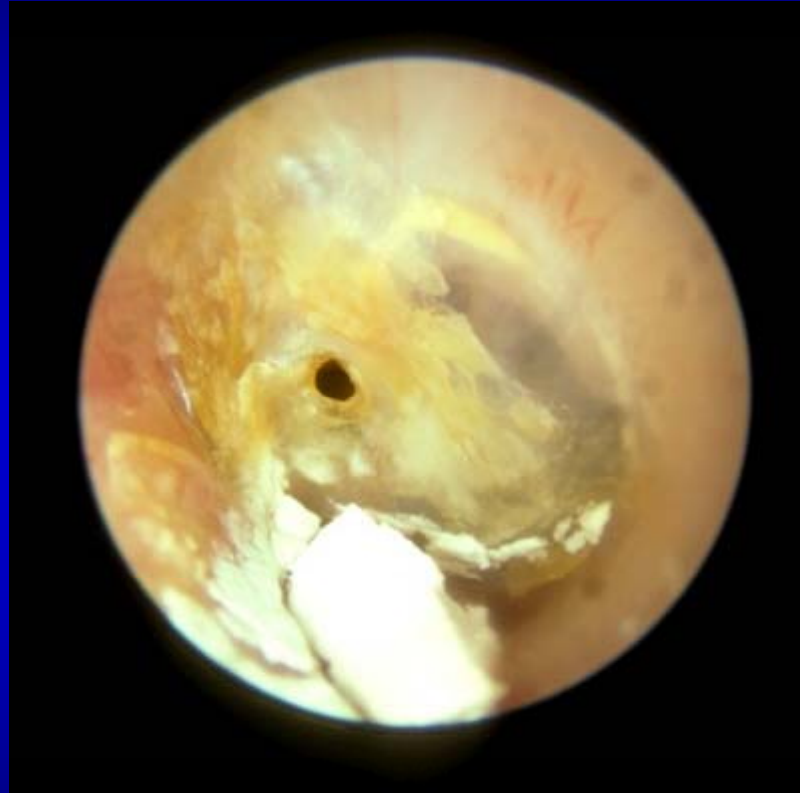


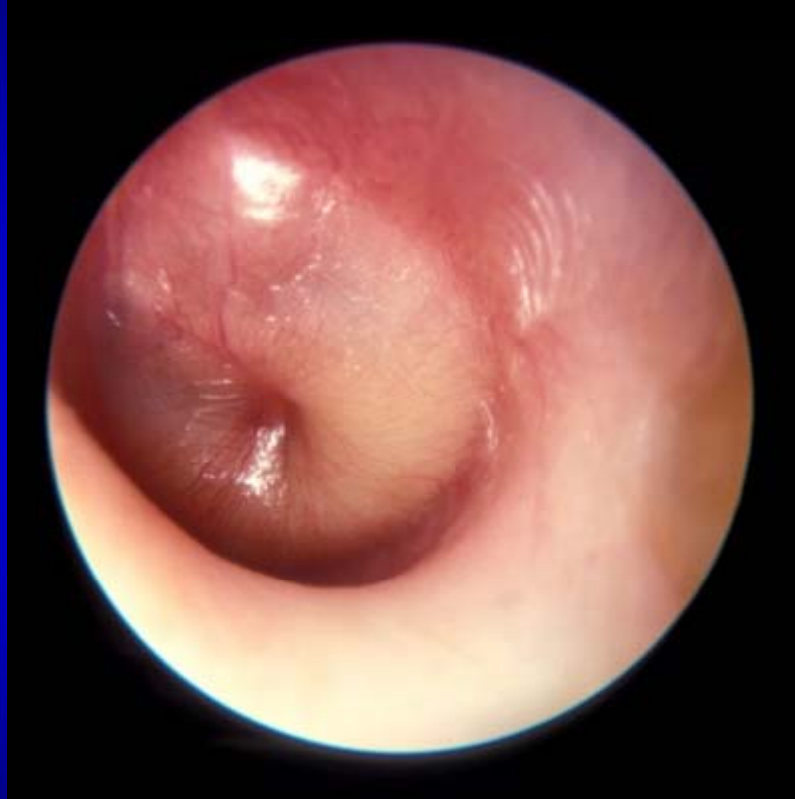


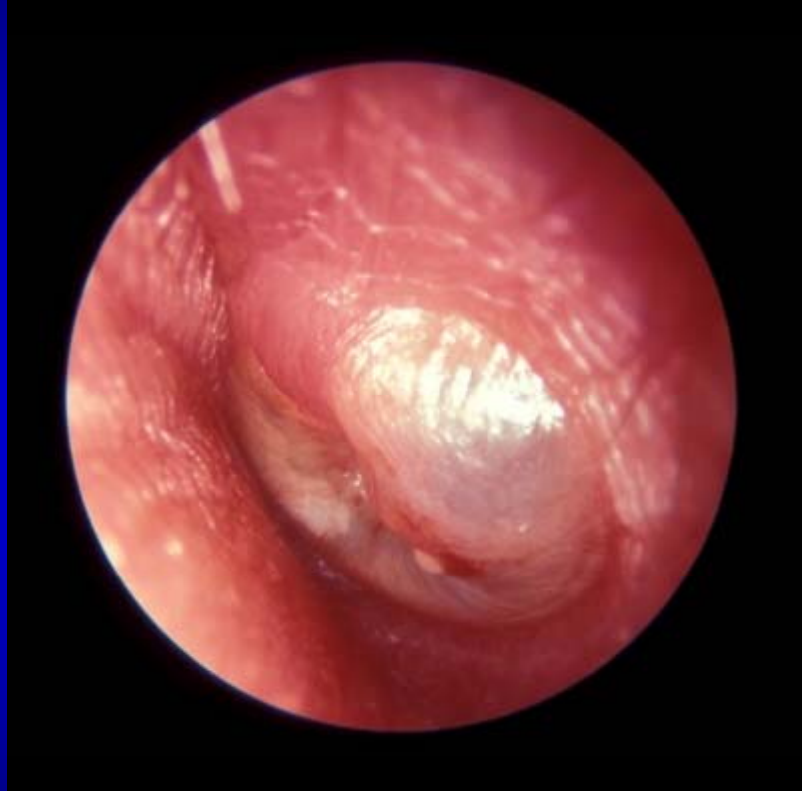


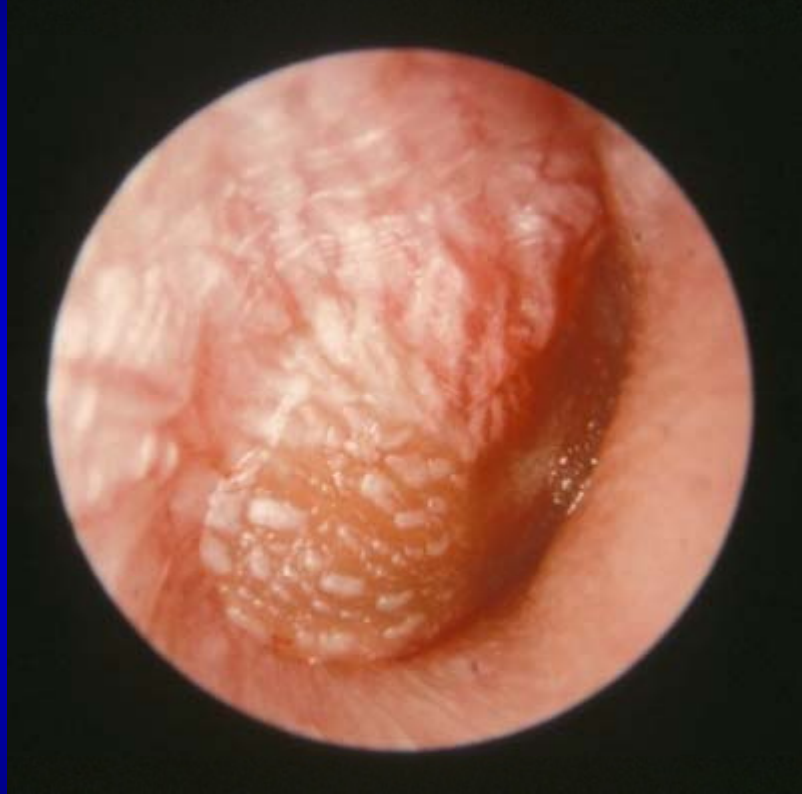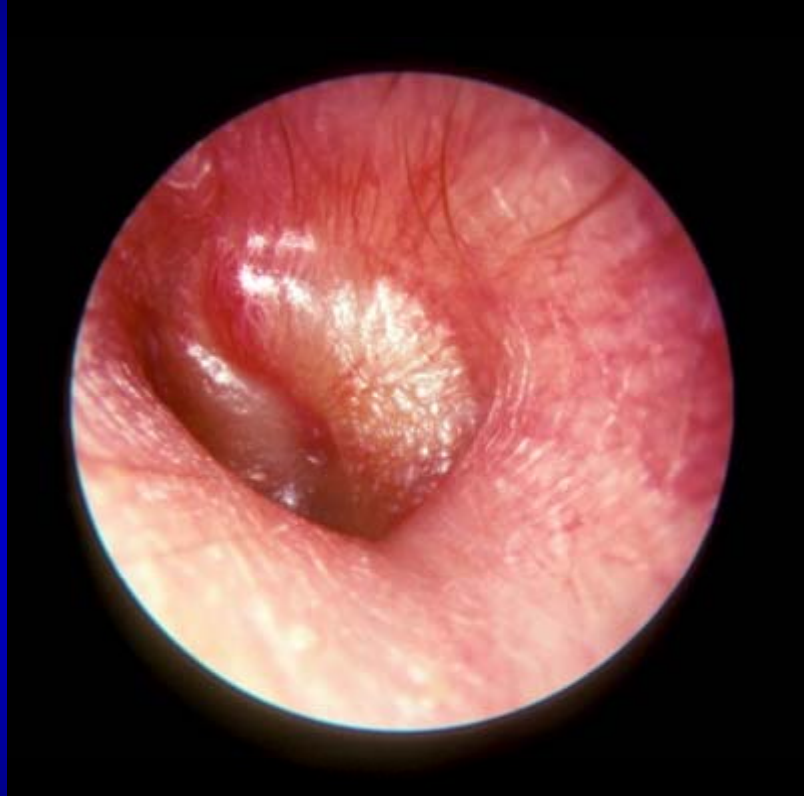TM 4 weeks post perforation

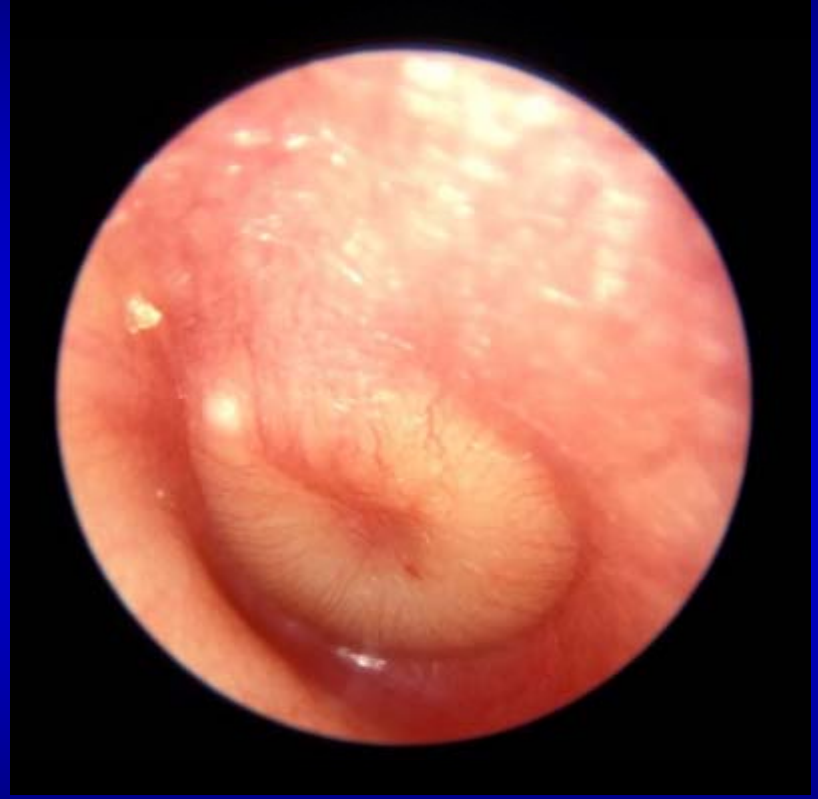
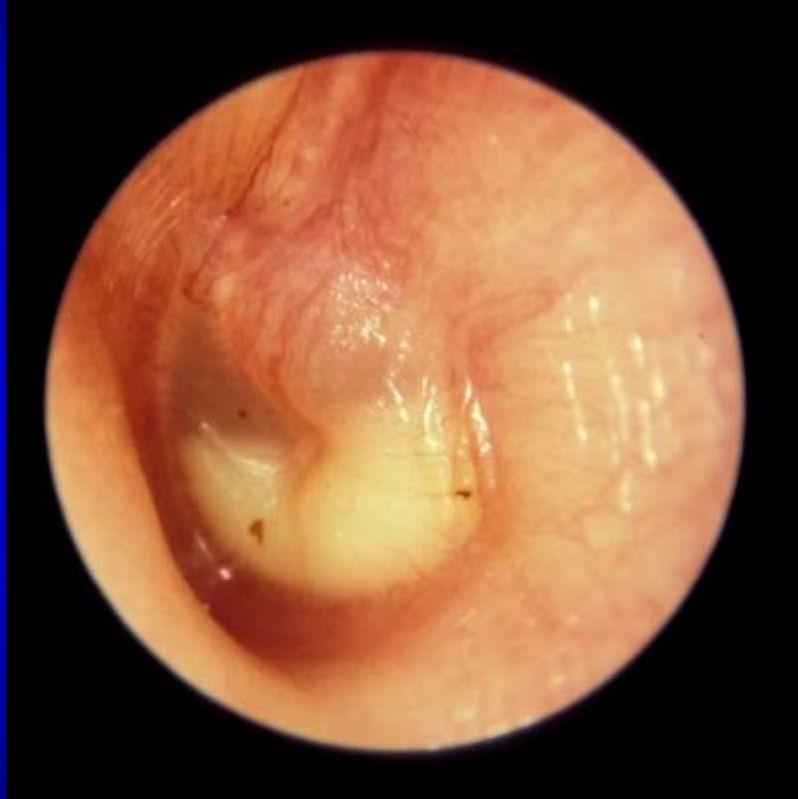


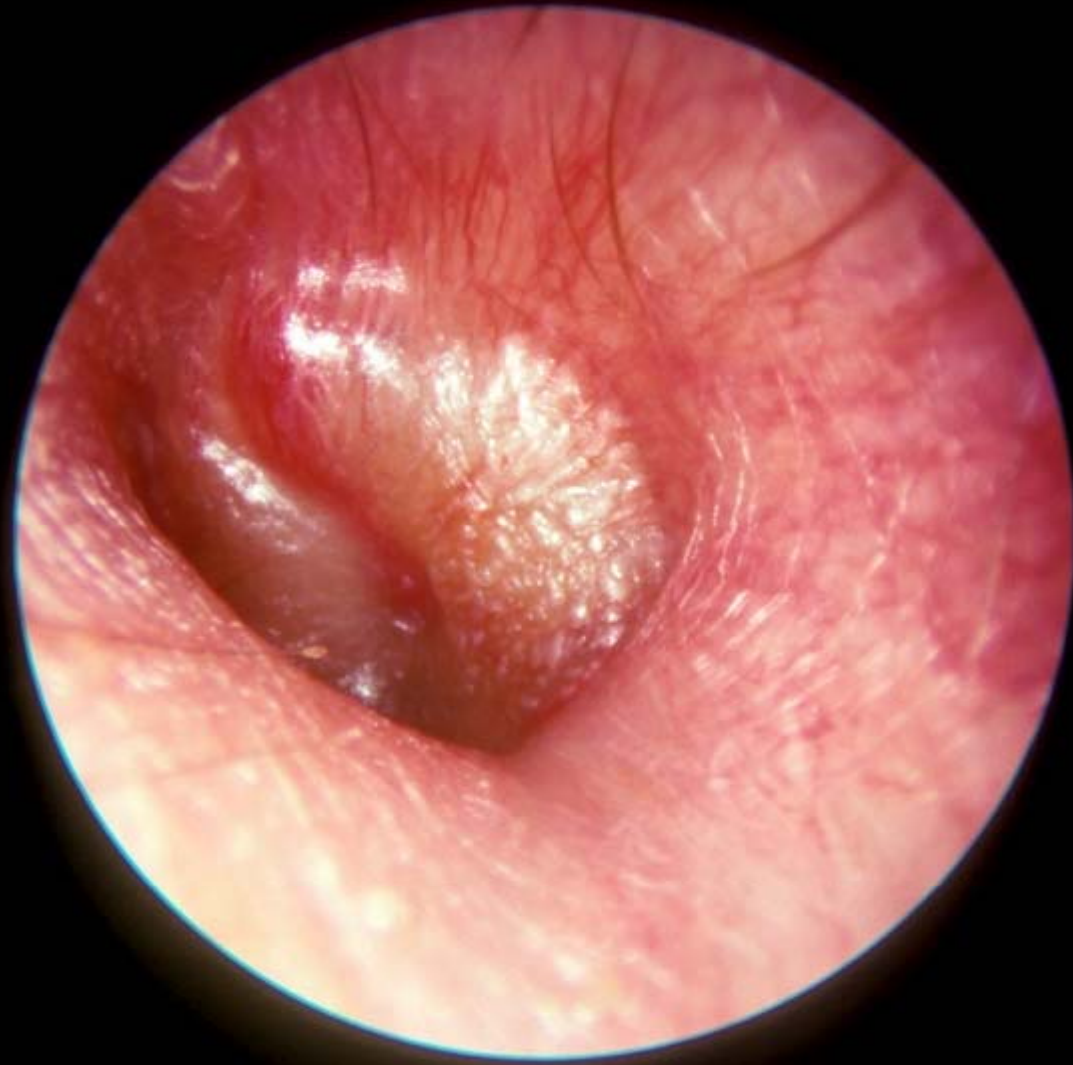











Michael Saunders FRCS

