

Spinal Injuries

Khalid A. AlSaleh, FRCSC

Associate Professor

Dept. Of Orthopedics

Objectives

- The ability to demonstrate knowledge of the following:
 - Basic anatomy of the spine
 - Initial assessment and treatment of spinal injuries at the field
 - Management of Cauda equina syndrome
 - Principle of spinal stability
 - Basic understanding of neurologic syndromes caused by spinal trauma

Spine Pathology Red Flag Conditions

- Cauda Equina/severe neurologic injury
 - perianal numbness, decreased rectal tone, loss of movement in the extremities
- Tumor weakening the vertebrae
 - causing cord compression or vertebral fracture
- Infection weakening bone
 - causing disc/vertebral destruction or cord compression.
- Traumatic Spine Fracture
 - causing vertebral angulation, pain, or neuro compromise.



Incidence and Significance

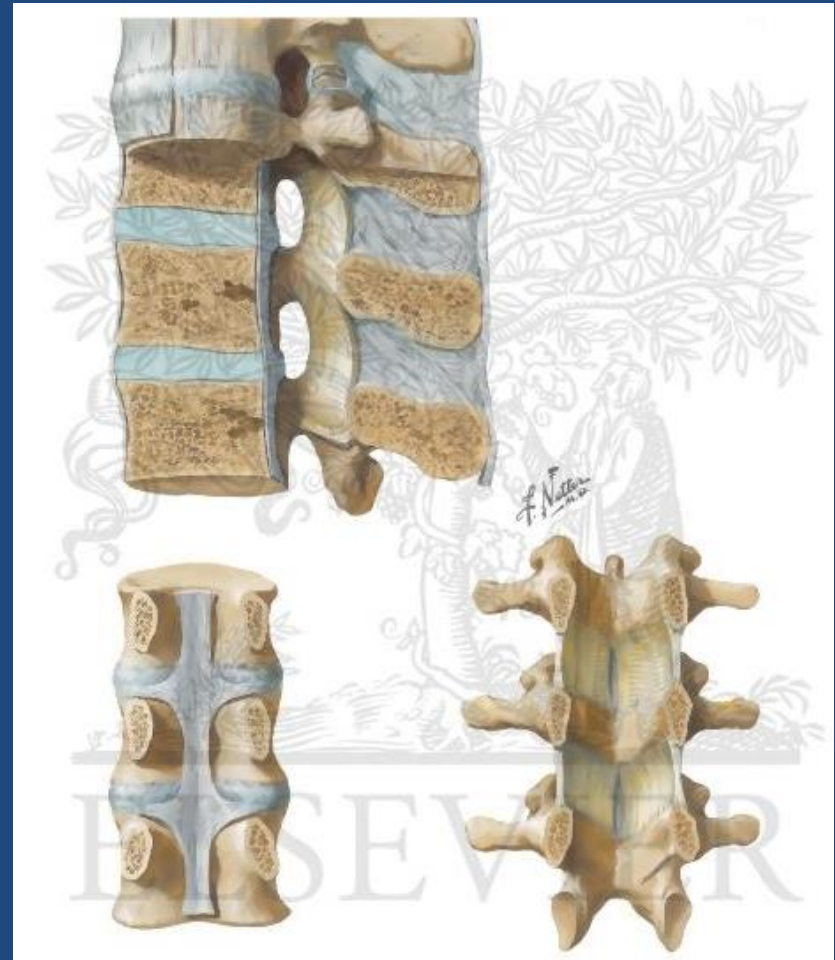- 50000 cases per year
- 40-50% involving the cervical spine
- 25% have neurologic deficit
- Age: mostly between 15-24 years
- Gender: mostly males (3:1)

Mechanism of Injury

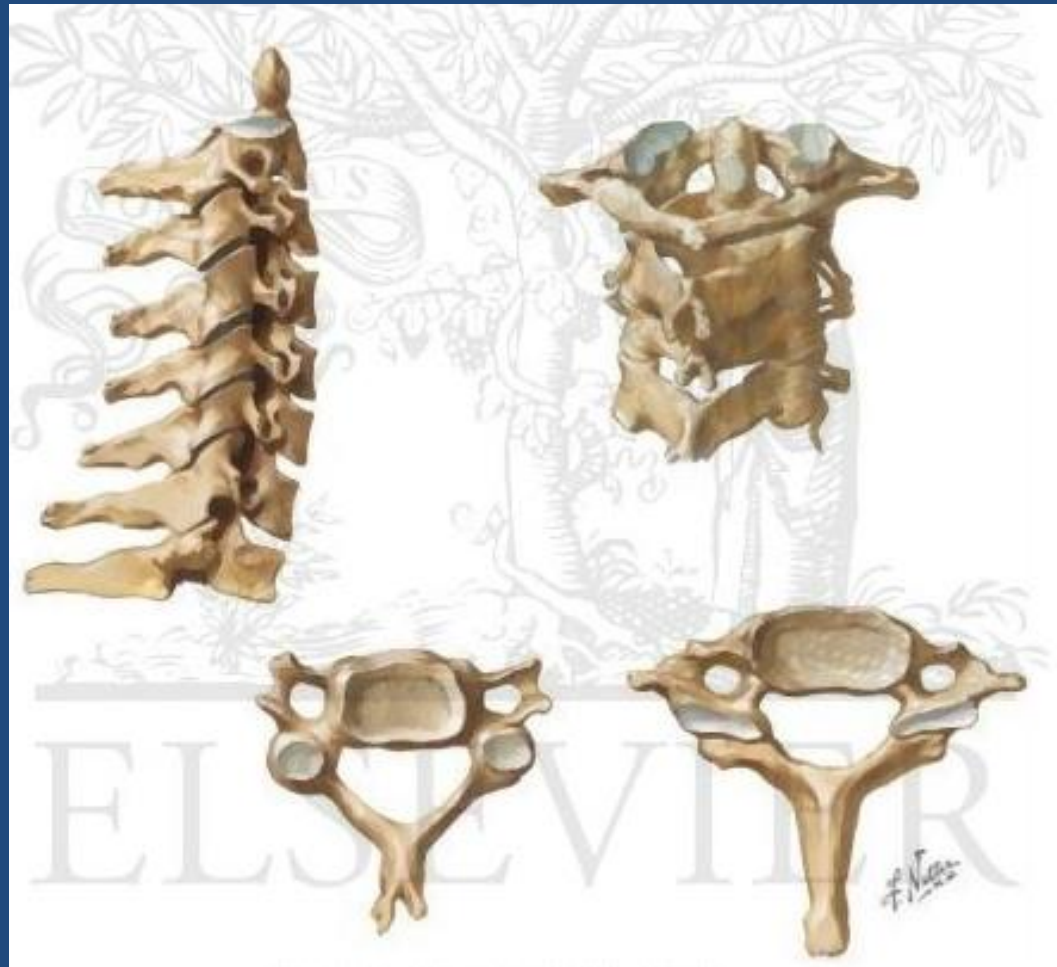- MVA: 40-55%
- Falls: 20-30%
- Sports: 6-12%
- Others: 12-21%

Anatomy of the Spine

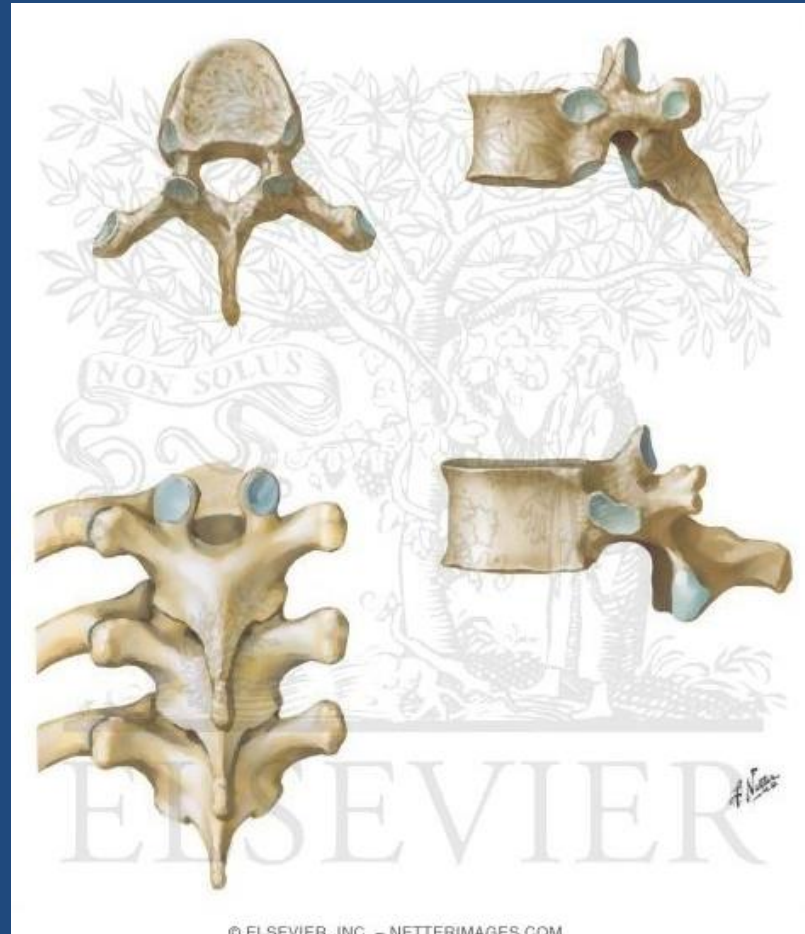
- Bones
- Joints
- Ligaments
- muscles



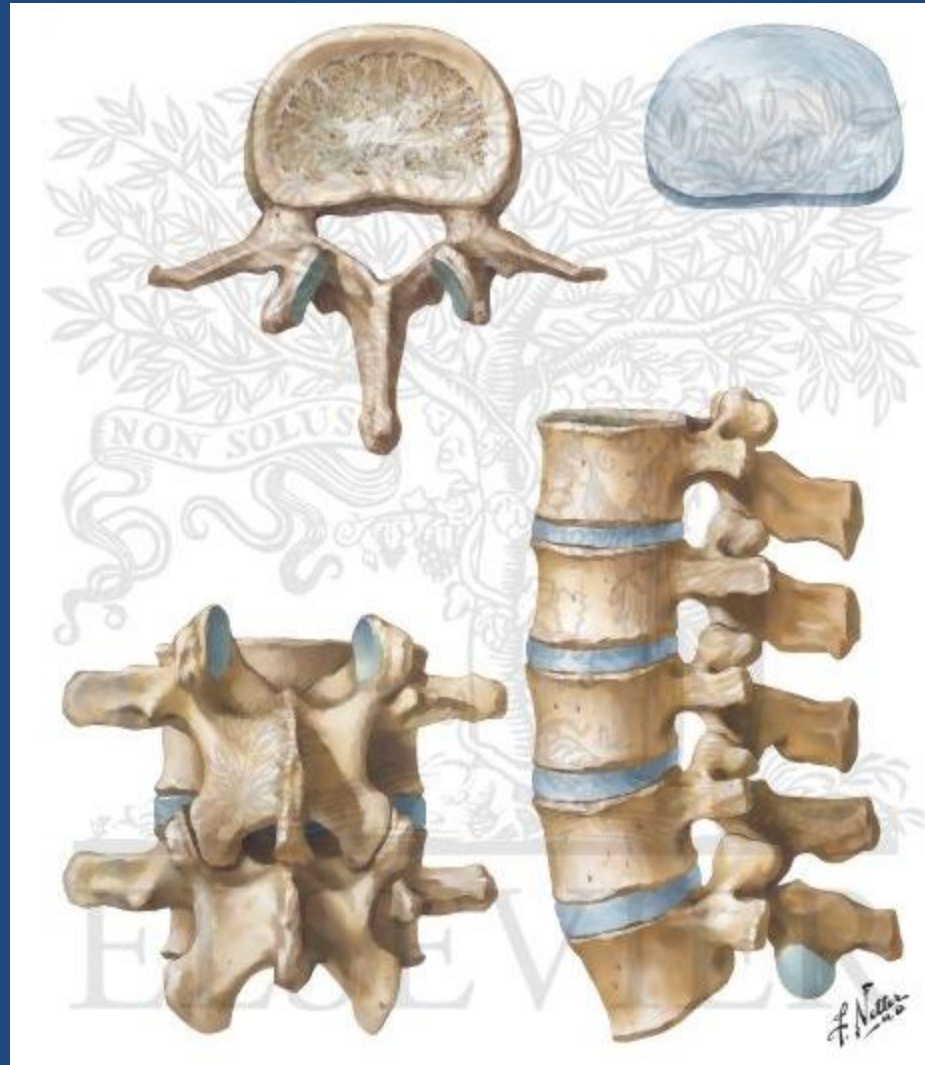
Cervical anatomy: C3-C7



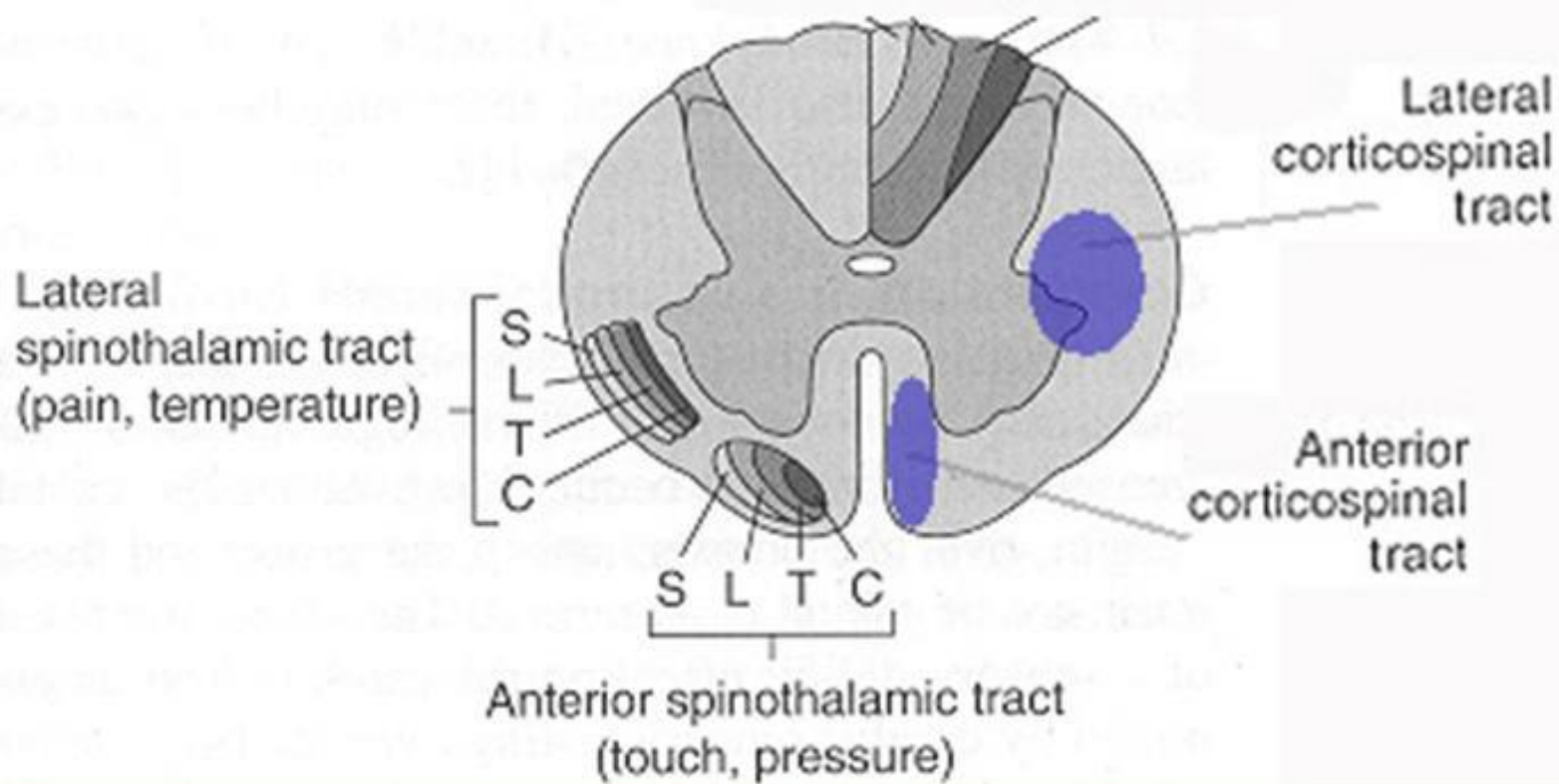
Thoracic Spine



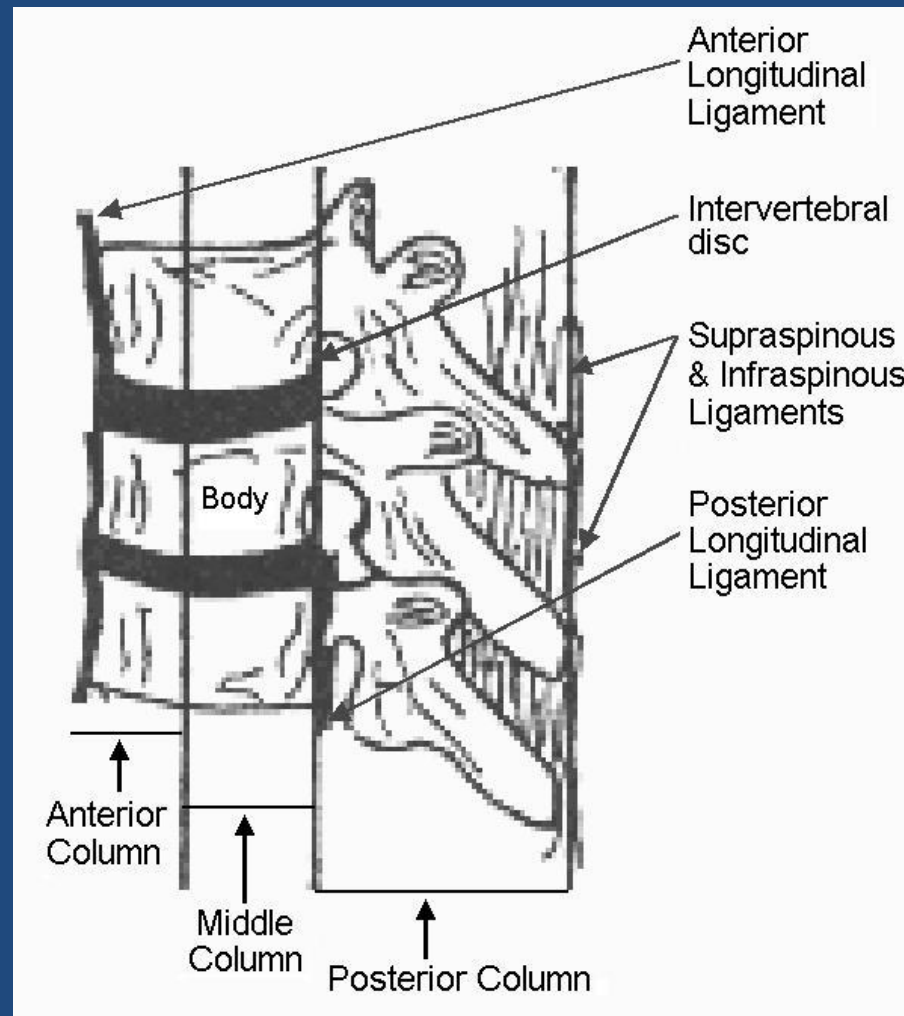
Lumbar Spine



Posterior column
(touch, pressure,
vibration, joint position)



The Three columns

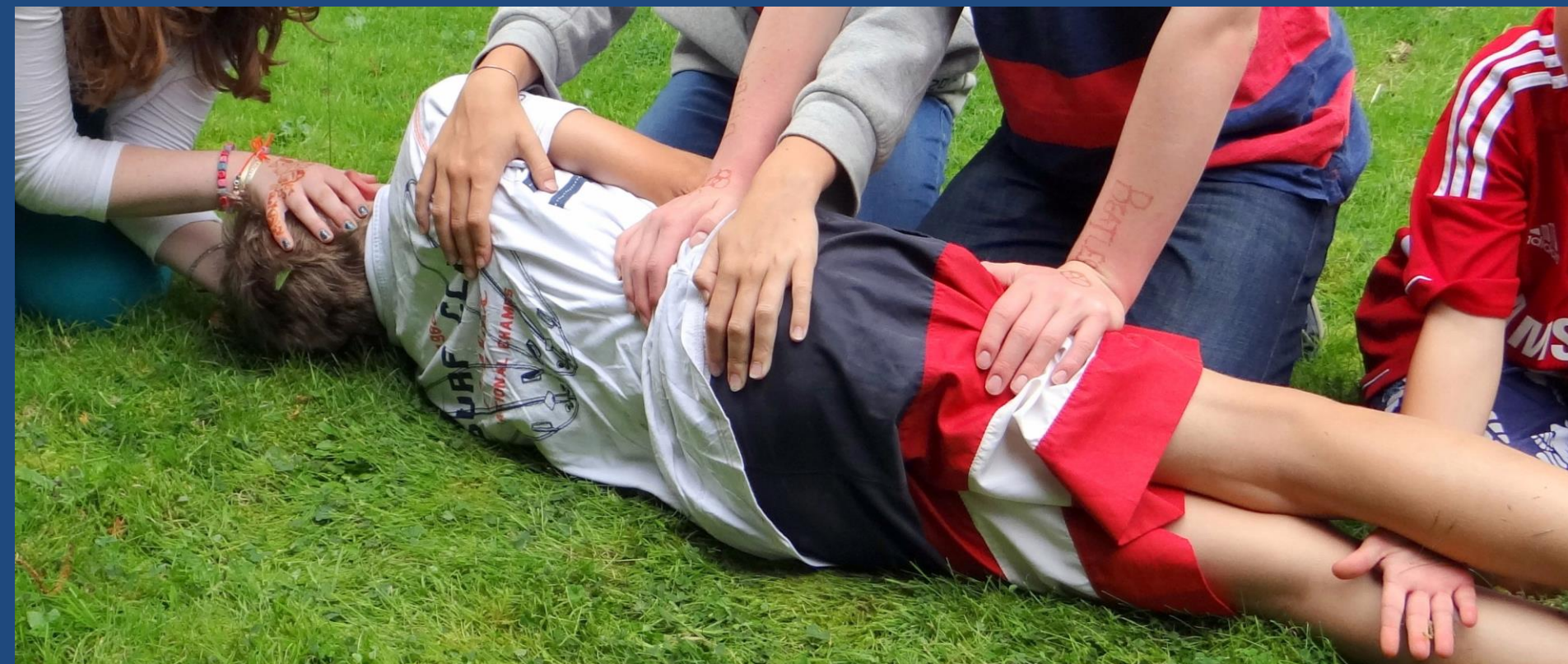

Assessment of the spine injured pt.

- Immobilization
- History:
 - Mechanism of injury:
 - compression, flexion, extension, distraction
 - Head injuries
 - Seat belt injury
- Physical examination
 - Inspection, palpation
 - Neurologic examination

Assessment

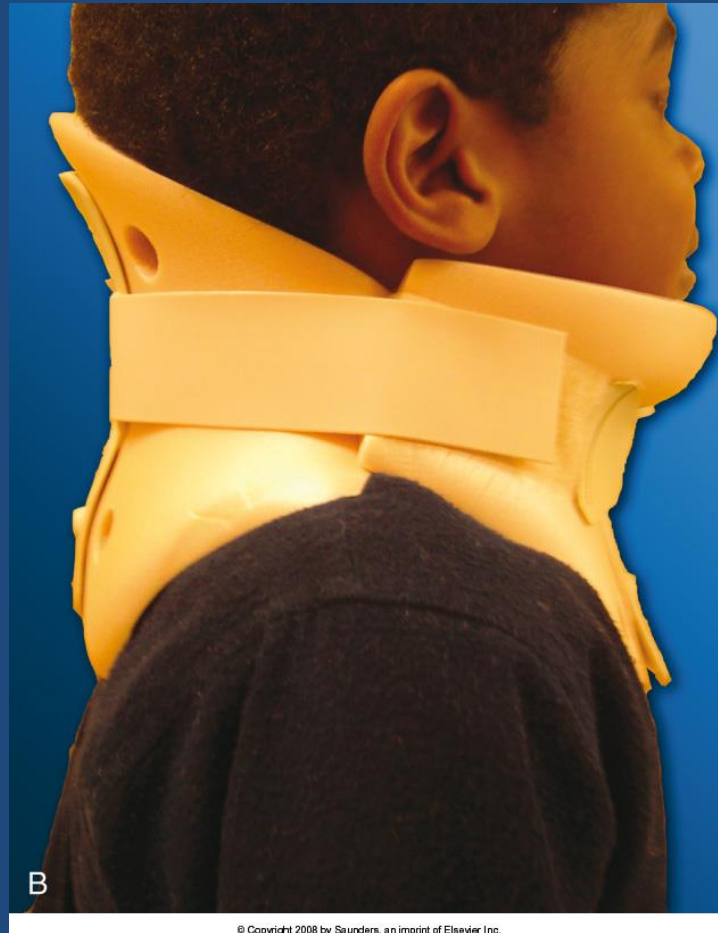- Immobilization.



inspection, palpation.

Neck injury assessment.

Cervical collar



B

Spine board



Cervical traction

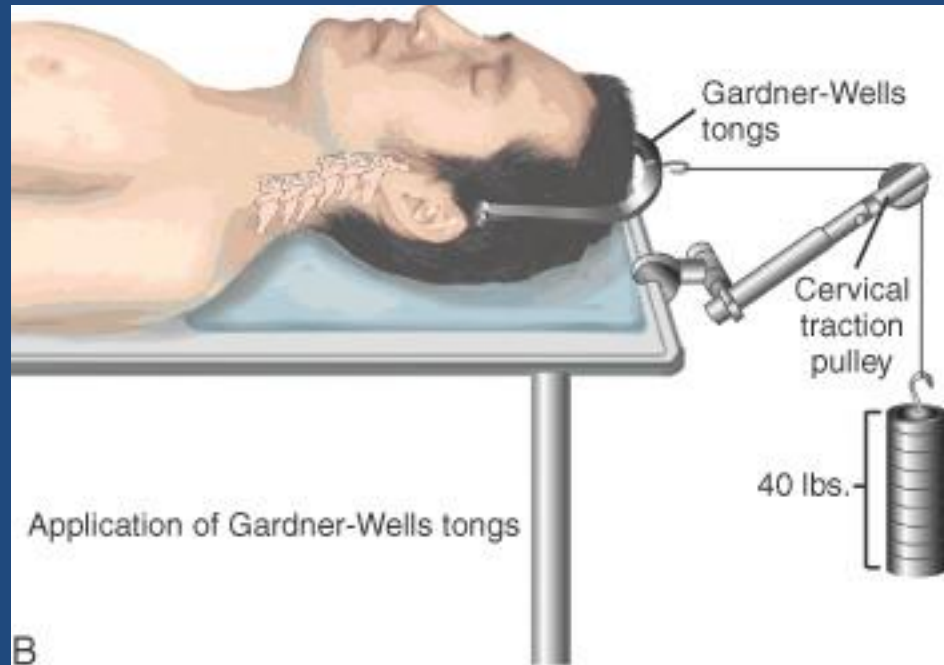
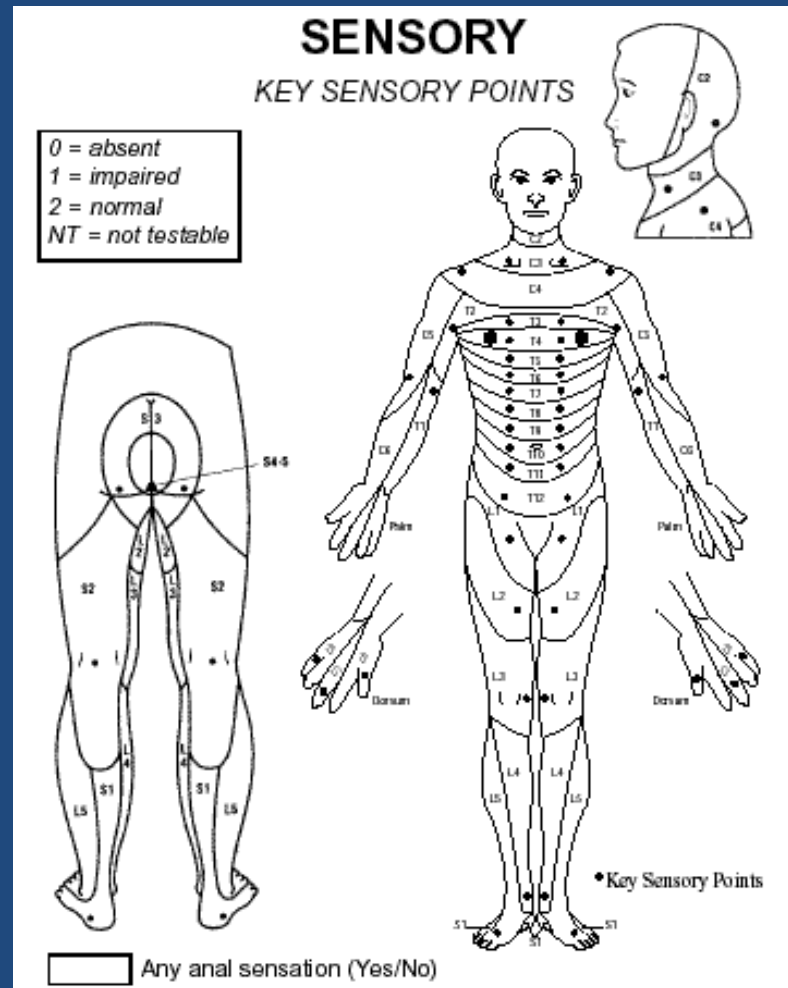


Fig. 10-15B A, Gardner-Wells tongs, a C-shaped ring with spring loaded pins that are placed approximately 1 cm above the pinna of the ear. B, Gardner-Wells tongs in place with weighted traction in an awake and alert patient.

© Copyright 2008 by Saunders, an imprint of Elsevier Inc.

Dermatomes



ASIA classification

ASIA IMPAIRMENT SCALE

- A = Complete:** No motor or sensory function is preserved in the sacral segments S4-S5.
- B = Incomplete:** Sensory but not motor function is preserved below the neurological level and includes the sacral segments S4-S5.
- C = Incomplete:** Motor function is preserved below the neurological level, and more than half of key muscles below the neurological level have a muscle grade less than 3.
- D = Incomplete:** Motor function is preserved below the neurological level, and at least half of key muscles below the neurological level have a muscle grade of 3 or more.
- E = Normal:** motor and sensory function is normal

CLINICAL SYNDROMES

- Central Cord
- Brown-Sequard
- Anterior Cord
- Conus Medullaris
- Cauda Equina

Neurologic examination

- Spinal cord syndromes:
 - Complete SCI
 - Flaccid paralysis below level of injury
 - May involve diaphragm if injury above C5
 - Sympathetic tone lost if fracture above T6
 - Incomplete SCI: Good prognosis for recovery
 - Central cord syndrome
 - Upper limb > lower limb deficit.
 - Brown-Sequard syndrome
 - Also called: cord hemi-section

Other neurologic syndrome

- Conus medullaris syndrome
 - Mixture of UMN and LMN deficits
- Cauda-Equina syndrome
 - Urinary retention, bowel incontinence and saddle anesthesia
 - Usually due to large central disc herniation rather than fracture
- Nerve root deficit: LMN

- Spinal Shock
 - Transient loss of spinal reflexes
 - Lasts 24-72 hours
- Neurogenic shock
 - Reduced tissue perfusion due to loss of sympathetic outflow and un-opposed vagal tone
 - Peripheral vasodilatation
 - Rx.: fluid resuscitation

Imaging

- X-rays:
 - Cervical: 3 views
 - AP, lateral and open mouth
 - Thoraco-lumbar: 2 views
 - AP & lateral
 - Flexion-Extension views
- CT: best for bony anatomy
- MRI: best to evaluate soft tissue

Management of Spinal Injuries

- Depends on:
 - Level of injury
 - Degree and morphology of injury: **STABILITY**
 - Presence of neurologic deficit
 - Other factors

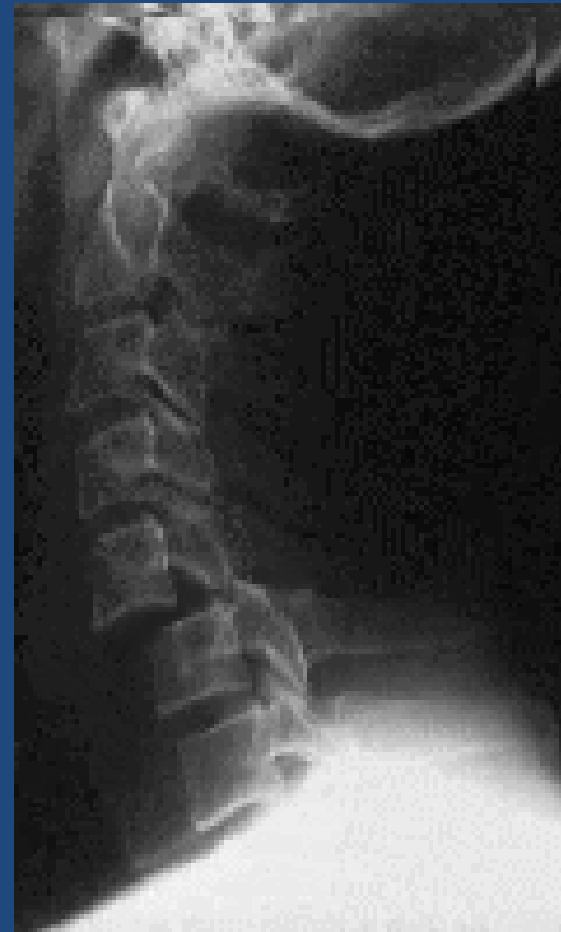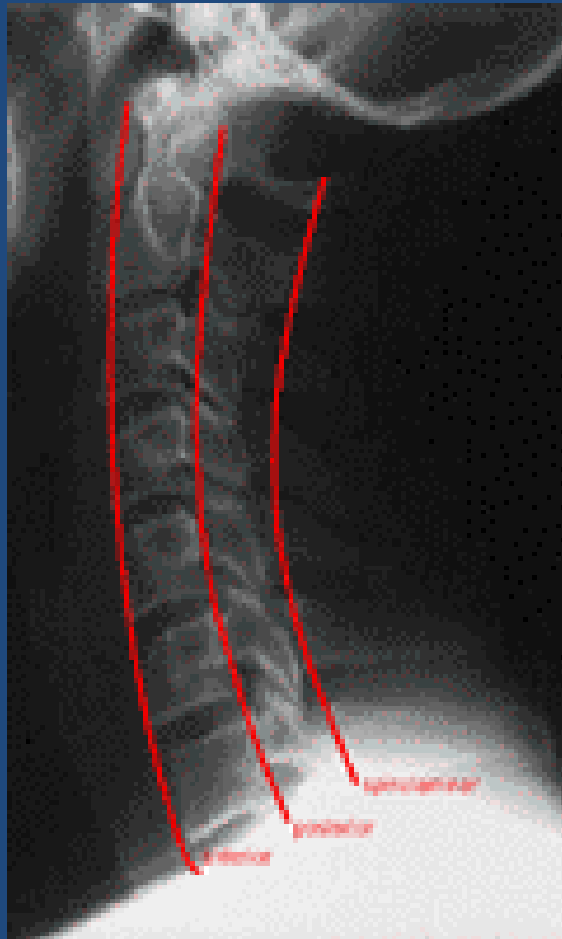
- Some general rules:
 - **Stable** injuries are usually treated conservatively
 - **Unstable** injuries usually require surgery
 - Neurologic compression requires decompression

Specific Injuries

Cervical spine fractures

- Descriptive: depends on mechanism of injury
 - Flexion/extension
 - Compression/distraction
 - Shear
- Presence of subluxation/dislocation
- SCI:
 - high fracture results in quadriplegia
 - Low fracture results in paraplegia

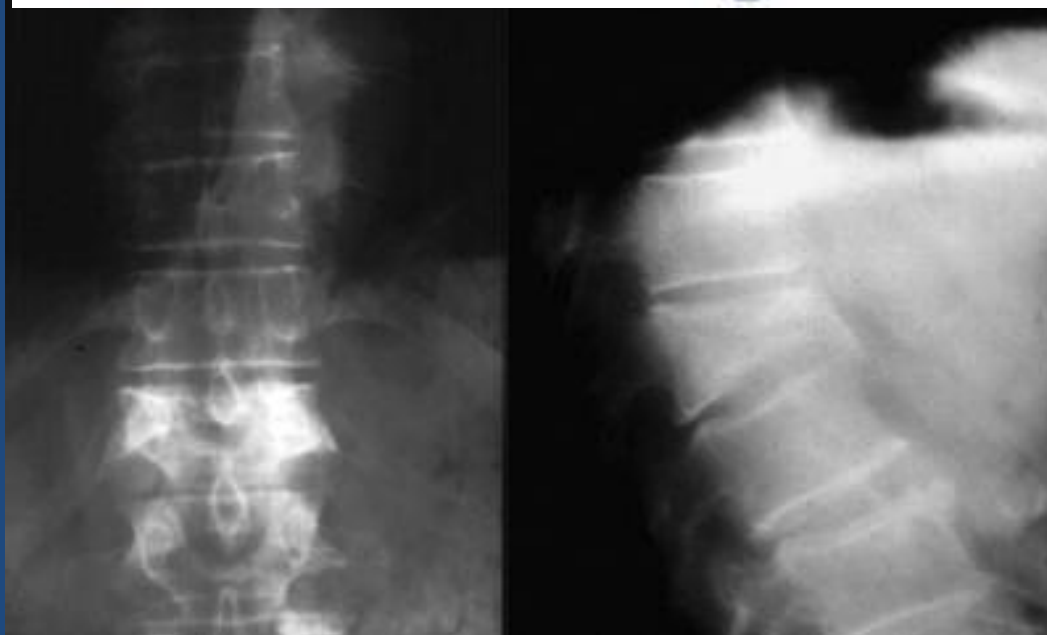
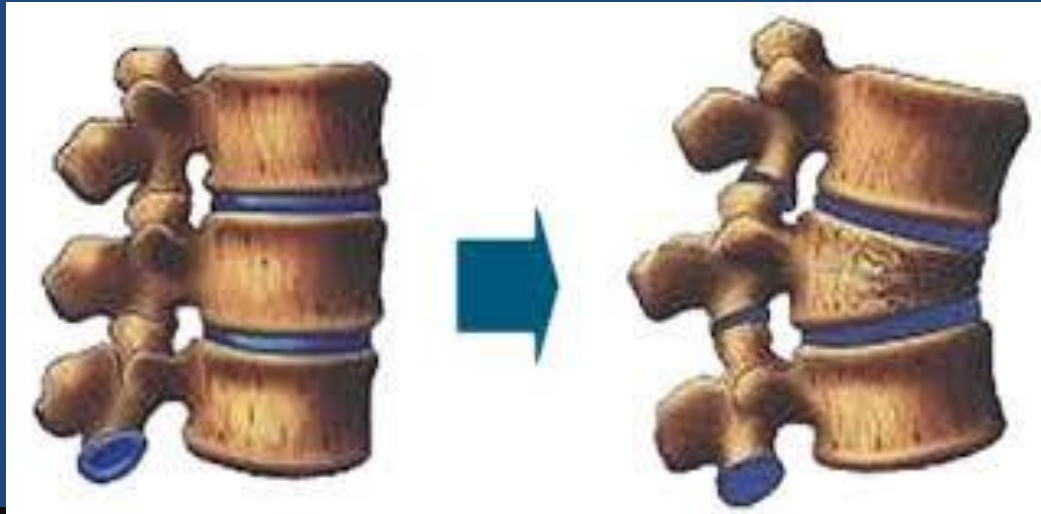
Cervical spine fractures



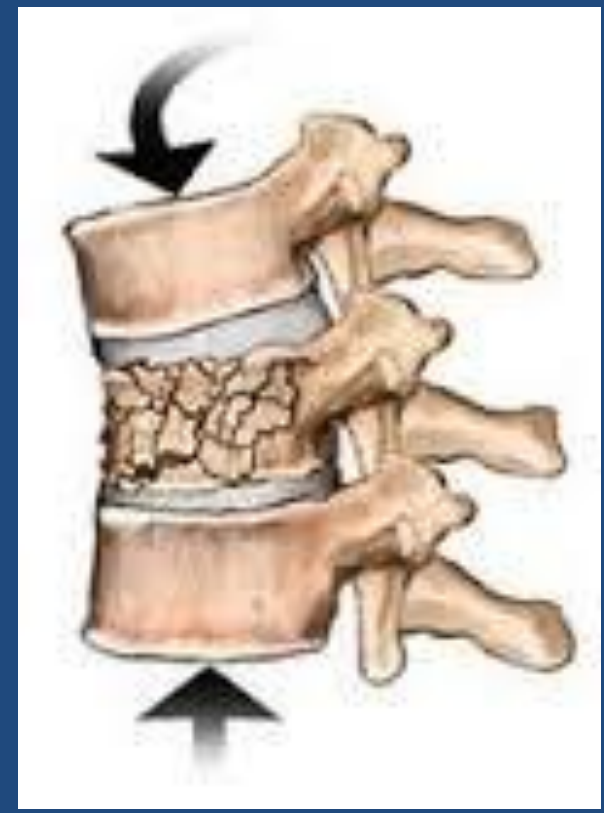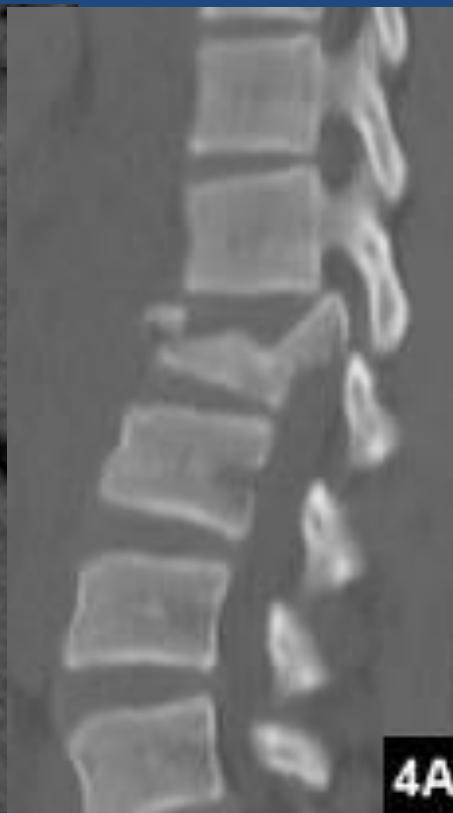
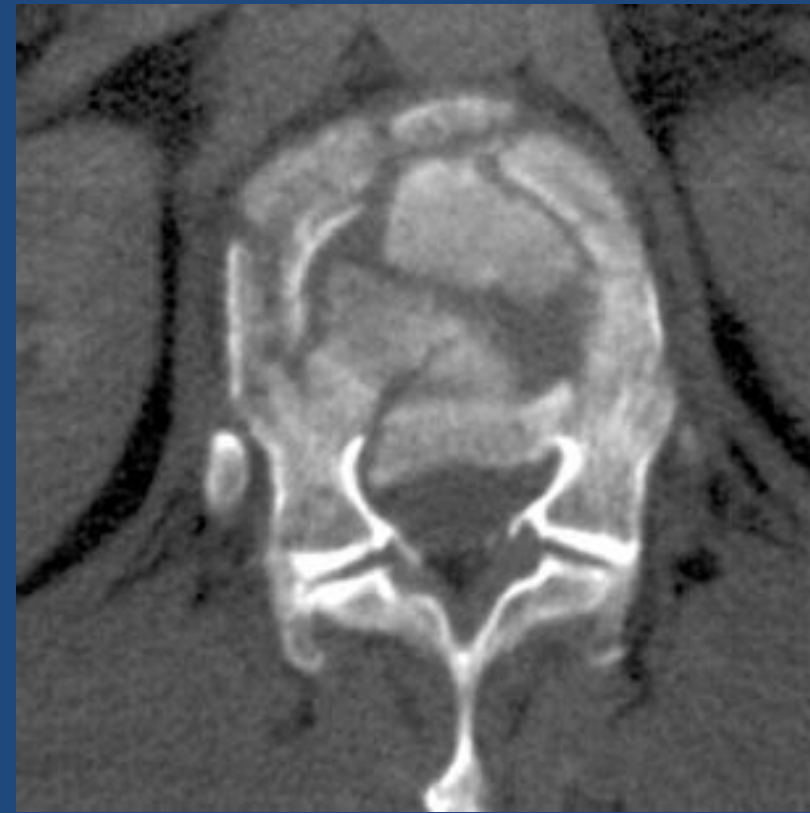Thoraco-Lumbar fractures

- Spinal cord terminates at L1/2 disc in adult
 - L2/3 in a child
- 50% of injuries occur at Thoraco-lumbar junction
- Common fractures:
 - Wedge fracture (flexion/compression)
 - Burst (compression)
 - Chance (flexion/distraction)

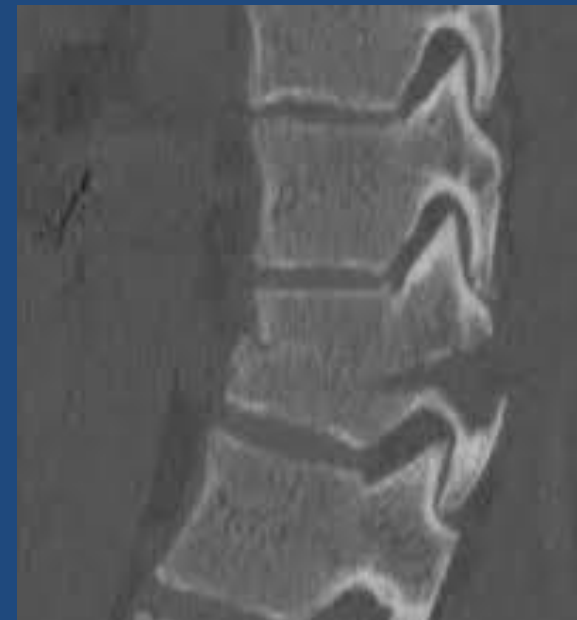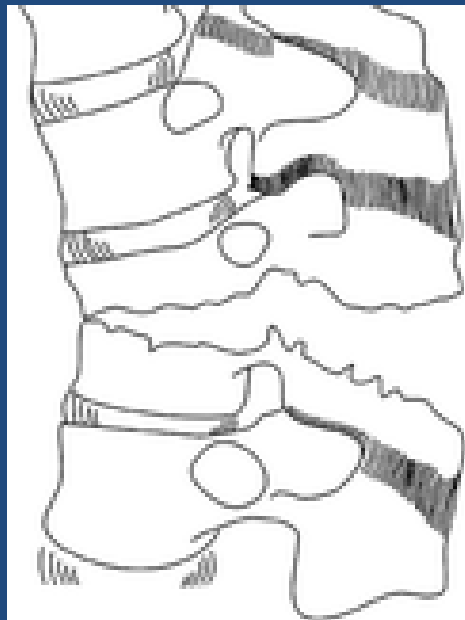
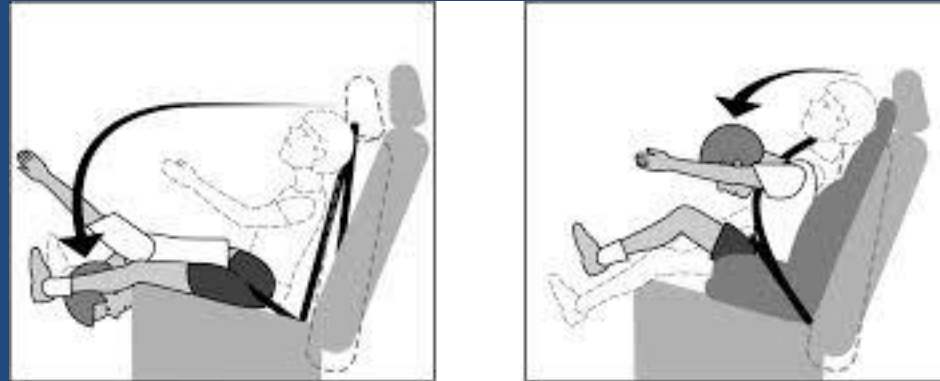
Wedge Fracture



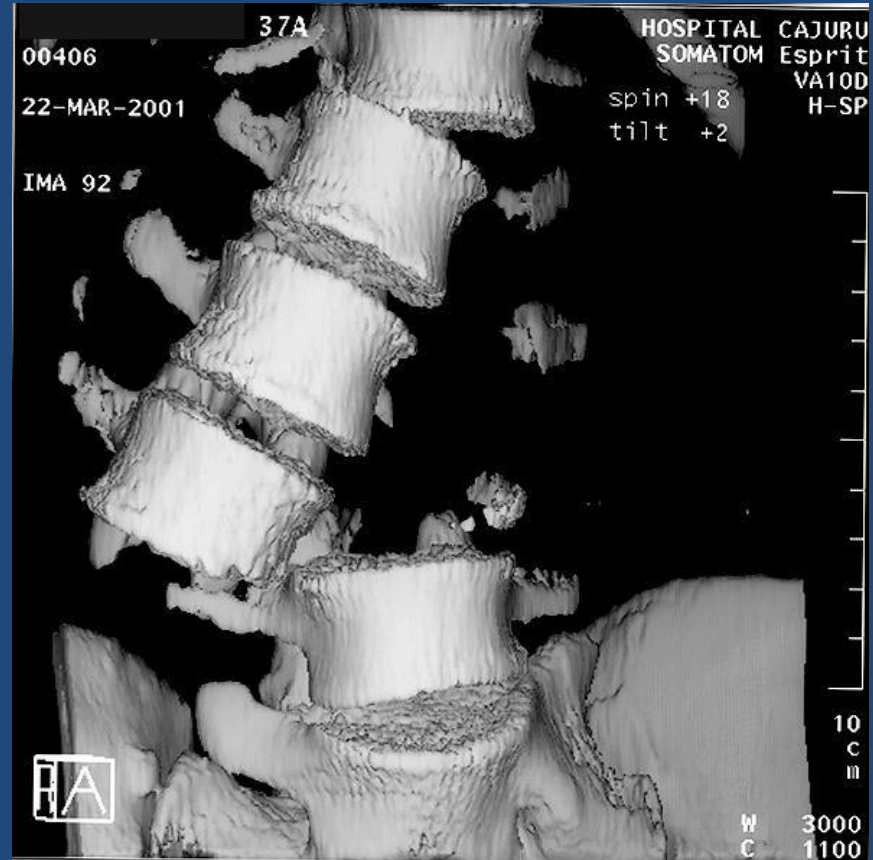
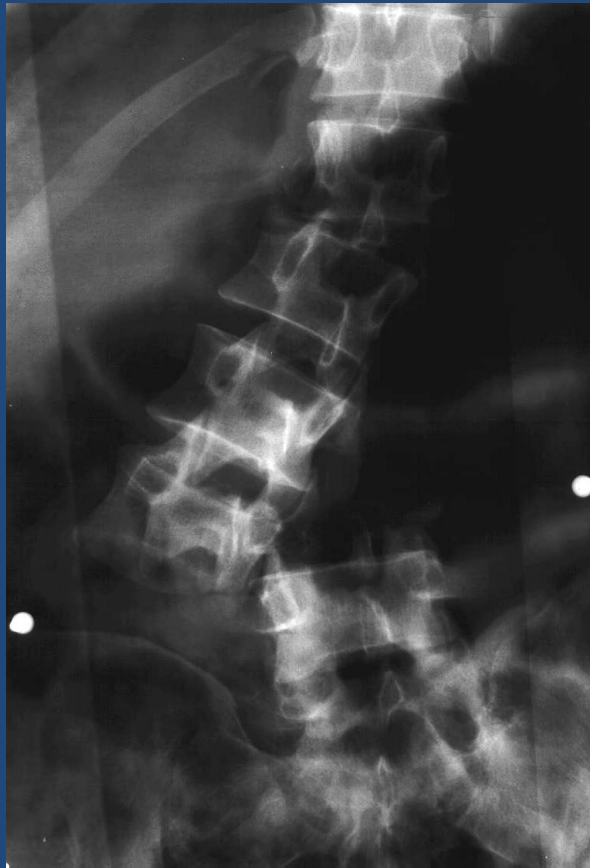Burst Fracture



Chance Fracture



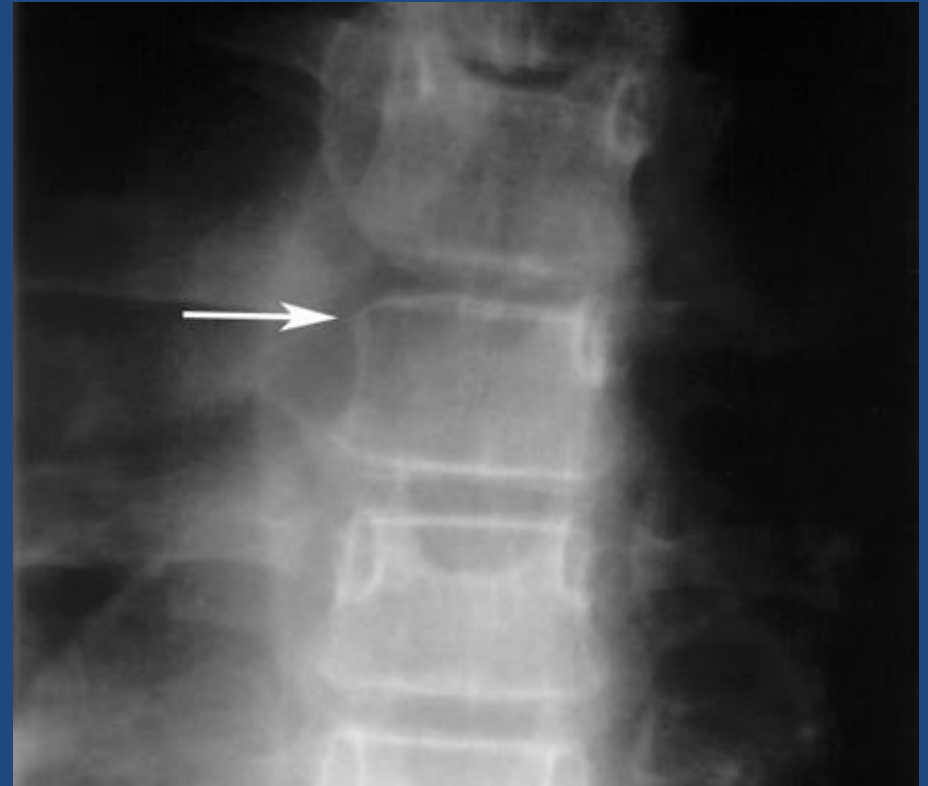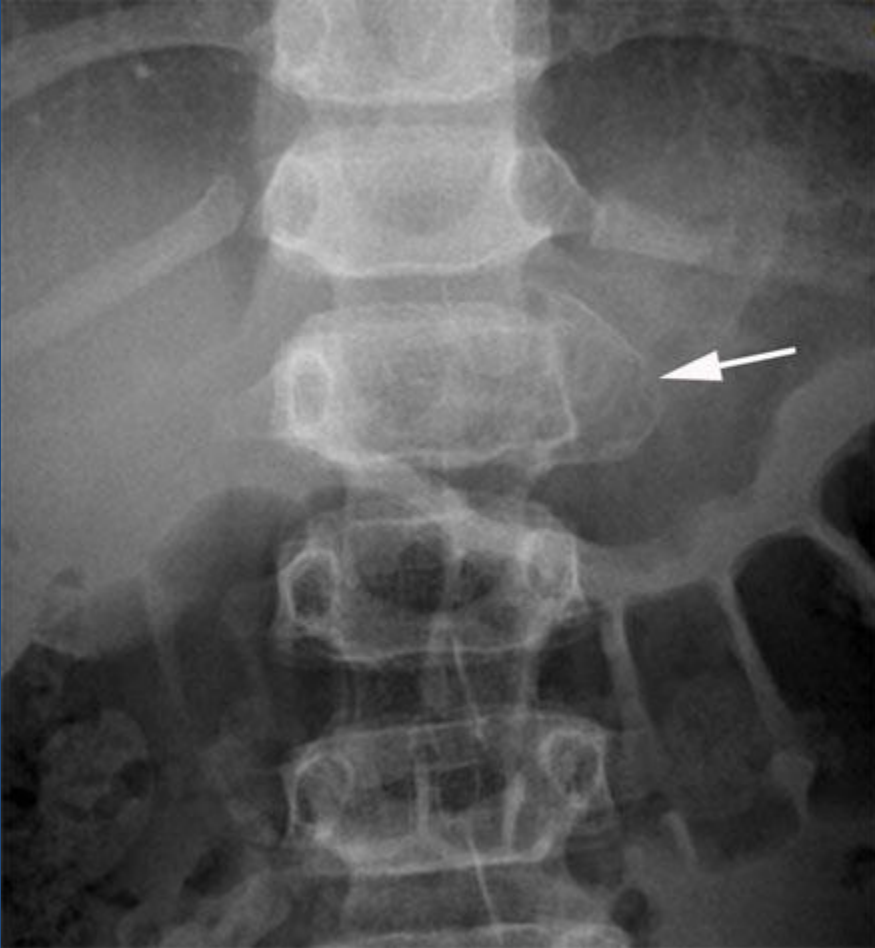Fracture dislocation



Pathologic fractures

- Usually due to infection or tumor
- Low-energy fractures
- Osteoporotic is common.
- X-rays: “winking owl” sign

Winking Owl sign

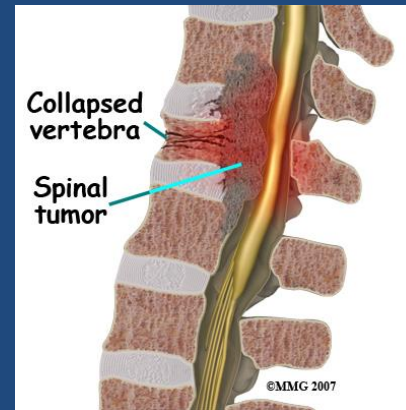


Cauda Equina Syndrome

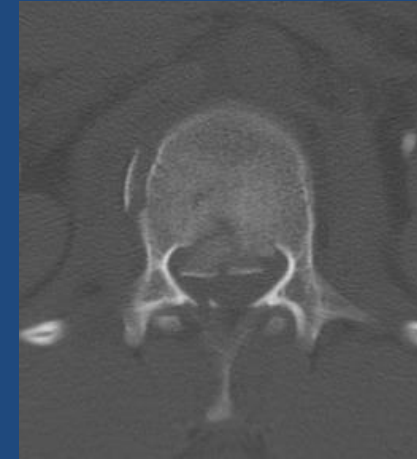
- A surgical emergency
- Requires full neurologic examination including rectal examination for anal tone
- Investigations: X-rays initially, but *MRI is mandatory as X-rays are usually unremarkable*
- Treatment: Emergency decompression-usually discectomy- within 24 hours.

Causes of Cauda Equina Synd.

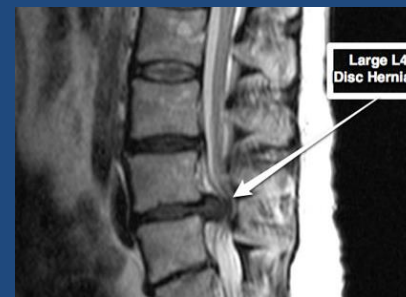- Central disc herniation.
- Burst fractures of lumbar spine.
- Tumors compressing the lower spinal nerve roots.
- Penetrating injuries such as stab wounds or bullets.



Tumor



Burst fracture



Disc hernia

Thank You