

# Neoplasms of the Nose and Paranasal Sinus



Khalid Hussain AL-Qahtani  
MD, MSc, FRCS(c)

Assistant Professor

Consultant of Otolaryngology

Advance Head & Neck Oncology ,  
Thyroid & Parathyroid, Microvascular  
Reconstruction, and Skull Base Surgery



# Neoplasms of Nose and Paranasal Sinuses

- Very rare 3%
- Delay in diagnosis due to similarity to benign conditions
- Nasal cavity
  - ½ benign
  - ½ malignant
- Paranasal Sinuses
  - Malignant

# Neoplasms of Nose and Paranasal Sinuses

- Multimodality treatment
- Orbital Preservation
- Minimally invasive surgical techniques

# Epidemiology

- Predominately of older males
- Exposure:
  - Wood, nickel-refining processes
  - Industrial fumes, leather tanning
- Cigarette and Alcohol consumption
  - No significant association has been shown

# Location

- Maxillary sinus
  - 70%
- Ethmoid sinus
  - 20%
- Sphenoid
  - 3%
- Frontal
  - 1%

# Presentation

- Nasal findings: 50%
  - Obstruction, epistaxis, rhinorrhea
- Oral symptoms: 25-35%
  - Pain, trismus, alveolar ridge fullness, erosion
- Ocular findings: 25%
  - Epiphora, diplopia, proptosis
- Facial signs
  - Paresthesias, asymmetry

# Radiography

- CT
  - Bony erosion
  - Limitations with periorbital involvement
- MRI
  - 94 -98% correlation with surgical findings
  - Inflammation/retained secretions: low T1, high T2
  - Hypercellular malignancy: low/intermediate on both
    - Enhancement with Gadolinium

# DDx

- Epithelial Benign:

- Fungiform papilloma
- Inverted papilloma
- Cylindrical papilloma
- Adenoma

- Epithelial Malignant

- Squamous cell ca
- Adenoid cystic ca
- Adenocarcinoma
- Melanoma
- Olfactory neuroblastoma
- Undifferentiated ca



# DDx

- Non-epithelial Benign:

- Fibroma
- Chondroma
- Osteoma
- Neurilemoma
- Neurofibroma
- Hemangioma

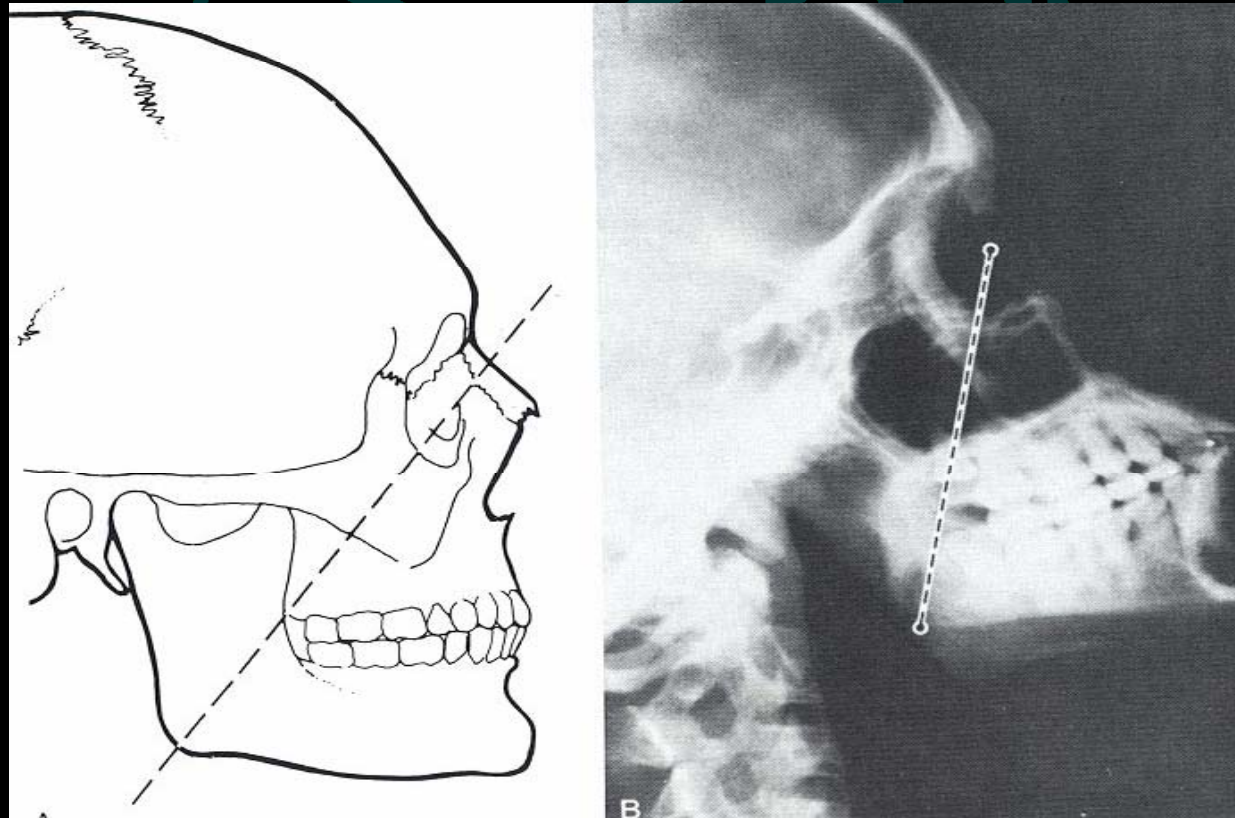
- Non-epithelial Malignant:

- Soft tissue sarcoma
- Connective-tissue sarcoma
- Lymphoreticular tumours

# Squamous cell carcinoma

- Most common tumor (80%)
- Location:
  - Maxillary sinus (70%)
  - Nasal cavity (20%)
- 90% have local invasion by presentation
- Lymphatic drainage:
  - First echelon: retropharyngeal nodes
  - Second echelon: subdiaphragmatic nodes

# Staging of Maxillary Sinus Tumors



# Staging of Maxillary Sinus Tumors

- T1: Tumor limited to maxillary sinus mucosa with no erosion or destruction of bone
- T2 : Tumor causing bone erosion or destruction including extension into the hard palate and/or middle nasal meatus, except extension to posterior wall of maxillary sinus and pterygoid plates
- T3 : Tumor invades any of the following: bone of the posterior wall of maxillary sinus, subcutaneous tissues, floor or medial wall of orbit, pterygoid fossa, ethmoid sinuses

# Staging of Maxillary Sinus Tumors

- T4a: Tumor invades anterior orbital contents, skin of cheek, pterygoid plates, infratemporal fossa, cribriform plate, sphenoid or frontal sinuses
- T4b: Tumor invades any of the following: orbital apex, dura, brain, middle cranial fossa, cranial nerves other than maxillary division of trigeminal nerve (V2), nasopharynx, or clivus

# Treatment

- 88% present in advanced stages (T3/T4)
- Surgical resection with postoperative radiation

# Orbital Invasion

- Pathways of invasion:
- Direct bony erosion (eg. medial wall or floor)
- Perivascular or perineural invasion (eg. infraorbital or ethmoidal NV bundles)
- Preformed pathways (eg. infraorbital fissure, nasolacrimal duct)

# Cervical Metastasis

- Incidence: 3-16% (10%)
- Poor prognostic indicator
- Elective neck dissection or irradiation for N0 neck not justified
- Cervical metastasis usually during first 48 months after initial treatment sign of tumour recurrence



# Pterygopalatine Fossa

- Incidence 10-20%
- Presence of tumour in this area a risk factor for recurrence
- Radical surgery and radiation therapy advised

# Infratemporal Fossa and Skull Base

- Pathways of invasion
- Direct bone erosion
- Preformed pathways (eg. cribriform plate, superior orbital fissure, foramen lacerum)
- NV structures (V2, V3)

# Craniofacial resection

- Absolute contraindications:
- Medical or nutritional problems (poor surgical candidate)
- Presence of distant metastases
- Invasion of prevertebral fascia
- Invasion of cavernous sinus
- Involvement of carotid artery in a high-risk patient
- Bilateral invasion of optic nerves or optic chiasm

# Craniofacial resection

- Relative contraindications:

Invasion of dura and intracranial involvement of neural structures by adenoid cystic ca

# Tracheostomy

- 130 maxillectomies only 7.7% required tracheostomy
- Of those not receiving tracheostomy during surgery, only 0.9% experienced postoperative airway complications
- Tracheostomy is unnecessary except in certain circumstances (bulky packing/flaps, mandibulectomy)

# Treatment of the Orbit

- Before 1970's orbital exenteration was included in the radical resection
- Preoperative radiation reduced tumor load and allowed for orbital preservation with clear surgical margins
- Currently, the debate is centered on what "degree" of orbital invasion is allowed.

# Current indications for orbital exenteration

- Involvement of the orbital apex
- Involvement of the extraocular muscles
- Involvement of the bulbar conjunctiva or sclera
- Lid involvement beyond a reasonable hope for reconstruction
- Non-resectable full thickness invasion through the periorbital into the retrobulbar fat

# COMPLICATIONS

- Orbital:
- Epiphora
- Diplopia
- Blindness:
- Exophthalmos or hypophthalmos



# COMPLICATIONS

- Skull Base:
- CSF leak
- Meningitis
- Pneumocephalus
- Osteomyelitis

# Conclusions

- Neoplasms of the nose and paranasal sinus are very rare and require a high index of suspicion for diagnosis
- Most lesions present in advanced states and require multimodality therapy