

Case Report

Anesthetic consideration in dystrophic epidermolysis bullosa

ABSTRACT

Epidermolysis bullosa is a group of inherited rare skin disease, characterized by bullae formation in the skin or mucous membranes. The fundamental abnormality is collagen degeneration leads to splitting of various epidermal layers. Dystrophic epidermolysis bullosa (DEB) is one of the major forms of epidermolysis bullosa. These patients often admitted to the hospital for corrective surgeries, change of dressing, contracture release, and skin grafting. Anesthetic management of these cases is always a challenge. We are reporting a case of 5-year-old boy diagnosed as a case of DEB scheduled for upper lip contracture release, skin grafting and debridement of nonhealing scars under anesthesia. In this case, we have focused mainly on the anesthetic management, preparation of the monitoring, transportation, difficulties in establishing the venous accesses, and airway management.

Key words: Anesthesia; dystrophic epidermolysis bullosa; management

Introduction

Epidermolysis bullosa is a rare skin disease with hallmark of blistering in response to minor injury, heat or friction, rubbing, and scratching from adhesive tapes. These disorders can be categorized into three groups depending on where the actual skin separation occurs, epidermolysis simplex, junctional epidermolysis, and epidermolysis bullosa dystrophica (DEB).^[1] In Saudi Arabia, 33-cases were reported from 1988 to 2004.^[2] In literature, very few cases are reported regarding anesthetic considerations of patients with the DEB. Airway control and maintenance of skin integrity are the major concerns in anesthetic management. DEB presents at birth or in infancy is one of the severest forms. This case illustrates the perioperative anesthetic management of a diagnosed case of DEB scheduled for plastic surgery for nonhealing upper lip ulcers and circumoral scars.


Case Report

Five-year-old boy diagnosed as a case of DEB at birth. Few months later he was diagnosed with a G6PD deficiency. Presented with nasal obstruction due to blister scarring of the upper lip. He was admitted multiple times for dermatology follow-up, chronic anemia, and infection control. Skin erosions were present on his anterior surface of hands, forearms, legs, chest, back, and abdomen. He was scheduled for contracture release, debridement and skin grafting of upper lip [Figure 1]. Family history includes father was a diagnosed case of G6PD deficiency and mother carrier sickle cell anemia. Laboratory investigations were normal except hemoglobin (Hb) was 7.9 g/dl His body weight was 11 kg and height 101 cm. Preoperatively he was hemodynamically stable and chest was clear. On airway examination, he had hoarseness of voice, restricted mouth opening due

This is an open access article distributed under the terms of the Creative Commons Attribution-NonCommercial-ShareAlike 3.0 License, which allows others to remix, tweak, and build upon the work non-commercially, as long as the author is credited and the new creations are licensed under the identical terms.

For reprints contact: reprints@medknow.com

How to cite this article: Narejo AS, Khan MU, Alotaibi WM, Khan MM. Anesthetic consideration in dystrophic epidermolysis bullosa. Saudi J Anaesth 2016;10:110-2.

Access this article online	
Website: www.saudija.org	Quick Response Code 
DOI: 10.4103/1658-354X.169489	

NAREJO AS, KHAN MU, ALOTAIBI WM, KHAN MM

Department of Anesthesia, College of Medicine, King Saud University, Riyadh, Saudi Arabia

Address for correspondence: Dr. Abdul Sattar Narejo, Department of Anesthesia, College of Medicine, King Saud University, Riyadh 74800, Saudi Arabia. E-mail: narejo27@hotmail.com

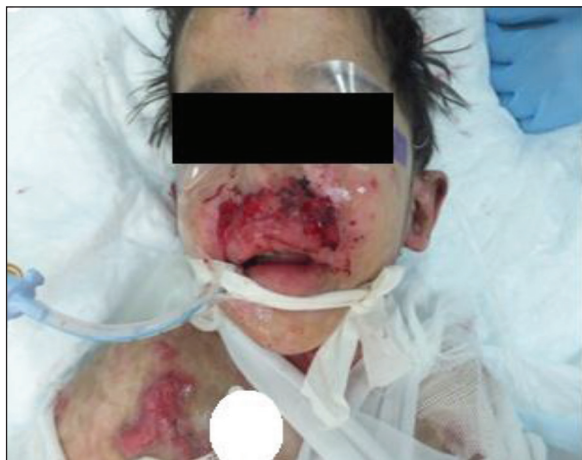

Figure 1: 5-year-old boy diagnosed case of dystrophic epidermolysis bullosa, immediately after induction of anesthesia

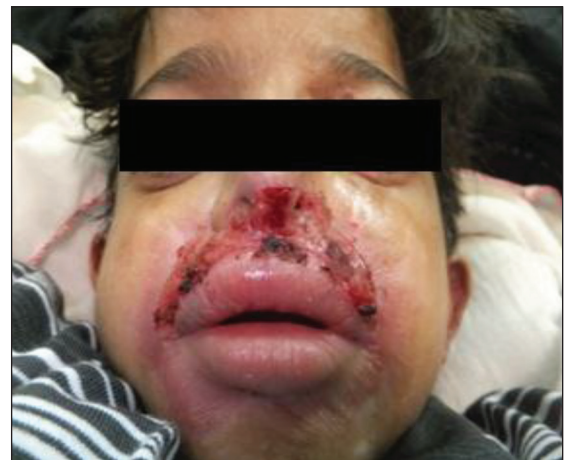

Figure 2: 5-year-old boy diagnosed case of dystrophic epidermolysis bullosa. Postoperatively after plastic surgical repair in post-anesthesia care unit

to contractures at angle of mouth, denuded oral mucosa, degenerative teeth enamel, and bad oral hygiene. The risk of difficult and traumatic endotracheal intubation was considered. Alternatives for establishing a secure airway and difficult intravenous (IV) access were discussed with the family and surgeon. Preoperatively blood transfusion was done and Hb was corrected to 10 g/dl. During shifting from ward to operation room table, all pressure areas were padded with cotton to avoid any friction and trauma to the skin. Lubricated central gel part of electrocardiography (ECG) electrodes was placed on the healthy skin, SpO₂, and noninvasive blood pressure cuff was applied on better arm padded with cotton. Non-adhesive tape was used for endotracheal tube and IV catheter fixation. Anesthesia was induced with IV propofol 2-mg/kg, and suxamethonium 1.5 mg/kg. Atraumatic endotracheal intubation was performed with size 5.5 mm PVC non-cuffed endotracheal tube in second attempt using lubricated laryngoscope blade. IV Cisatracurium 0.1 mg/kg as a muscle relaxant and fentanyl 2 mcg/kg were given for analgesia. Anesthesia was maintained with sevoflurane 1-2% in 40% oxygen with air. Total duration of surgery was 2.5 h which was uneventful. Blood loss of 150 ml was replaced with packed red blood cells transfusion. At the end of surgery, muscle relaxant was reversed and trachea was extubated when patient was fully awake and shifted to post-anesthesia care unit [Figure 2]. Postoperatively morphine 2 mg IV was given for analgesia.

Discussion

Epidermolysis bullosa is autosomal inherited or acquired pediatric disease characterized by bullae formation in the skin or mucous membranes. The reported incidence is about 20 cases per one million inhabitants.^[3] The acquired forms are autoimmune disorders in which autoantibodies

are produced that destroy the basement membrane of the skin and mucosa. DEB is caused by a defect in type VII collagen. DEB produces severe scarring of the fingers and toes with pseudosyndactyly formation, ankylosis of the interphalangeal joints, and resorption of the metacarpals and metatarsals.^[4] Involvement of the esophagus and heart resulting in dysphagia, esophageal strictures, dilated cardiomyopathy, and formation of intracardiac thrombi. Hypoalbuminemia, secondary to nephritis and protein loss into bullae is usual. Anemia is due to poor nutrition and repeated infections. Hypoplasia of tooth enamel results in carious degeneration of the teeth. DEB patients rarely survive beyond the third decade. Medical therapy for DEB has not been very successful. Skin transplantation with gene therapy, stem cell transplantation and intradermal injection of allogeneic fibroblasts may be an effective treatment in future.^[5]

Anesthetic management and nursing care of DEB patients are always a challenge. In order to avoid skin trauma and mucous membranes, ECG gel pads can be used. Blood pressure cuff should be padded with cotton dressing and intravascular catheters should be anchored with sutures or gauze dressing rather than tape. Face mask trauma can be minimized by appropriate filling of face mask cuff and lubrication of the face mask and patient's face. The use of upper airway devices should be avoided because frictional trauma to the oropharynx can result in the formation of intraoral bullae, airway obstruction, and extensive hemorrhage. Laryngeal involvement is rare in patients with DEB. If tracheal intubation is required, the laryngoscope and tracheal tube should be well lubricated to reduce friction against the oropharyngeal mucosa. Scarring of the oral cavity can cause microstomia and immobility of the tongue that increases the difficulty of tracheal intubation. Endotracheal intubation is generally

safe,^[6] however, fiberoptic tracheal intubation may be considered for atraumatic endotracheal intubation. In our patient, we have observed all possible precautions and trachea was atraumatically intubated and extubated successfully. Peripheral surgeries can be performed using IV ketamine which provides good analgesia and sedation. However, there is no contraindication to inhaled anesthetics. Regional anesthesia, including spinal, epidural, and brachial plexus anesthesia is safe for DEB patients.^[7]

Despite of all potential complications careful intraoperative management is associated with few adverse effects. Avoiding trauma to the fragile skin and mucus membranes is the key to success for providing atraumatic anesthetic care to DEB patients. We suggest that DEB patient care should be provided in centers where adequate facilities and expertise are available for taking care of these types of patients.

Declaration of patient consent

The authors certify that they have obtained all appropriate patient consent forms. In the form the patient(s) has/have given his/her/their consent for his/her/their images and other clinical information to be reported in the journal. The patients understand that their names and initials will not be published and due efforts will be made to conceal their identity, but anonymity cannot be guaranteed.

Financial support and sponsorship

Nil.

Conflicts of interest

There are no conflicts of interest.

References

1. Ho AM, Tsui CS. Epidermolysis bullosa in a newborn. *Anesthesiology* 2012;116:925.
2. Jalalah SM, Sawan AS, Zimmo SK. Epidermolysis Bullosa: Experience from the western province of Saudi Arabia. *J King Abdulaziz Univ Med Sci* 2006;13:49-58.
3. Galan Gutierrez JC, Martinez Suarez MA, Tobera Noval B, Avello Taboada R, Herlitz. Epidermolysis bullosa in the paediatric patient: Anaesthetic implications. *Rev Colomb Anesthesiol* 2014;42:132-5.
4. Fine JD, Johnson LB, Weiner M, Stein A, Cash S, Deleoz J, *et al.* Pseudosyndactyly and musculoskeletal contractures in inherited epidermolysis bullosa: Experience of the National Epidermolysis Bullosa Registry, 1986-2002. *J Hand Surg Br* 2005;30:14-22.
5. James I, Wark H. Airway management during anesthesia in patients with epidermolysis bullosa dystrophica. *Anesthesiology* 1982; 56:323-6.
6. Boschini M, Ellger B, van den Heuvel I, Vowinkel T, Langer M, Hahnenkamp K. Bilateral ultrasound-guided axillary plexus anesthesia in a child with dystrophic epidermolysis bullosa. *Paediatr Anaesth* 2012;22:504-6.
7. Herod J, Denyer J, Goldman A, Howard R. Epidermolysis bullosa in children: Pathophysiology, anesthesia and pain management. *Paediatr Anaesth* 2002;12:388-97.