



KING SAUD UNIVERSITY
College of Dentistry

Department of Restorative Dental Sciences
DIVISION OF ENDODONTICS

322 RDS
Pre-Clinical Endodontics Manual

Third Year

Course Director:

Dr. Ahmed Alkahtani

Course Contributors

Prof. Saad Al-Nazhan

Dr. Sulaiman Al-Hadlaq

Dr. Ahmed Bamanie

Dr. Abdulrahman Al-Ghamdi

Dr. Tariq Al Jebreen

Dr. Mohammed Al Obaida

Dr. Abdullah Al-Daafas

Dr. Ziad Al Lahem

2009 – 2010

322 RDS

PRE-CLINICAL MANUAL
PART I

Contents:

		Page
Session	Guidelines for 322 RDS	4
1	Teeth Selection	7
	Mounting	8
	Endodontic Radiography “Basic Concepts”	10
2	Endodontic Instruments	14
	Rubber Dam Isolation	19
3	Access Cavity Preparation of Anterior Teeth	21
	Premolars	28
4	Working Length Determination on 1 st Anterior tooth	35
5	Instrumentation, Stepback Technique	40
6	A. Obturation, B. Temporization	43
7	Access, Working length determination and Instrumentation on 2 nd anterior tooth.	49
8	Obturation and temporization of 2 nd anterior tooth.	57
9	FIRST PRACTICAL ASSESSMENT- Endodontic Instrument spotting	59
10	Access, Working length determination and Instrumentation on 3 rd anterior tooth	60
11	Obturation and temporization of 3 rd anterior tooth.	62
12	Endodontic Radiography : Buccal Object Rule	63
	Access, Working length determination on first premolar (2 canals)	
13	Instrumentation on first premolar (2 canals)	64
14	Obturation and temporization of first premolar (2 canals)	66
15	Access, Working length determination and Instrumentation on 2 nd premolar (one canal)	67
16	Obturation and temporization of 2 nd premolar (one canal)	69
17	SECOND PRACTICAL ASSESSMENT Access cavity preparation, instrumentation and obturation of an anterior or single canal premolar tooth	

322 RDS
PRE-CLINICAL MANUAL
PART II

Contents:

Session		Page
1	Teeth Selection	71
2	Access Cavity Preparation	72
	Maxillary Molars	73
	Mandibular Molars	76
3	Access cavity preparation and working length determination of 1 st molar tooth	79
4	Instrumentation of 1 st molar tooth	82
5	Obturation of 1 st molar tooth	83
6	Access cavity preparation and working length determination of 2 nd molar tooth	84
7	Instrumentation of 2 nd molar tooth	86
8	Obturation of 2 nd molar tooth	87
9	THIRD PRACTICAL ASSESSMENT - Access cavity preparation	
10	Post Space Preparation	88
11	Access cavity preparation, working length determination and instrumentation of 3 rd molar tooth	90
	Use of Gates Glidden Drills	89
12	Continue Instrumentation and Obturation of 3 rd molar tooth	92
13	Retreatment Ca(OH) ₂ Application	93
14	FINAL EXAM - Access Cavity Preparation, instrumentation, and obturation of a molar.	
15	FINAL EXAM - Access Cavity Preparation, instrumentation, and obturation of a molar.	

Important Guiding Principles to be observed in Practical (Lab) of Course 322 RDS

General:

1. Mobile phones must be turned off throughout the session.
2. All students must wear prescribed uniform, appropriate shoes
3. Reports on students' performance will be submitted to the department chairman twice in each semester.
4. Absence will be reported to the administration when it reaches 25% or above.

This course is “four (4) credit hours” and consists of two (2) components: Didactic and Practical:

In the Practical Part:

1. Laboratory session will start immediately after the lecture.
2. Attendance sheet will be passed around in the laboratory for the first 15 minutes only.
3. Each student should have her own ruler, endodontic box and instruments, and a well-sealed container to keep the dentoform.
4. Between the practical sessions, the mounted teeth should be covered with gauze pads soaked with saline solution and kept in a sealed container to ensure 100% humidity and prevent tooth cracking during instrumentation and obturation. **The dentoform should not be soaked in water.**

5. The dentoform should be cleaned periodically **(with a toothbrush)**. Unclean, foul-smelling or otherwise unpresentable dentoforms will be penalized by deducting marks.
6. No one will be allowed to leave the laboratory session without the designated instructor's permission.
7. You should stick to your designated instructor for any inquiries or questions unless he/she is not around or absent.
8. Always show your instructor your work during the session.
9. Working with the model in your hand or without rubber-dam is totally prohibited, and will result in a score of ZERO.
10. An evaluation form designed in a way to guide the student to evaluate her work at each step will be used. In the first two cases the instructor will show the student her mistakes at each step and give her the grade accordingly. Later the student shall evaluate her work and correct if possible before seeking the advice of her instructor.
11. Make sure to have your evaluation form signed and graded by the assigned instructor at the end of each session. All dentoforms and evaluation forms should be left with the lab technician at the end of the session. Any forms or dentoforms not with the lab technician will be subject to questioning and possible mark deduction.
12. Students who fail to have their evaluation form signed in the same session **CAN NOT** have it signed the following week.
13. **Each finished case must be handed over to the course director in the endodontic form.**

- a. The endodontic form must be completed (e.g. student's name, finished date, case number, tooth number, working length, size of MAF – etc.)
 - b. The radiographs of the finished case must be mounted, dated and submitted in the endodontic form.
14. Cases with incomplete data will not be considered.
 15. Student will lose 2 points for missing radiograph, poorly preserved radiographs, or poorly mounted radiographs.
 16. Students are not allowed to use the facility of radiograph in the x-ray department during the session.
 17. You are strictly prohibited to use the manual processing after the laboratory session.
 18. All students must finish their laboratory work by 4:30 PM.

Session 1

A. Teeth Selection

- Freshly extracted teeth will be used in this course. The teeth must be clean, free of debris and preferably have sound crown or with minimum caries destruction.
- The pulp chamber and canals must be accessible as confirmed by radiographs:
 - Teeth with immature apices.
 - Teeth with calcified canals.
 - Teeth with severely curved canals.
 - Teeth with previous root canal treatment.
 - Teeth with internal or external root resorption.
 - Teeth with too short or too long root should not be used.
- All the selected teeth (7 anterior, 4 premolars and 7 molars) must be approved by your instructor before mounting.
- If you have not collected enough teeth for mounting during the first two weeks of the course, you have two options:
 1. Collect at least enough teeth (approximately half) to mount one jaw (maxillary or mandibular).
 2. Mount as many teeth as you can, and place wax in the area of the remaining teeth, then as you collect more teeth remove the wax and replace it with teeth.
- Students are encouraged to cooperate with one another and exchange teeth to complete collection of suitable teeth.

B. Mounting

Upper and lower jaw moulds will be provided. Use the upper and lower rubber moulds for mounting as follows:

1. The apices of the selected teeth should be covered with small balls of beading wax to simulate periapical lesion.
2. Each tooth should be placed into its individual socket in the rubber mould. Be sure of the orientation of each tooth surface before pouring the mixture.
3. In a disposable paper cup add:
 - 3 x 25 ml scoops polymer (powder)
 - 3 x 25 ml scoops saw dust
4. Mix until the mixture becomes homogenous.
5. Add the mixture to approximately 6.5 x 5.5 ml measuring cylinders (**35 ml monomer** (liquid) and mix until a smooth creamy mass is obtained.
6. Pour the mixture slowly into the rubber mould covering the apices of the roots.
7. During the initial setting of the acrylic, a threaded plastic lock component of a screw attachment should be embedded in the middle of the acrylic base. The key component of the attachment that is in the manikin phantom head can be screwed into the lock component. This permits stable mounting of the model in the manikin phantom head.

8. Mounting teeth for access cavity preparation exercises should be on a separate block.

Three blocks should be made by mixing plaster of paris and water and placing it in a rectangular mold. The teeth should be embedded into the plaster till the CEJ and left to dry.

The teeth selected should have complete crowns, teeth with unacceptable roots for the endodontic therapy exercises may be used.

The sets of teeth should be:-

- a) 2 anterior teeth and 1 premolar in one block.
- b) Two molars (maxillary and mandibular) in one block.
- c) One anterior, one premolar, and one molar in one block. This will be saved for the access cavity preparation practical assessment. This block should be prepared, approved by the course director, signed, stored in a container and handed in before the day of the designated assessment.

C. Endodontic Radiography Basic Concepts

Radiographs are essential to all phases of endodontic therapy. They assist in the diagnosis and the various treatment phases and help evaluate the success or failure of treatment

Principles of Endodontic Radiography

- Size 1 film should be used for the anterior teeth and size 2 for the posterior teeth.
- Insert the film in the groove, so that the tooth that needs to be exposed will be in the middle of the film.
- The front of the radiograph packet has a small raised dot; this side is always placed towards the x- ray tube. The back, which has the tab used for opening the packet before processing, is always placed away from the tube.
- For the anterior teeth the paralleling technique will be used (also known as the long-cone or right angle technique).

In this technique the film is placed parallel to the long axis of the teeth and the central beam is directed at right angles to the film and aligned through the root apex (Fig 1)

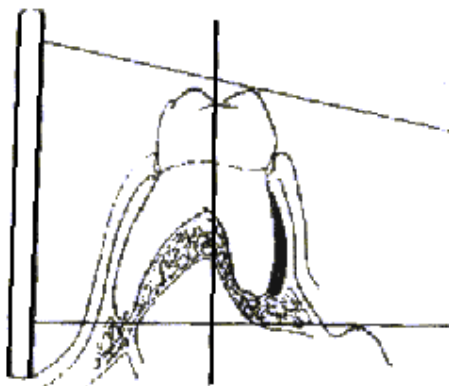


Fig.1

Processing

Proper processing is as important as the exposure technique in producing good diagnostic quality radiographs.

- If the film is overexposed or over developed, it will be dark.
- If the film is underexposed, underdeveloped, or overfixed, it will be light.

Manual processing machines will be used for film developing. Manual processing depends upon a combination of temperature (of the solution) and time (how long the film remains in each solution). Both are critical for successful processing of the films.

Each manual-processing machine contains separate processing tanks (cups) for developer, rinse water, and fixer solution.

To develop the film:

1. Place your hands through lightproof cuffs and observe your hand movement inside the hood through the red Plexiglass cover.
2. Open the film under the hood; caution should be taken to hold the films only by their edge to avoid damage to the film surface.
3. Attach the films to the film holder so that films are parallel and not touching each other. **The film packets should be thrown in the trash and not in the hood.**
4. Immerse the film (**for at least 1 minute**) in the developer with mild agitation to sweep air bubbles off the film and bring

fresh developer in contact with the entire surface of the emulsion.

5. After development, the films are rinsed in the tank running water for about 20 seconds. **This step will remove much of the excess developer that would otherwise contaminate the fixer.**
6. Immerse the films in the fixer (and agitate a few times to eliminate bubbles) for about 10 minutes. If the films must be viewed, they can be removed from the fixer after 3 minutes. However, they must be returned to the fixer for a total of 10 minutes.
7. Finally the films should be rinsed under running water and then kept in a disposable cup containing water for about 1 – 2 hours and then air-dried. **Failure to do this step will result in an incomplete wash, and the films will eventually turn brown.**
8. When the films are completely dry, they should be mounted in an appropriately labeled frame. If the films are to be mounted with the images of the teeth in the anatomical position, they should be mounted with the convex side of the dot toward the viewer.

A Diagnostic Endodontic Film requires that:

- The tooth is centered on the film.
- At least 5mm of bone beyond the apex of the tooth is visible.
- The image is as anatomically correct as possible.


Total of 6 radiographs will be taken and mounted for each case.

- Preoperative radiograph (without rubber dam).
- Working length radiograph (with rubber dam).
- Master apical file radiograph (with rubber dam).
- Master cone radiograph (with rubber dam).
- Intermediate radiograph (with rubber dam).
- Final radiograph (without rubber dam).


Session 2

A. Endodontic Instruments

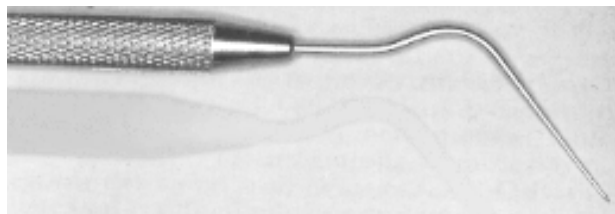
1. Endodontic Explorer



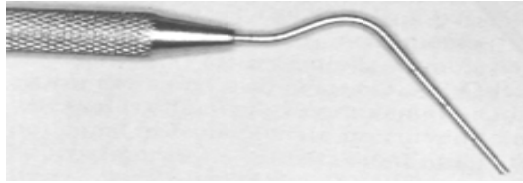
2. Endodontic Spoon Excavator



3. Spreaders



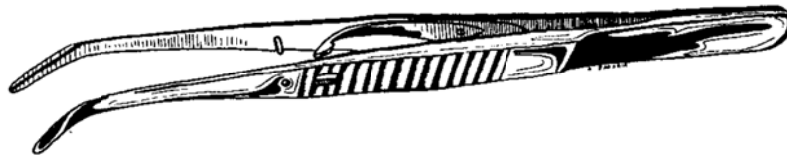
4. Pluggers



5. Plastic Instrument



6. Endodontic Locking Pliers

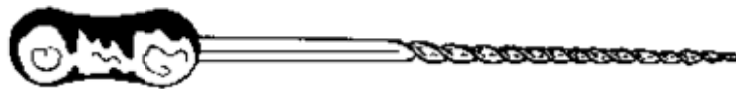

Hand Instruments

1. Broaches:



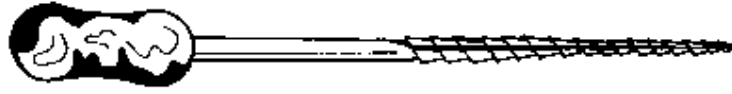
2. Endodontic Files:



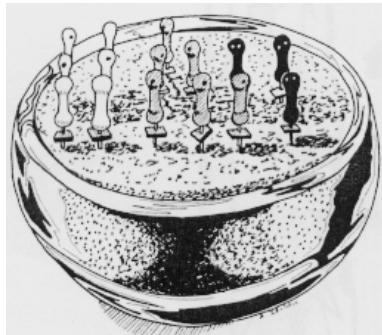3. Reamers:



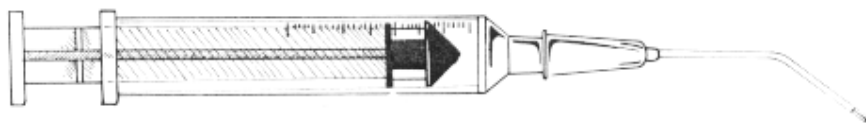
4. Hedstrom Files (H- file)



5. Transfer sponge



11. Endodontic Syringe




II- Engine-Driven Instruments

1. Gates-Glidden Burs



2. Pessio Reamers



3. Lentulo Spirals



B. Isolation

Definition:

To isolate the tooth that needs root canal treatment from other teeth in the mouth using rubber-dam.

No isolation, No root canal treatment

Rubber Dam Equipment:

I. Dam Material

II. Frame

III. Clamps

- There are many different styles and shapes of clamps that have been designed for numerous different situations.
- Regardless of the type of jaw configuration, **the prongs of the jaws should engage at least four points on the tooth.**
- For most uncomplicated endodontic isolation, the dentist's basic armamentarium should consist of winged clamps .A butterfly type for anterior teeth (e.g. Ivory 9" or #212), universal premolar clamp (e.g. Ivory 2), mandibular molar clamp (e.g. Ivory 56), and maxillary molar clamp (e.g. Ivory 14)
- Clamps may also be modified by grinding to adapt to unusual situations.

IV. Punch

V. Forceps

VI. Tucking Instrument

A plastic instrument or spoon excavator is used to slide the rubber dam off the wings of the clamp and invert the edge of the dam into the gingival sulcus.

VII. Dental Floss

Dental floss is used for testing of contacts prior to dam application and for passing the dam material through the contacts of the teeth.

Technique of Application

There are many methods that can be used to place the rubber-dam. However, the most efficient method that can be used in the vast majority of cases is the following:

1. Select clamp to be used
2. Test contacts with floss to ensure passing of dam and to test for sharp edges that might tear the dam.
3. Punch one appropriate sized hole just off center of a dam material
4. Place the wings of the selected clamp in the punched hole with the bow of the clamp to the distal
5. Once the clamp is secured on the tooth, the dam is teased under the wings of the clamp with a plastic instrument.
6. Finger pressure is used to ensure seating of the clamp.
7. Draw the dam through the contact area with floss.
8. Stretch the dam over the frame.

Removal of the Dam

Simply remove the clamp with the forceps and remove the dam.

Session 3

Access Cavity

Session 3

Access Cavity

Definition:

Root canal access is the cavity prepared in the crown of the tooth to reach the root canal.

Purpose:

The purpose of an adequate access cavity is to gain direct access to the root canal for cleansing, enlarging, shaping, and filling of the root canals.

Instruments:

A good root canal access can be made with:

1. A #2, #4, or #6 Round bur
2. An endodontic explorer

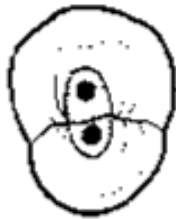
Technique:

The following is a general technique for opening an access cavity. The different teeth have different access cavities and you should refer to the access cavity preparation section for each tooth you are working on.

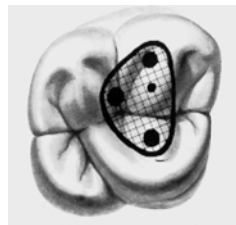
1. Draw an outline of the access cavity on either the lingual (for anterior teeth) or the occlusal surface (for premolars and molars). The outline of the access generally follows the shape of the tooth (i.e. triangular in anterior, oval in premolars, square in molars).



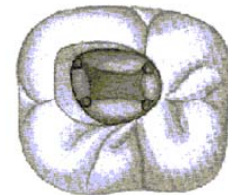
Incisor



Premolar

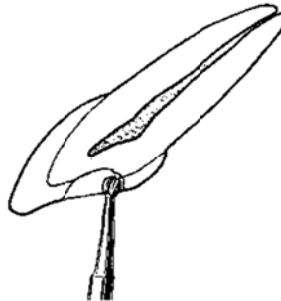
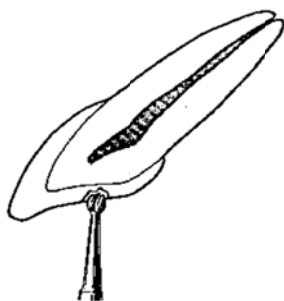

Max. molar

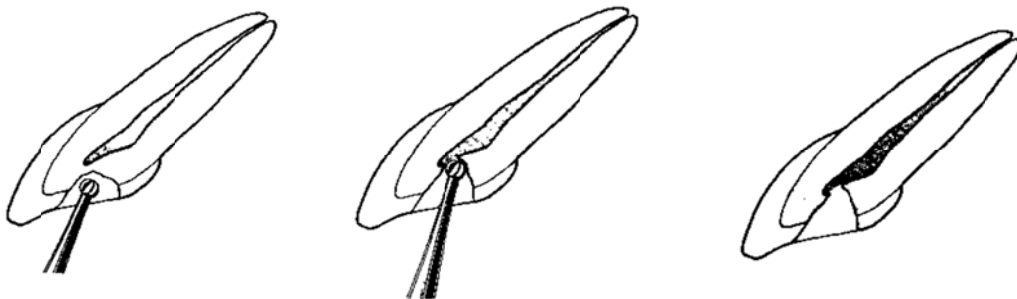


Mand. molar

2. Make the initial access using a #4 Round bur positioned at right angles (perpendicular) to the center of the outline. Once you reach the dentine, extend your cavity to include all caries, old restorations, and unsupported enamel.



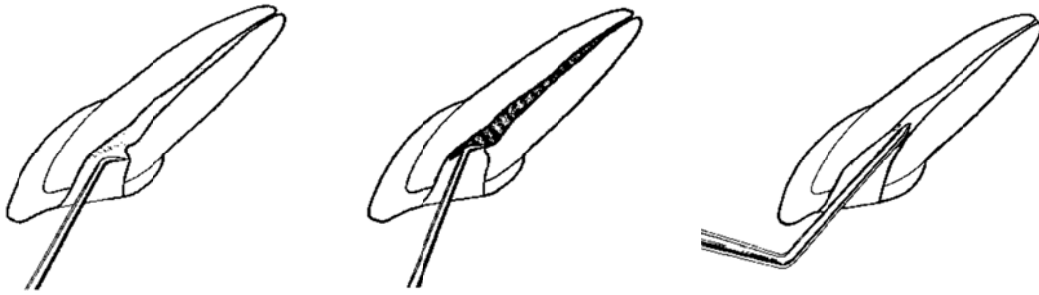
3. Extend your bur in the center of your outline beyond the dentine. Once you reach the pulp you will feel a “drop”. This indicates you have reached the pulp tissue. This feeling depends on your tactile sensation and it must be practiced to be perfected.



4. Once you have “dropped” into the pulp chamber, move your slowspeed bur from the inside of the pulp chamber to the outside uncovering the pulp chamber. MOVE ONLY WITH AN OUTWARD MOVEMENT. The operative word is UNCOVER. DO NOT DIG into the pulp chamber, otherwise you will perforate the floor of the pulp chamber.



5. Evaluate your exposed pulp chamber with your endodontic explorer.
 - a. Try to locate pulp horns to include in your access cavity.
 - b. Try to locate all your canal orifices and ensure there is straight-line access to them. (Your explorer should not bend to the side).

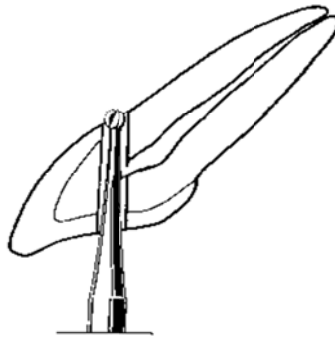


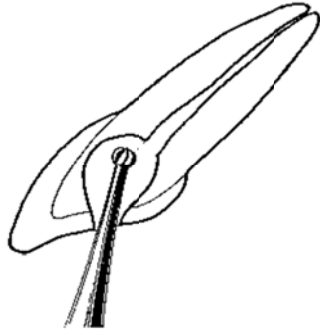
6. Make sure that the occlusal surface is flat, as this will serve as a reference point for your future measurements. It must be flat, and level.

Evaluation Criteria:

1. Correct Location
2. Proper Outline
3. Pulp Chamber Deroofed
4. Pulp Horns Removed
5. No Overextension
6. No Gouging
7. Smooth Walls
8. Clean Cavity
9. Straight Line Access to canals
10. All Canals Located

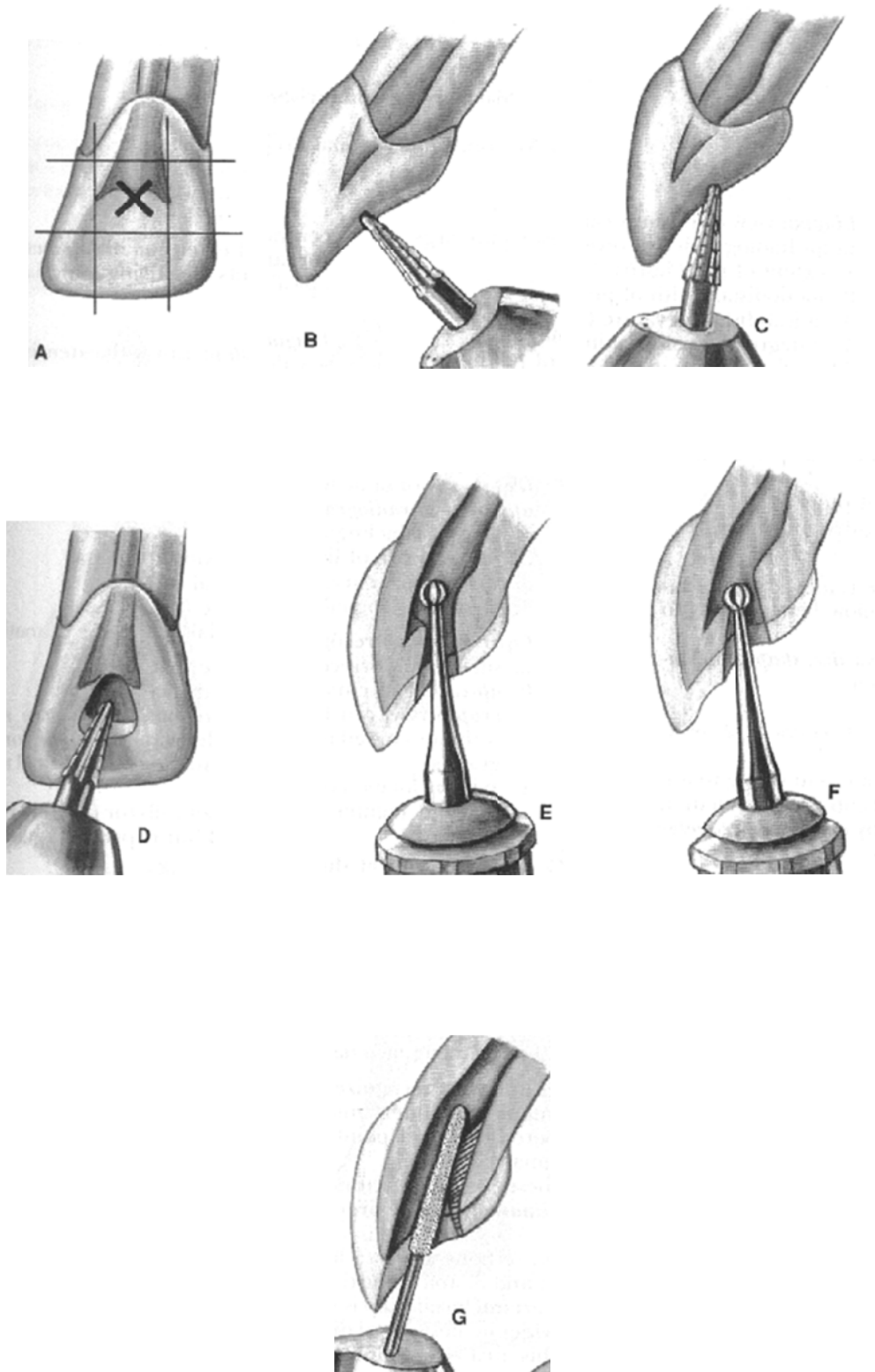
Errors:








Access for Maxillary Anterior teeth

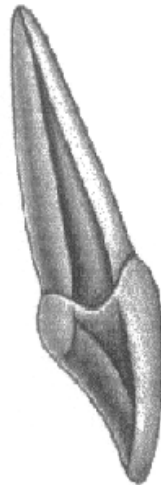


Maxillary Central Incisor

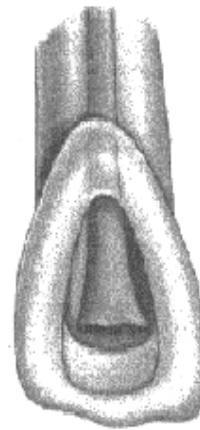
- The shape of the access cavity is triangular with the base of the triangle toward the incisal edge and the apex toward the cingulum.
- The first entry point, with the end-cutting fissure bur is made just above the cingulum in the palatal surface (dropping).
- The direction should be in the long access of the root.
- The access cavity differs from older to younger patients.
- Average tooth length is 22.5mm.
- Always (99.9%) one canal.



Labial View



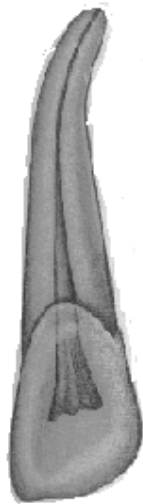
Proximal View



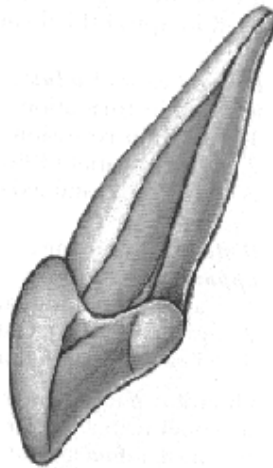
Palatal View

Maxillary Lateral Incisor

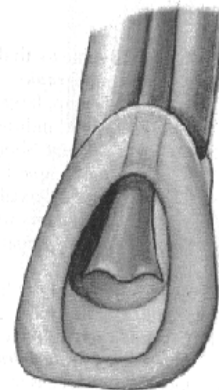
- The shape of the cavity is ovoid.
- The first entry point, with end-cutting fissure bur, is made just above the cingulum in the palatal surface (dropping).
- The direction should be in the long access of the root.
- The access cavity differs from older to younger patients.
- Access could be complicated with presence of dens-in-dente.
- The root is slightly conical and tends toward curvature, usually toward distal, in its apical portion.
- Average length: 22 mm.
- Always (99.9%) one canal.



Labial View



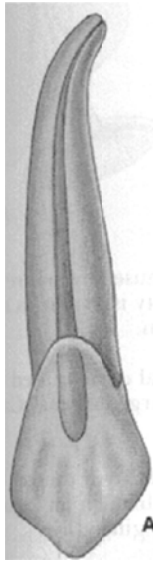
Proximal View



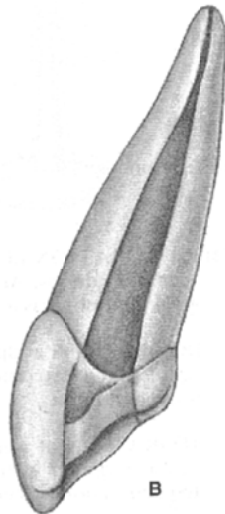
Palatal View

Maxillary Canine

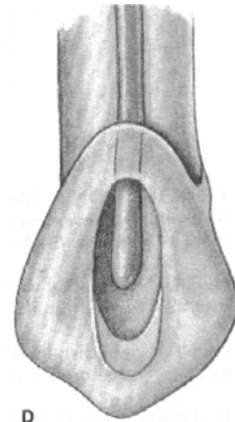
- The shape of the access is ovoid.
- The first entry point, with end-cutting fissure bur, is made slightly below midcrown on the palatal surface (dropping).
- The direction should be in the long access of the root.
- The apex will often curve in the last 2 or 3 mm.
- Average length: 26.5 mm.
- Always (99.9%) one canal.



Labial View

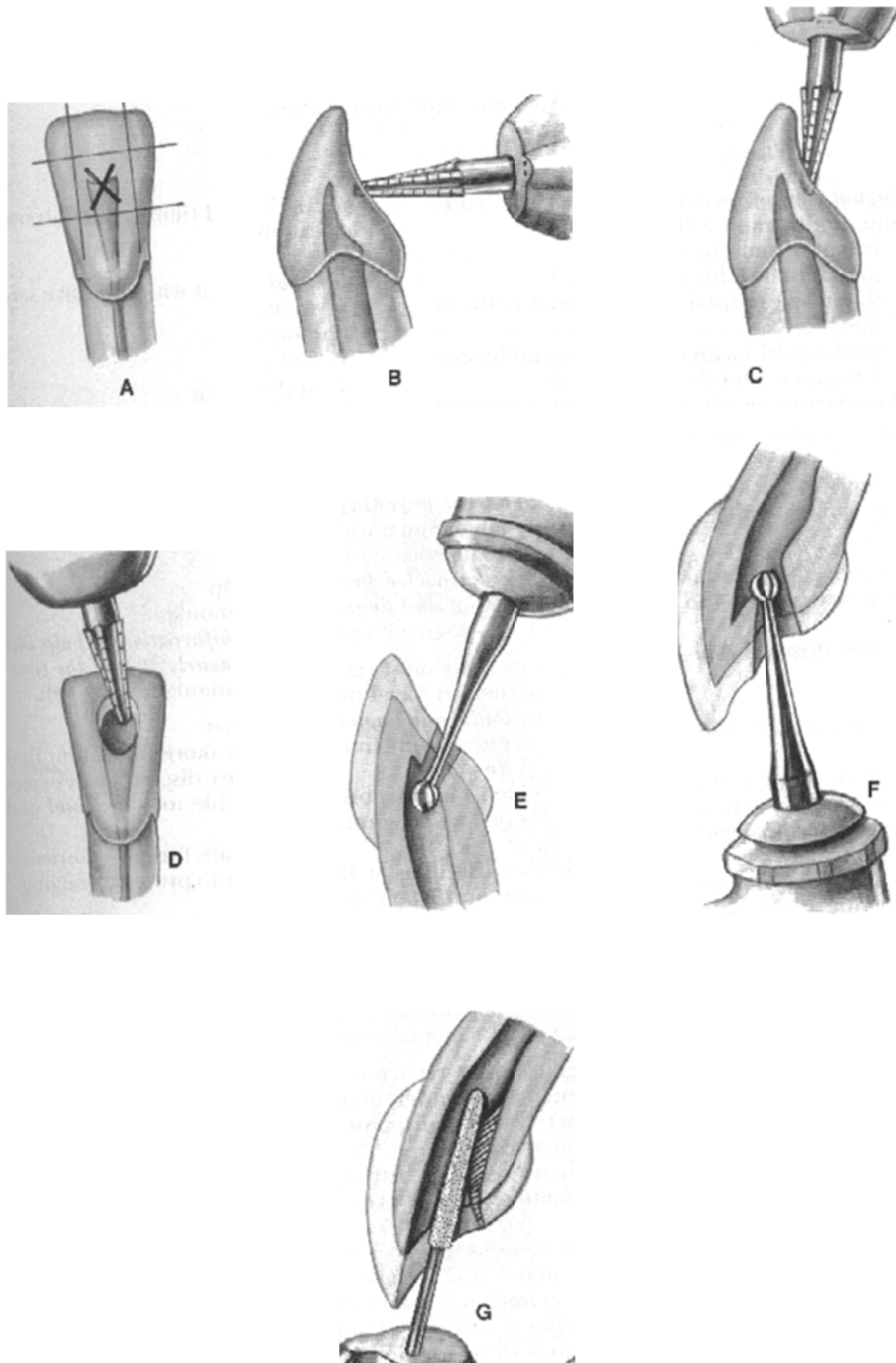


Proximal View



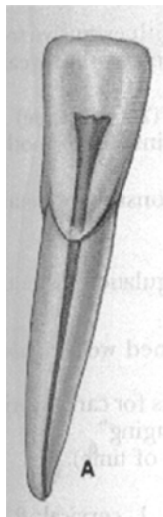
Palatal View

Access for Mandibular Anterior teeth

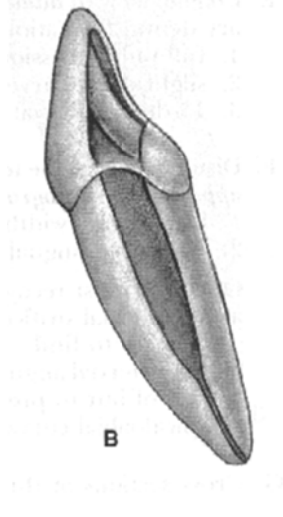


Mandibular Central and Lateral Incisors

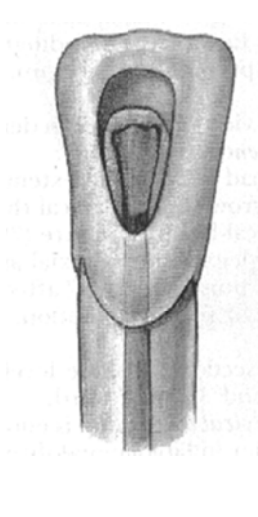
- The shape of the access is ovoid.
- The access cavity is done from the lingual side, with a small fissure bur (dropping).
- The direction should be in the long access of the root.
- Average length: 20.7 mm.
- Frequently (42%) mandibular incisors have 2 canals (Buccal and Lingual).



Labial View



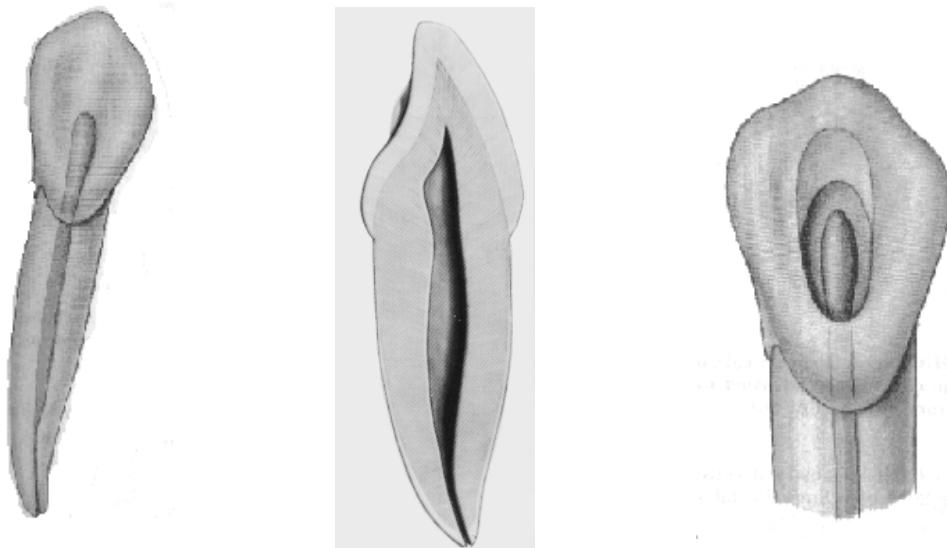
Proximal View



Lingual View

Mandibular Canine

- The shape of the access is ovoid.
- The access cavity is done from the lingual side, with a small fissure bur (dropping).
- The direction should be along the long access of the root.
- Average length: 25.6 mm.
- Frequently mandibular canine has one canal.

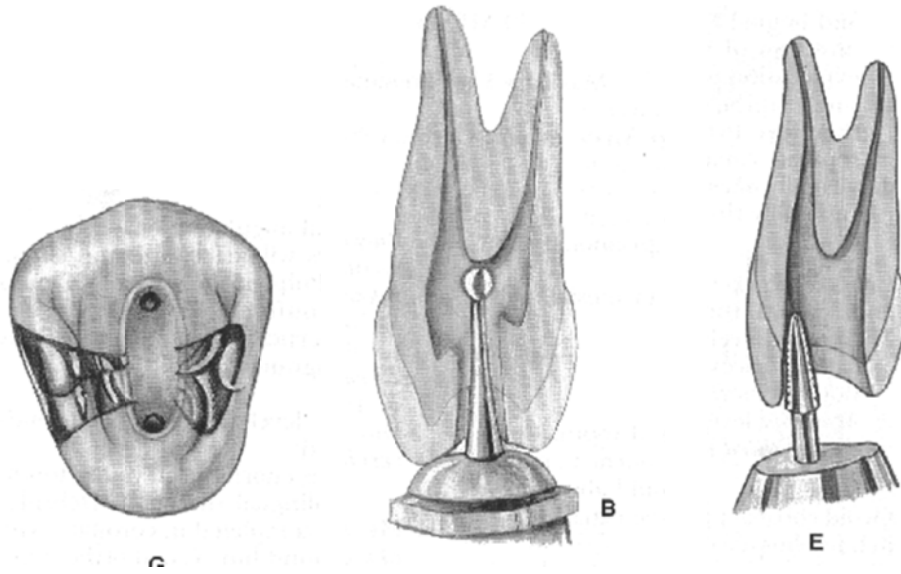


Buccal View

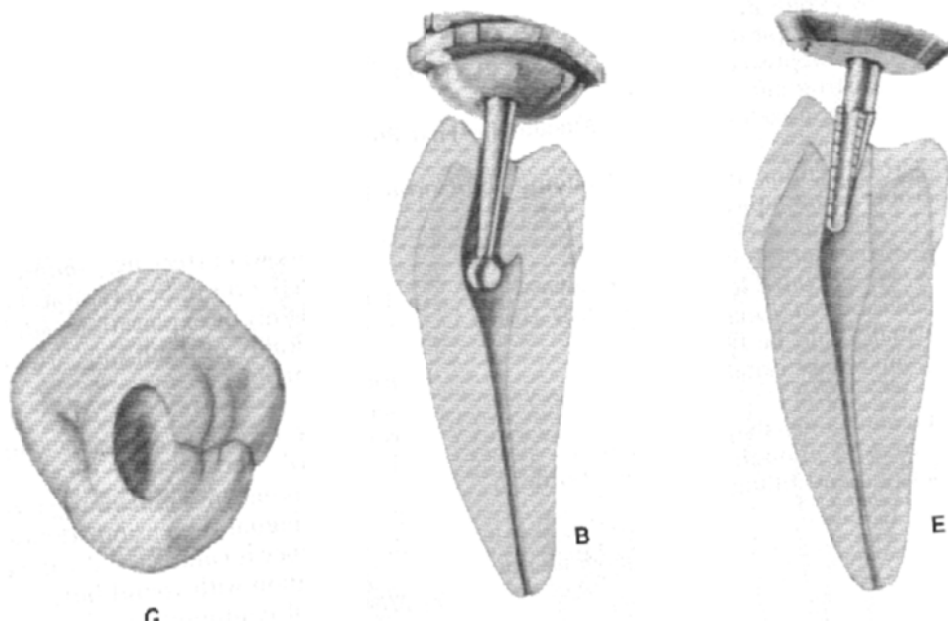
Proximal View

Lingual View

Access for Maxillary Premolar teeth

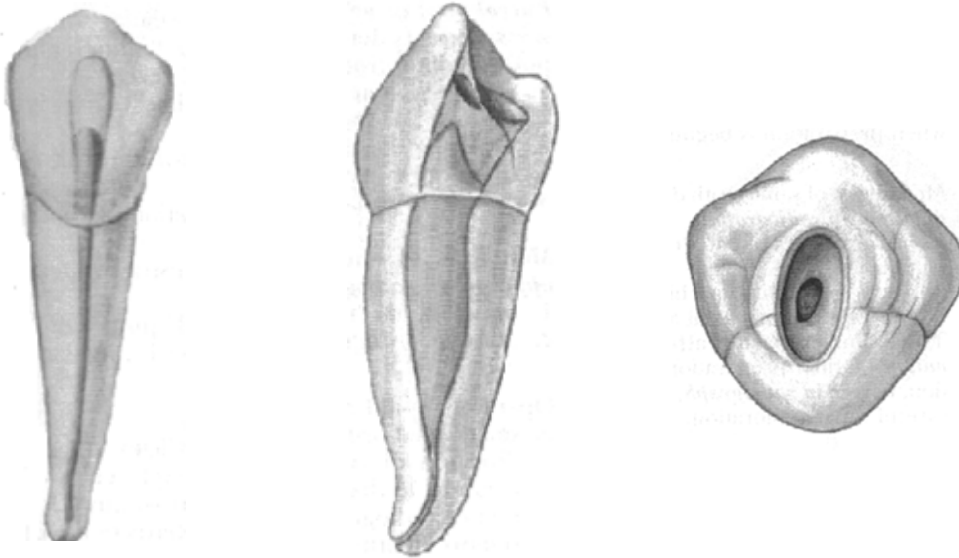


Access for Mandibular Premolar teeth



Mandibular First Premolar

- The shape of the access is ovoid bucco-lingually enough to allow visualization and instrumentation of two canals.
- The direction should be along the long access of the root.
- The canal might have an apical curvature to distal.
- Average length: 22.1 mm.
- One canal (73.5%), two canals with two foramens (19.5%), two canals with one foramen (6.5%), three canals (0.5%).



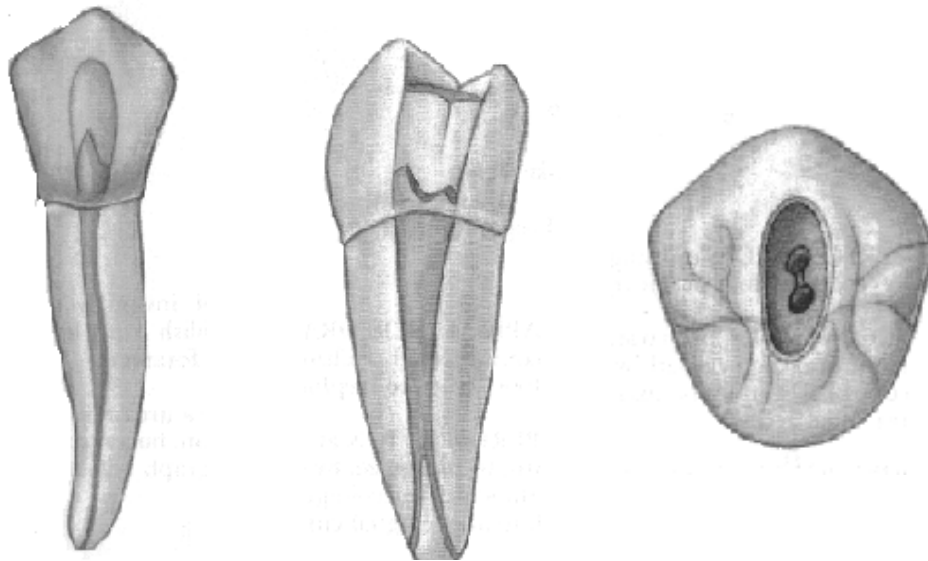
Buccal View

Proximal View

Occlusal View

Mandibular Second premolar

- The shape of the access is ovoid bucco-lingually, slightly skewed to the mesial, enough to allow visualization and instrumentation of two canals.
- The direction should be along the long access of the root.
- The canal might have an apical curvature to distal.
- Average length: 21.4 mm.
- One canal (85.5%), two canals with two foramens (11.5%), two canals with one foramen (1.5%), three canals (0.5%).



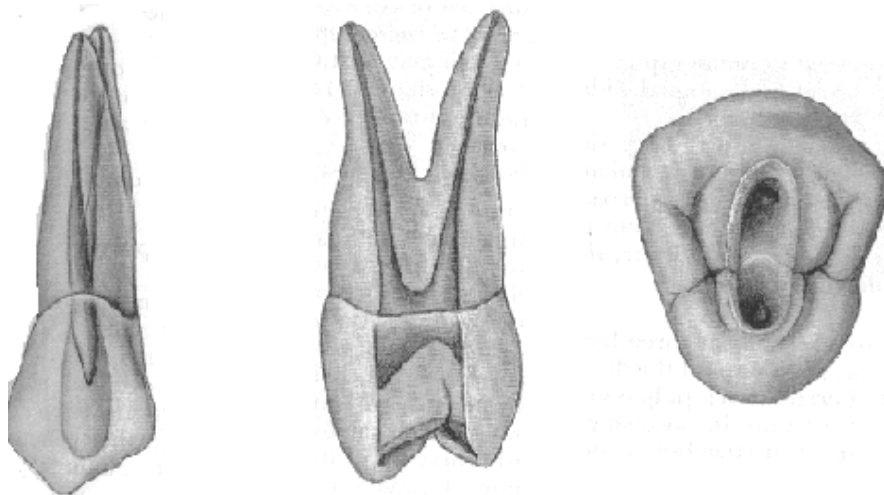
Buccal View

Proximal View

Occlusal View

Maxillary First Premolar

- The shape of the access is ovoid bucco-lingually with more extensive preparation enough to allow visualization and instrumentation of two canals.
- The direction should be along the long access of the root.
- The canal might have an apical curvature to distal.
- Average length: 21.8 mm.
- One canal (9%), two canals with two foramens (72%), two canals with one foramen (13%), three canals (6%).



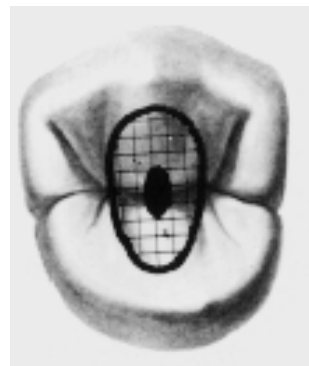
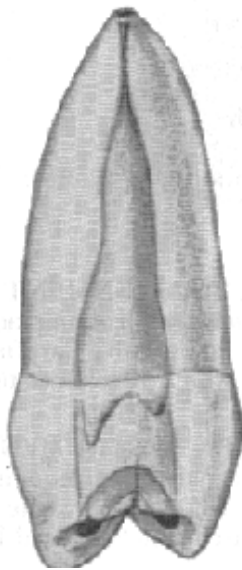

Buccal View

Proximal View

Occlusal View

Maxillary Second Premolar

- The shape of the access is ovoid bucco-lingually skewed well to the mesial enough to allow visualization and instrumentation of two canals.
- The direction should be along the long access of the root.
- The canal most likely has an apical curvature to distal.
- Average length: 21 mm.
- One canal (75%), two canals with two foramens (24%), three canals (1%).



Buccal View

Proximal View

Occlusal View

Session 4

A. Working Length Determination

Definition:

It is to establish the length (distance from the apex) at which canal preparation and subsequent obturation are to be completed.

Purpose:

Optimal length of the canal is established to ensure complete cleaning of the entire canal.

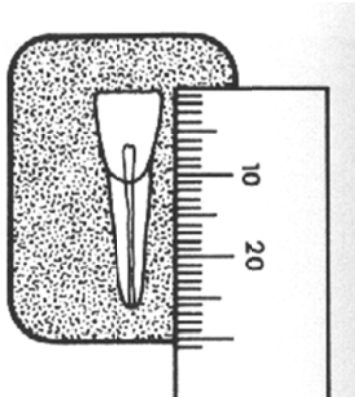
Instruments:

1. Radiograph.
2. Ruler, or measurement device.
3. Endodontic files.

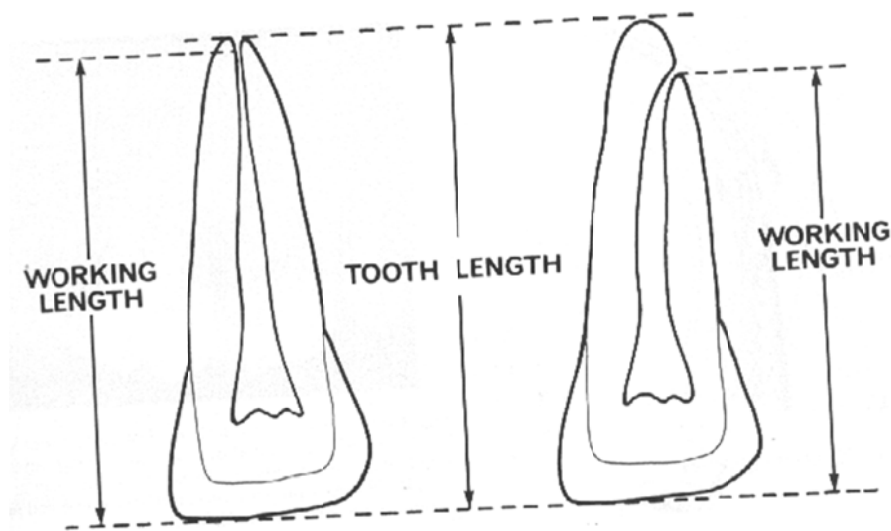
4. Rubber stoppers.

Technique:


1. From your **initial radiograph**, measure the distance from your reference point to the apex.



2. From this mea 0 mm for the **estimated working length**. This 0.5 – 1.0 mm includes:
 - a. The distance between the radiographic apex and the apical constriction.
 - b. The magnification factor of the radiograph.



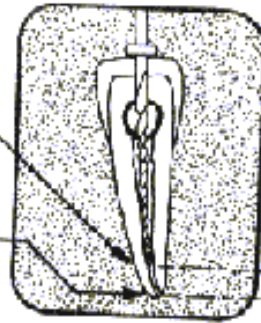
3. Measure a size 10 or 15 file to this estimated working length and place a rubber stopper on your file.



4. Use these files in sequence to enter the canal. The first file that binds (feels tight) at or near the estimated working length will be your **Initial file**. Do not use sizes smaller than 15, because they will not appear clearly on your radiograph.
5. With the file in place at your estimated working length, and the rubber stopper in the correct position (not tilted), expose a radiographic film. This is your **initial working length radiograph**.
6. According to this radiograph, adjust the length of your file. Measure the distance between the tip of your file and the radiographic apex. Your file should be 0.5 mm shorter than the radiographic apex. This is your **working length**.

File at estimated
working length

Radiographic apex



0.5 - 1.0 mm
difference

B. Instrumentation

Definition:

It is the cleaning and shaping the canal using files and other instruments.

Purpose:

The purpose of cleaning the canal is to remove microorganisms, necrotic debris and tissue to reduce the chance of further inflammation and promote healing. The purpose of shaping the canal is to allow the insertion and adaptation of the filling material.

Instruments:

- Endodontic files
- Endodontic spreader

Materials:

- Radiographs & radiographic equipment
- Irrigating syringe and solution
- Alcohol swabs
- Paper points

Technique:

The technique followed in the school is the step-back method (flaring- serial preparation). This technique is:

- Safe to use.
- Creates a smoother flow.
- More tapered technique form apical to coronal.

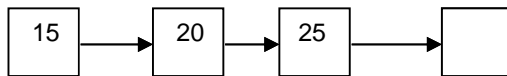
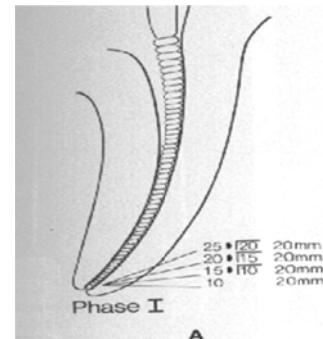
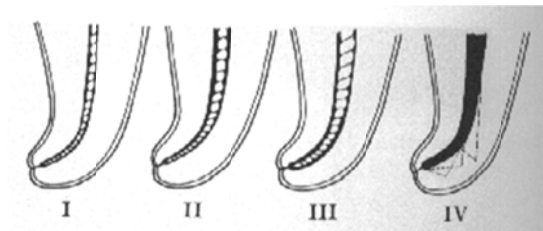
1. Initial Apical Preparation (Phase I):

- After creating a straight-line access, ream or file the first file to bind in the canal three to five sizes larger.

Ex. The first file to bind is #15. File with #15, 20, 25, and #30 files.

This is your **MASTER APICAL FILE (MAF)**.

EXCEPTION: If the canal is very curved do not apically prepare beyond size #25 (WHY?)



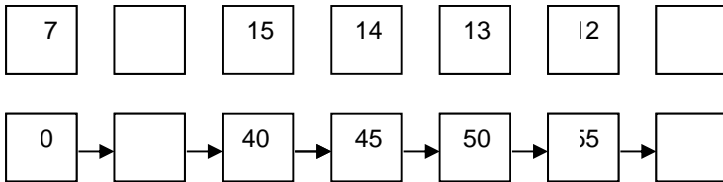
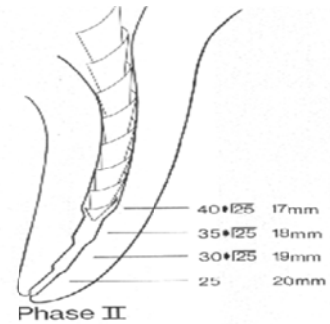
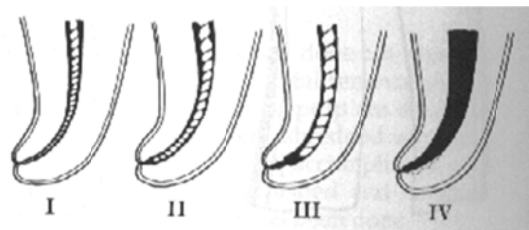
2. MAF Radiograph:

After reaching your MAF, expose a radiograph with the MAF in the canal.

3. Step-back:

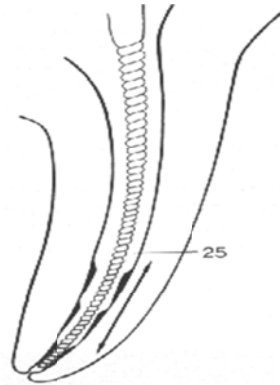
- After reaching your MAF. Consecutively use larger sizes, 1mm shorter than your working length.

Ex. If your WL is 18 mm, and your MAF is #30, your next file should be a size #35 at 17mm, then #40 at 16mm...etc until size #60 or #70.

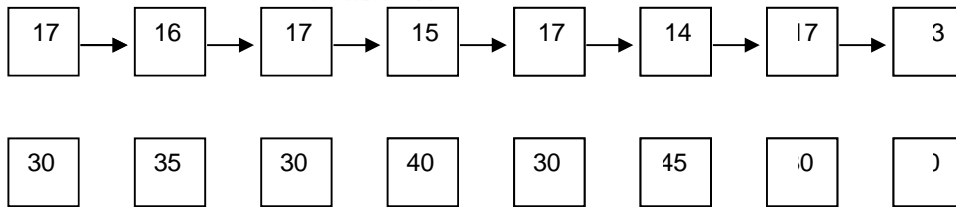


Recapitulation:

- After each step-back file is used, you should insert your MAF to WL. Ex. after filing with #40 at 16mm go back to #30 (MAF) at 18mm (WL), after filing with #45 at 15mm, go back to #30 (MAF) at 18mm (WL). (WHY?)



Refining Phase II - I



Irrigation:

- Using a large disposable syringe, dispense at least 2ml of irrigant after each instrument use. WHY?

Dispense drop by drop. DO NOT FORCE IRRIGANT INTO THE CANAL. WHY?

Cleaning the file:

After each use of the file, wipe it with an alcohol swab. **Do not insert a dirty file into the canal.**

4. Evaluate your Taper:

After step-back, your canal should be tapered enough to accept the filling material. Evaluate your preparation by inserting your spreader into the canal; it should fit loosely within 2 mm of your working length.

5. Drying the canal:

Use a paper point corresponding to the same size MAF, and insert it in the canal to the WL. Keep changing the paper point until it comes out of the canal dry.

Evaluation Criteria:

1. Canal walls are smooth
2. There is adequate taper (spreader)
3. Apical stop
4. The anatomy of the canal is still the same.

Session 5

A. Obturation

Definition:

Filling the prepared root canal with a root-filling material to prevent reinfection of the canal.

Purpose:

To create a fluid-tight seal along the length of the root canal system from the coronal opening to the apical termination.

Instruments:

- Endodontic files
- Glass slab and spatula
- Endodontic spreader
- Endodontic plugger
- Torch and lighter
- Plastic filling instrument.

Materials:

- Standardized gutta-percha cones
- Accessory gutta-percha cones
- Sealer cement
- Paper point

Technique:

The technique used in the school will be the lateral condensation with gutta percha.

1. Master Cone Selection:

Select a master apical cone (MAC) of the same size as your MAF and insert it into the canal. The cone should:

- Reach the full working length.
- Have a tug-back (The cone should fit snugly in the canal and should be slightly resistant to removal).



2. Master Apical Cone (MAC) Radiograph:

After completing your step-back expose a radiograph with your MAC in the canal.

- If the MAC is too short (underextended)--> Reinstrument the canal, and repeat your step-back. Are you sure you checked your taper?
- If the MAC is too long (overextended)--> You have overinstrumented the canal and the apical foramen has been violated. To remedy this you need to:
 1. Try to create another apical seat by filing with a larger file shorter than your current working length. This is done by selecting the file that will bind at the new estimated location

of your apical termination and then filing one or two sizes larger.

2. Use a larger size MAC (ex. Your MAC is #30, use a #35, #40 , etc. until you have tug back at the new working length).
3. Cut your MAC (with a blade) 1mm from the apical end.
WHY?

3. Obturation:

Mix the sealer cement (AH26): Add 2 drops of liquid to 2 scoops of powder and mix on a glass slab to reach a smooth consistency (Note: You should do this step with one or more friends, so you will share the sealer and not waste it, however, each student should have his own portion of the sealer on his glass slab, never share the same glass slab)

Apply the sealer to the canal with the MAF after cleaning it from debris. Coat the canal walls thoroughly. WHY?

Reinsert and fit the MAC, make sure that you mark your MAC at your working length (with a pen or pinching it with your pliers) and make sure that this mark does not go below your reference point during the whole obturation procedure to avoid overfilling the canal.

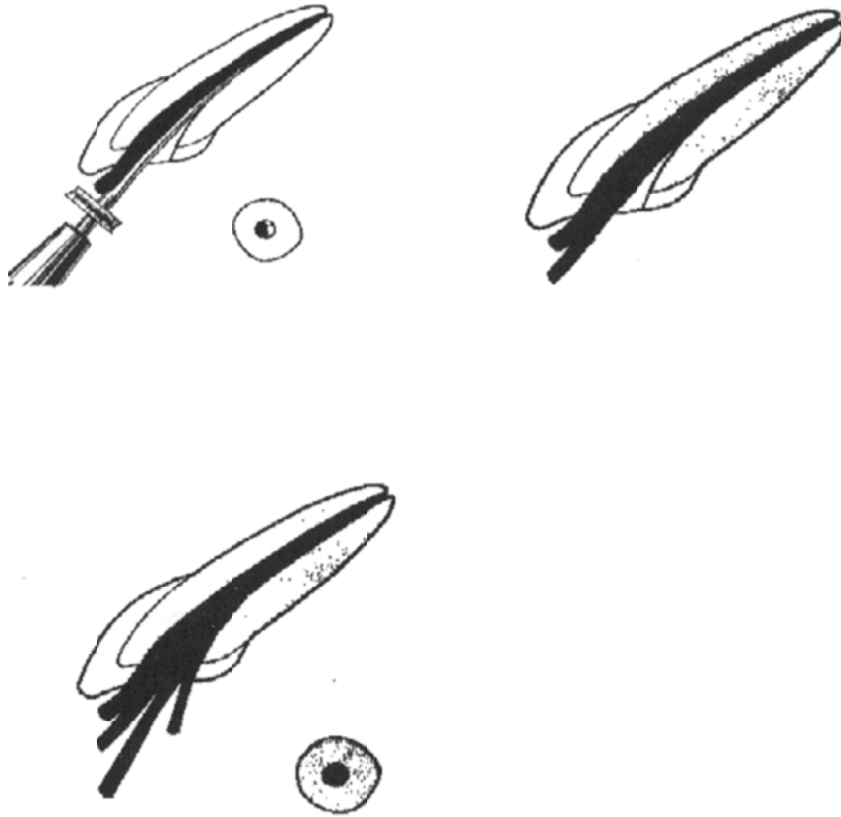
Insert the spreader to the full WL minus 1 mm between the MAC and the canal wall. Use firm pressure in the apical direction to create space for the accessory cones.

Rotate the spreader back and forth around its axis and remove it. Immediately insert an accessory cone coated with sealer in the space created. Make sure you measure and mark (like with MAC) the first two accessory cones at your working length. To avoid overextension, make sure that the mark on the accessory cone does not go beyond your reference point.

4. Intermediate Radiograph:

After inserting two accessory cones, expose a radiograph with your MAC and accessories in the canal. WHY?

Repeat the lateral condensation and insert accessory cones until your spreader cannot go more than 2 mm below the canal orifice. (The location of the canal orifice can be determined by measuring the distance on the labial side between the incisal edge and the CEJ). Your last procedure should be inserting an accessory cone. WHY?



Use a heated instrument and cut the excess Gutta percha to just below the CEJ. WHY?



percha
(CEJ)

Vertically condense the gutta-percha gently into the canal orifice using an endodontic plugger.

Clean the pulp chamber from excess sealer. Use a cotton pellet soaked in alcohol. WHY?

5. Final Radiograph:

Expose a final radiograph after placing a temporary restoration in the access.

Evaluation Criteria:

1. The obturation should show no voids on the radiograph.
2. The obturation should be of a good density.
3. The length of the obturation should be adequate.
4. The obturation should duplicate the canal shape.

B. Temporization

Definition:

It is the placement of a temporary restoration between endodontic appointments or after the obturation till the time of final restoration.

Purpose:

Temporization is done inter-appointment to prevent contamination of the canal from the oral cavity between appointments. It is performed after obturation to coronally seal the canal and protect the remaining tooth structure.

Instruments:


- Glass slab and spatula
- Plastic filling instrument

Material:

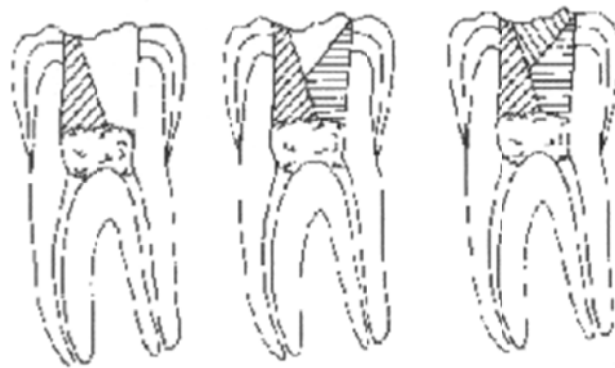
- Temporary restorative material (such as IRM or Cavit).
- Cotton pellets

Technique:

- Between appointments, a small cotton pellet should be placed over the canal orifices and a temporary restoration (IRM or Cavit) should be mixed and placed in the pulp chamber.
- After obturation, the temporary restoration should be placed without a cotton pellet underneath (Why?).



- In both cases, the access cavity should be packed with IRM or Cavit using a plastic instrument. The restoration should be placed in increments from the bottom up and should be pressed into the undercuts and cavity walls.



- Excess material should be removed (Be careful a high restoration is VERY PAINFUL). The surface should be smoothed with a moist cotton pellet.

3. Discuss the problems you faced during your access, working length determination, and instrumentation. Mention how they might have occurred and how you could have avoided the problem. Discuss your options in correcting the problem.

Session 7

Obturation and Temporization of 2nd anterior tooth

Discuss the problems you might have faced during obturation, how they may have occurred, and how you could have avoided these problems.

Session 8

Access, working length determination and instrumentation on the 3rd anterior tooth

Introduction of gates glidden

1. Draw the crown of the tooth you will be working on, and draw the outline of the access opening.

Use of Gates Glidden drills in preparation

Gates Glidden drills are sometimes used with the stepback technique as well as other techniques to prepare the radicular access and the coronal third of the canal.

Use of Gates Glidden Drills has many benefits, it is fast, minimizes zipping, and facilitates easier instrumentation because of straighter canals. However GG drills also have disadvantages such as its potential to create perforations in inexperienced hands.

Larger GG (4,5,6) should be used in the orifice only. Size 2,3,4 can be used in the coronal third of the canal. Do not exceed the coronal third of the canal.

2. Determine your working length, and your MAF.

3. Discuss the problems you faced during your access, working length determination, and instrumentation. Mention how they might have occurred and how you could have avoided the problem. Discuss your options in correcting the problem.

Session 9

Obturation and Temporization of 3rd anterior tooth

Discuss the problems you might have faced during obturation, how they may have occurred, and how you could have avoided these problems.

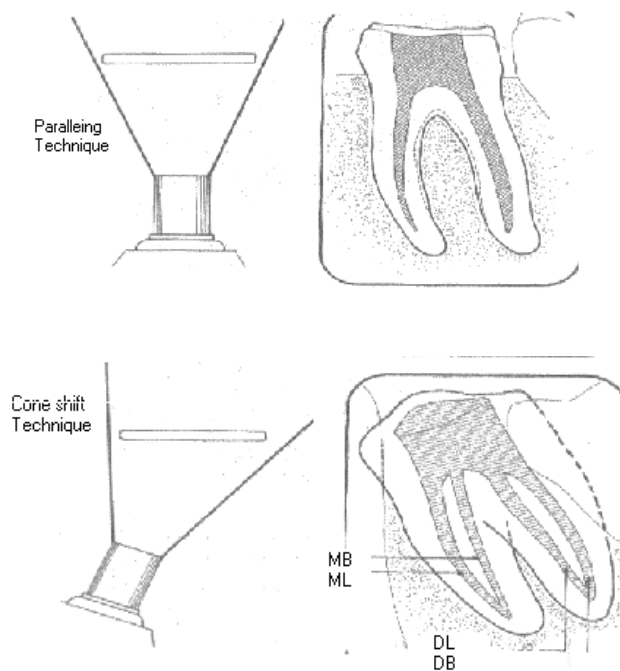
Session 10

A. Endodontic Radiography

Buccal Object Rule

- For the posterior teeth (premolars and molars) cone shift technique will be used. Other names for this procedure are the buccal object rule, Clark's rule and the SLOB (same lingual opposite buccal) rule.

The principle of this technique states that the object closest to the buccal surface appears to move in the direction opposite the movement of the cone, while objects closest to the lingual surface appears to move in the same direction that the cone moved. (If the canal moves with or in the same direction as the cone head, the canal is lingually located in the root).



**B. Access, working length determination and
instrumentation on the 1st Premolar tooth
(Two canals)**

1. Draw the crown of the tooth you will be working on, and draw the outline of the access opening.

2. Determine your working length, and your MAF.

3. Discuss the problems you faced during your access, working length determination, and instrumentation. Mention how they might have occurred and how you could have avoided the problem. Discuss your options in correcting the problem.

Session 11

Obturation and Temporization of the 1st Premolar tooth

(Two canals)

Discuss the problems you might have faced during obturation, how they may have occurred, and how you could have avoided these problems.

Session 13

Access, working length determination and instrumentation on the 2nd premolar tooth (One canal)

1. Draw the crown of the tooth you will be working on, and draw an outline of the access opening.

2. Determine your working length, and your MAF.

3. Discuss the problems you faced during your access, working length determination, and instrumentation. Mention how they might have occurred and how you could have avoided the problem. Discuss your options in correcting the problem.

Session 14

Obturation and Temporization of the 2nd premolar tooth

(One canal)

Discuss the problems you might have faced during obturation, how they may have occurred, and how you could have avoided these problems.

PART TWO

Session 1

Teeth Selection

- Molars selected should follow the same guidelines for all teeth selection (review teeth selection section in part 1).

- A total of 7 molars are required:-

Two for the access cavity preparation exercises.

Three for endodontic therapy exercises.

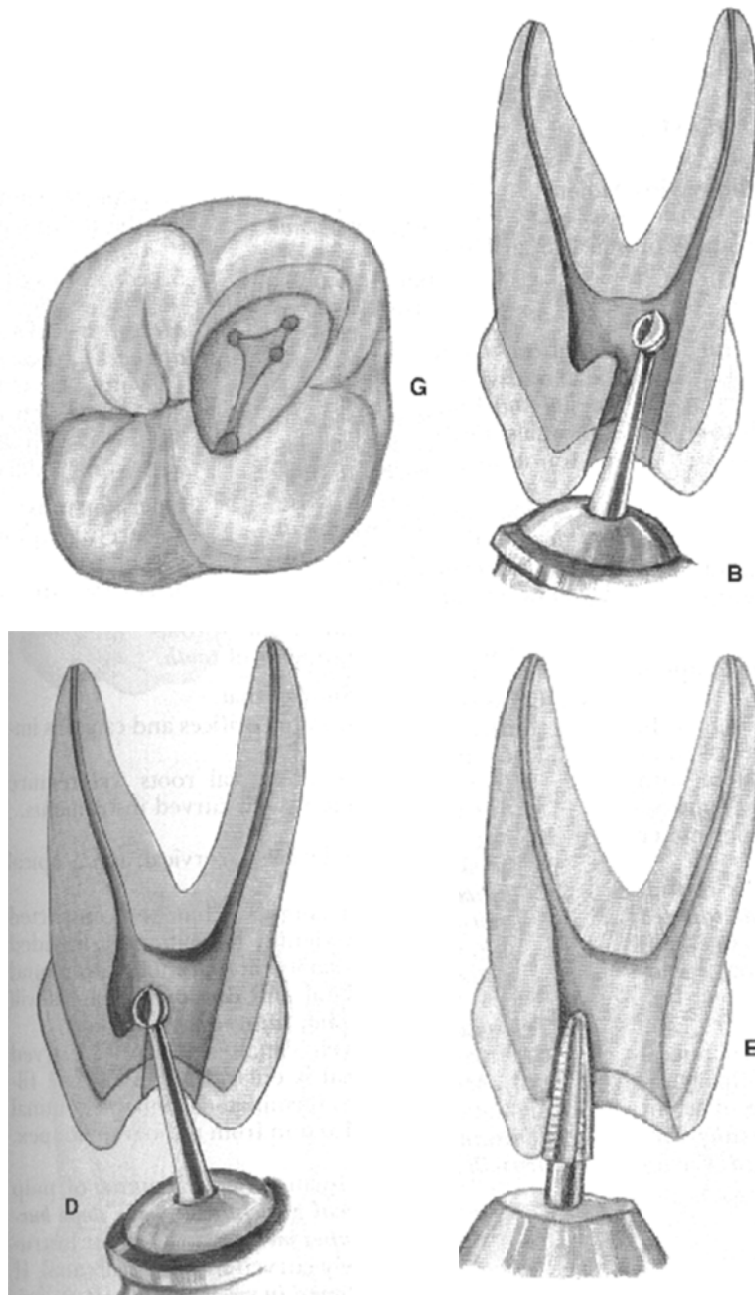
One for the access cavity preparation Assessment.

One for the Final Exam.

Session 2
Access Cavity
Preparation for
Molars

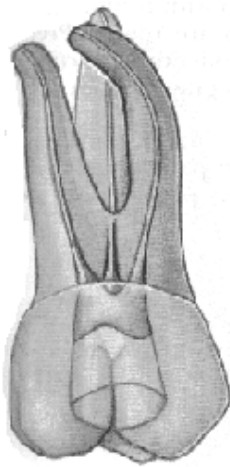
Access Cavity Preparation for Maxillary Molars

- Straight-line access is evaluated with files, which should not be deflected by the tooth structure. The straighter the approach of the file in the curved canal, the less the probability of preparation error in the apical region.

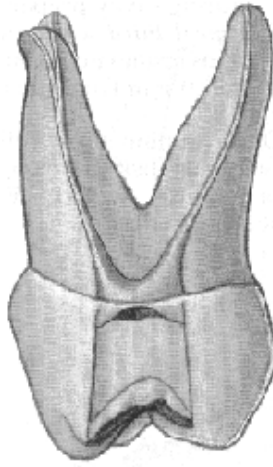


Access Cavity for Maxillary 1st Molar

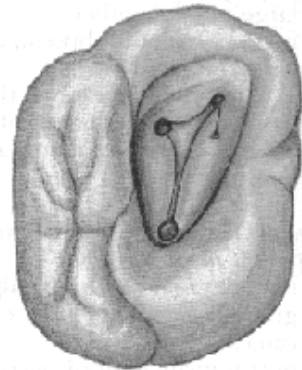
- The shape of the access cavity is triangular, with the base towards the buccal and the apex to the lingual. Entirely in the mesial half of the tooth.
- Buccal and lingual walls of the cavity slope buccally.
- Average length: 19.9mm (buccal canals), 20.6mm (palatal canal).
- Four canals (56.5%), three canals (41.1%), five canals (2.4%).



Buccal View



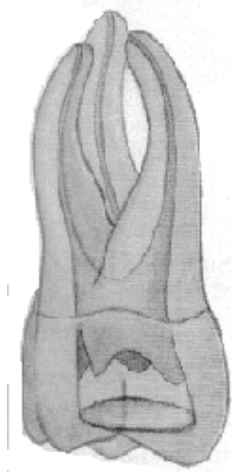Proximal View



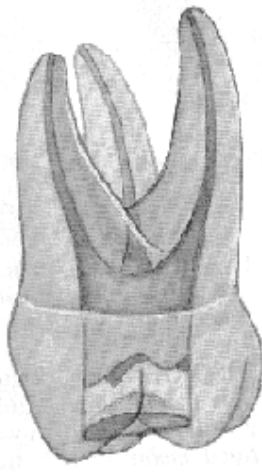
Occlusal View

Access Cavity for Maxillary 2nd Molar

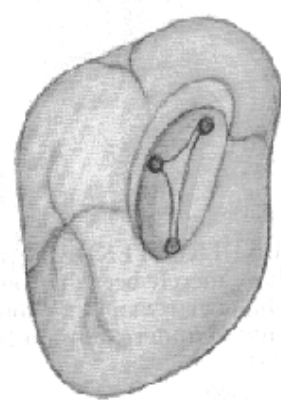
- The shape of the access cavity is a flattened triangular shape, with the base towards the buccal and the apex to the lingual. Entirely in the mesial half of the tooth.
- Entire cavity slopes buccally.
- Average length: 20 mm (buccal canals), 20.8 mm (palatal canal).
- Three canals (54%), fused (46%).



Buccal view

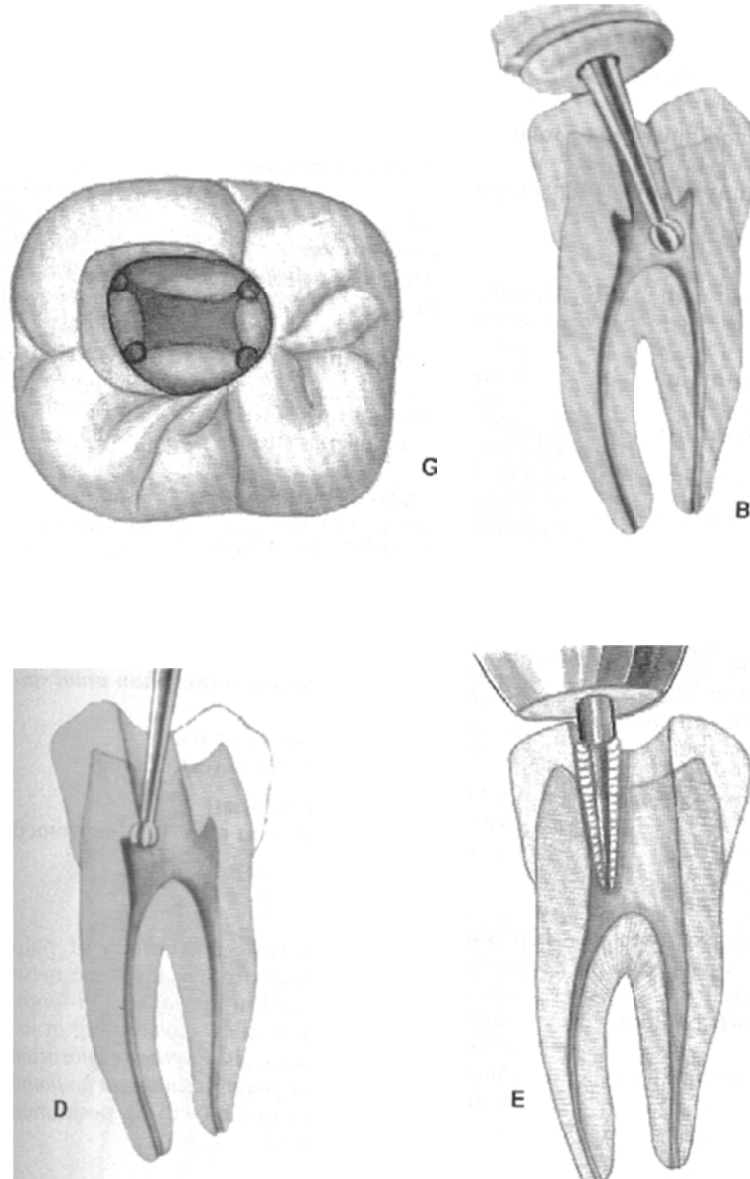


Proximal view



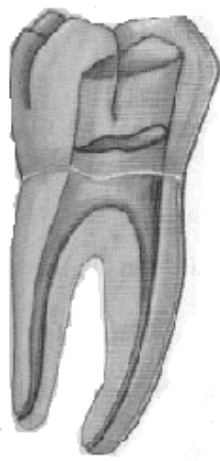
Occlusal view

Access Cavity Preparation for Mandibular Molars

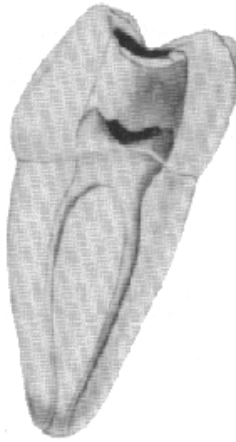


Access Cavity for Mandibular 1st Molar

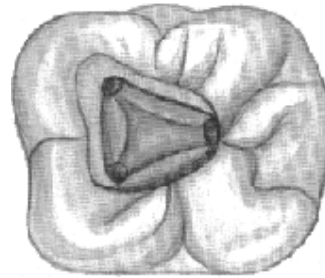
- The shape of the access cavity is triangular, with the base towards the mesial and the apex to the distal.
- Cavity is primarily in the mesial half of the tooth.
- Average length: 20.9mm.
- Three canals (64.4%), four canals (28.9%), two canals (6.7%).



Buccal view



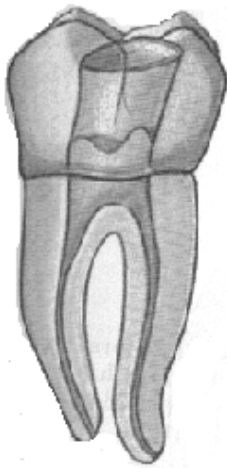
Proximal view



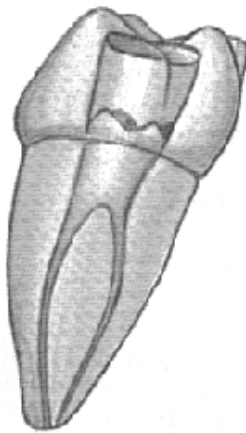
Occlusal view

Access Cavity for Mandibular 2nd Molar

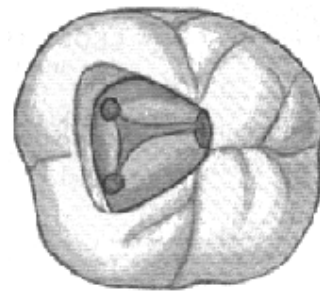
- The shape of the access cavity is triangular, with the base towards the mesial and the apex to the distal. Occasionally rhomboid shape.
- Cavity primarily in the mesial half of the tooth.
- Average length: 20.9mm.
- Two canals with one foramen (49%), two canals with two foramen (38%).



Buccal view



Proximal view



Occlusal view

Session 3

Access Cavity Preparation and working length determination of Molar #1

- Optimal working length is 0.5 – 1.0 mm short of the apex,
- In multicaled teeth, instruments are usually placed in all canals at the same time.
- A mesial angulation for the radiograph exposure is needed to visualize the canals in multi-rooted teeth, except in some maxillary molars that have only 3 canals where a straight approach might be used.

1. Draw the crown of the tooth you will be working on, and draw an outline of the access opening.

2. Determine your working length, and your MAF.

3. Discuss the problems you faced during your access, and working length determination. Mention how they might have occurred and how you could have avoided the problem. Discuss your options in correcting the problem.

Session 4

Instrumentation of Molar #1

Discuss the problems you might have faced during instrumentation, how they may have occurred, and how you could have avoided these problems.

Session 5

Obturation and Temporization of Molar #1

Discuss the problems you might have faced during obturation, how they may have occurred, and how you could have avoided these problems.

Session 6

Access Cavity Preparation and working length determination of Molar #2

1. Draw the crown of the tooth you will be working on, and draw an outline of the access opening.

2. Determine your working length, and your MAF.

3. Discuss the problems you faced during your access, and working length determination. Mention how they might have occurred and how you could have avoided the problem. Discuss your options in correcting the problem.

Session 7

Instrumentation of Molar #2

Discuss the problems you might have faced during instrumentation, how they may have occurred, and how you could have avoided these problems.

Session 8

Obturation and Temporization of Molar #2

Discuss the problems you might have faced during obturation, how they may have occurred, and how you could have avoided these problems.

Session 10

Access Cavity Preparation and working length determination of Molar #3

1. Draw the crown of the tooth you will be working on, and draw an outline of the access opening.

2. Determine your working length, and your MAF.

3. Discuss the problems you faced during your access, and working length determination. Mention how they might have occurred and how you could have avoided the problem. Discuss your options in correcting the problem.

Session 11

Instrumentation of Molar #3

Discuss the problems you might have faced during instrumentation, how they may have occurred, and how you could have avoided these problems.

Session 12

Instrumentation, Obturation and Temporization of Molar

#3

Discuss the problems you might have faced during instrumentation and obturation, how they may have occurred, and how you could have avoided these problems.

Session 13

A. Post Space Preparation

In determining where to place the post, what are the principles for choosing which:

1. Root

2. Post size

3. Post depth

Steps in Post Space Preparation:

1. Place a rubber stopper on a plugger to the length of desired post space. Heat the plugger and rapidly place and remove the plugger until you reach the desired depth.
2. Compact the remaining Gutta percha vertically.
3. Expose a radiograph to verify the amount of remaining gutta percha.

B. Retreatment

Definition

Endodontic retreatment is a procedure performed on a tooth that has received inadequate treatment resulting in a condition requiring further endodontic treatment to achieve a successful result.

Instruments:

- Endodontic file
- Hedstrom file
- Endodontic plugger
- Torch and lighter

Materials:

- Chloroform
- 1ml/cc syringe
- Irrigating solution
- Paper points
- Radiograph & radiographic equipments
- Alcohol swabs

Technique

Removal of the gutta-percha depends on the quality of the filling:

- **If the gutta-percha filling is defective** (poorly condensed), it may be lifted out by the blades of a file, or possibly, with 2 Hedstrom files that are engaged between the canal wall and the gutta-percha filling and then the gutta-perch is retrieved in one piece by pulling back the instrument.

- **If the filling is solid**

- 1- Remove the coronal portion of gutta-perch by hot plugger in order to provide reservoir for the solvent “**chloroform**” that will be used to dissolve the remaining gutta-percha.
- 2- Estimate the working length of treated tooth from the preoperative radiograph and should be confirmed radiographically during instrumentation of the canal.
- 3- Dispense **ONE** drop of chloroform into the coronal part of the canal, leave it for a few seconds, then with large files (e.g. # 30k) remove the gutta-percha high in the canal and decrease the size of the file as you moved toward the apex.
- 4- Use an irrigant in between, and repeat step (3) until all the gutta-percha is removed.
- 5- After the bulk of the old filling removed, circumferential filling is done to remove all the gutta-percha and sealer form the walls.
- 6- Expose a radiograph to ensure complete removal of gutta-percha.

- Extrusion of solvent into periapical tissues should be prevented (**WHY?**).

C. Ca(OH)₂ Application

- Calcium hydroxide is placed in the canal between appointments as an intra-canal medicaments.
- It is available in many forms and combinations and it has many different actions.
- It is a white, odorless powder with the formula Ca(OH)₂
- It has a high pH (about 12.5-12.8).
- Calcium hydroxide can be mixed with a suitable vehicle at the chairside or available as a proprietary paste (e.g. Calasept and Pulpdent).

Advantages of Ca(OH)₂

- It has anti-microbial effect that allows natural healing to occur without infectious irritation.
- When Ca(OH)₂ paste is packed well in the root canal, it decreases the space available for tissue fluid to enter the pulp space and thereby to provide nutrients for residual bacterial cells.
- The high pH of Ca(OH)₂ is responsible for the destructive effect on bacterial cell membrane and protein structures.
- It has a long shelf life.
- Its low solubility makes it act as a slow release system within the root canal.

Instruments:

- Endodontic files
- Lentulo spirals

- Messin-gun
- Glass slab and spatula
- Endodontic plugger

Materials:

- Calcium hydroxide
- Saline
- Barium sulfate
- Paper points
- Radiograph & radiographic equipments
- Alcohol swabs

Technique

- Mix Ca(OH)_2 powder with the liquid (sterile water, distilled H_2O , saline or anesthetic solution) on a sterile glass slab using a sterile spatula until the desired consistency is achieved.
- Barium sulfate can be added to the Ca(OH)_2 powder to improve the radiopacity (7 portions calcium hydroxide to 1 portion barium sulfate)
- Apply the paste to the root canal with either messin-gune, endodontic file (anti-clockwise), or lentulospiral (clockwise).
- Dried with coarse absorbent points, and packed with appropriately sized root canal pluggers. Often this procedure has to be repeated to give a dense fill.
- Expose a radiograph to ensure complete filling of the canal with the calcium hydroxide.

Thank you

The Manual was Prepared By

Dr. Ebtissam Al-Madi

Dr. Hanan Balto

Revised and Finalized:

Dr.Solaiman Al-Hadlaq, B.D.S.,M.S., Ph.D