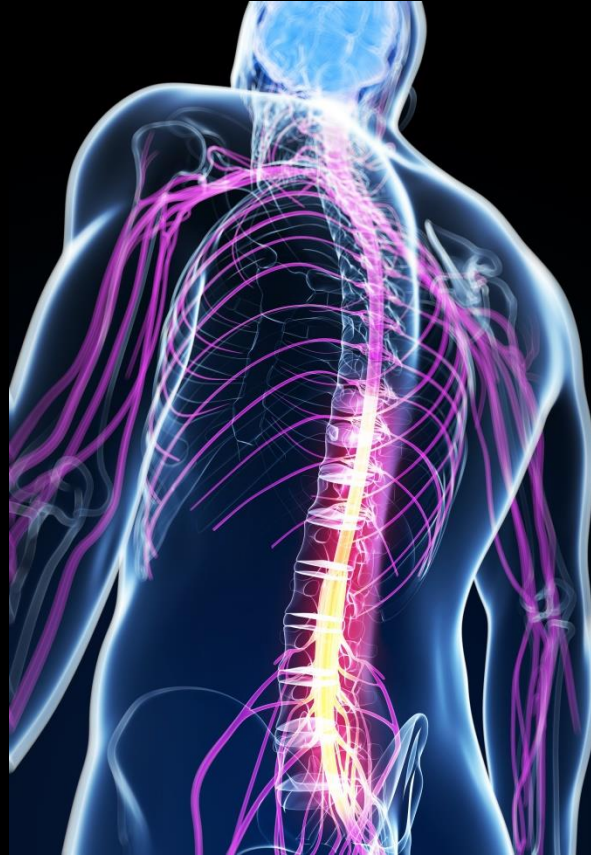

ANATOMY OF SPINAL CORD



Khaleel Alyahya, PhD, MEd
King Saud University
School of Medicine
@khaleelya

OBJECTIVES

At the end of the lecture, students should be able to:

- ✓ Describe the external anatomy of the spinal cord.
- ✓ Describe the internal anatomy of the spinal cord.
- ✓ Describe the spinal nerves: formation, branches and distribution via plexuses.
- ✓ Define Dermatome and describe its significance.
- ✓ Describe the meninges of the spinal cord.
- ✓ Define a reflex and reflex arc, and describe the components of the reflex arc.

REVIEW

FUNCTIONS

The nervous system has 3 functions:

➤ **Collection of Sensory Input**

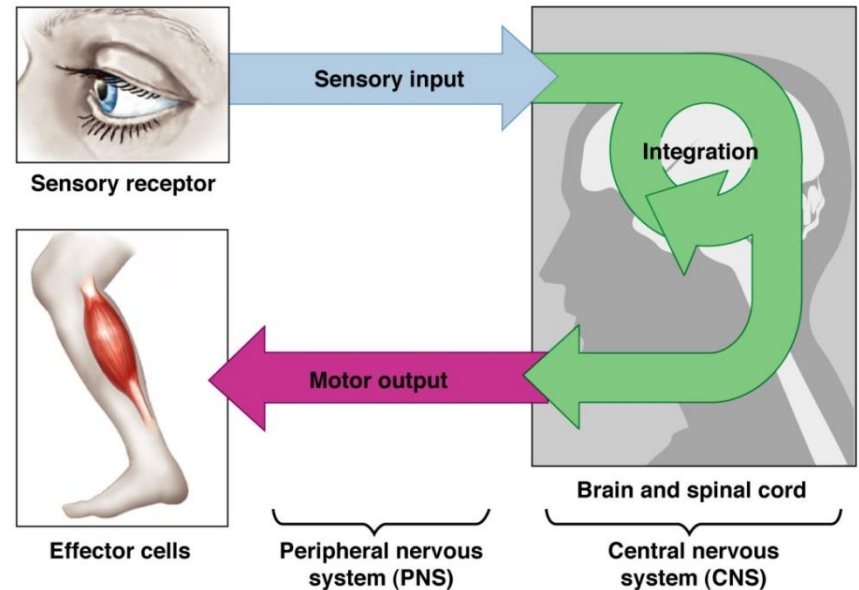
- ✓ Identifies changes occurring inside and outside the body by using sensory receptors. These changes are called stimuli

➤ **Integration**

- ✓ Processes, analyses & interprets these changes and makes decisions

➤ **Motor Output**

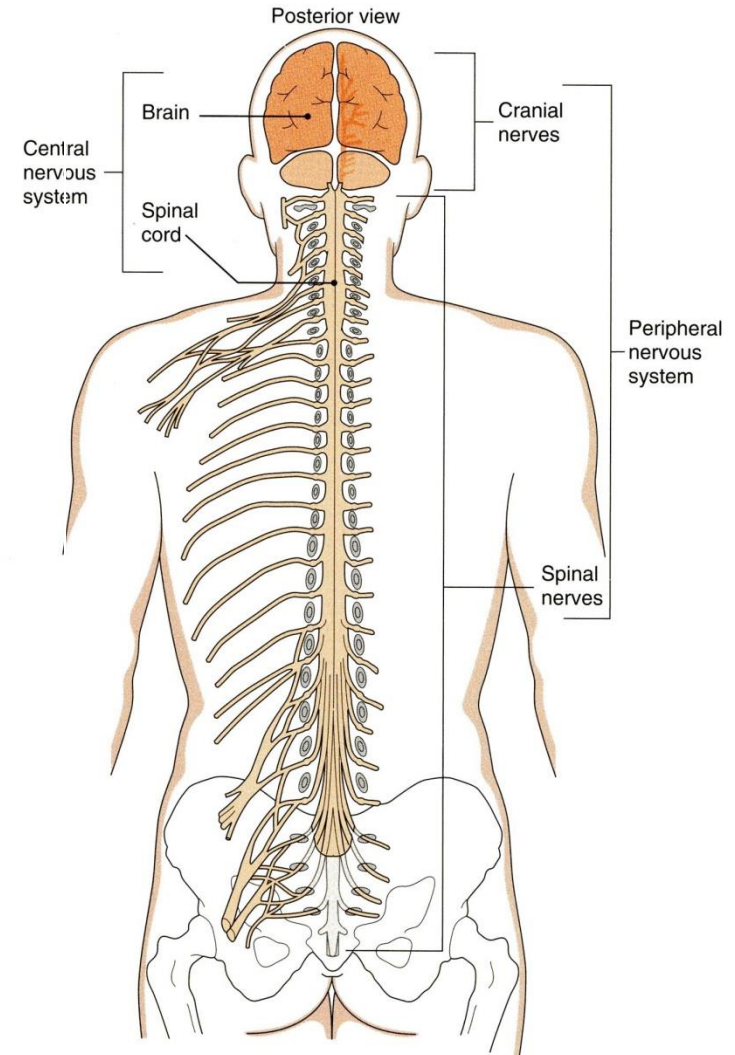
- ✓ It then effects a response by activating muscles or glands (effectors) via motor output



ORGANIZATION

STRUCTURAL

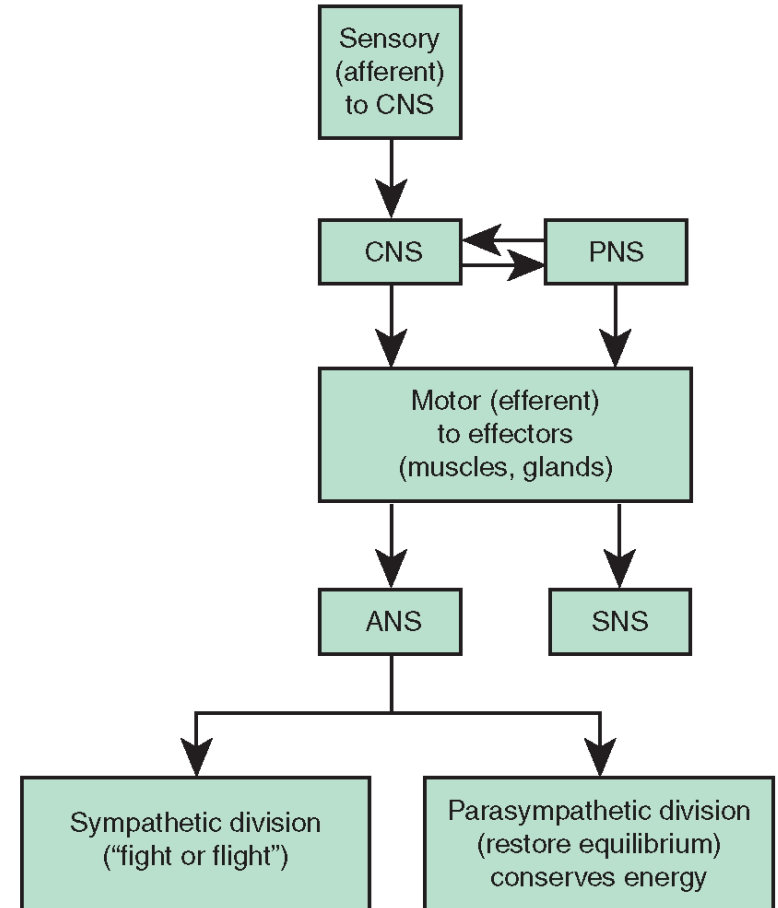
- Central Nervous System (CNS)
 - Brain & Spinal Cord
- Peripheral Nervous System (PNS)
 - Nerves & Ganglia
 - Cranial nerves
 - Spinal nerves



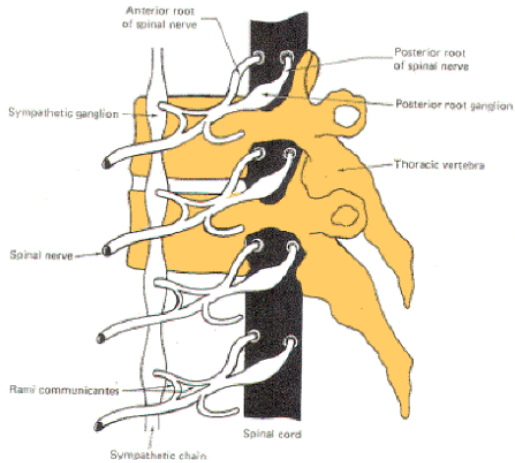
ORGANIZATION

FUNCTIONAL

- Sensory Division (Afferent)
- Motor Division (Efferent)
 - Autonomic
 - Somatic

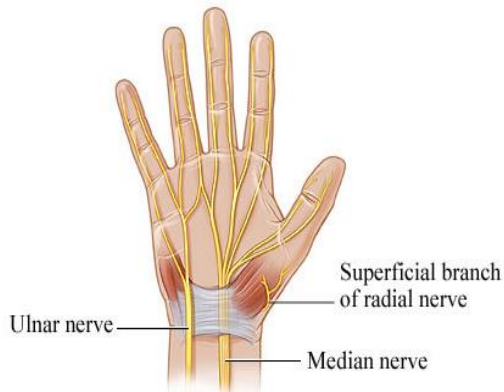


CNS = Central nervous system
PNS = Peripheral nervous system
ANS = Autonomic nervous system
SNS = Somatic nervous system



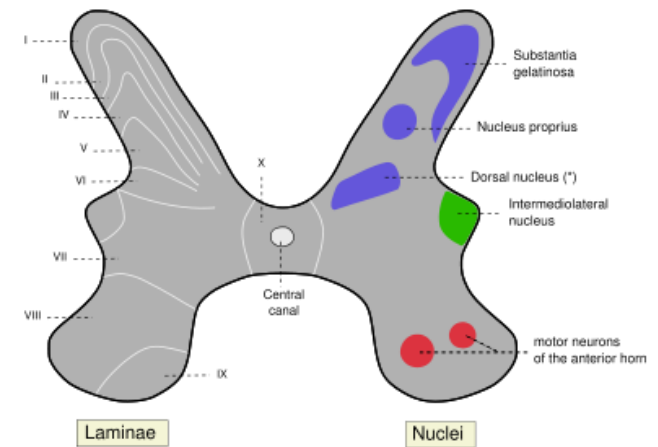
Ganglion

A group of neurons outside the CNS



Nerve

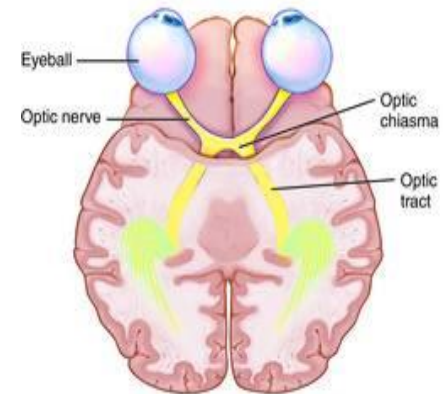
A group of nerve fibers (axons) outside the CNS



* Posterior thoracic nucleus or Column of Clarke

Nucleus

A group of neurons within the CNS

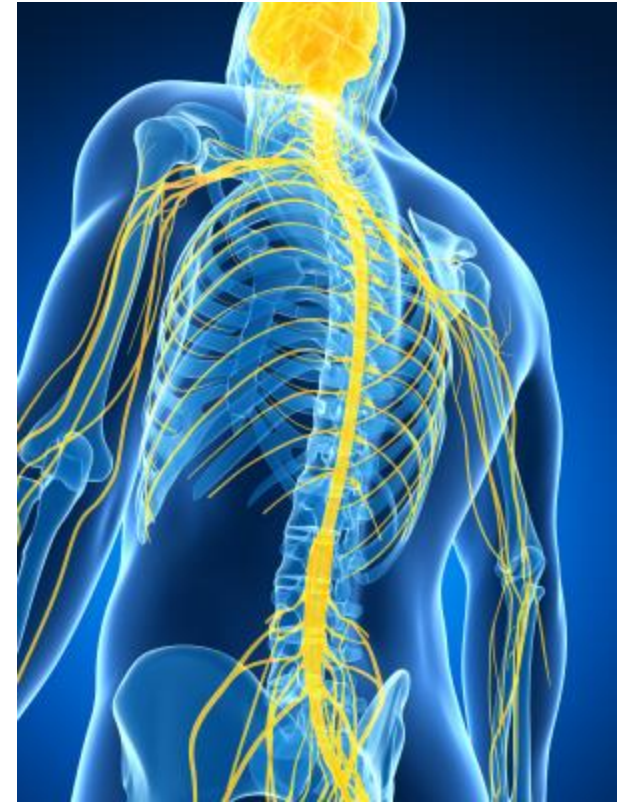

Tract

A group of nerve fibers (axons) within the CNS

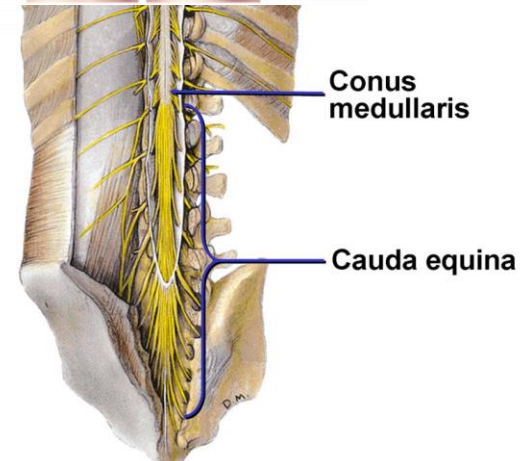
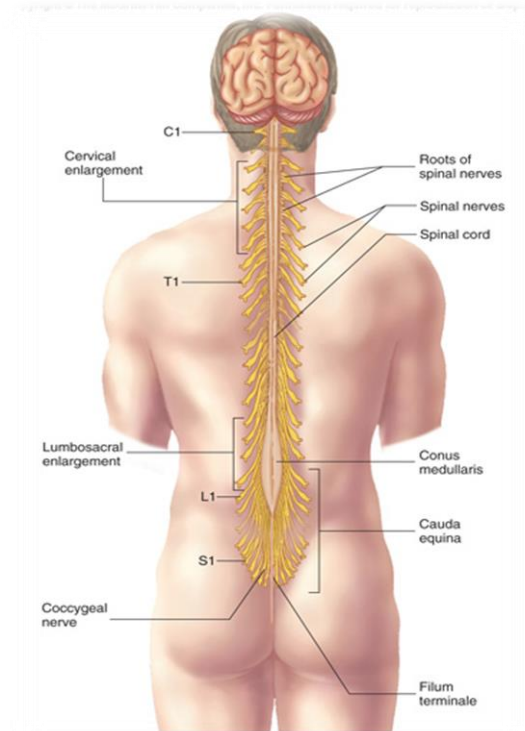
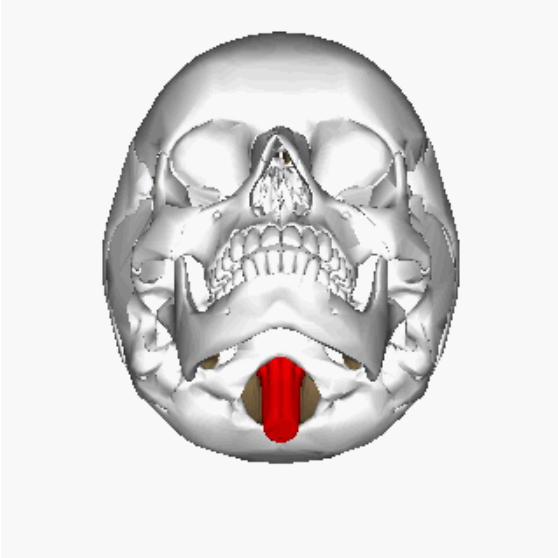
SPINAL CORD

- ❑ The main pathway for information connecting the brain and peripheral nervous system.
- ❑ It is elongated, cylindrical, suspended in the vertebral canal and protected by vertebrae
- ❑ Surrounded by the meninges and cerebrospinal fluid (CSF).
- ❑ The primary function of spinal cord is a transmission of neural signals between the brain and the rest of the body.
 - Sensory
 - Motor
 - Local reflexes



SPINAL CORD

- ❑ Extends from foramen magnum to second lumbar vertebra.
- ❑ Continuous above with the *medulla oblongata*.
- ❑ The tapered inferior end forms *conus medullaris*.
- ❑ It is connected to the coccyx by a non-neuronal cord called *Filum Terminale*.



SPINAL CORD

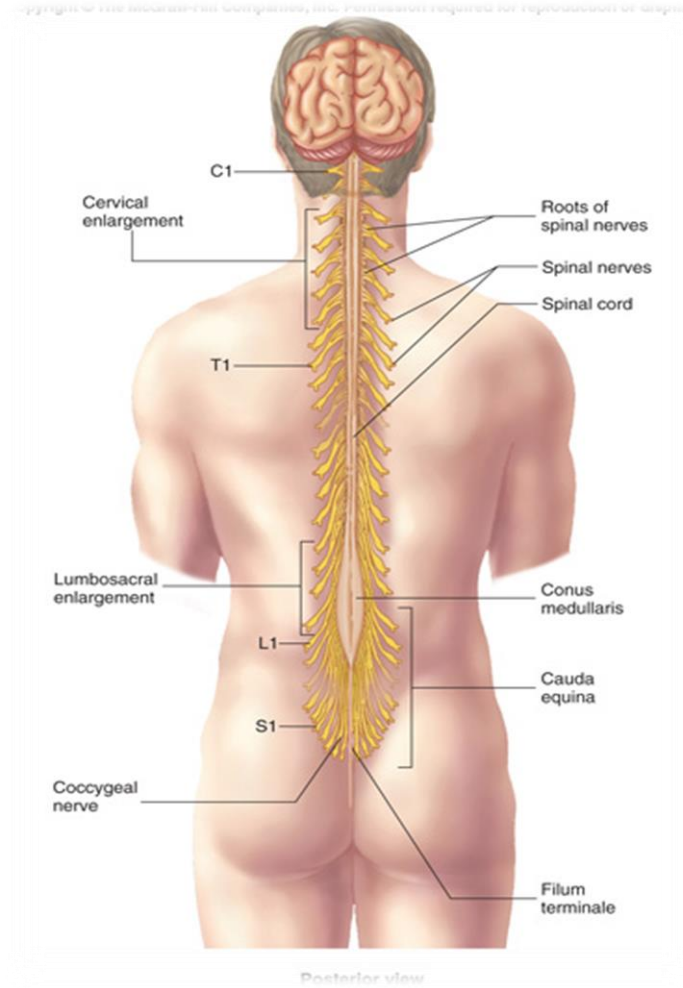
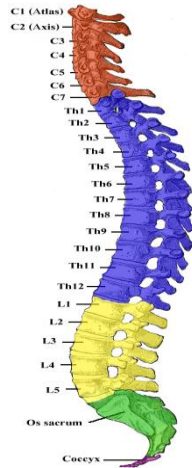
- ☐ Gives rise to 31 pairs of spinal nerves
- ☐ The bundle of spinal nerves extending inferiorly from *lumbosacral enlargement* and *conus medullaris* surround the *filum terminale* and form *cauda equina*

- ☐ Segmented

- 8 Cervical
- 12 Thoracic
- 5 Lumbar
- 5 Sacral
- 1 Coccygeal

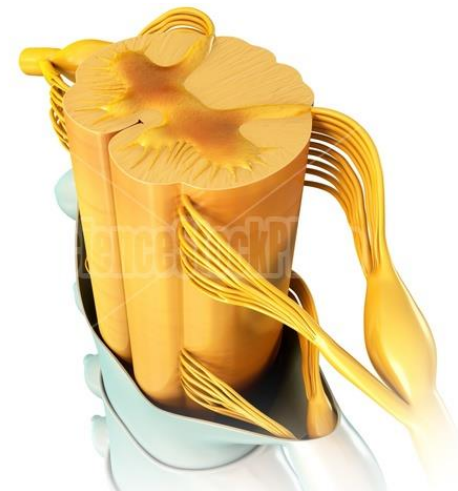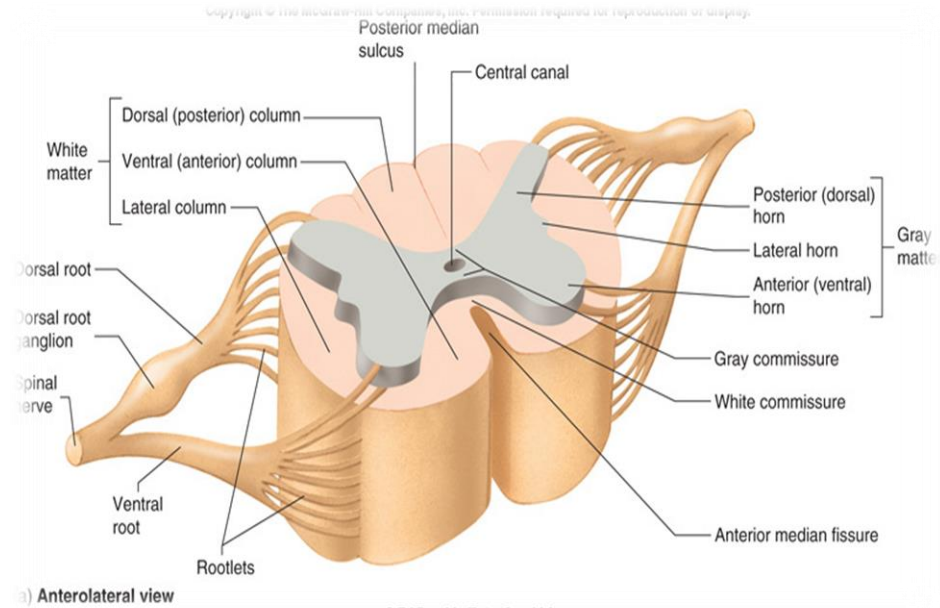
- ☐ Has two enlargements:

- Cervical Enlargement: supplies upper limbs.
- Lumbosacral Enlargement: supplies lower limbs.



CROSS SECTION OF SPINAL CORD

- ❑ The spinal cord is incompletely divided into two equal parts, anteriorly by a short, shallow **median fissure** and posteriorly by a deep narrow septum, **the posterior median sulcus**.
- ❑ Composed of **grey matter** in the center surrounded by **white matter** supported by neuroglia.
- ❑ **Commissures**: connections between left and right halves
 - Gray with central canal in the center
 - White
- ❑ **Roots**: spinal nerves arise as rootlets then combine to form roots
 - Dorsal (posterior) root has a ganglion
 - Ventral (anterior)
 - Two roots merge laterally and form the spinal nerve



GREY MATTER

☐ The nerve cells are **multipolar**, and are of **THREE** main categories:

➤ **Sensory neurons (Tract cells)**

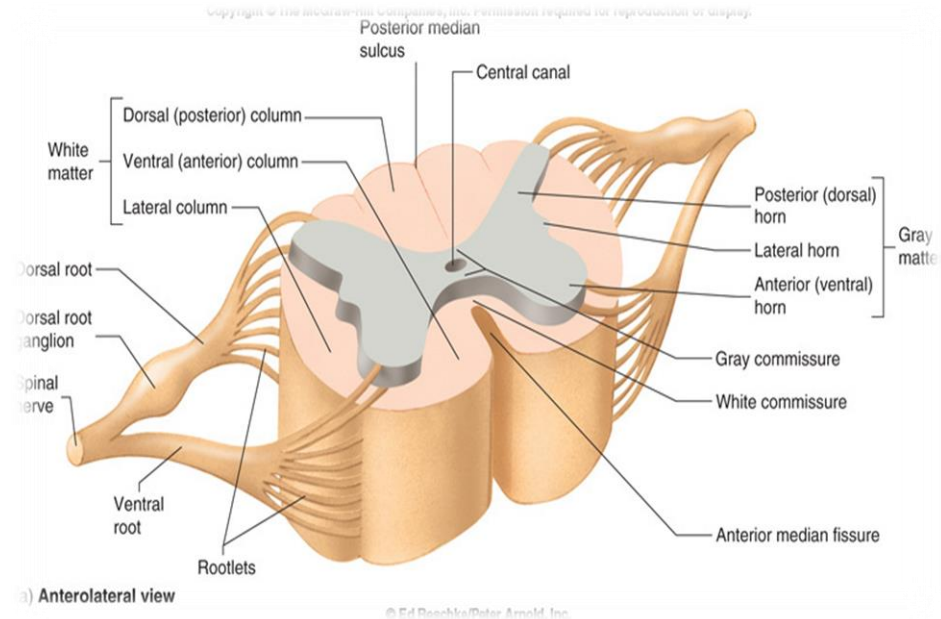
- receive impulses from the periphery of the body and whose axons constitute the ascending fasciculi of the white matter.
- located in the dorsal horns.

➤ **Lower motor neurons**

- transmit impulses to the skeletal muscles.
- **located in the ventral horns**
 - similar neurons in the lateral horn are the preganglionic neurons of the autonomic system.

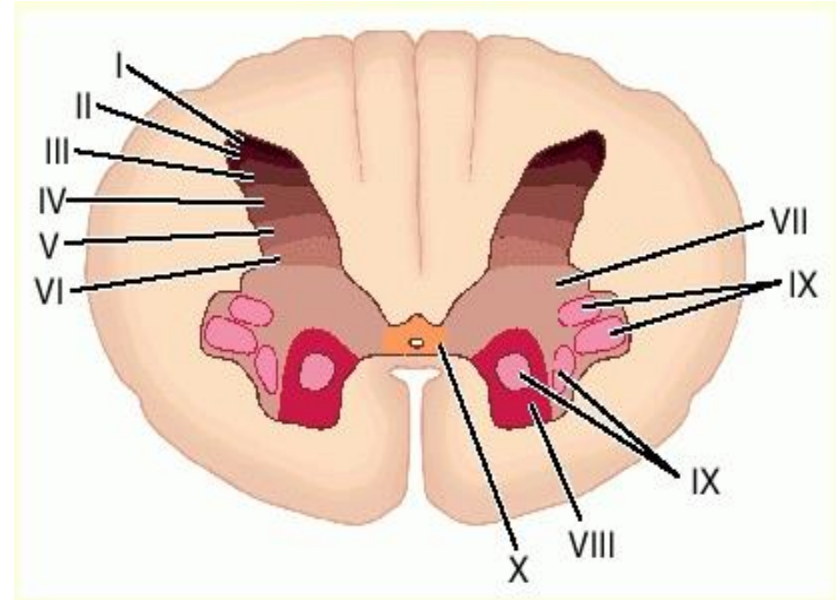
➤ **Interneurons (connector neurons)**

- linking sensory and motor neurons, at the same or different levels, which form spinal reflex arcs.



NEURONAL ARCHITECTURE OF SPINAL GREY MATTER

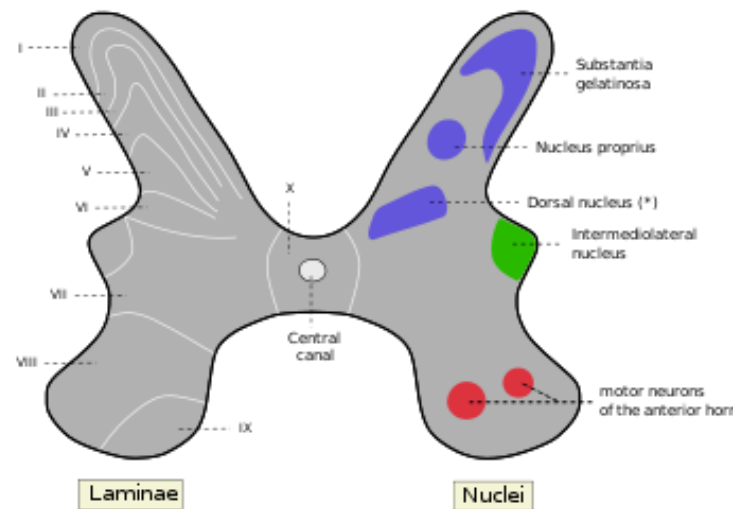
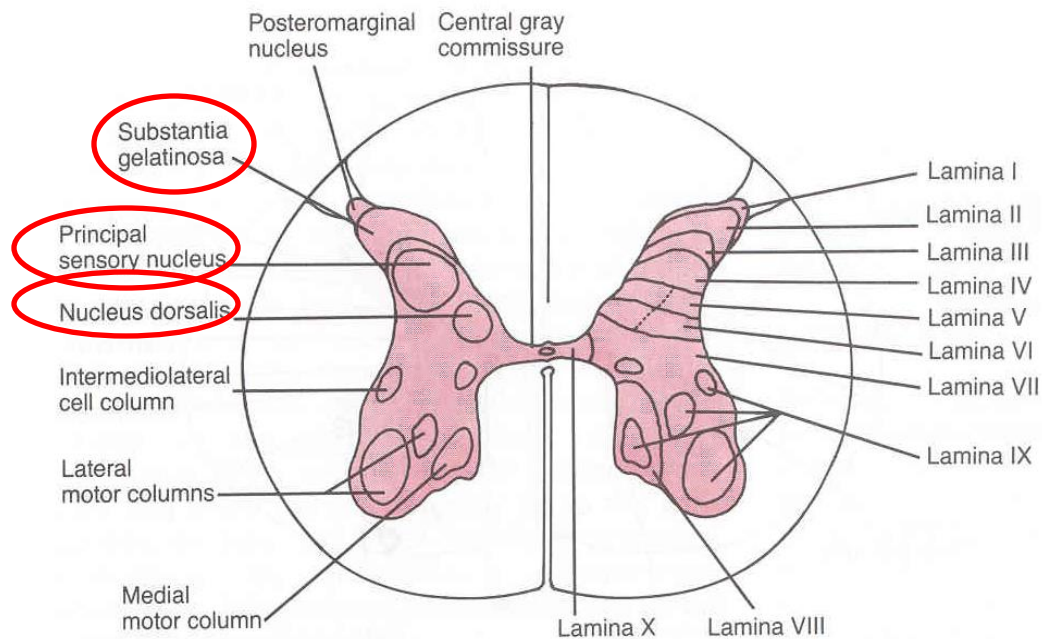
- ❑ Cells of the same type are clustered into groups, which occur in **long columns**
- ❑ In transverse section, these columns appear as **layers**, especially within the dorsal horn
- ❑ These layers are called the **laminae of Rexed** that are numbered by **Roman numerals**, starting from the tip of the dorsal horn and moving ventrally into the ventral horn.
- ❑ The Rexed laminae comprise a system of ten layers of grey matter (I-X), identified in the early 1950s by Swedish neuroscientist.



NERVE CELL GROUPS IN DORSAL HORN

Four main groups

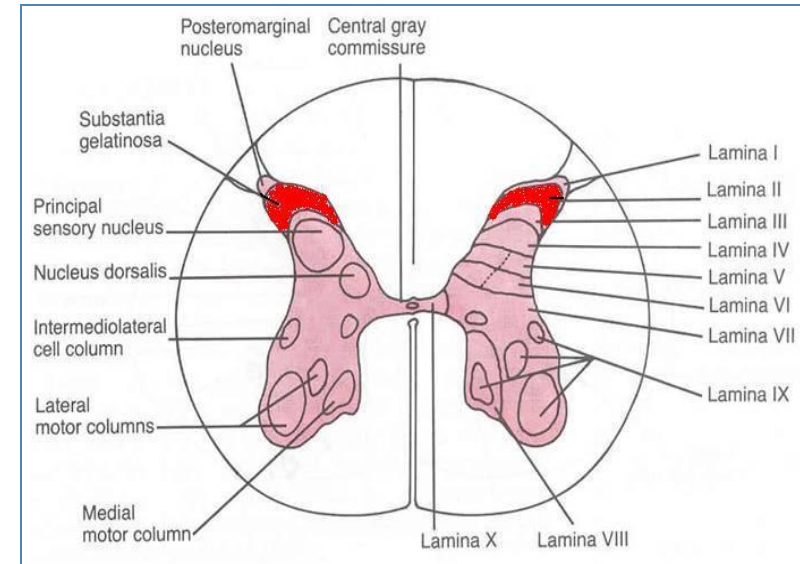
1. **Substantia Gelatinosa**
2. **Nucleus Proprius**
3. **Nucleus Dorsalis**
 - Clark's column
 - Nucleus thoracis
4. **Visceral Afferent Nucleus**



* Posterior thoracic nucleus or Column of Clarke

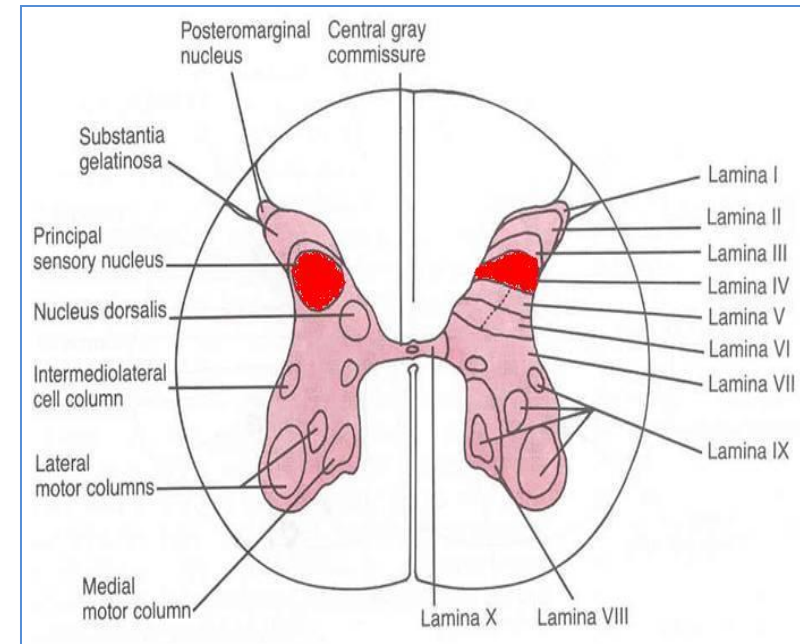
Substantia Gelatinosa

- Rexed Laminae II
- Located at the **apex of the horn**
- Composed of **large neurons**
- Extends **throughout the length** of spinal cord
- **Afferents**: dorsal root fibers concerned with **pain, temperature and touch**



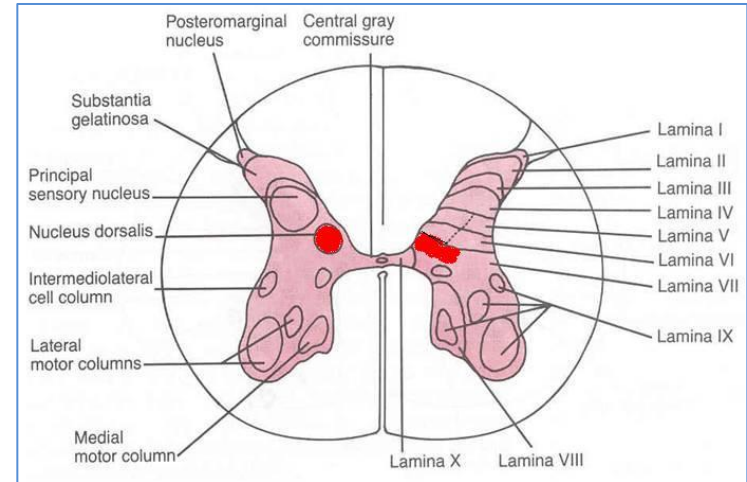
Nucleus Proprius

- Rexed Lamina IV
- Located anterior to substantia gelatinosa
- Composed of **large neurons**
- Extends **throughout the length** of spinal cord
- **Afferents**: dorsal root fibers concerned with **senses of position & movement** (proprioception)



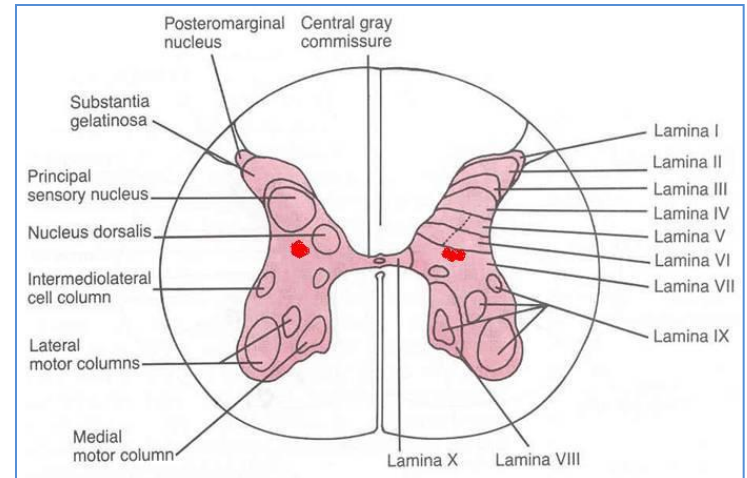
Nucleus Dorsalis (Clark's column, Nucleus thoracis)

- **Rexed Lamina VII**
- Located at the base of dorsal horn
- Composed mostly of large neurons
- Extends from **C8 to L3-4** segments
- Associated with **proprioceptive endings**
- **Afferents:** dorsal root fibers concerned with **information from muscle spindles and tendon organs.**



Visceral Afferent Nucleus

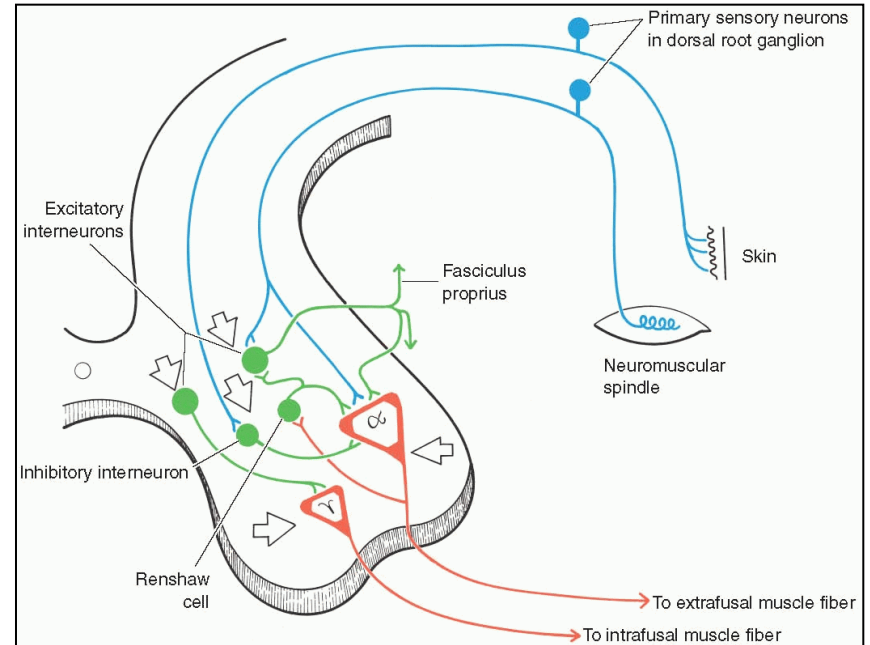
- **Rexed Lamina VII**
- Located lateral to nucleus dorsalis
- Composed mostly of **medium size neurons**
- Extends from **T1 to L3** segments
- **Afferents: Visceral afferents**



NERVE CELL GROUPS IN VENTRAL HORN

□ **Motor neurons**, also called **lower motor neurons**.

□ A special type of **interneurons**, the **Renshaw cells**, whose branched axons form **inhibitory** synaptic junctions on motor neurons



MOTOR NEURONS IN VENTRAL HORN

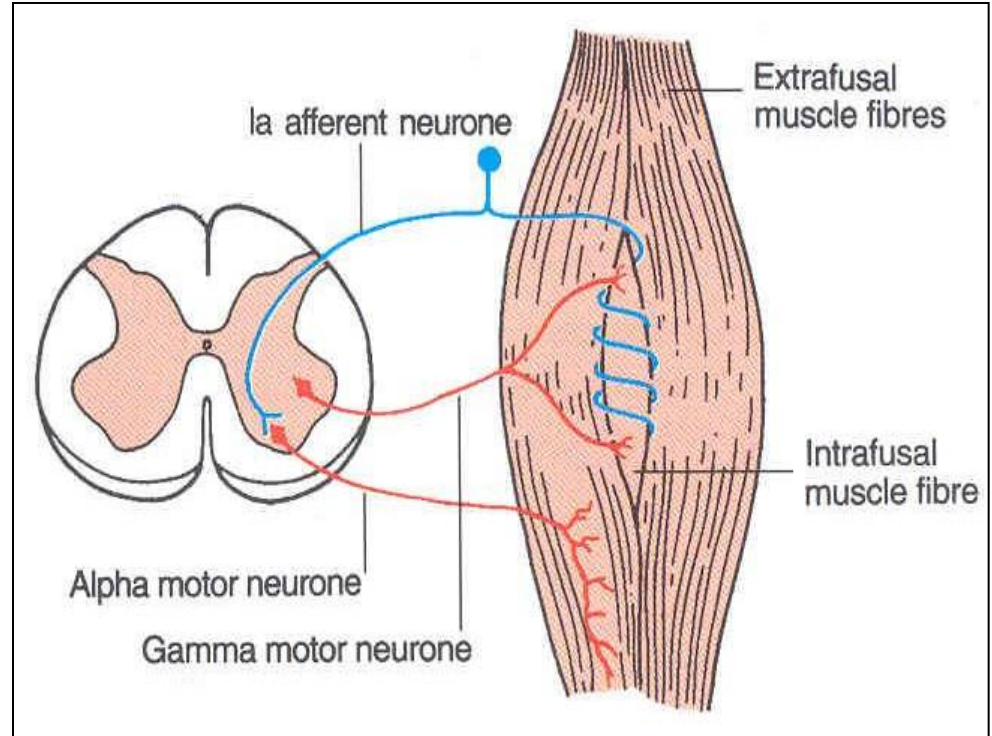
❖ Are of Two types

❑ Large multipolar cells

- whose axons pass out in the ventral roots of spinal nerves as **alpha** efferents which innervate **extrafusal muscle fibers of skeletal muscles**.

❑ Less numerous smaller multipolar cells

- whose axons pass out in the ventral roots of spinal nerves as **gamma** efferents which innervate **intrafusal muscle fibers** of neuromuscular spindles



Both alpha and gamma motor neurons are under the influence of descending pathways from brain

MOTOR NEURONS IN VENTRAL HORN

Motor neurons are organized in 3 groups:

☐ Medial:

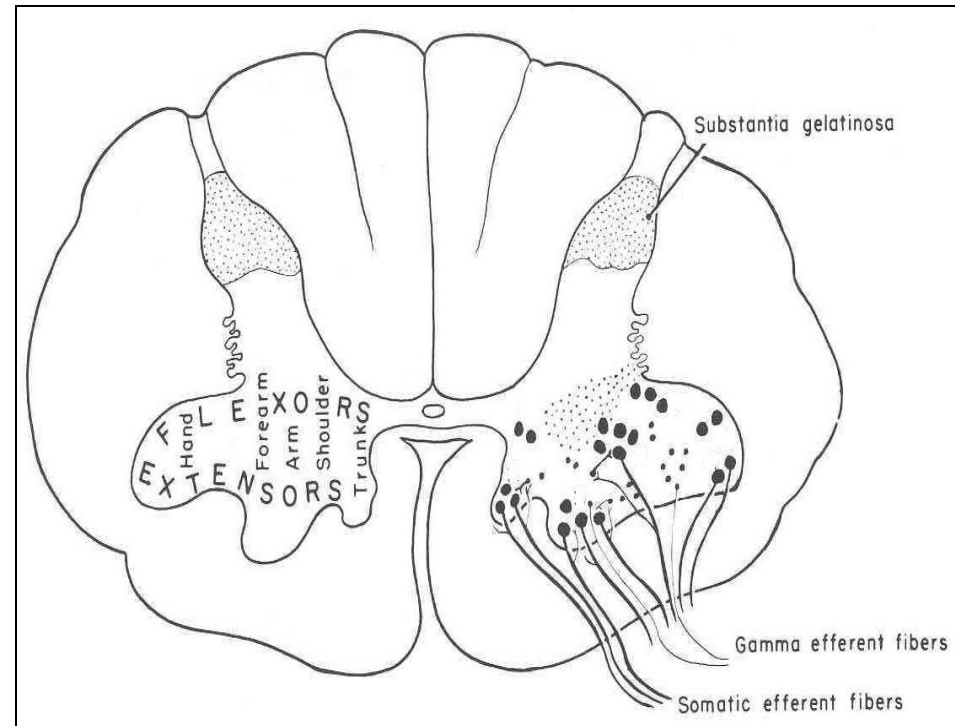
- Present in **most segments**, innervates muscles of **neck and trunk** (including intercostal and abdominal muscles)

☐ Central:

- Smallest, present in some **cervical** (phrenic C3-5, spinal accessory C1-6) and **lumbosacral** (L2-S1) segments

☐ Lateral:

- Present in **cervical** and **lumbosacral** segments, **innervates muscles of the limbs**

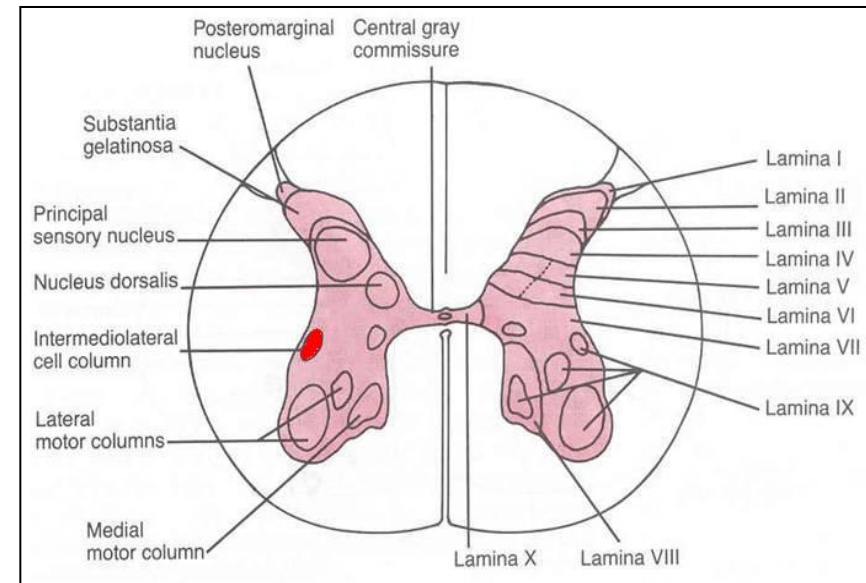


Neurons supplying flexor muscles
are located dorsal to neurons for
extensor muscles

NERVE CELL GROUPS IN LATERAL HORN

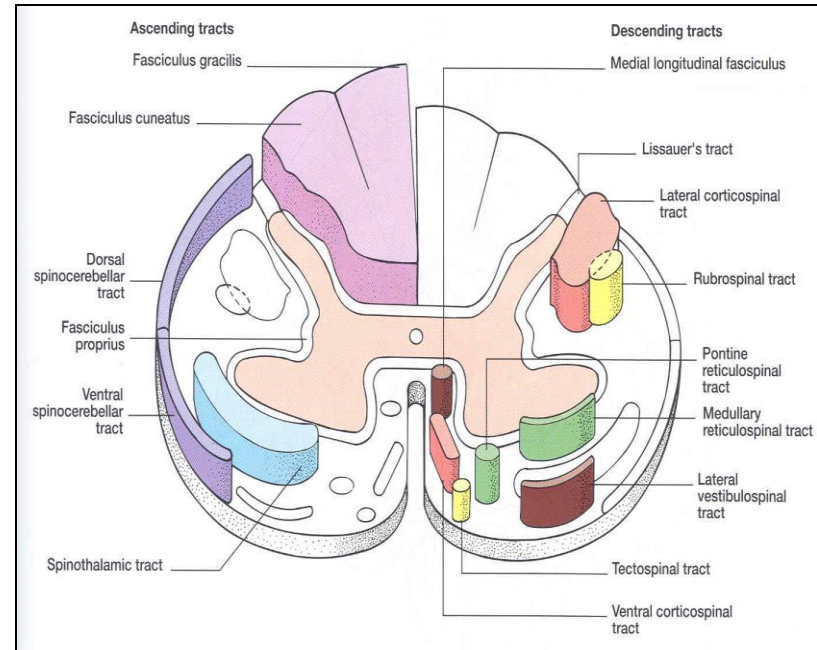
❖ Small Column composed of small neurons

- Extends from **T1 to L2-3** segments:
 - Give rise to preganglionic **sympathetic fibers**
- Extends from **S2-4** segments:
 - Give rise to preganglionic **parasympathetic fibers**



WHITE MATTER

- ❑ Consists of mixture of **nerve fibers**, **neuroglia** and **blood vessels**.
- ❑ White color is due to high proportion of **myelinated nerve fibers**
- ❑ The white matter of the spinal cord is arranged in columns/funiculi; **anterior, posterior and lateral**.
- ❑ The nerve fibers are arranged as bundles, running vertically through the cord.
- ❑ A group of nerve fibers (axons) that share a common origin, termination and function form a **tract** or **fasciculus**
- ❑ These tracts are formed by **sensory nerve fibers ascending to the brain**, **motor nerve fibers descending from the brain** and **fibers of connector neurons**.
- ❑ Tracts are often named according to their points of origin and destination, e.g. **spinothalamic**, **corticospinal**.



Depending on their function, the spinal tracts are divided into ascending and descending tracts



Ascending tracts

Dorsal surface



Descending tracts

Dorsal columns:

1. Fasciculus gracilis

(conscious muscle sense concerned with awareness of body position; crossed touch, pressure, vibration)

Dorsal spinocerebellar (uncrossed;

unconscious muscle sense—important in control of muscle tone and posture)

Ventral spinocerebellar (crossed;

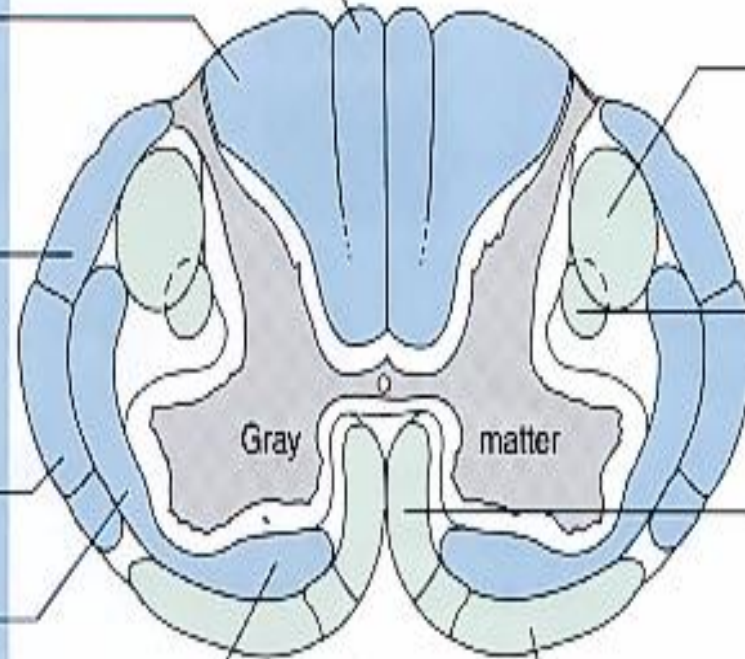
unconscious muscle sense)

Lateral spinothalamic (crossed;

pain and temperature)

Ventral spinothalamic (crossed;

touch)



Lateral corticospinal (crossed; voluntary control of skeletal muscles)

Rubrospinal (crossed; involuntary control of skeletal muscle concerned with muscle tone and posture)

Ventral corticospinal (uncrossed down spinal cord; crosses at level of termination in spinal cord; voluntary control of skeletal muscles)

Vestibulospinal (uncrossed; involuntary control of muscle tone to maintain balance and equilibrium)

Ventral surface
(a)

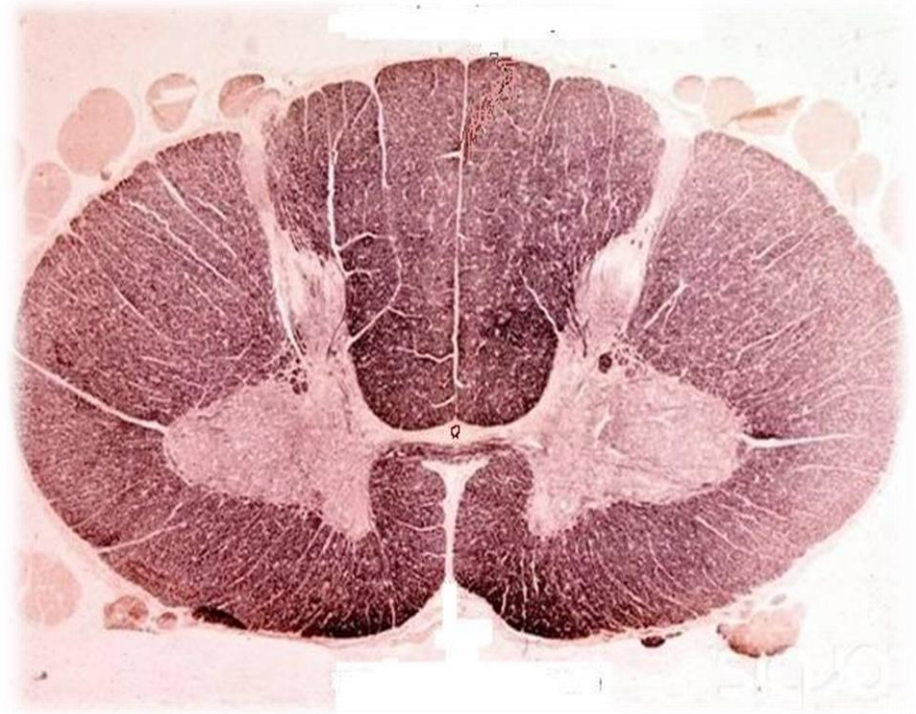COMMISSURES OF THE SPINAL CORD

□ Grey Commissure:

- Transverse bridge of grey matter connecting the anterior and posterior gray horns on each side
- Is pierced by the **central canal** that divides it into anterior and posterior parts

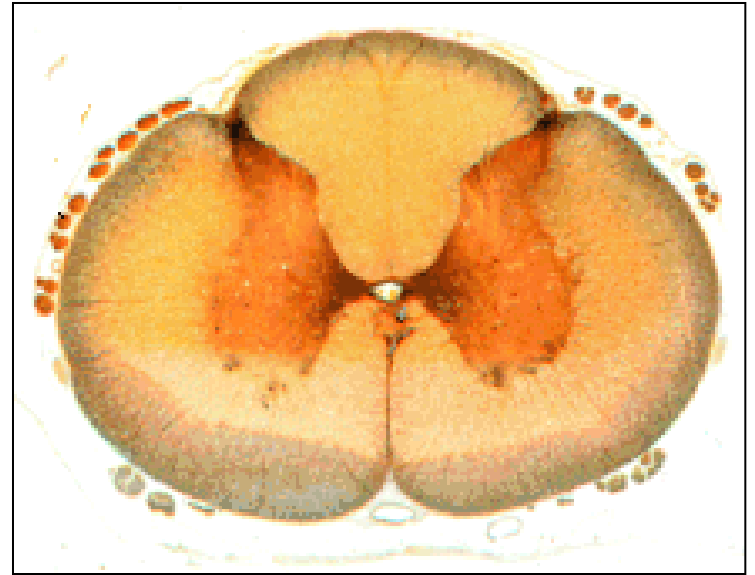□ White Commissure:

- Lies ventral to the gray commissure
- Mainly contains decussating nerve fibers



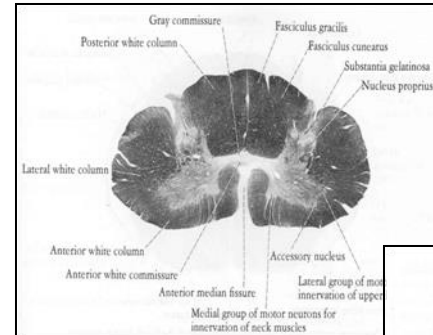
CENTRAL CANAL

- ❑ The cerebrospinal-filled space that runs longitudinally through the entire length of the spinal cord.
- ❑ Lined by **ependyma** (ciliated columnar epithelium)
- ❑ Continuous with the **ventricular system** of the brain
- ❑ Superiorly opens into the 4th ventricle
- ❑ Inferiorly in the conus medullaris, it expands into the fusiform **terminal ventricle** and terminates below at the root of filum terminale



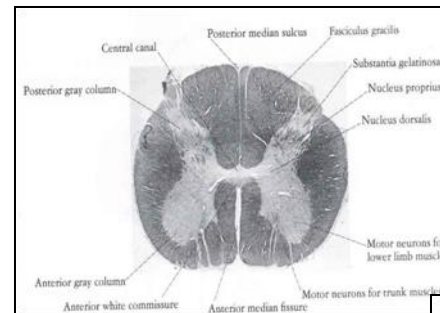
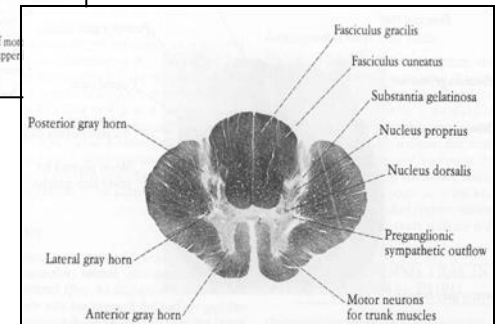
REGIONAL DIFFERENCES

- ❑ Although the general pattern of gray matter is the same throughout spinal cord, **regional differences** are apparent in transverse sections
- ❑ The **amount of white matter** increases in a caudal-to-cranial direction because fibers are added to ascending tracts and fibers leave descending tracts
- ❑ The **gray matter** is in increased volume in **cervical & lumbosacral enlargements** for innervation of upper & lower limbs
- ❑ The **lateral horn** is characteristic of **thoracic and upper lumbar segments**



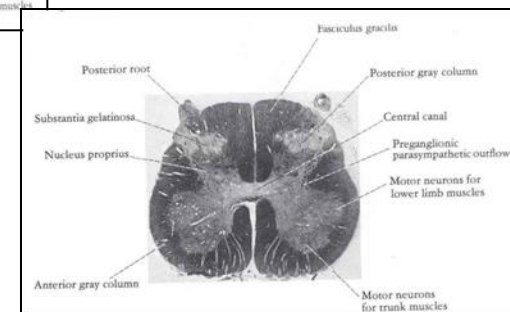
Cervical

Thoracic



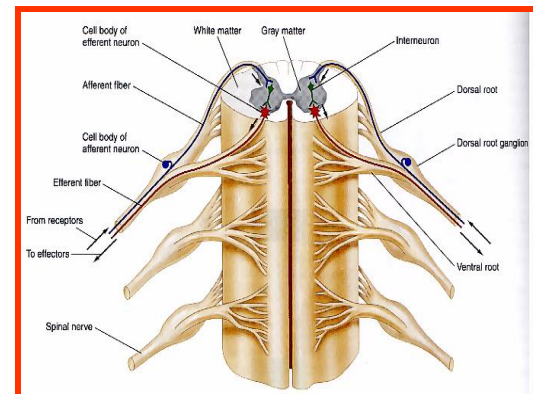
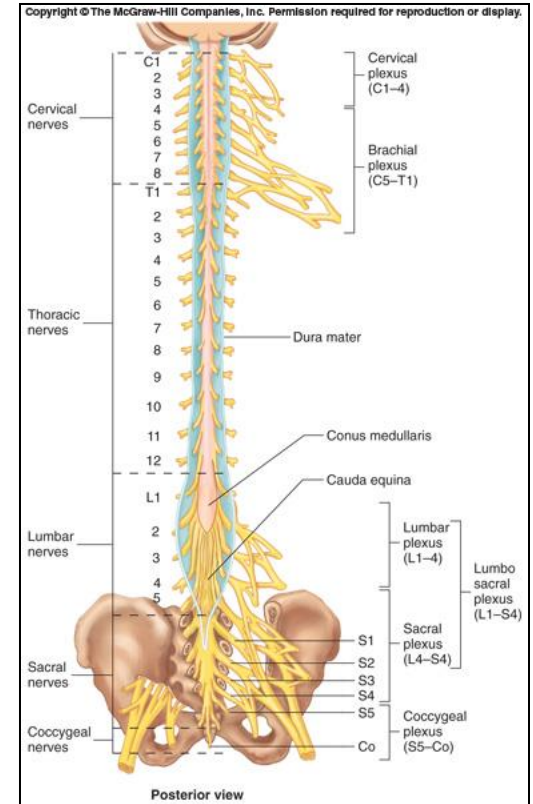
Lumbar

Sacral



SPINAL NERVES

- ❑ **Thirty-one pairs** of spinal nerves
- ❑ First pair exit vertebral column between skull and atlas, last four pairs exit via the sacral foramina and others exit through intervertebral foramina
- ❑ **Eight pair cervical, twelve pair thoracic, five pair lumbar, five pair sacral, one pair coccygeal**
- ❑ Each spinal nerve arises as rootlets which then combine to form **dorsal (posterior) & ventral (anterior) roots**.
- ❑ Two roots merge laterally and form the **spinal nerve**.
- ❑ Dorsal (posterior) root has a **ganglion (dorsal root/sensory ganglion)** that contains the **cell bodies of the sensory neurons**
- ❑ Each spinal nerve then divides into a **smaller dorsal** and a **larger ventral ramus**

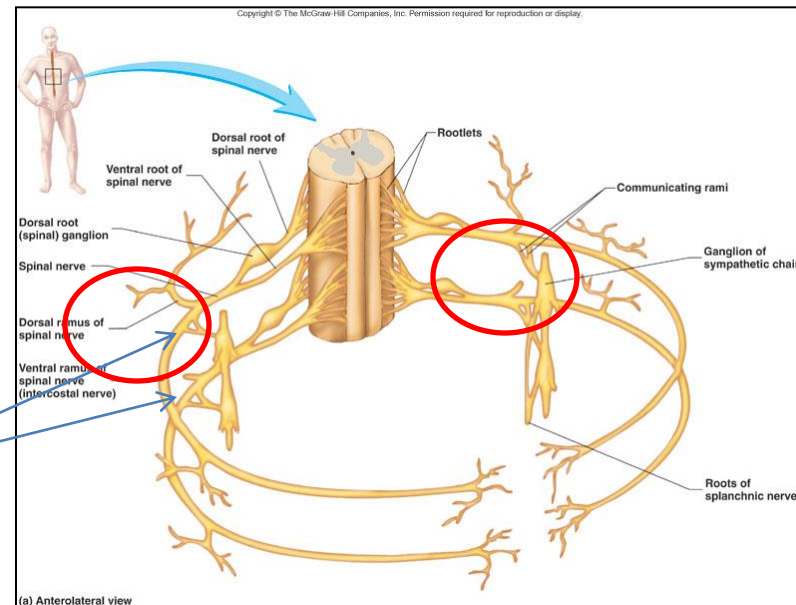


BRANCHES OF SPINAL NERVES

- ❑ **Dorsal Ramus:** innervate deep muscles of the trunk responsible for movements of the vertebral column and skin near the midline of the back.
- ❑ **Ventral Ramus:** what they innervate depends upon which part of the spinal cord is considered.
 - **Thoracic region:** form **intercostal nerves** that innervate the intercostal muscles and the skin over the thorax
 - **Remaining spinal nerve ventral rami (roots of the plexus):** form five plexuses (intermingling of nerves).

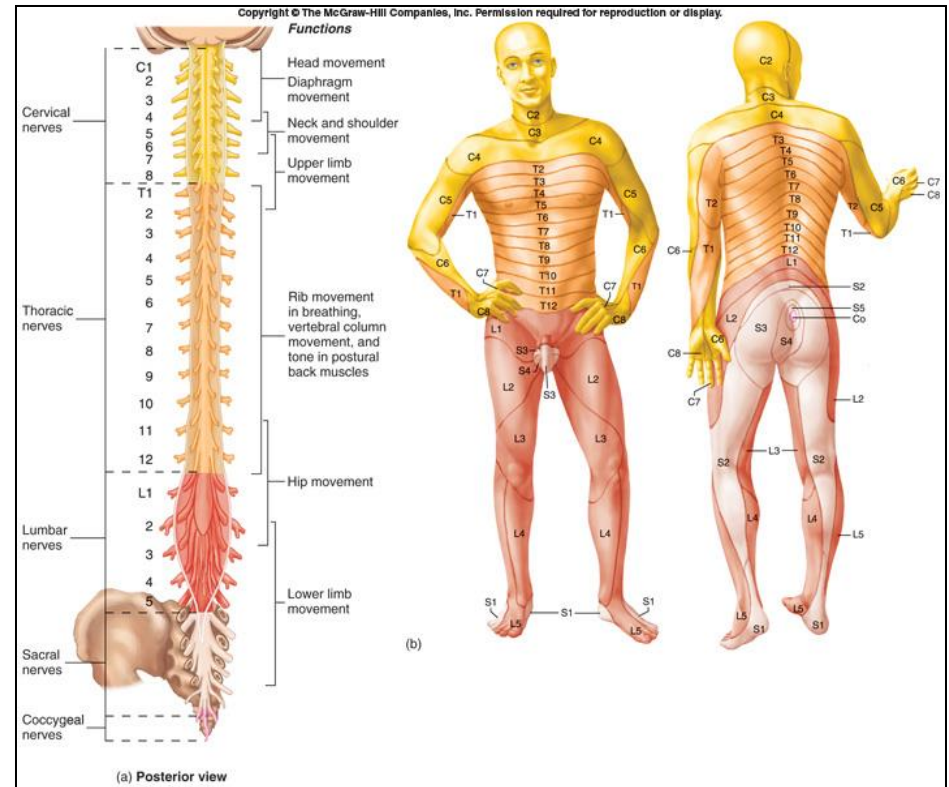
- Ventral rami of C1-C4= **cervical plexus**
- Ventral rami of C5-T1= **brachial plexus**
- Ventral rami of L1-L5= **lumbar plexus**
- Ventral rami of L4-S4= **sacral plexus**
- Ventral rami of S4 & S5= **coccygeal plexus**

- **Communicating Rami:** communicate with sympathetic chain of ganglia.



DERMATOMES

- ❑ Dermatome is a segment of skin supplied by **one spinal nerve**
- ❑ Cutaneous areas supplied by adjacent spinal nerves **overlap**.
- ❑ There is therefore little or sensory loss after interruption of a single spinal nerve or dorsal root



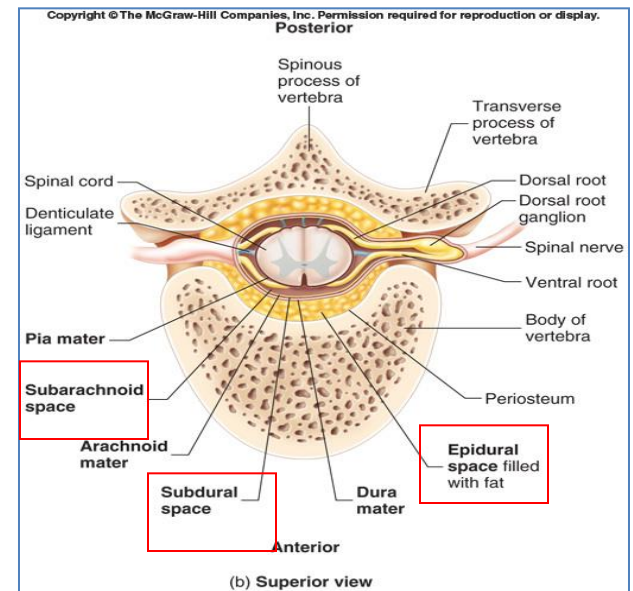
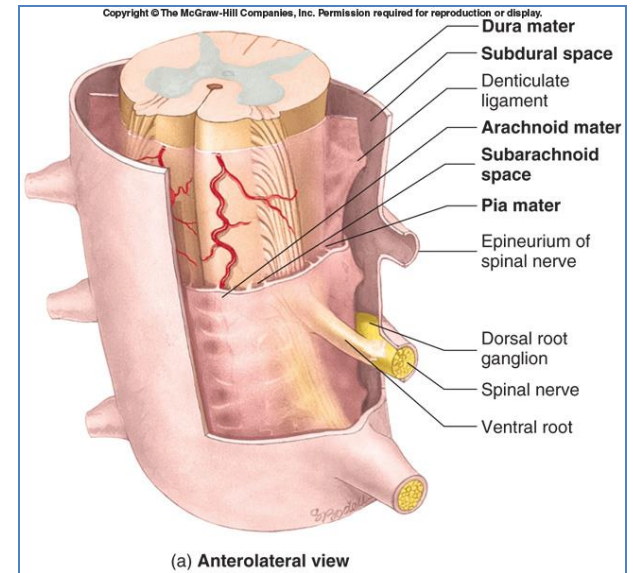
SPINAL MENINGES

Connective tissue membranes surrounding spinal cord and brain

- **Dura mater:** continuous with epineurium of the spinal nerves
- **Arachnoid mater:** thin and wispy
- **Pia mater:** bound tightly to surface of brain and spinal cord.
 - Forms the **filum terminale**, which anchors spinal cord to coccyx and the denticulate ligaments that attach the spinal cord to the dura mater

Spaces

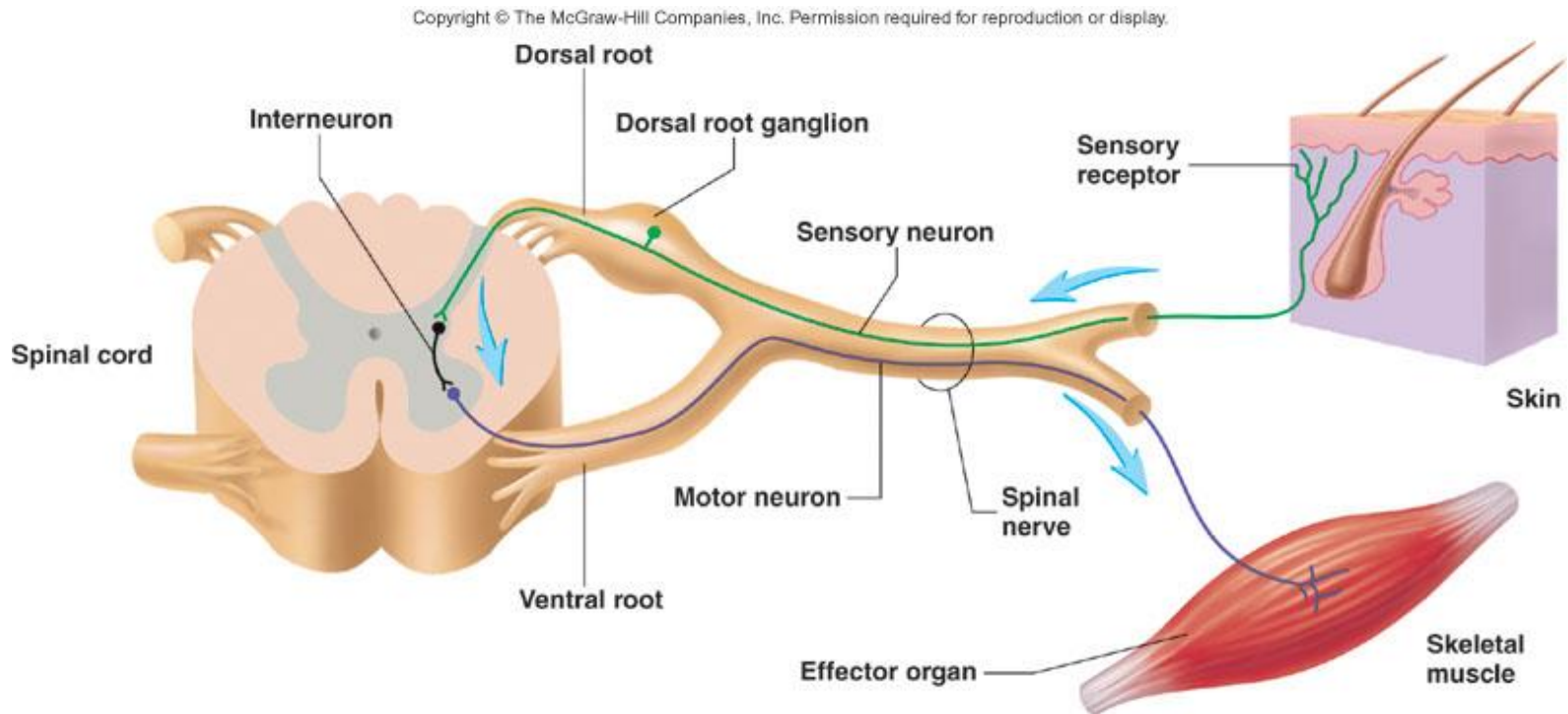
- **Epidural:** Contains blood vessels, connective tissue and fat.
- **Subdural:** Contains serous fluid
- **Subarachnoid:** Contains CSF and blood vessels within web-like strands of arachnoid tissue



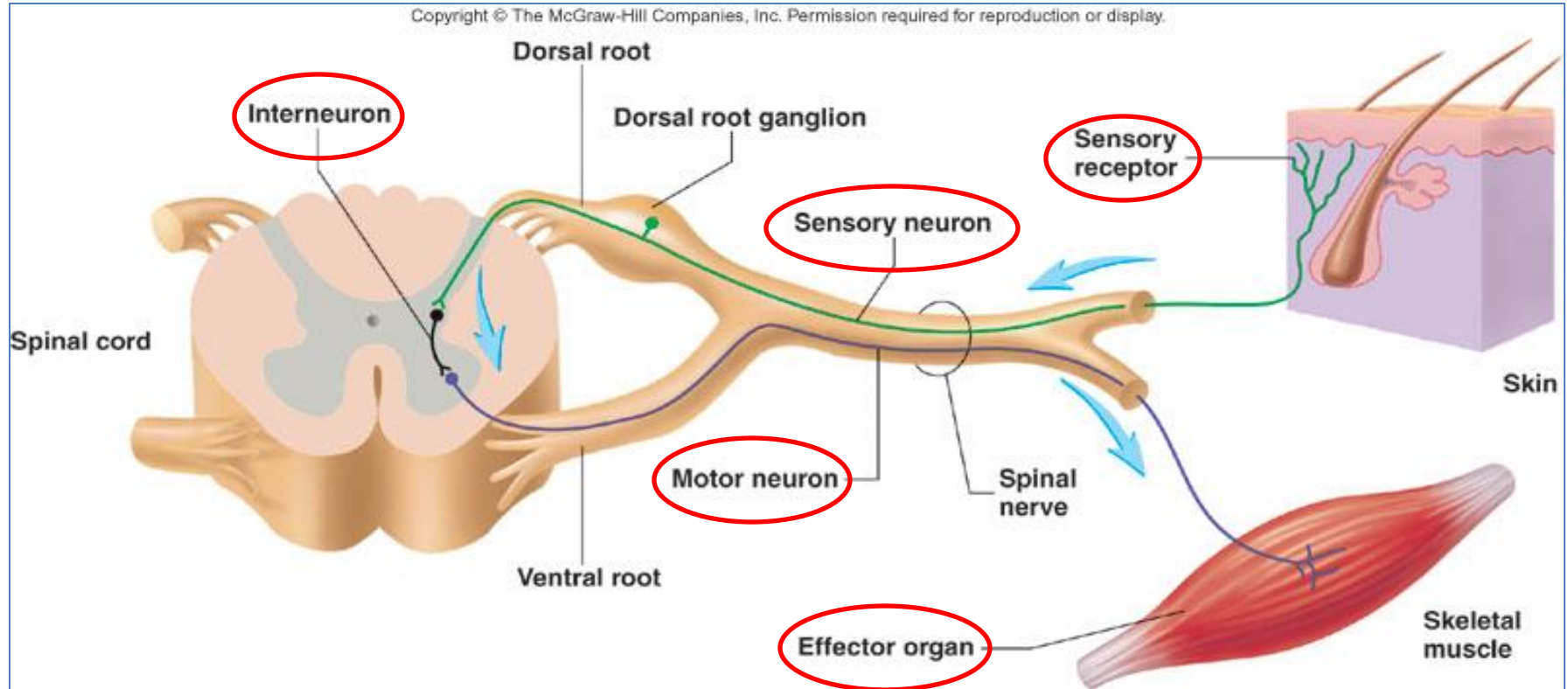
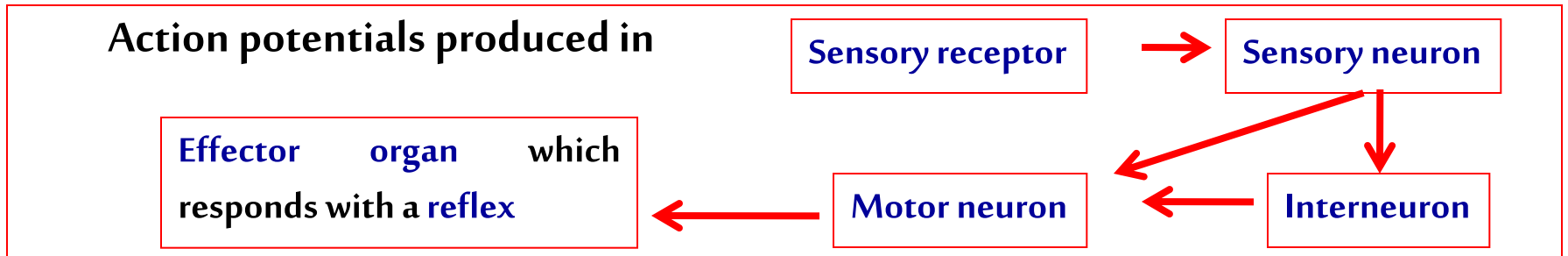
REFLEX & REFLEX ARC

A reflex is a **rapid, involuntary, stereotyped pattern** of response brought by a **sensory stimulus**

A neural pathway mediating the reflex actions is called **reflex arc**.



COMPONENTS OF A REFLEX ARC



QUESTIONS!