



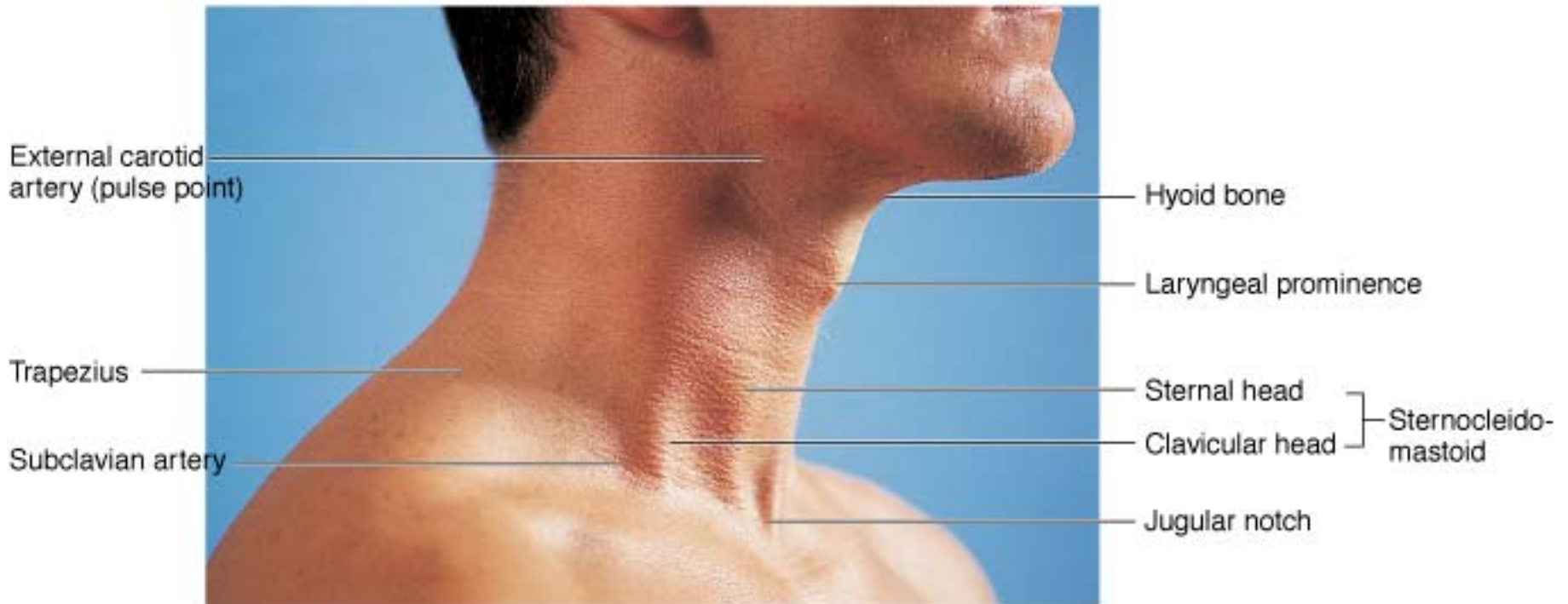
Surface Anatomy

Anatomy

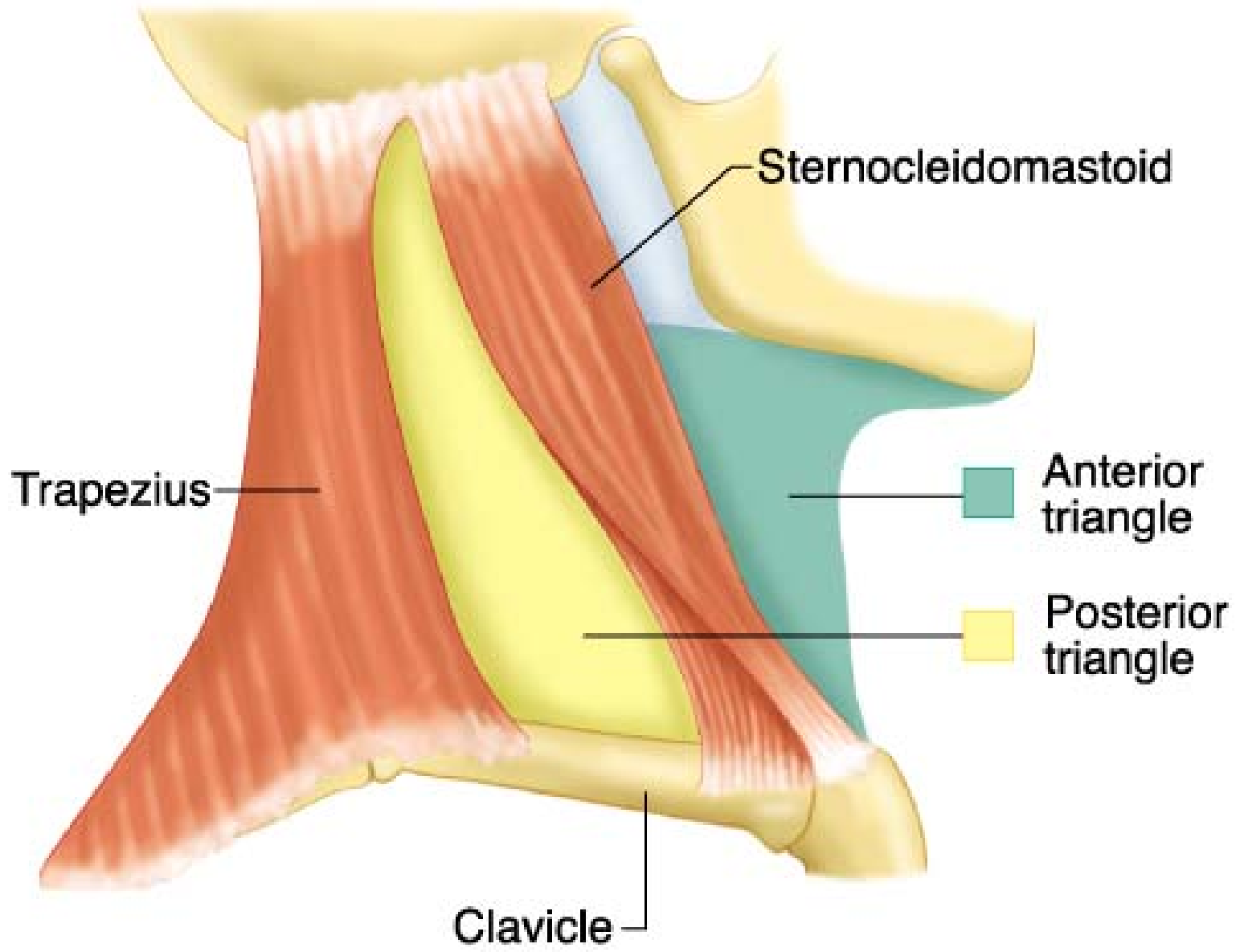
RHS 241

Lecture 20


Dr. Einas Al-Eisa



Copyright © 2001 Benjamin Cummings, an imprint of Addison Wesley Longman, Inc.



(a)



Trapezius

Biceps brachii

Triceps brachii

Superior border of latissimus dorsi

Deltoid:

Anterior part

Intermediate part

Posterior part

Teres major

Inferior angle of scapula

Erector spinae

(b)

Copyright © 2001 Benjamin Cummings, an imprint of Addison Wesley Longman, Inc.

Trapezius:
Superior part
Inferior part

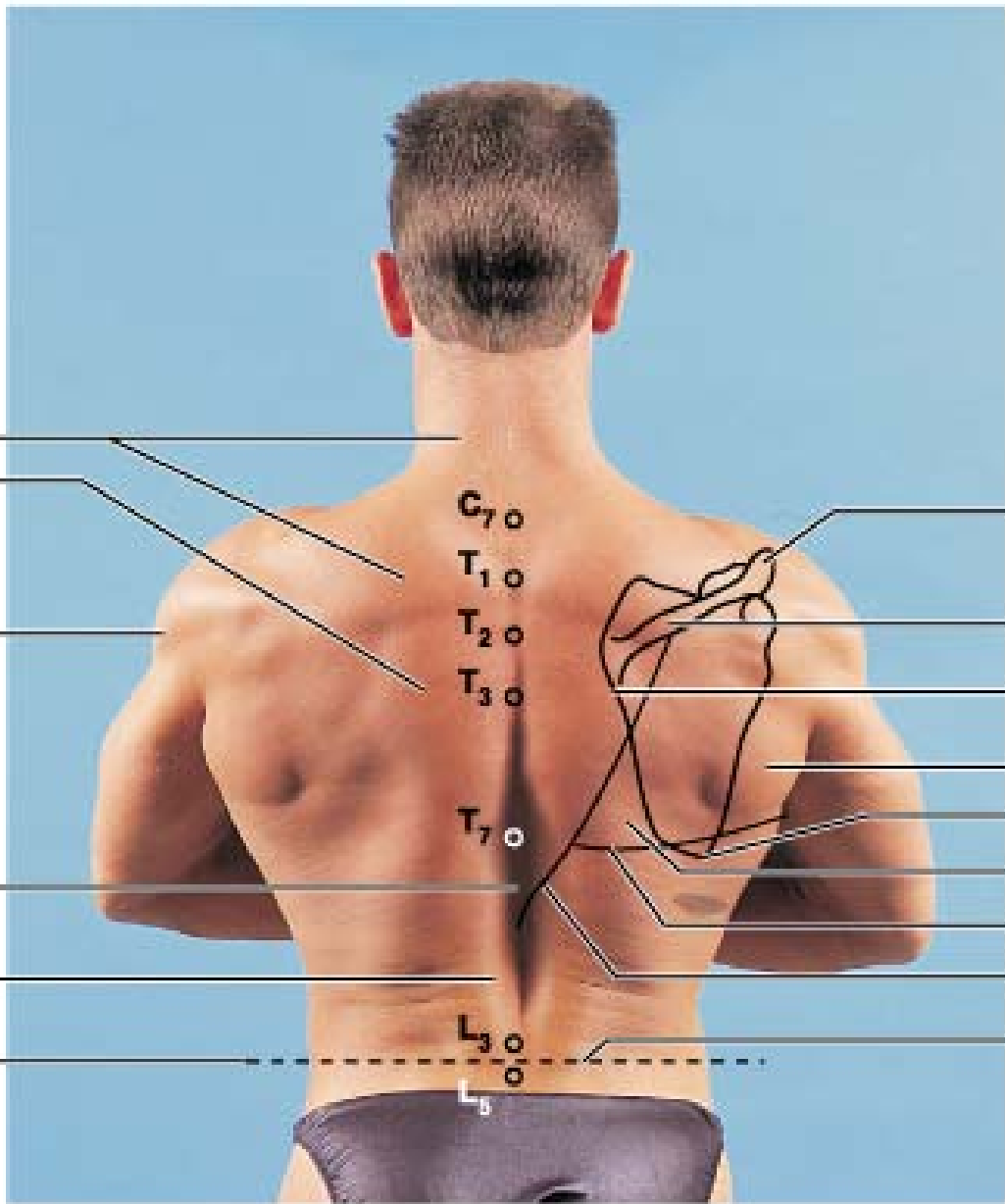
Deltoid muscle

Posterior
median furrow
Erector spinae

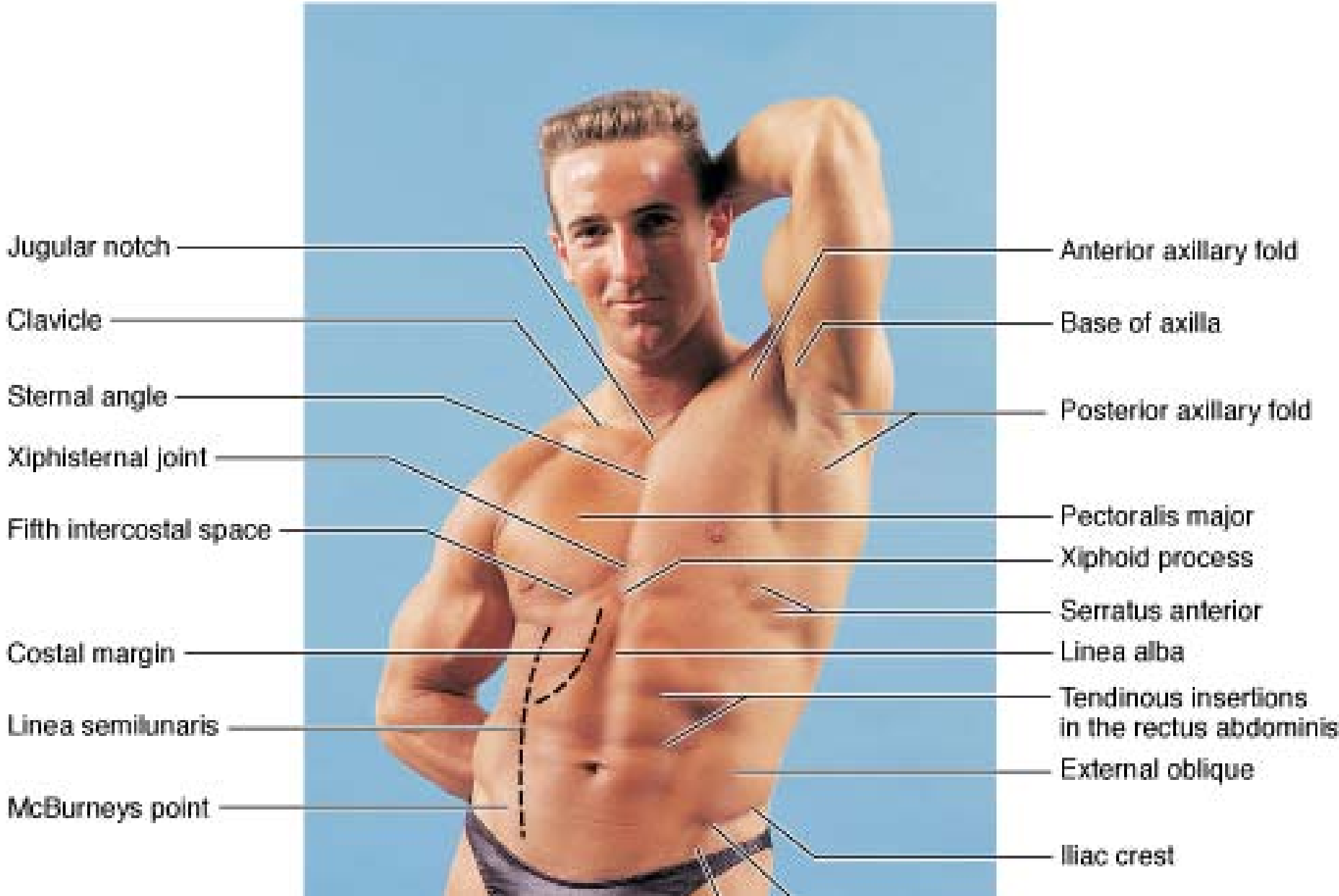
Supracristal
line at L₄

C₇ ◯
T₁ ◯
T₂ ◯
T₃ ◯
T₇ ◯
L₃ ◯
L₅ ◯

Acromion
Spine of scapula
Medial border of scapula
Teres major
Inferior angle of scapula
Triangle of auscultation
Latissimus dorsi (superior border)
Trapezius (lateral border)
Most superior point
of iliac crest



(a)



Jugular notch

Clavicle

Sternal angle

Xiphisternal joint

Fifth intercostal space

Costal margin

Linea semilunaris

McBurneys point

Anterior axillary fold

Base of axilla

Posterior axillary fold

Pectoralis major

Xiphoid process

Serratus anterior

Linea alba

Tendinous insertions
in the rectus abdominis

External oblique

Iliac crest

Triceps brachii:

Lateral head

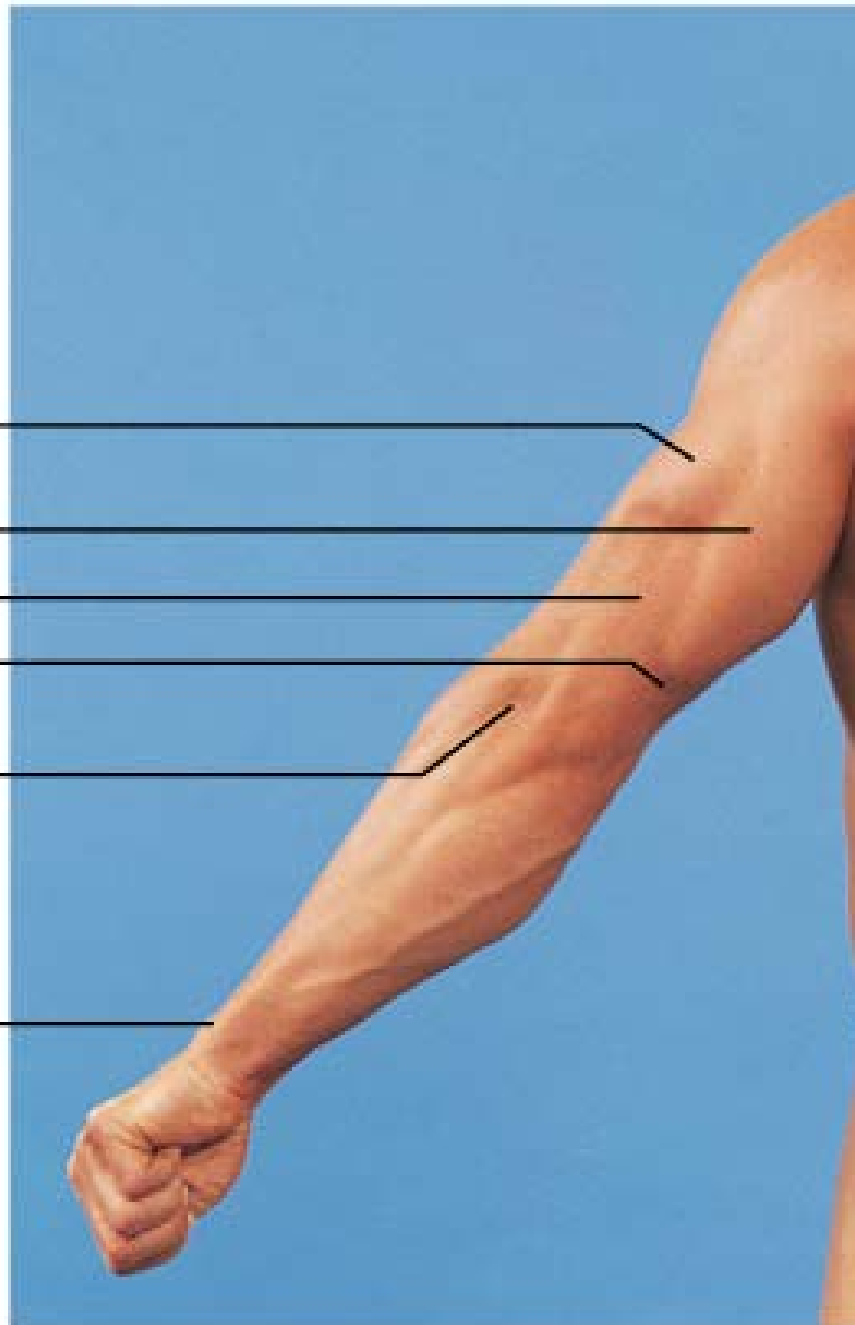
Long head

Tendon

Medial head

**Dimple in which
head of radius is felt**

Head of ulna



Acromioclavicular joint

Deltoid

Biceps brachii


Medial bicipital furrow

Medial epicondyle of the humerus

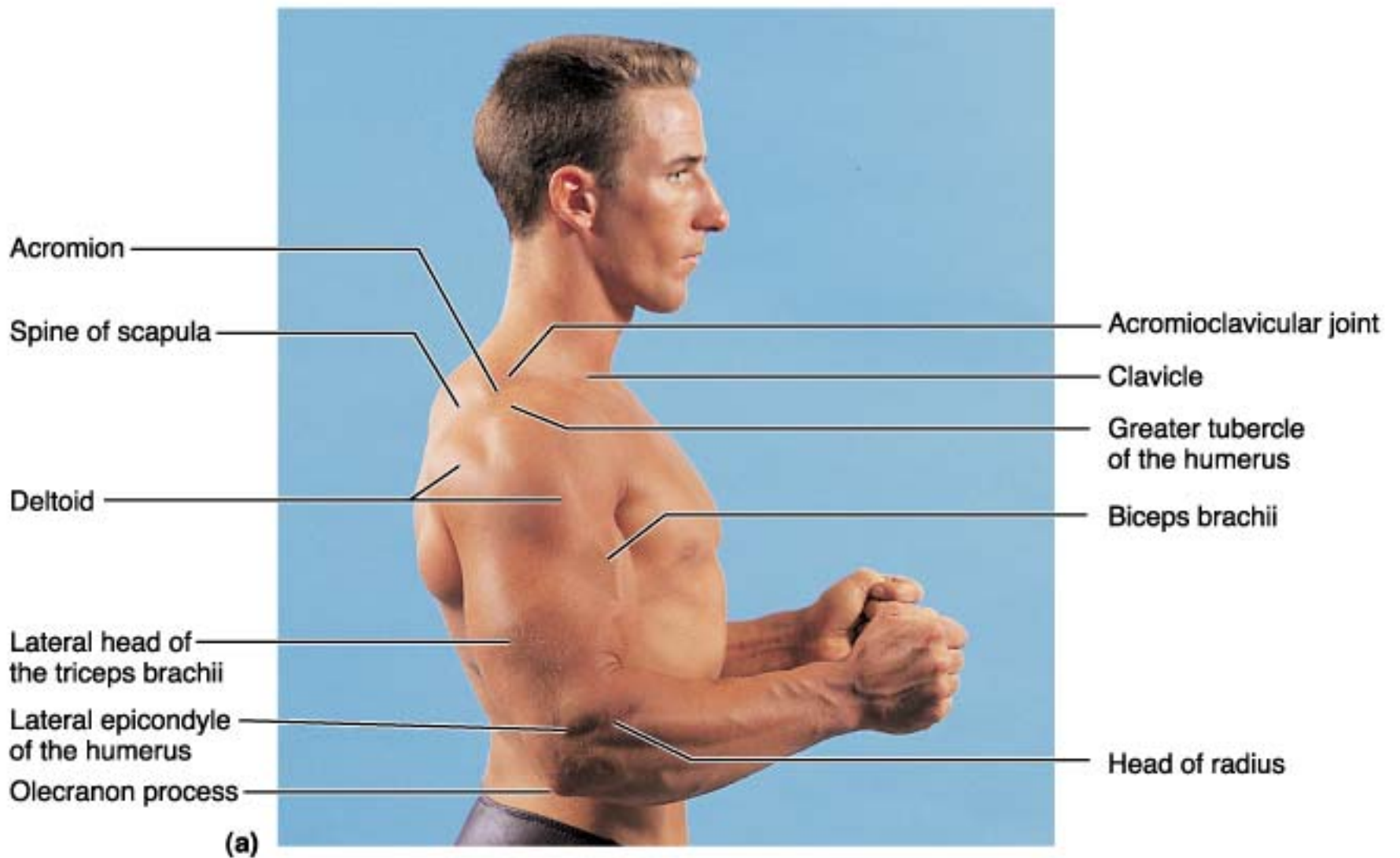
Clavicle

Greater tubercle of the humerus

Cephalic vein



(b)




Brachioradialis

Tendon of flexor
carpi radialis

Tendon of
palmaris longus

Tendon of flexor
carpi ulnaris

(a)



Pisiform bone

Ulnar artery
(pulse point)

Flexor carpi
ulnaris

Flexor digitorum
superficialis

Radial artery
(pulse point)

Flexor carpi
radialis

Palmaris longus

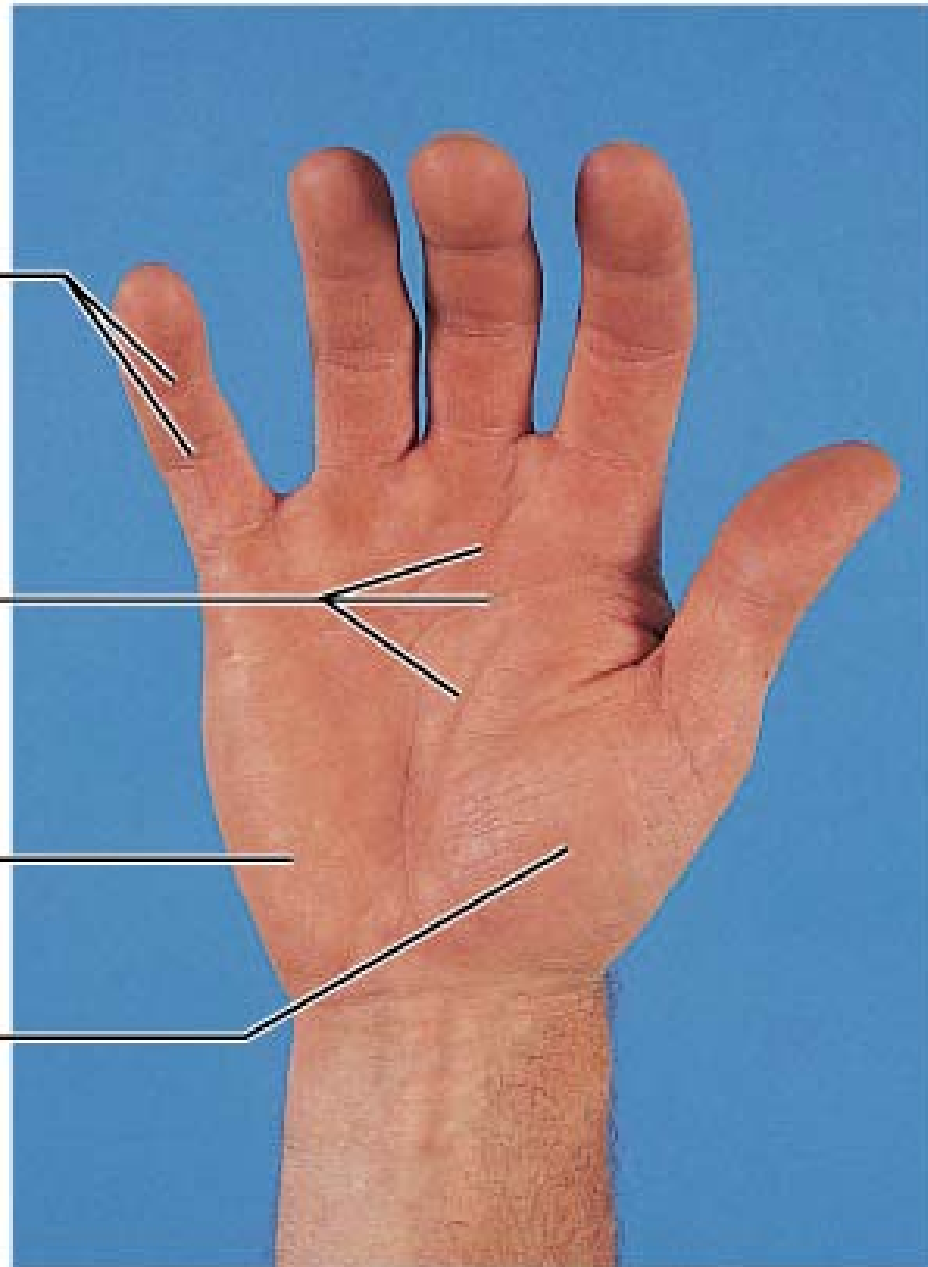
(b)

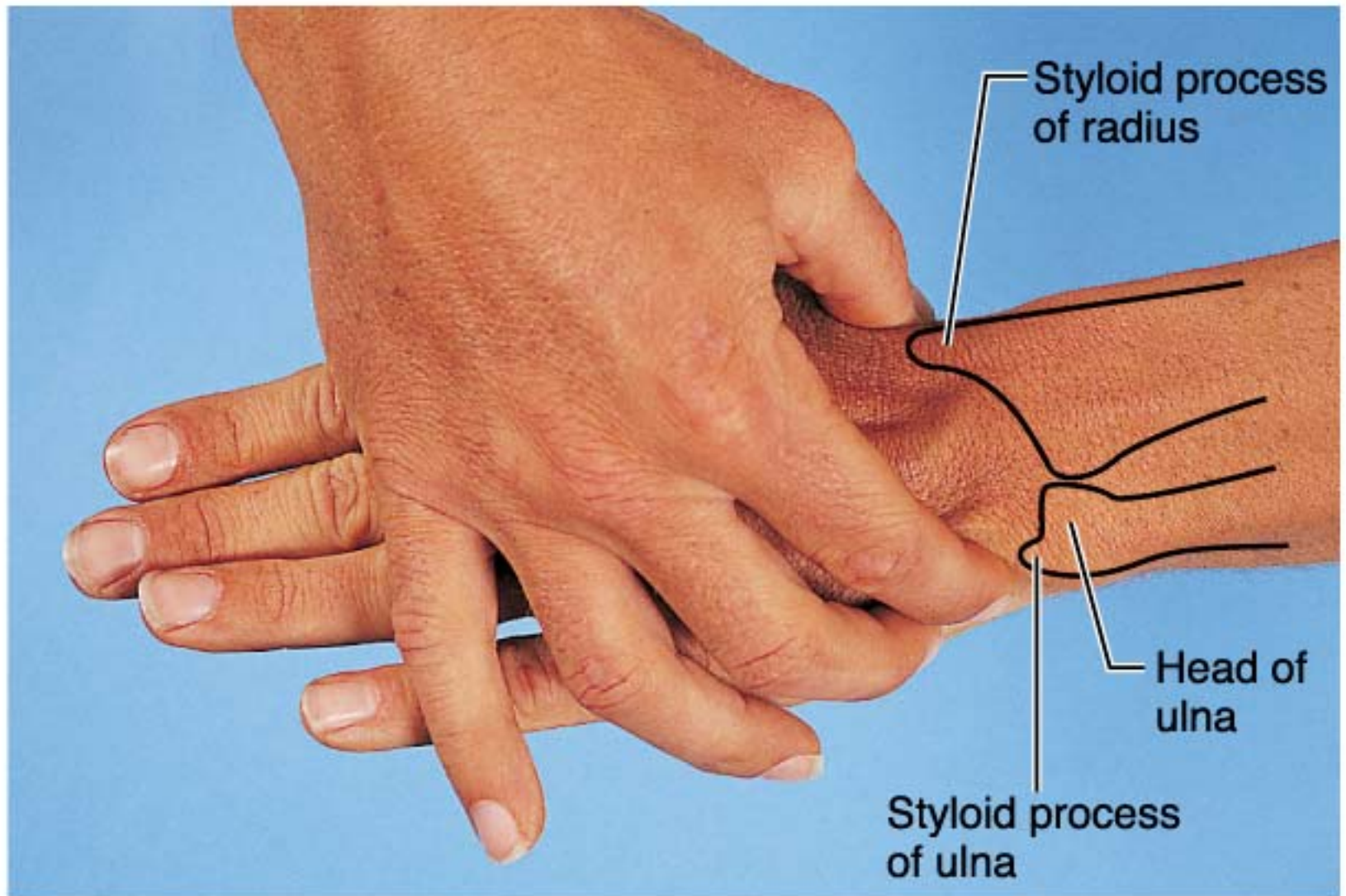
Flexion creases
on digit

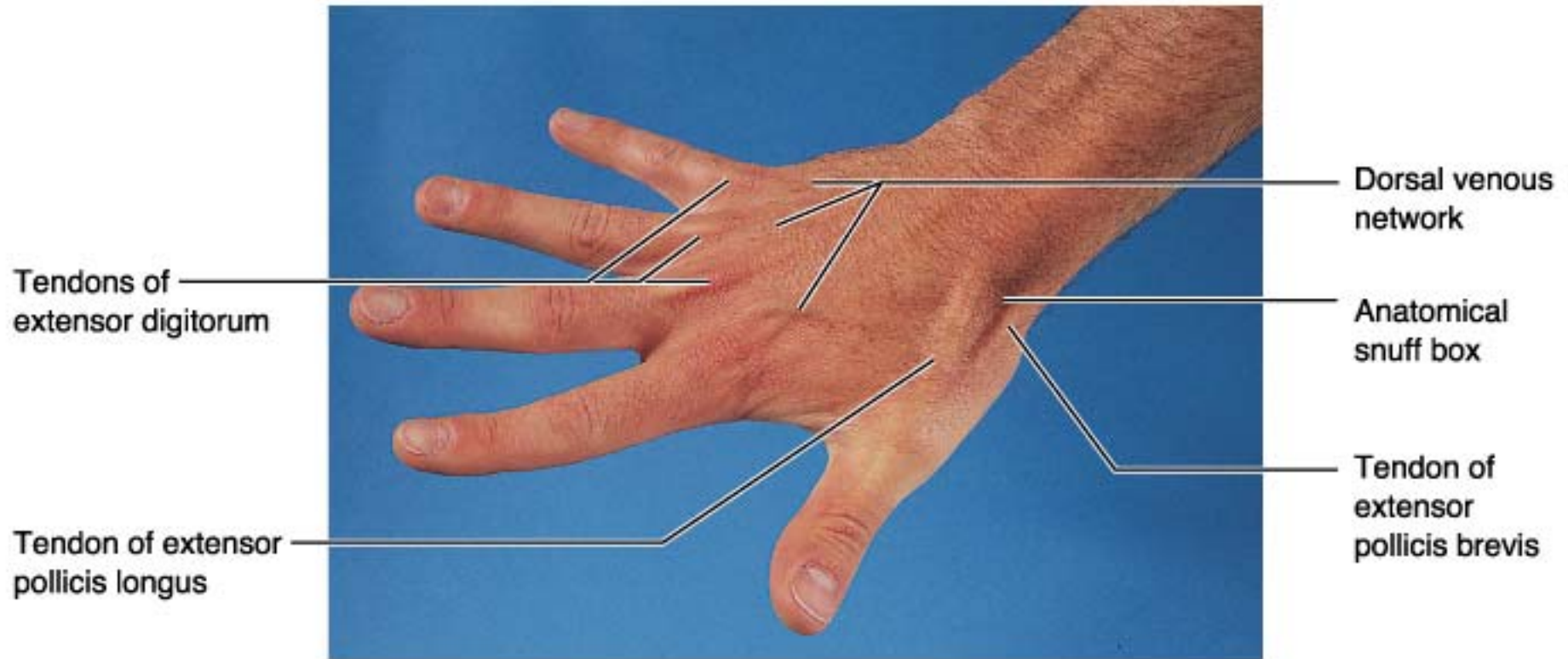
Flexion creases
on the palm

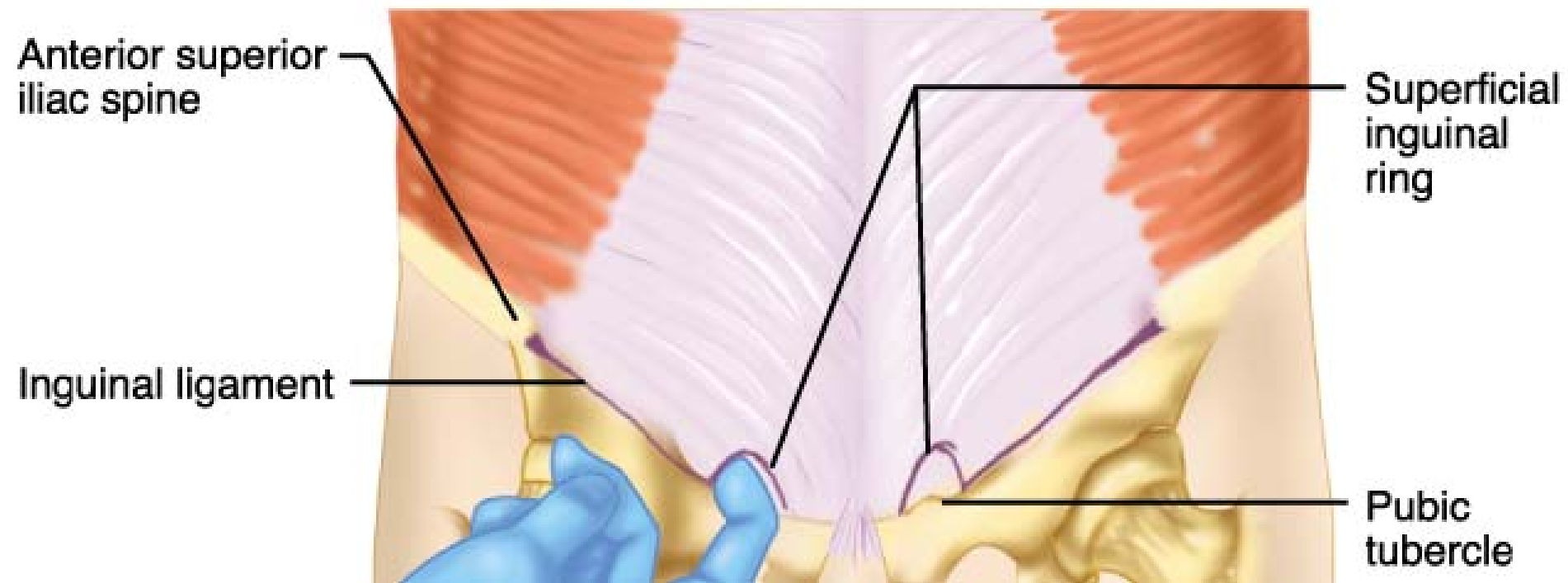
Hypothenar
eminence

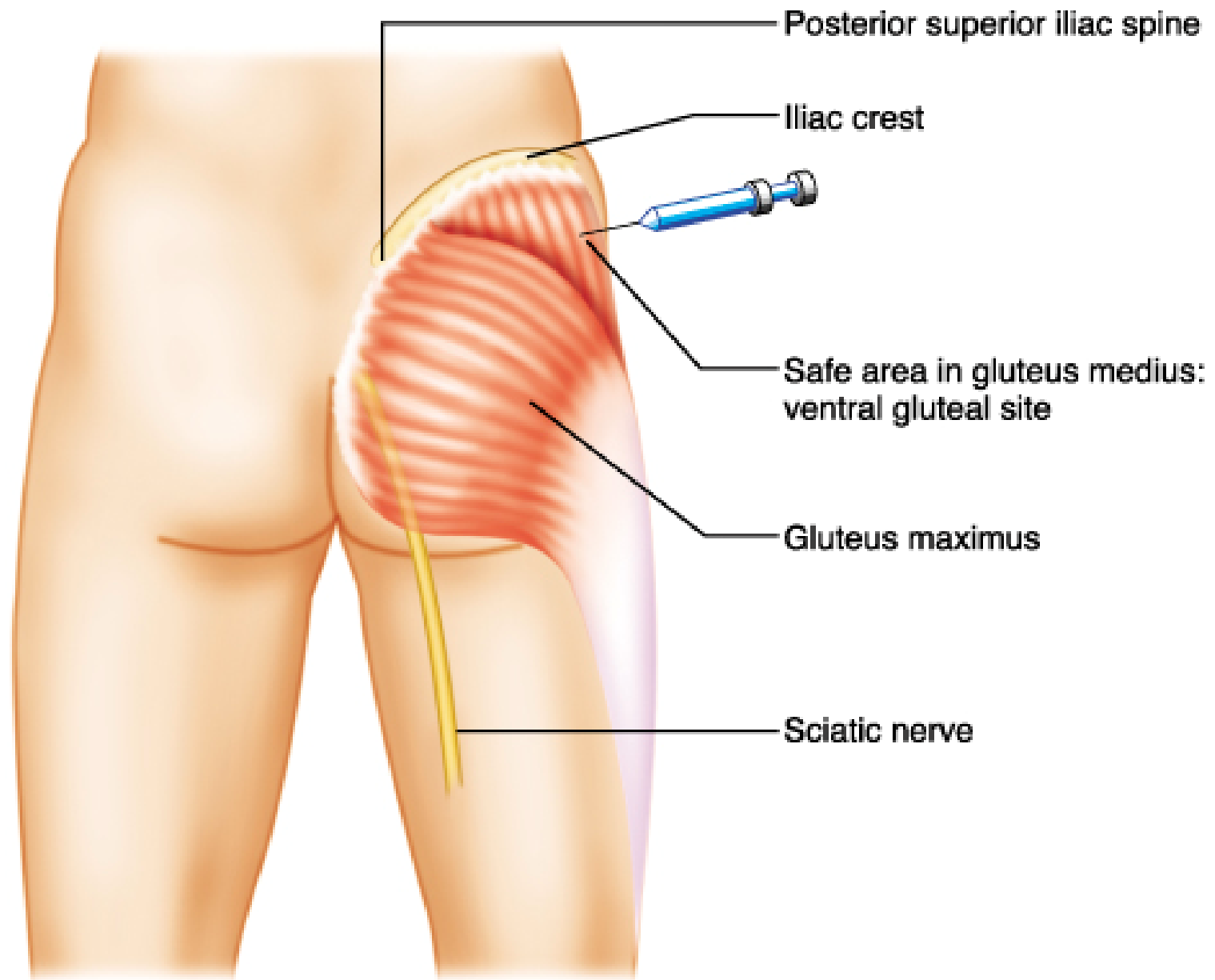
Thenar
eminence







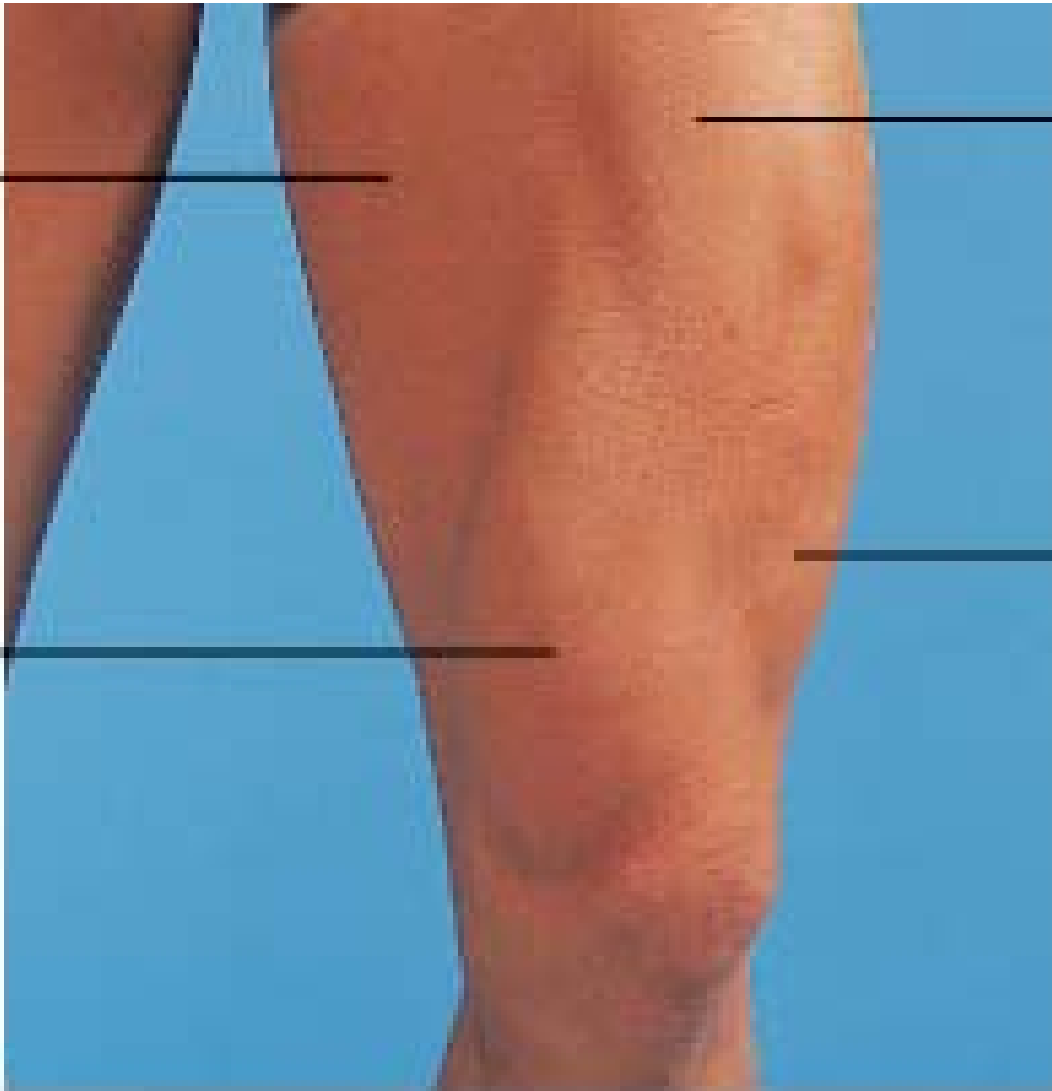




(b)

Adductor longus

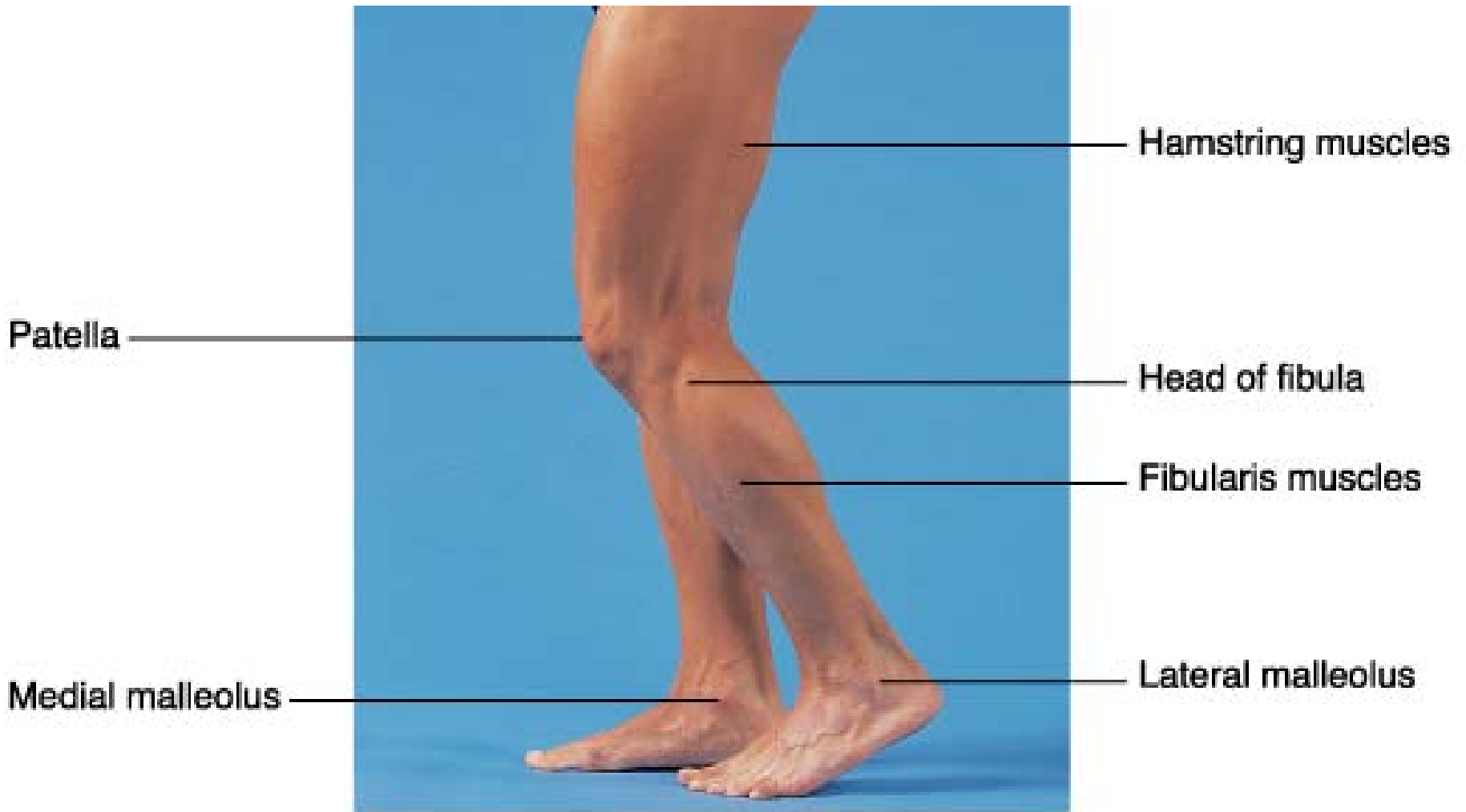
Vastus medialis



Rectus femoris

Vastus lateralis

(b)



Hamstring muscles:

Biceps femoris

Semitendinosus

Semimembranosus

Popliteal fossa

Gastrocnemius:

Lateral head

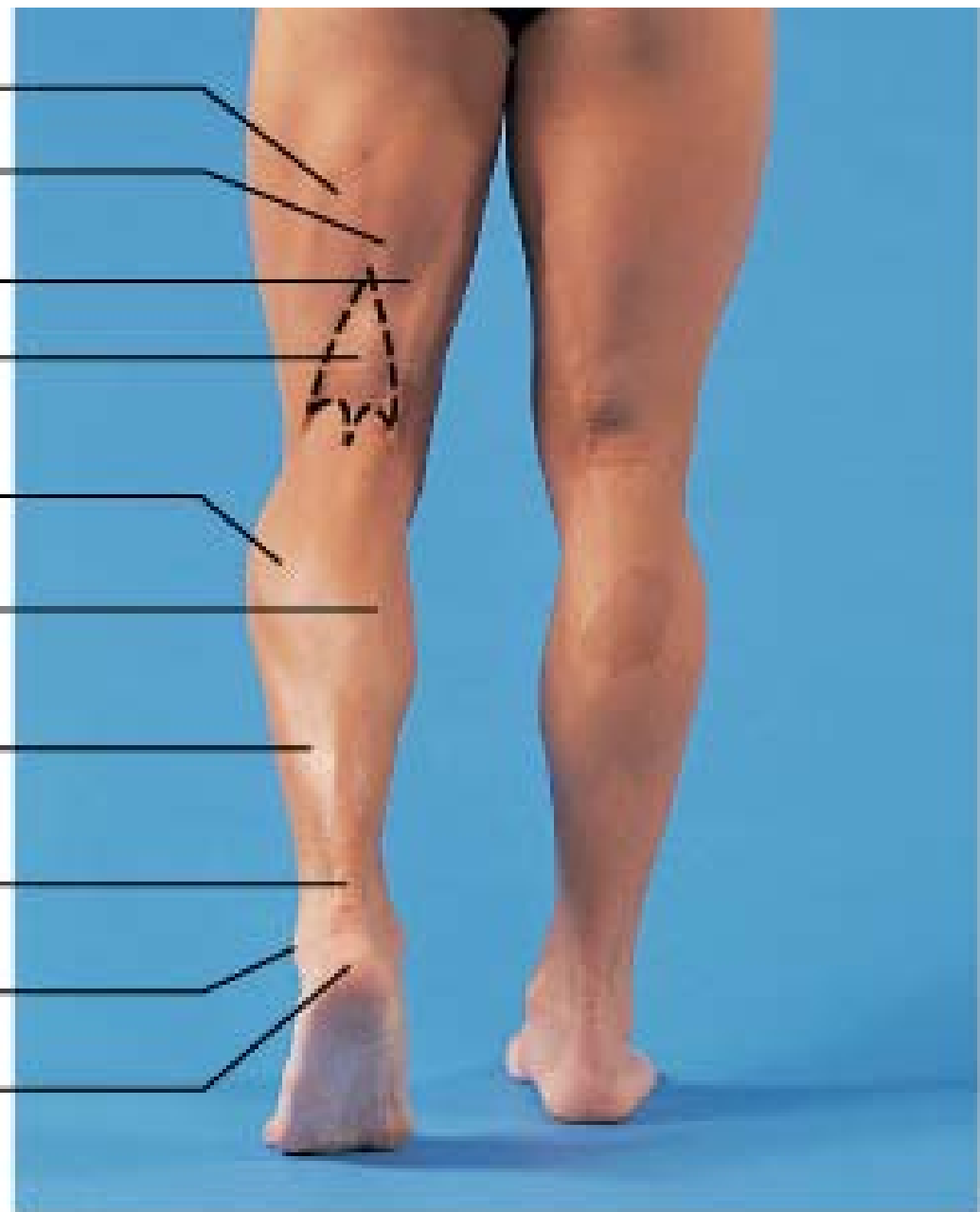
Medial head

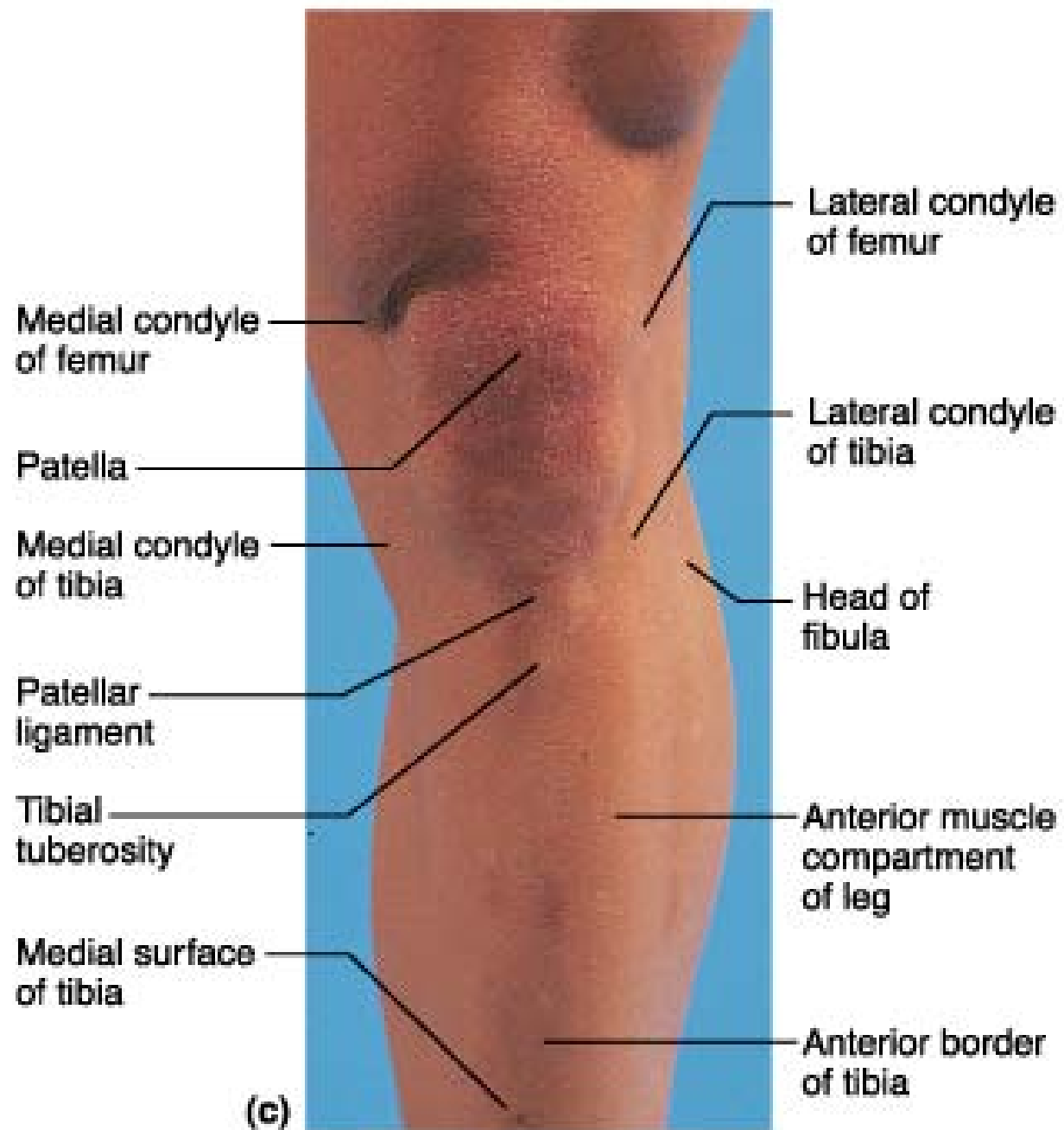
Soleus

Calcaneal tendon

Lateral malleolus

Calcaneus





Anterior border
of tibia

Medial surface
of tibia

Medial
malleolus

Dorsalis pedis
artery (pulse
point)

Tendon of
extensor hallucis
longus

(d)

Tibialis anterior
in anterior
muscle
compartment

Lateral
malleolus

Dorsal venous
arch

Tendons of
extensor
digitorum
longus

