



The Lower Limb



Anatomy

RHS 241

Lecture 2

Dr. Einas Al-Eisa

The bony pelvis

- Protective osseofibrous ring for the pelvic viscera
- Transfer of forces to:
 - acetabulum & head of femur (when standing)
 - ischial tuberosities (when sitting)
- Large surface area for the attachment of muscles

The bony pelvis

Orientation

- When in the anatomical position: the ASIS and pubic symphysis lie within the same vertical line

Articulations

- Anteriorly: Pubic symphysis
- Posteriorly: sacroiliac joints

What are the primary functions of the sacroiliac joints when in the anatomical position?

Innominate bone

```
graph TD; A[Innominate bone] --> B[Ilium]; A --> C[Ischium]; A --> D[Pubis]
```

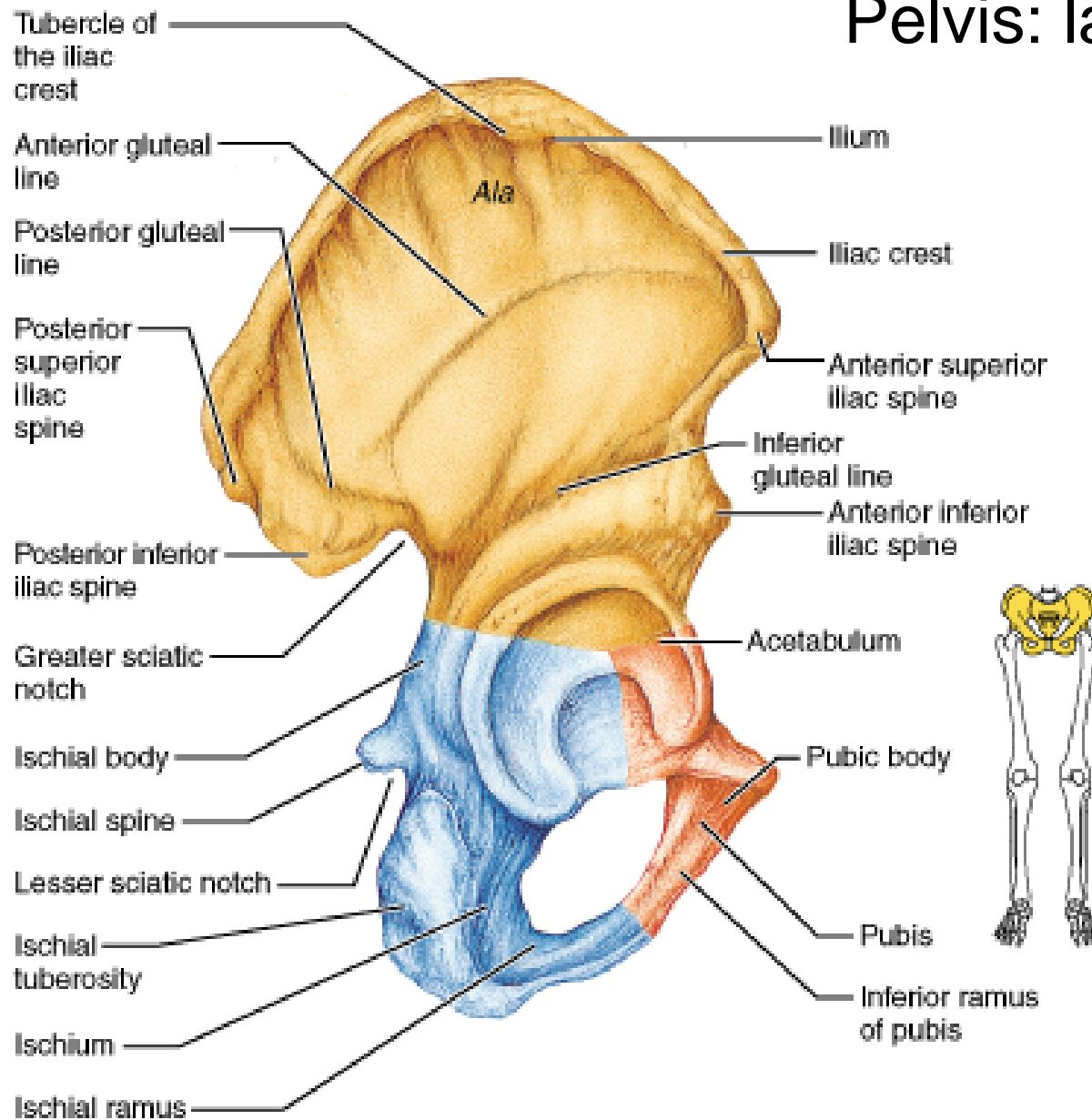
Ilium

Ischium

Pubis

Where (i.e., in which region approximately) does fusion of the three components of an innominate bone occur to form a single bone as seen in adults?

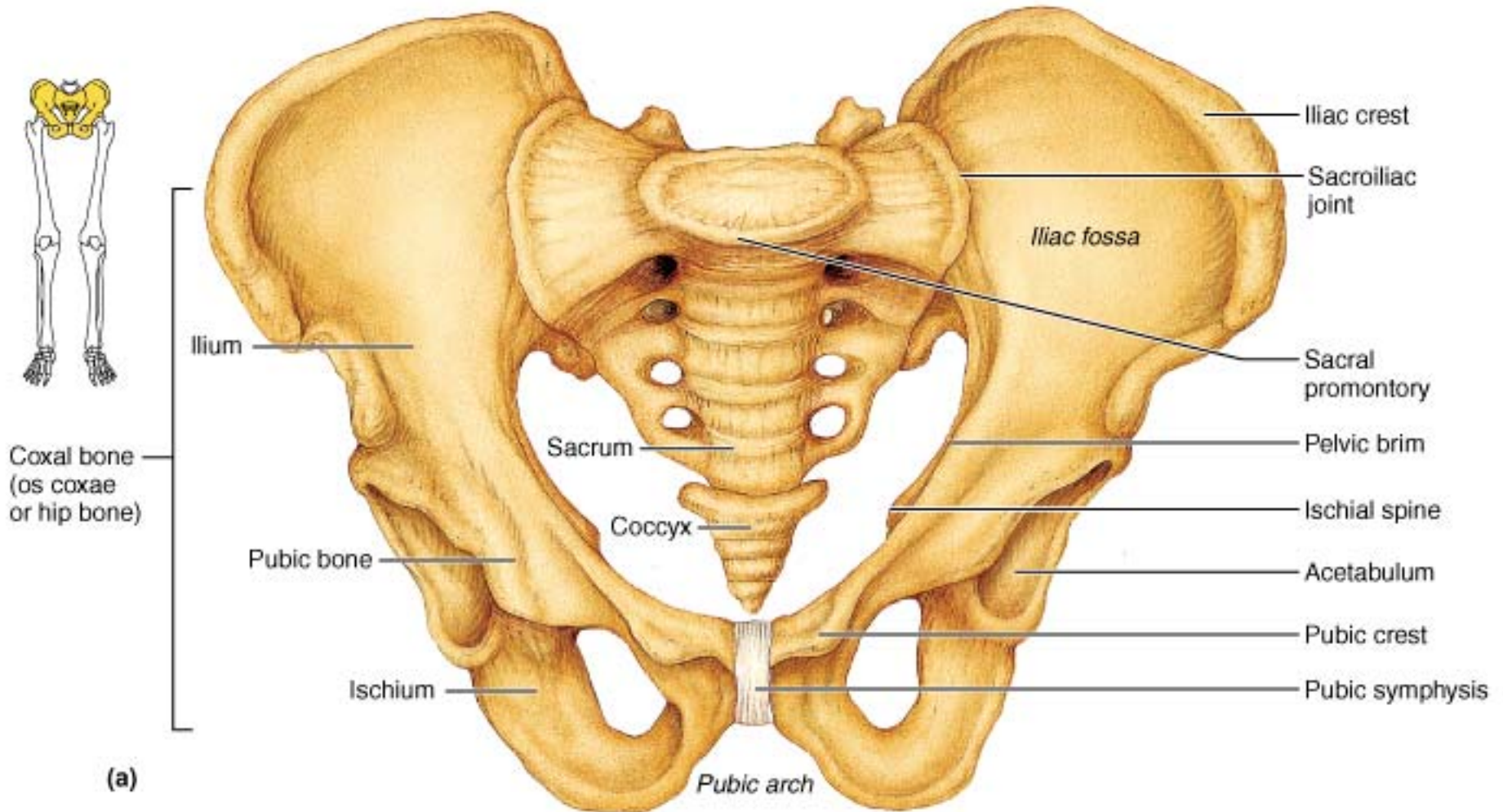
Pelvis: lateral view



(b)

Ilium

- **Iliac crest**
- **Anterior superior iliac spine (ASIS)**
- Anterior inferior iliac spine
- **Posterior superior iliac spine (PSIS)**
- Auricular surface (articular surface of SIJ)
- **Supracristal line**: joins the highest points of the iliac crests (to locate the position the spinous process of L4)

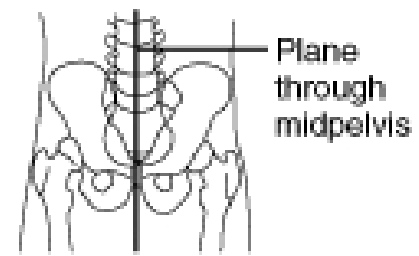


Pubis

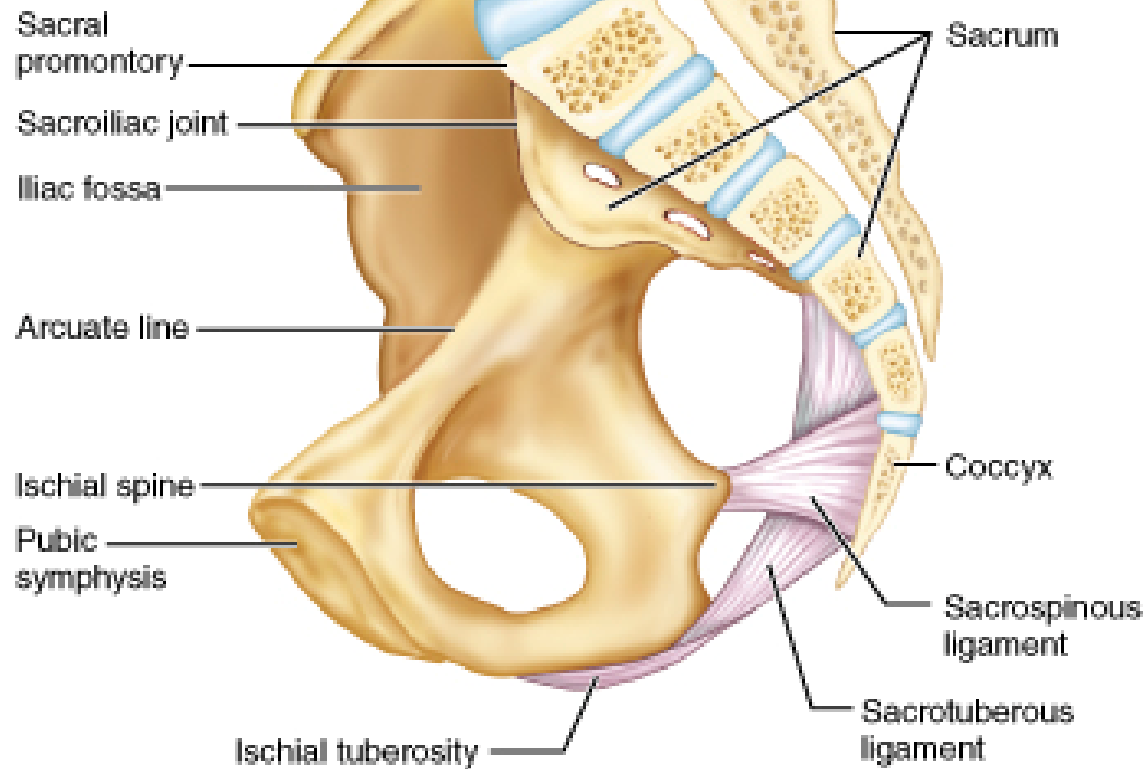
- Body
- Pubic crest (superior margin of the body)
- Pubic tubercles (prominent lateral eminence of pubic crest)
- Superior & inferior rami (project laterally from the body)

Ischium

- **Ischial tuberosity**
- **Greater sciatic notch** (superior to the iliac spine)
- **Lesser sciatic notch** (inferior to the iliac spine)

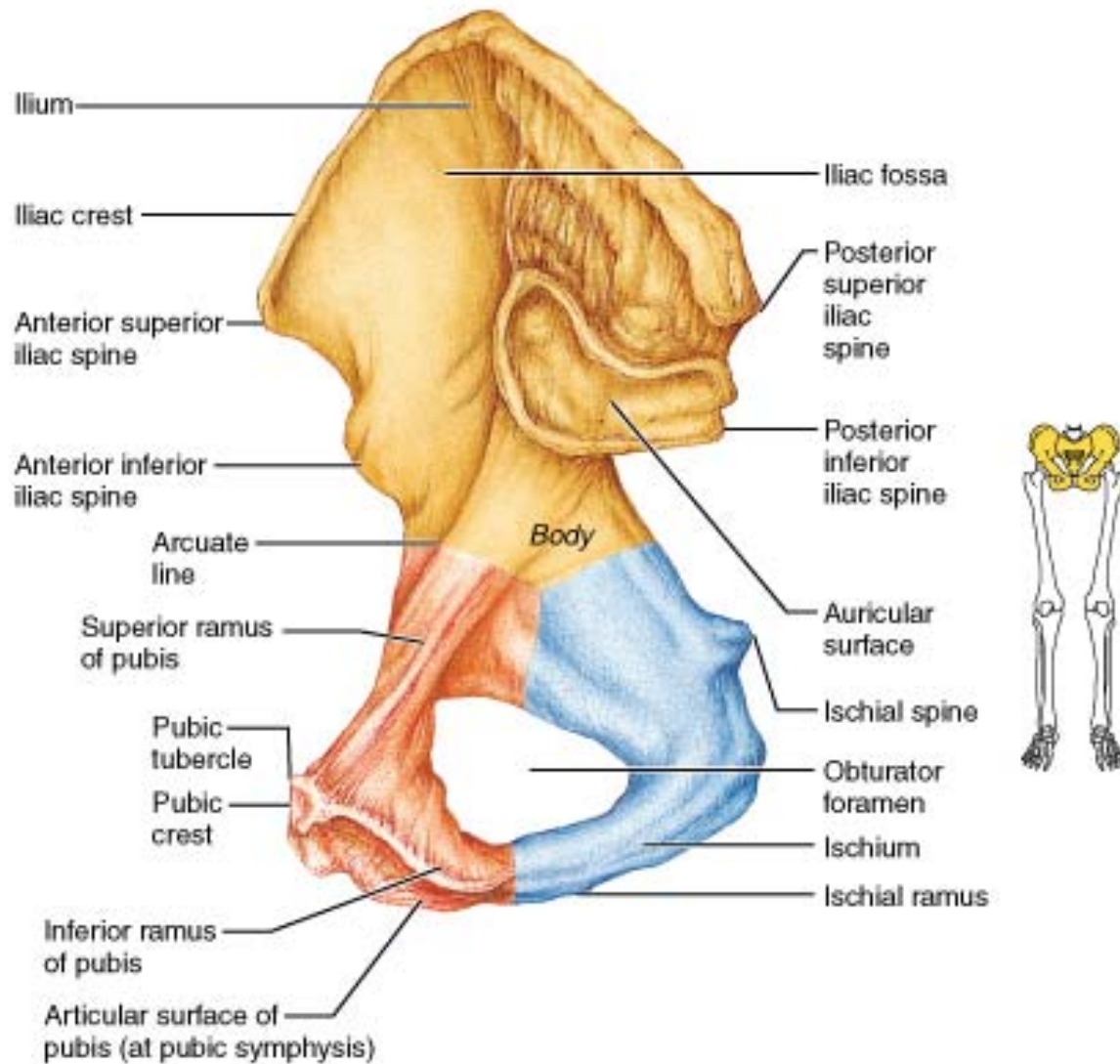


← Anterior



(a)

Pelvis: medial view



(c)

Table 8.2**Comparison of the Male and Female Pelves**

Characteristic	Female	Male
General structure and functional modifications	Tilted forward; adapted for childbearing; true pelvis defines the birth canal; cavity of the true pelvis is broad, shallow, and has a greater capacity	Tilted less far forward; adapted for support of a male's heavier build and stronger muscles; cavity of the true pelvis is narrow and deep
Bone thickness	Less; bones lighter, thinner, and smoother	Greater; bones heavier and thicker, and markings are more prominent
Acetabula	Smaller; farther apart	Larger; closer
Pubic angle/arch	Broader (80° to 90°); more rounded	Angle is more acute (50° to 60°)

Anterior view

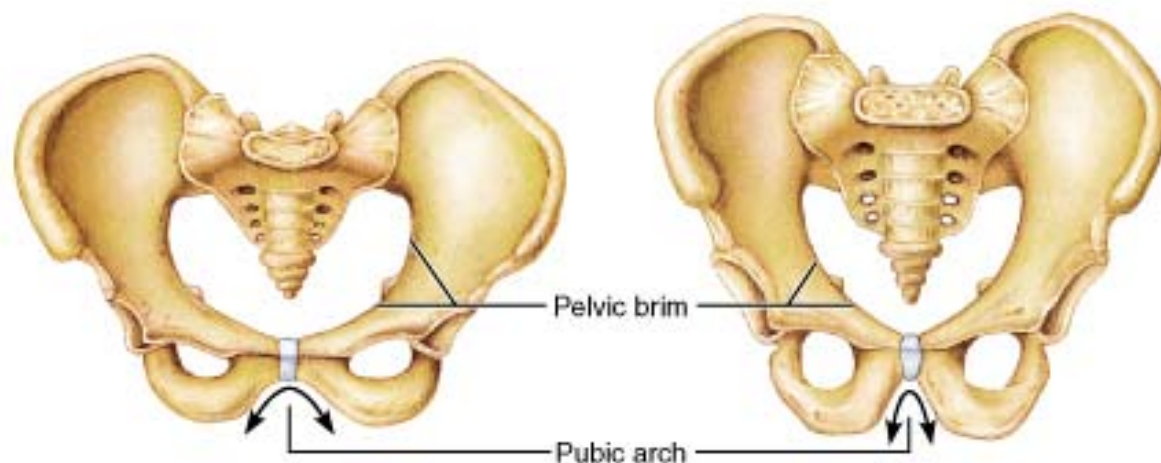
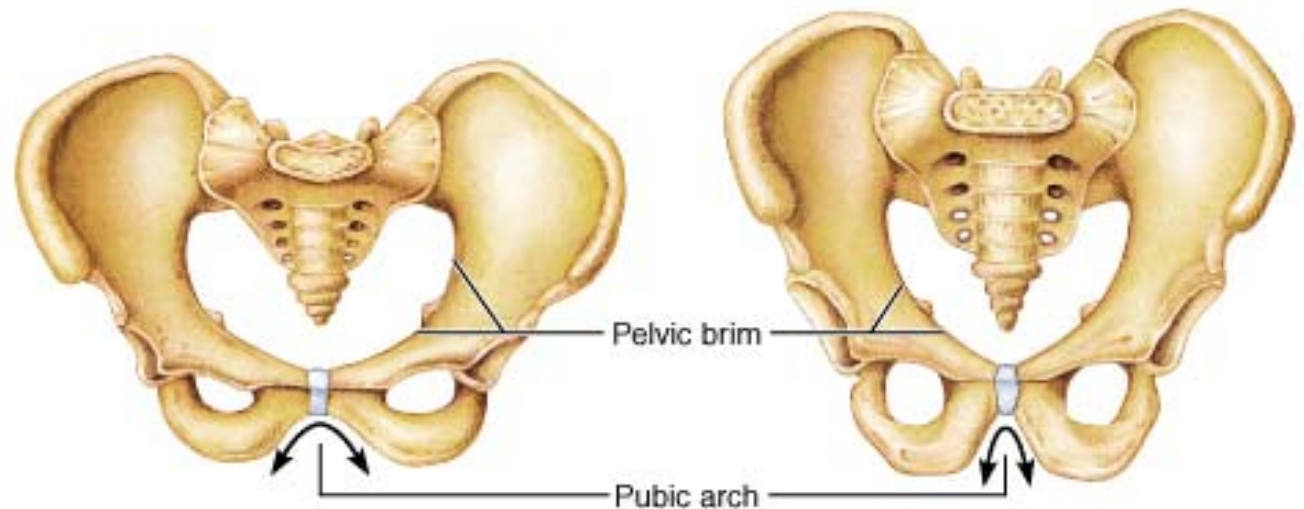


Table 8.2**Comparison of the Male and Female Pelves**

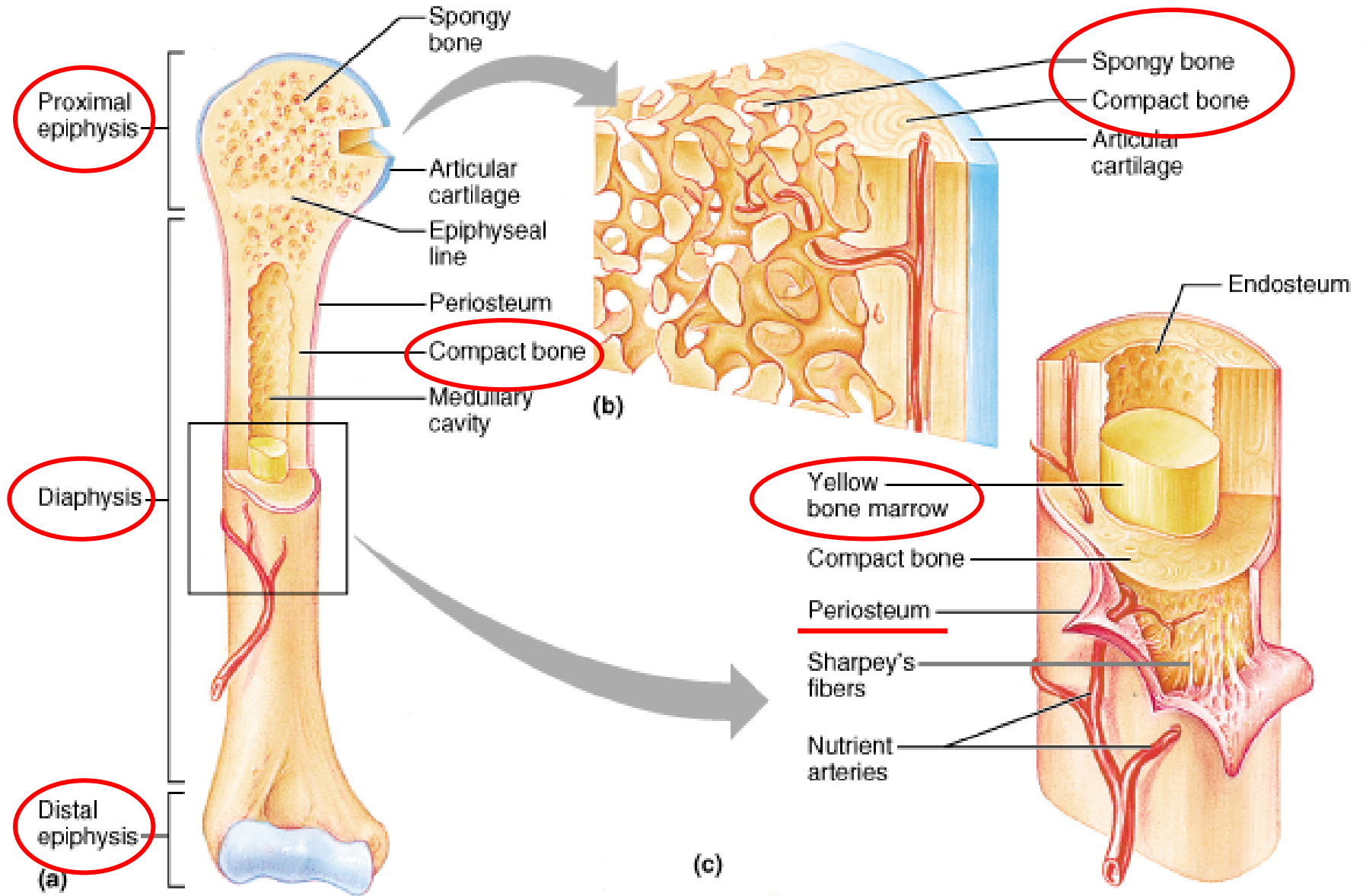
Characteristic	Female	Male
Sacrum	Wider; shorter; sacral curvature is accentuated	Narrow; longer; sacral promontory more ventral
Coccyx	More moveable; straighter	Less moveable; curves ventrally
Pelvic inlet (brim)	Wider; oval from side to side	Narrow; basically heart-shaped
Pelvic outlet	Wider; ischial tuberosities shorter, farther apart and everted	Narrower; ischial tuberosities longer, sharper, and point more medially



Femur

- Long bone:
 - Shaft (**diaphysis**)
 - Enlarged proximal & distal ends (**epiphysis**)
- **Angle of obliquity**: in the anatomical position, the distal ends are closer to midline than proximal ends (more in females)

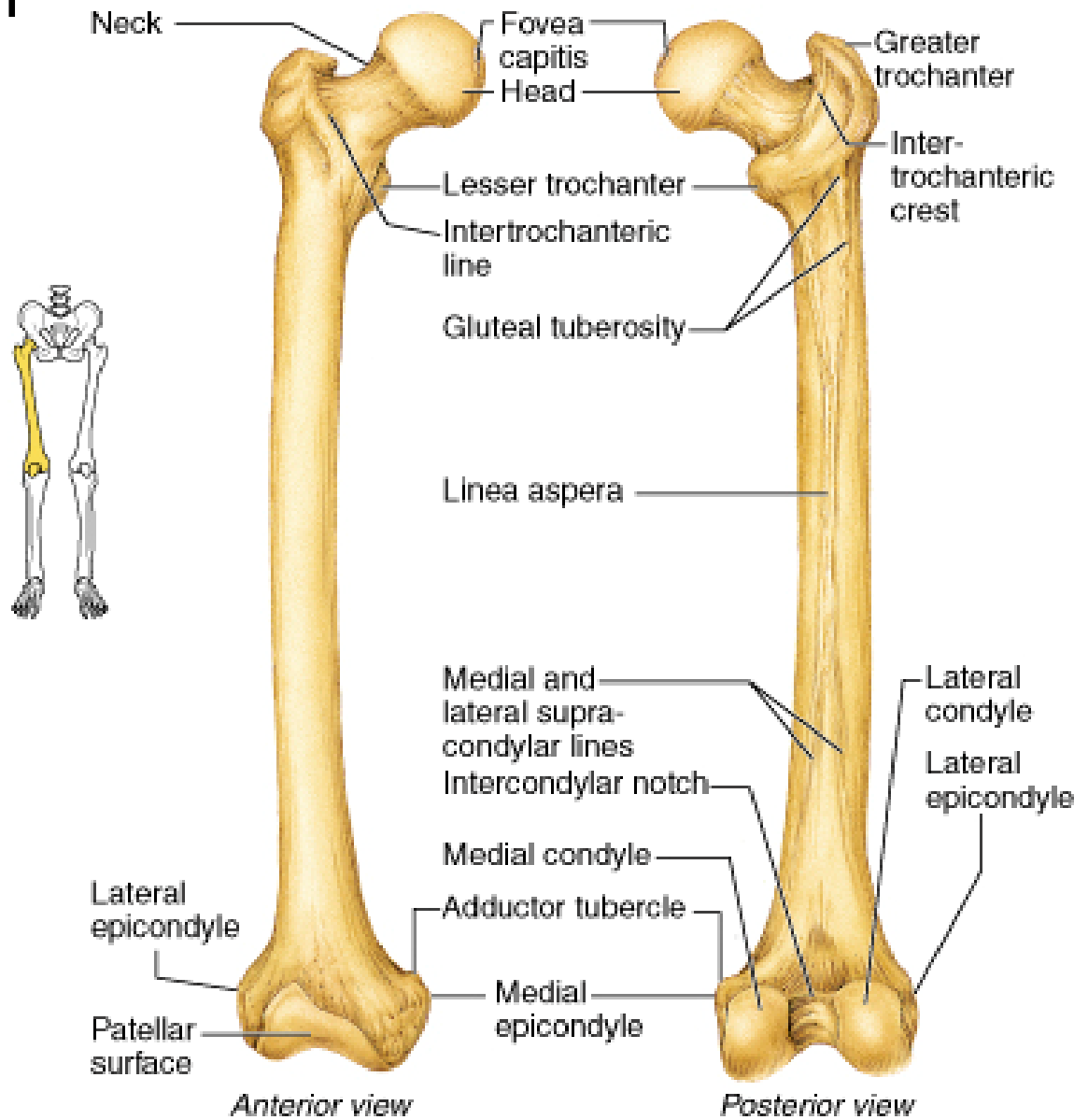
Long Bones



Femur- proximal end

- **Head**: articulates with acetabulum (hip J)
- **Pit** (fovea of head): attachment of a ligament
- **Neck**: directed laterally, downward, & posteriorly (common site of fractures)

Right femur



(b) Femur

Femur- proximal end

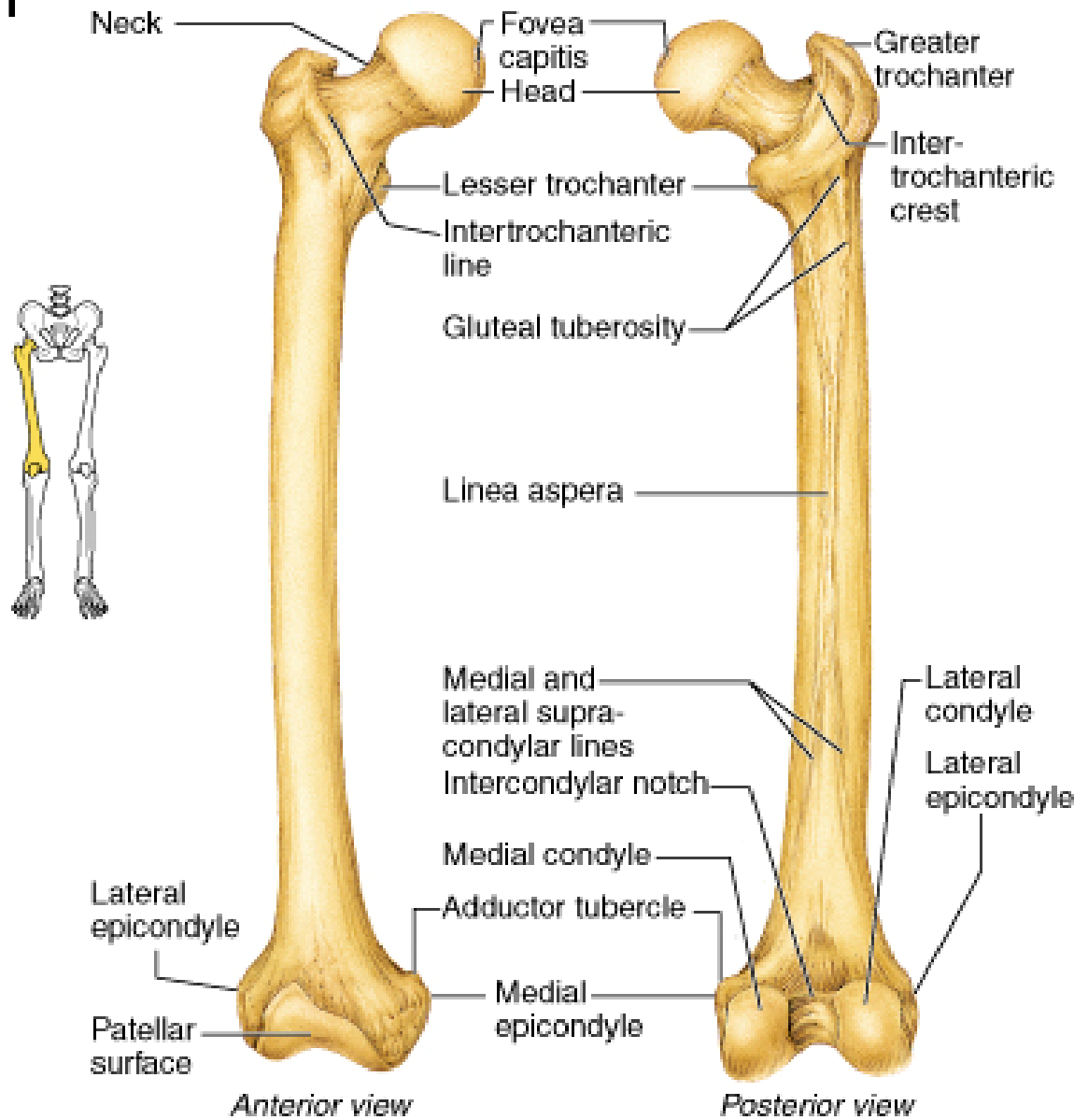
- **Greater trochanter:** attachment of muscles
- **Lesser trochanter:** attachment of muscles

- **Intertrochanteric line:**
anterior at the junction of the neck & shaft
- **Intertrochanteric crest:** prominent;
posterior at the junction of the neck & shaft

Femur- shaft

- **Linea aspera**: posterior (roughened by the attachment of thigh muscles)
- **Popliteal surface**: posterior
- **Supracondylar lines**: medially & laterally

Right femur



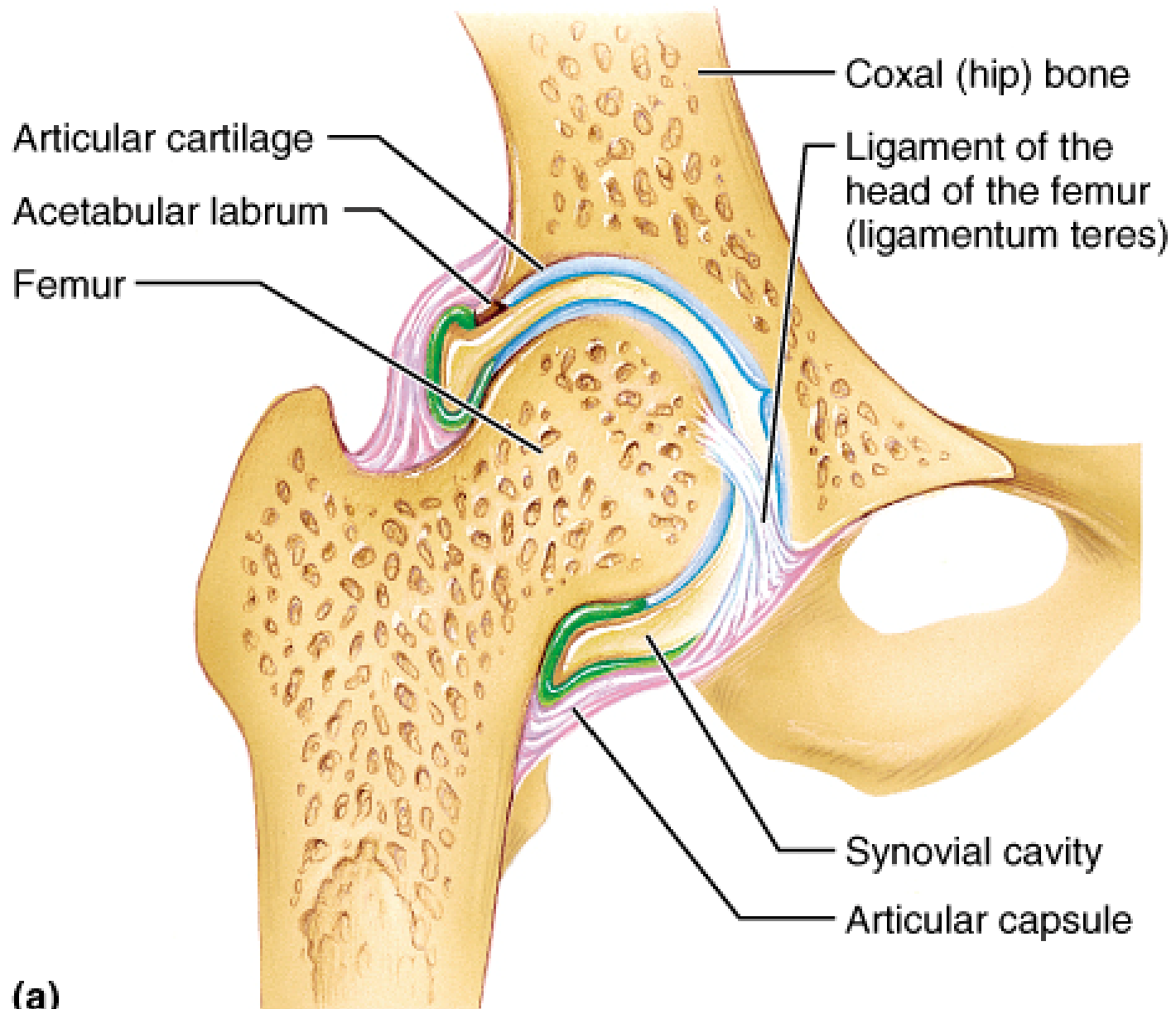
(b) Femur

Femur- distal end

- Why is the distal end of femur enlarged?
- **Medial & lateral condyles**: articulate with the tibia (knee joint)
- **Intercondylar notch** (fossa): posterior
- **Patellar surface**: anterior (articulates with the patella to form the femoropatellar joint)

Hip joint

- Synovial
- Ball & socket (multiaxial)
- Articular surfaces:
 - Head of femur
 - Lunate surface of acetabulum (U-shaped)
 - Acetabular labrum: complete ring of fibrocartilage



(a)

What function is served by the acetabular labrum?

Ligaments

- Capsular ligaments of the hip are strong and taut (particularly in the extended position)
- The joint is most vulnerable to **dislocation** when in flexion and external rotation (e.g., sitting in a car)

Ligaments

- **Iliofemoral:**

- anterior

- two bands of fibers (medial & lateral)

- known clinically as the 'Y' ligament of Bigelow

- ASIS to intertrochanteric line

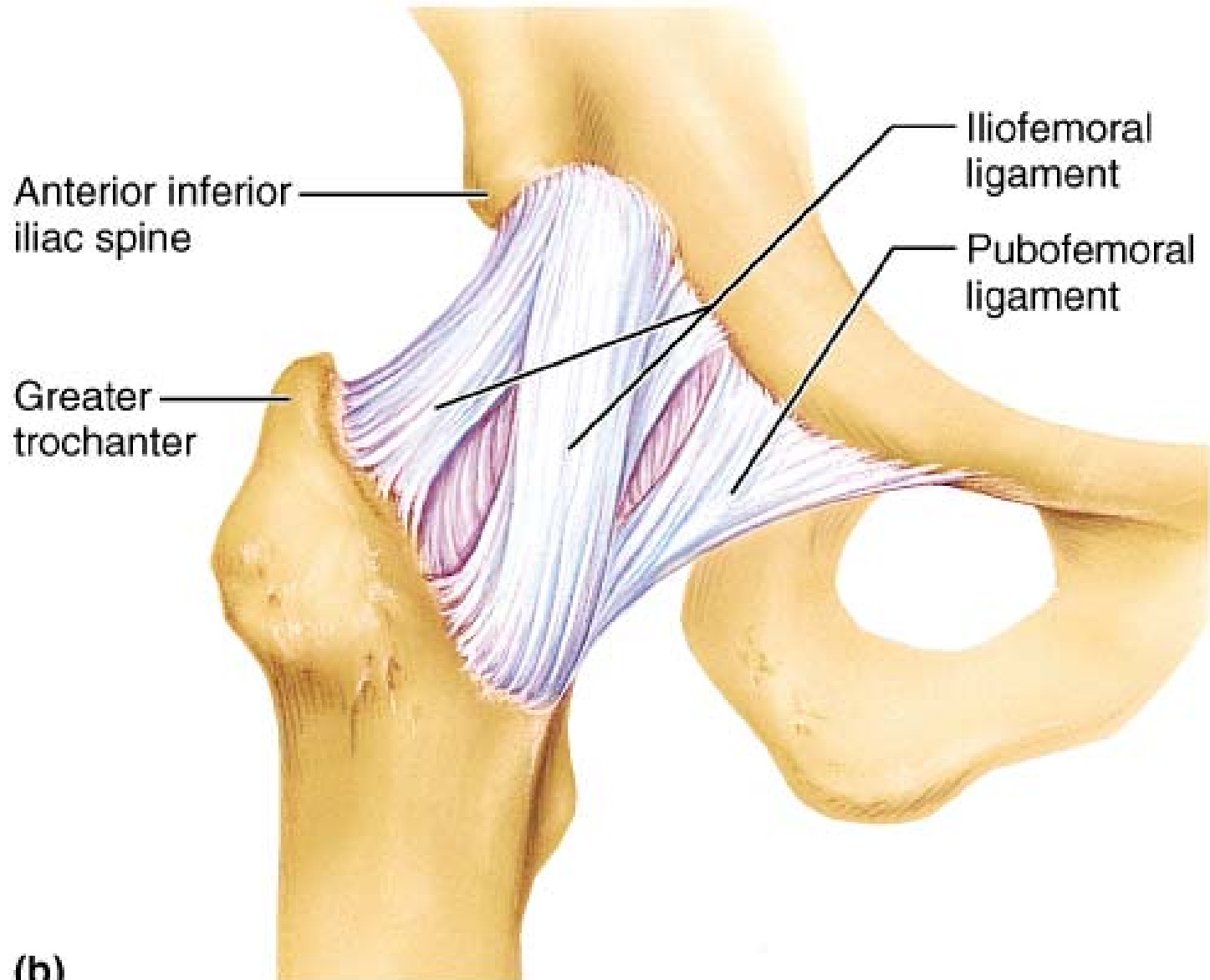
- prevent overextension of hip

Ligaments

- **Pubofemoral:**

- anterior & inferior
- extends laterally from the pubic bone to the intertrochanteric line
- prevent over-abduction

Hip Joint: Anterior View



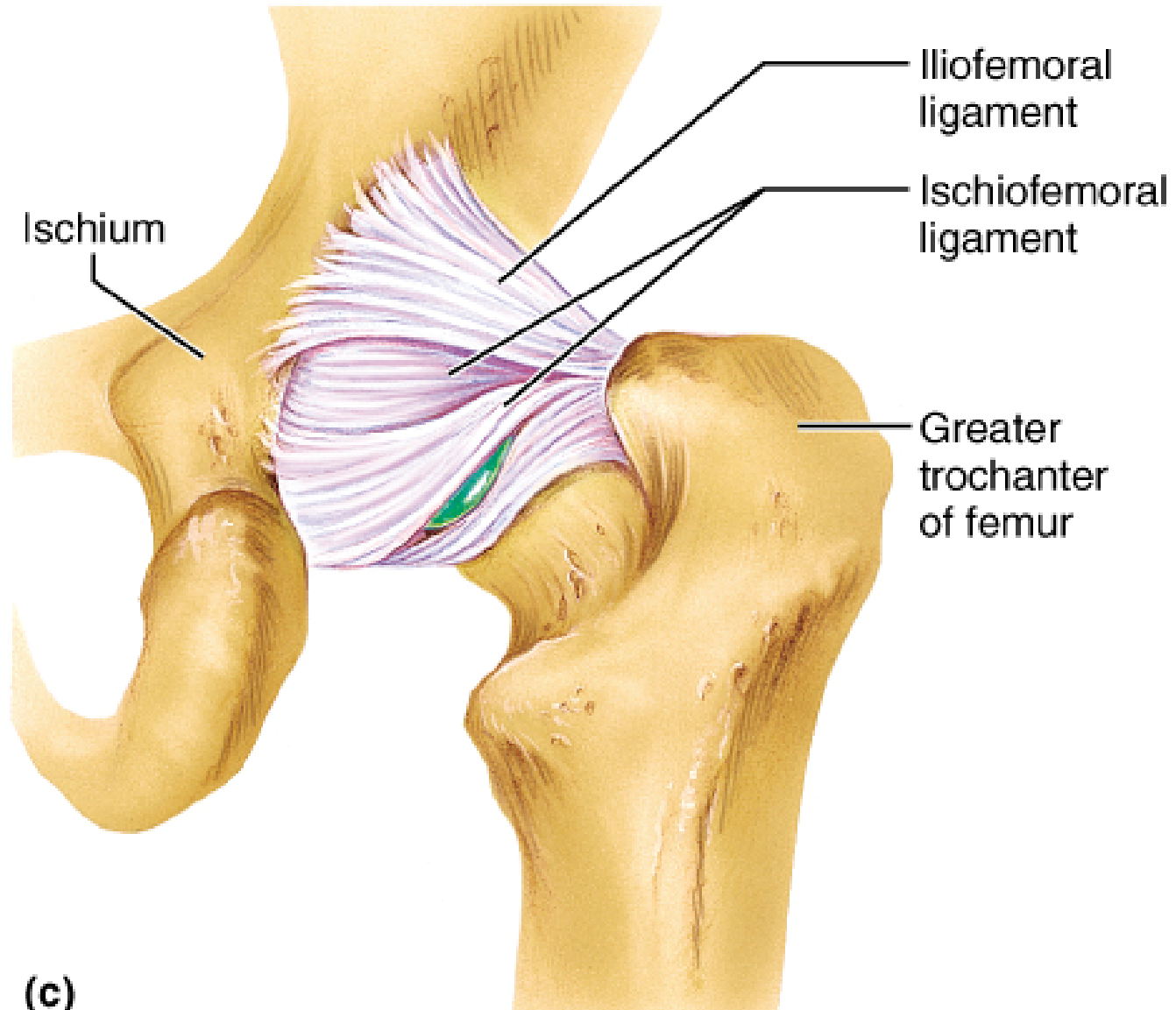
(b)

Ligaments

- **Ischiofemoral:**

- posterior
- from the ischium, arches forward over the neck of the femur
- attaches anteriorly to the intertrochanteric line
- prevent hyperextension of hip

Hip Joint: Posterior View



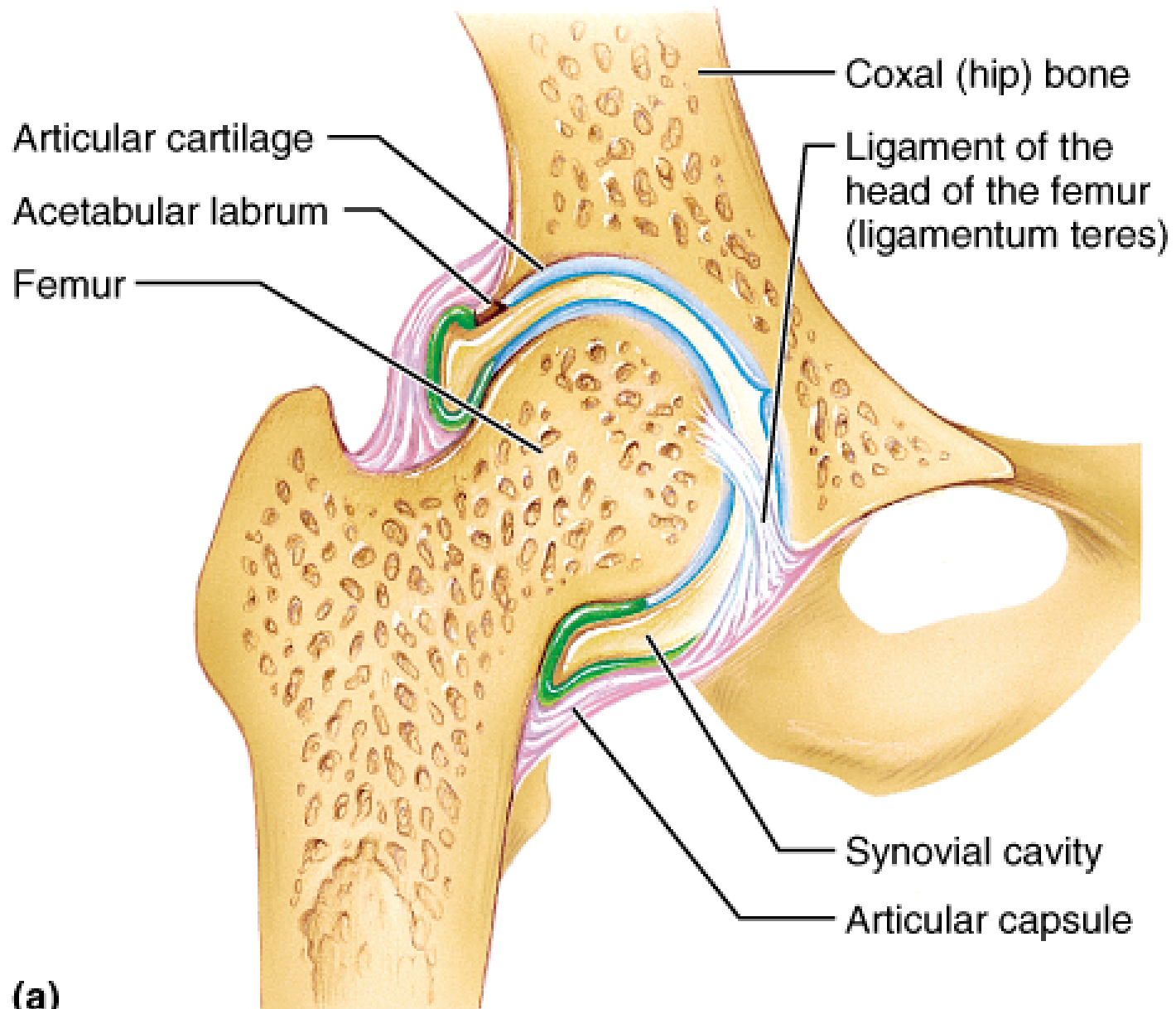
(c)

Ligaments

- **Transverse ligament of the acetabulum:**
 - inferior
 - bridges the ends (horns) of the lunate articular surface

Ligaments

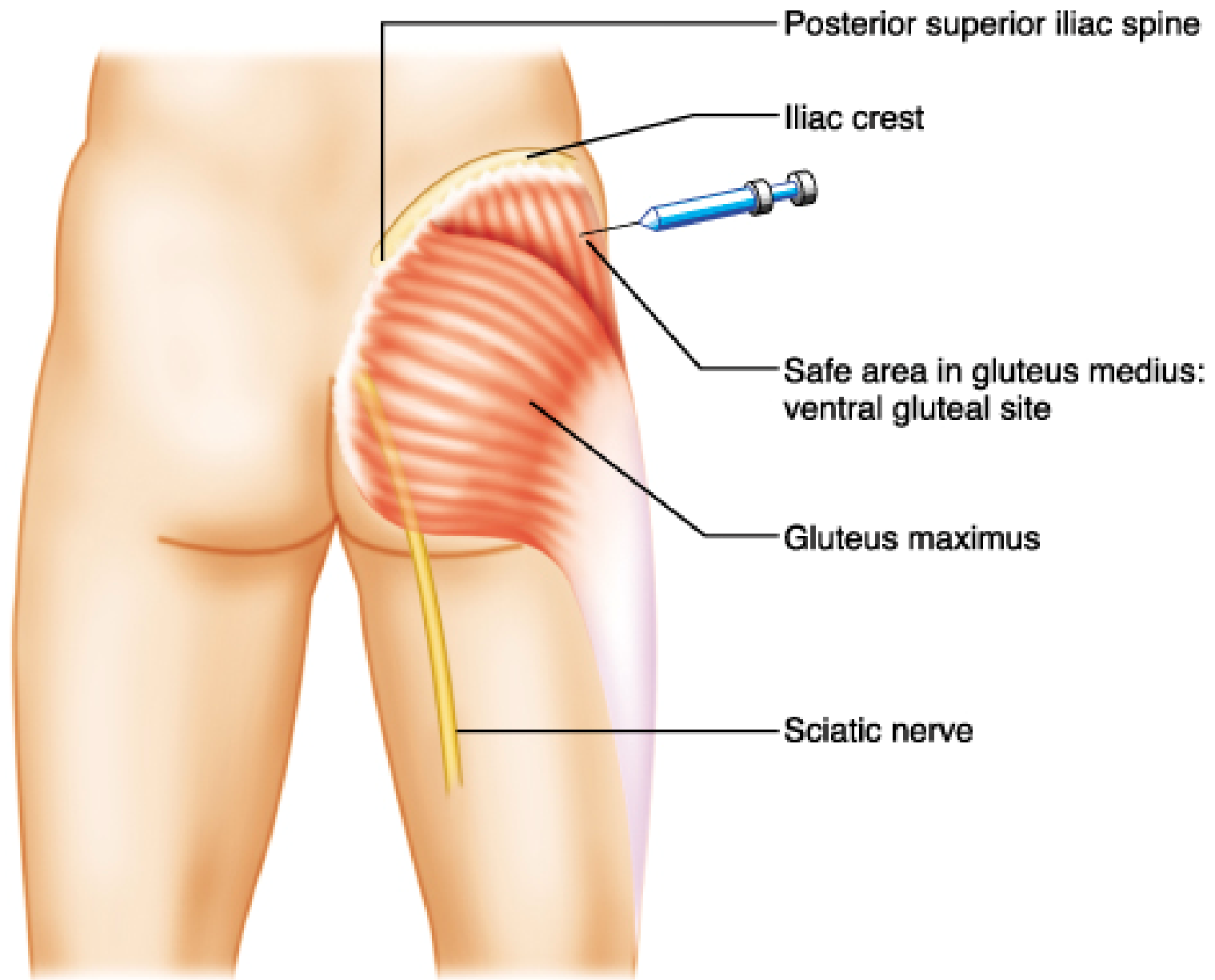
- **Ligament of the head of femur:**
 - Carries a blood vessel to the femoral head
 - Attached to the pit (fovea) of the femur



(a)

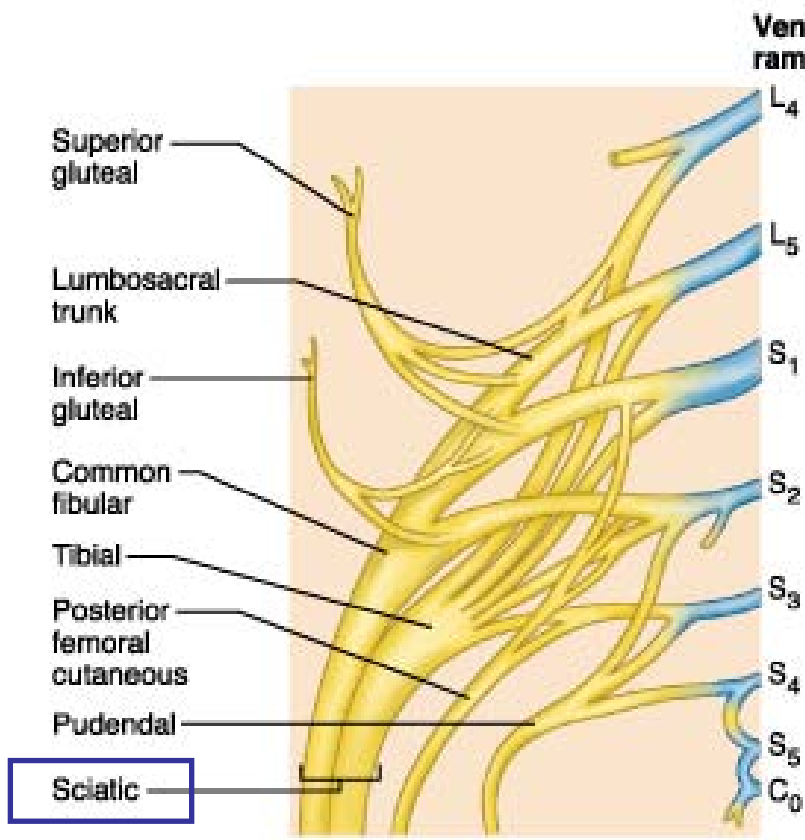
Gluteal region

- **Sciatic nerve** enters the gluteal region near the midpoint of a line joining the PSIS & ischial tuberosity
- Common site for intramuscular injections: upper lateral quadrant (to avoid damage to the sciatic nerve)

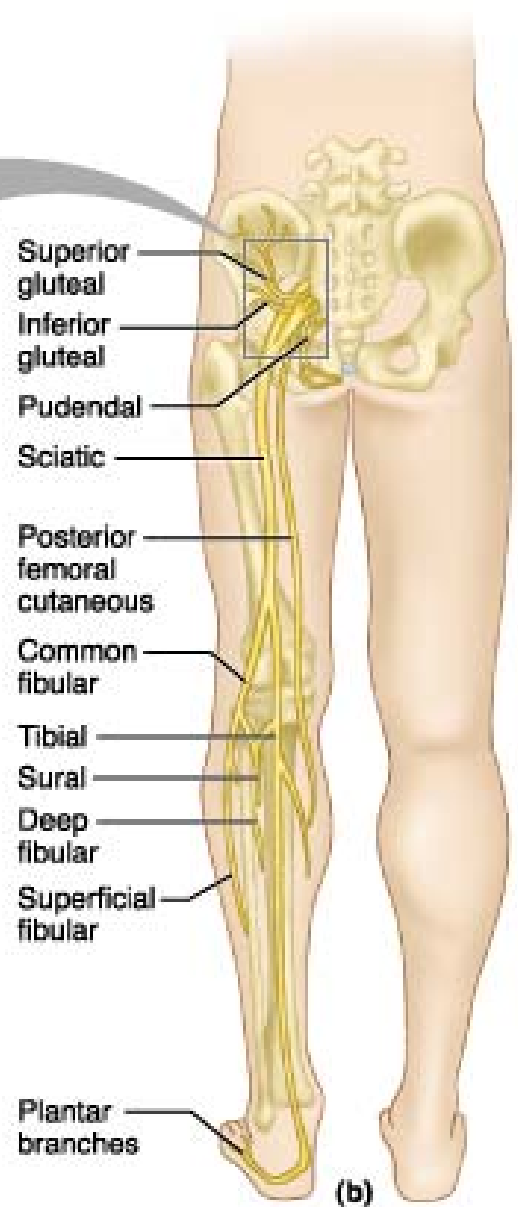


(b)

Sacral Plexus



(a)



(b)

Key:

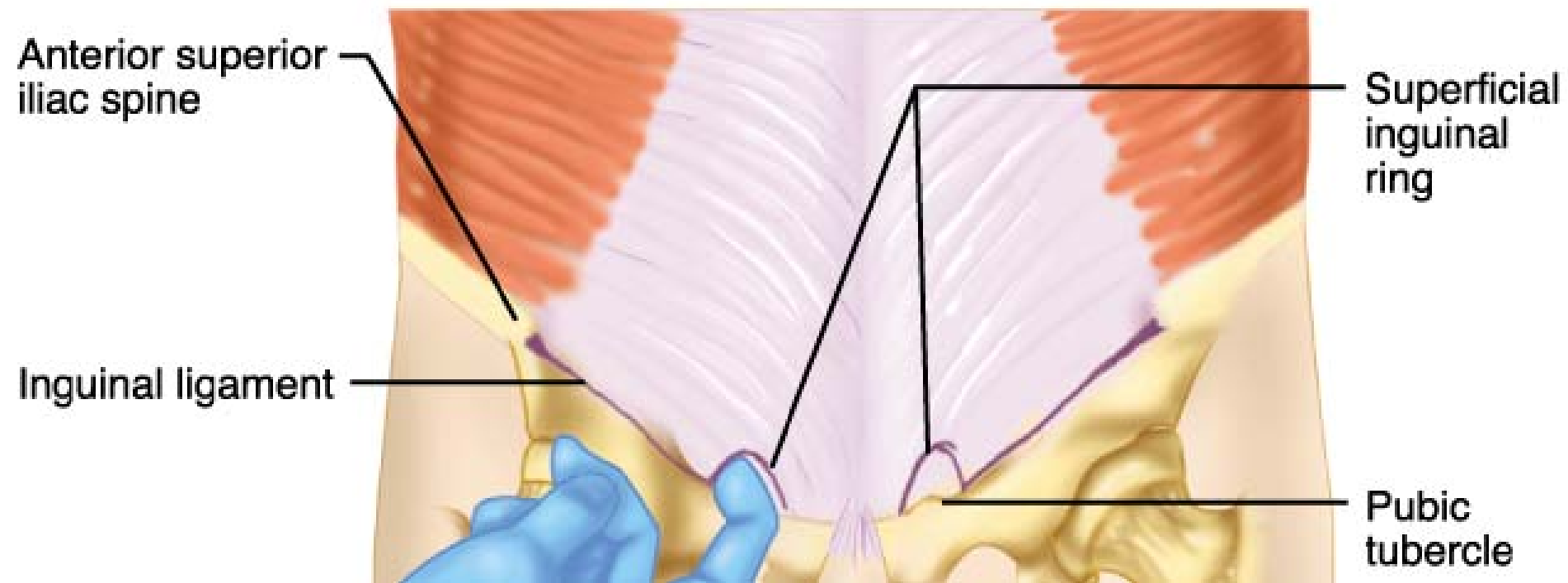
 = Ventral rami

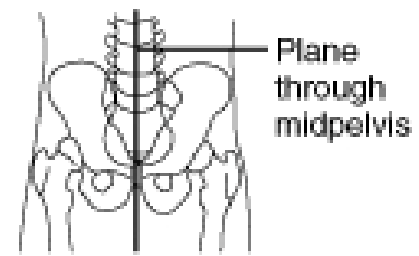
Routes for neurovascular structures from the pelvis to gluteal region & thigh

= osseofibrous spaces or holes through which nerves and blood vessels enter and leave the thigh from the pelvis

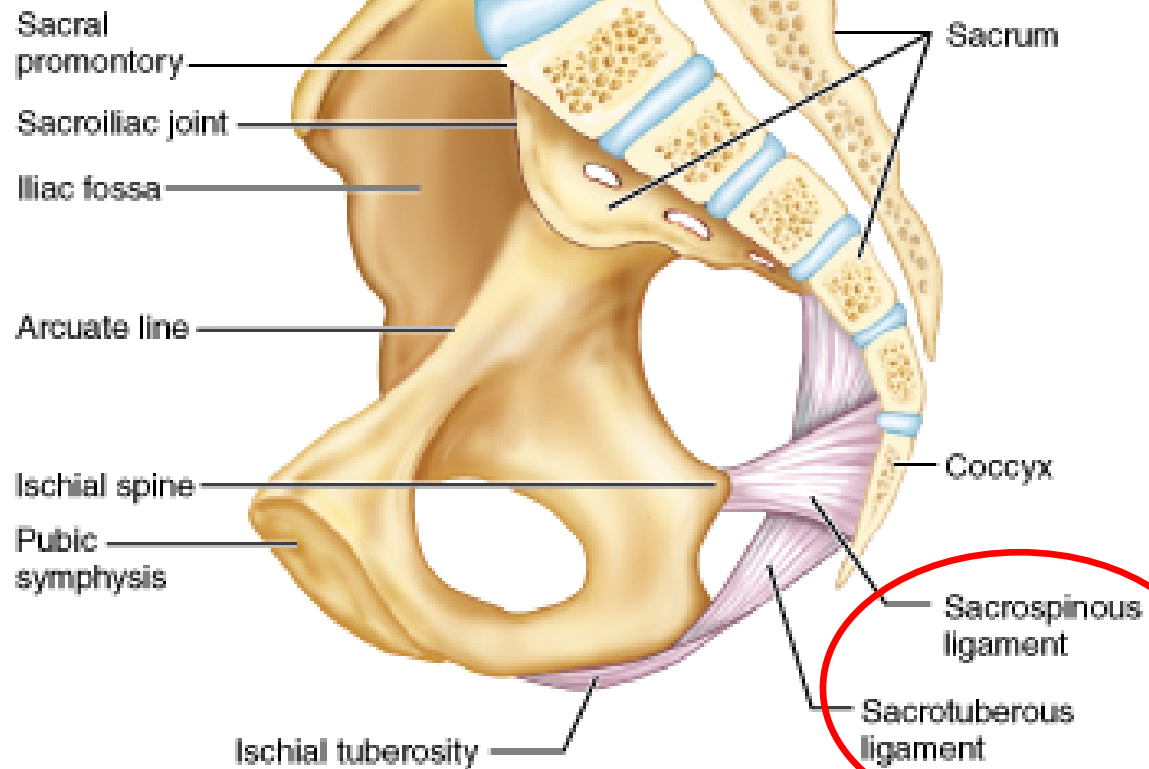
Routes for neurovascular structures

- **Inguinal route:** formed by the inguinal ligament and the innominate bone (anterior)
- **Obturator route:** the opening or canal within the obturator membrane
- **Gluteal route:** osseofibrous ring formed by the greater sciatic notch and accessory ligaments of the SIJc





← Anterior

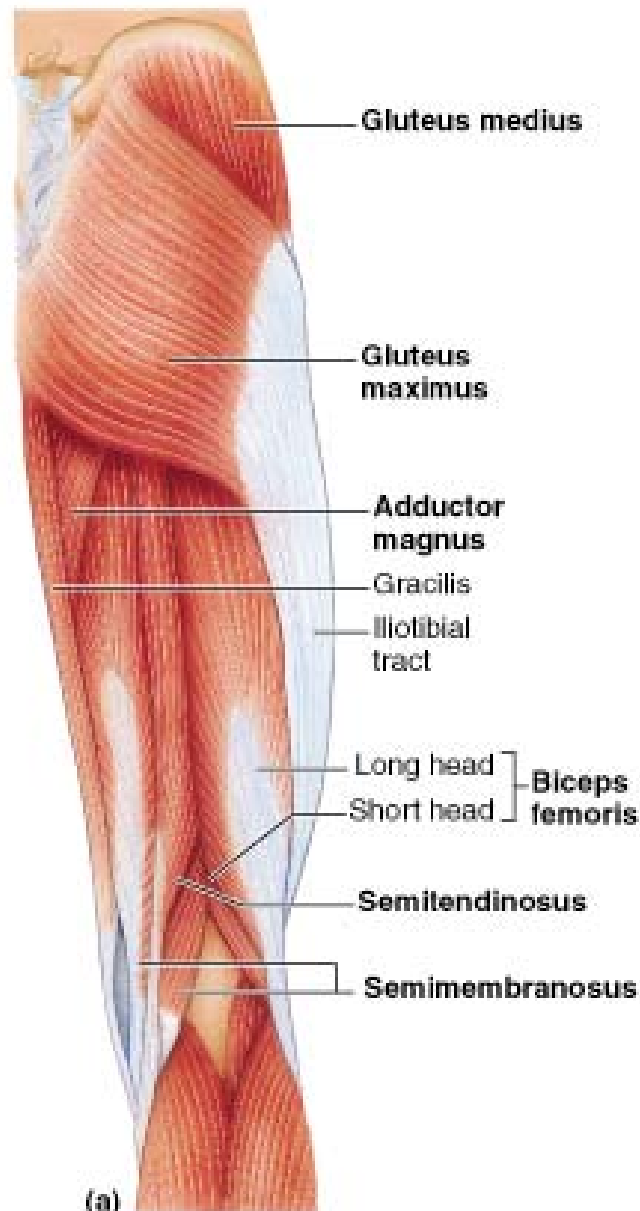


(a)

Muscles of the gluteal region

- Gluteus maximus:
 - inferior gluteal nerve
 - extension & lateral rotation
- Gluteus medius:
 - superior gluteal nerve
 - abduction
- Gluteus minimus: superior gluteal nerve

Gluteal Region & Posterior thigh



Muscles of the gluteal region

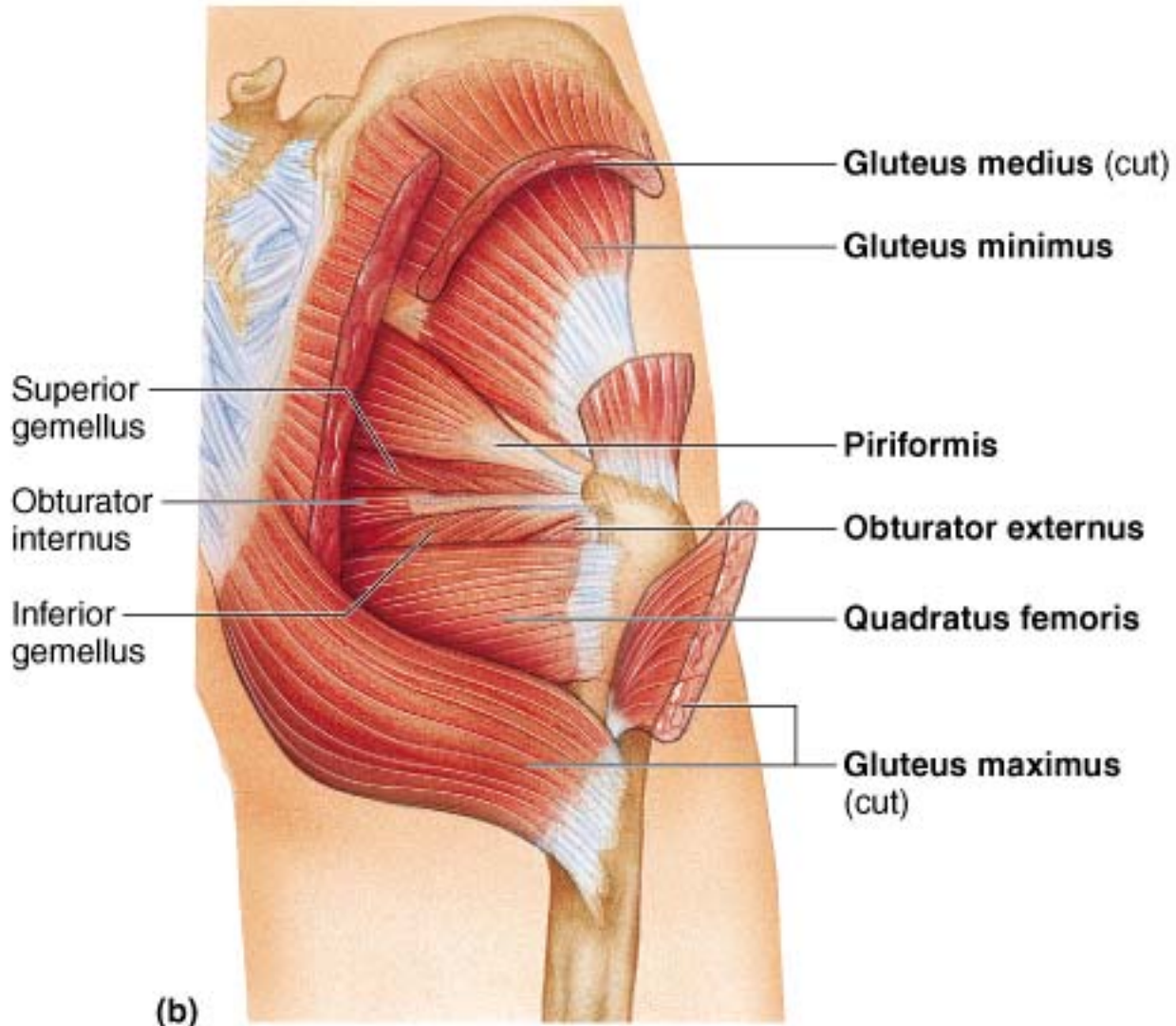
- **Gluteus medius & minimus**: chief abductors (on a free limb)
- During walking, they contract on the weight-bearing side to prevent the pelvis on the non-weight-bearing side from dropping
- **Trendelenburg gait?**

When standing on both feet and shifting your weight from one limb to the other, on which side are the gluteus medius & minimus contracting?

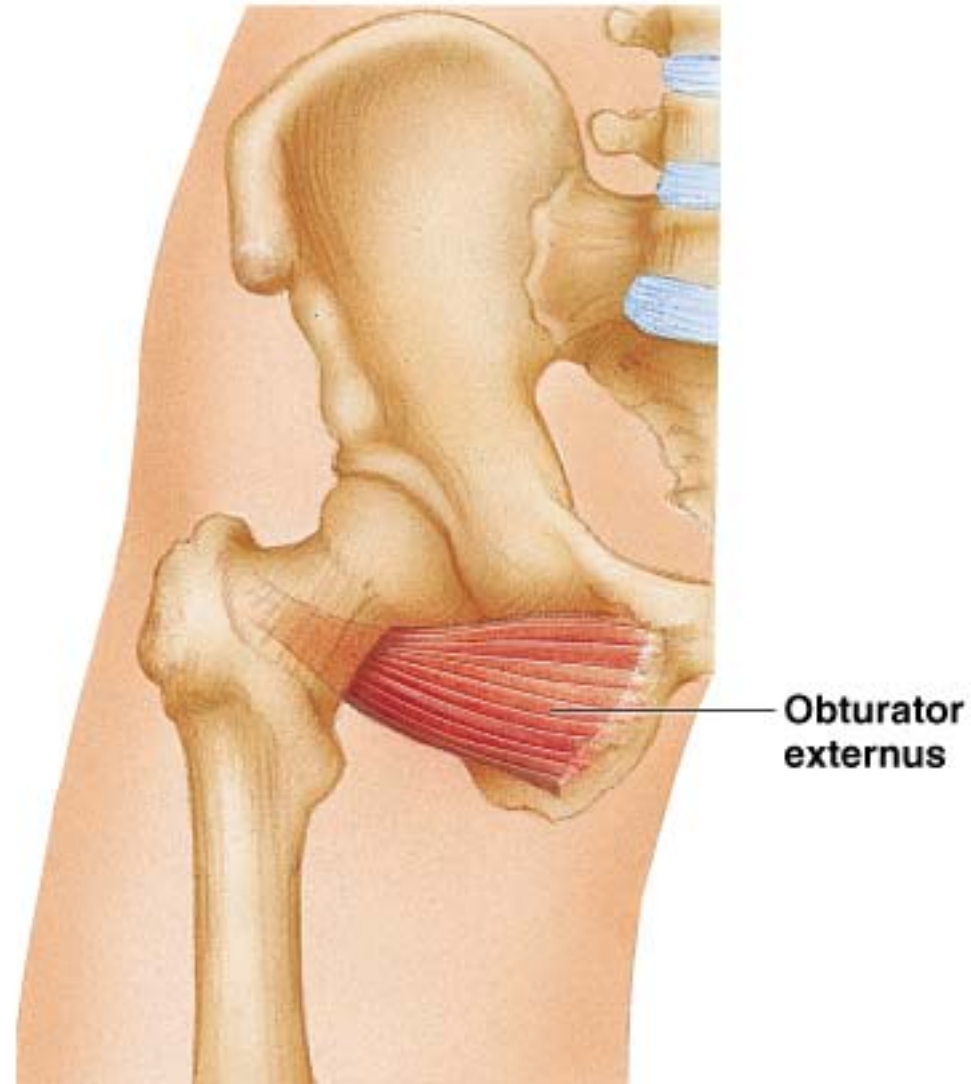
Short lateral rotators of the thigh

- **Piriformis** (anterior surface of sacrum to greater trochanter)
- **Obturator internus** (to greater trochanter)
- **Obturator externus** (to greater trochanter)
- The **gemelli** muscles (superior & inferior)
- **Quadratus femoris** (ischial tuberosity to intertrochanteric crest)

Gluteal Region



Gluteal Region: Deep



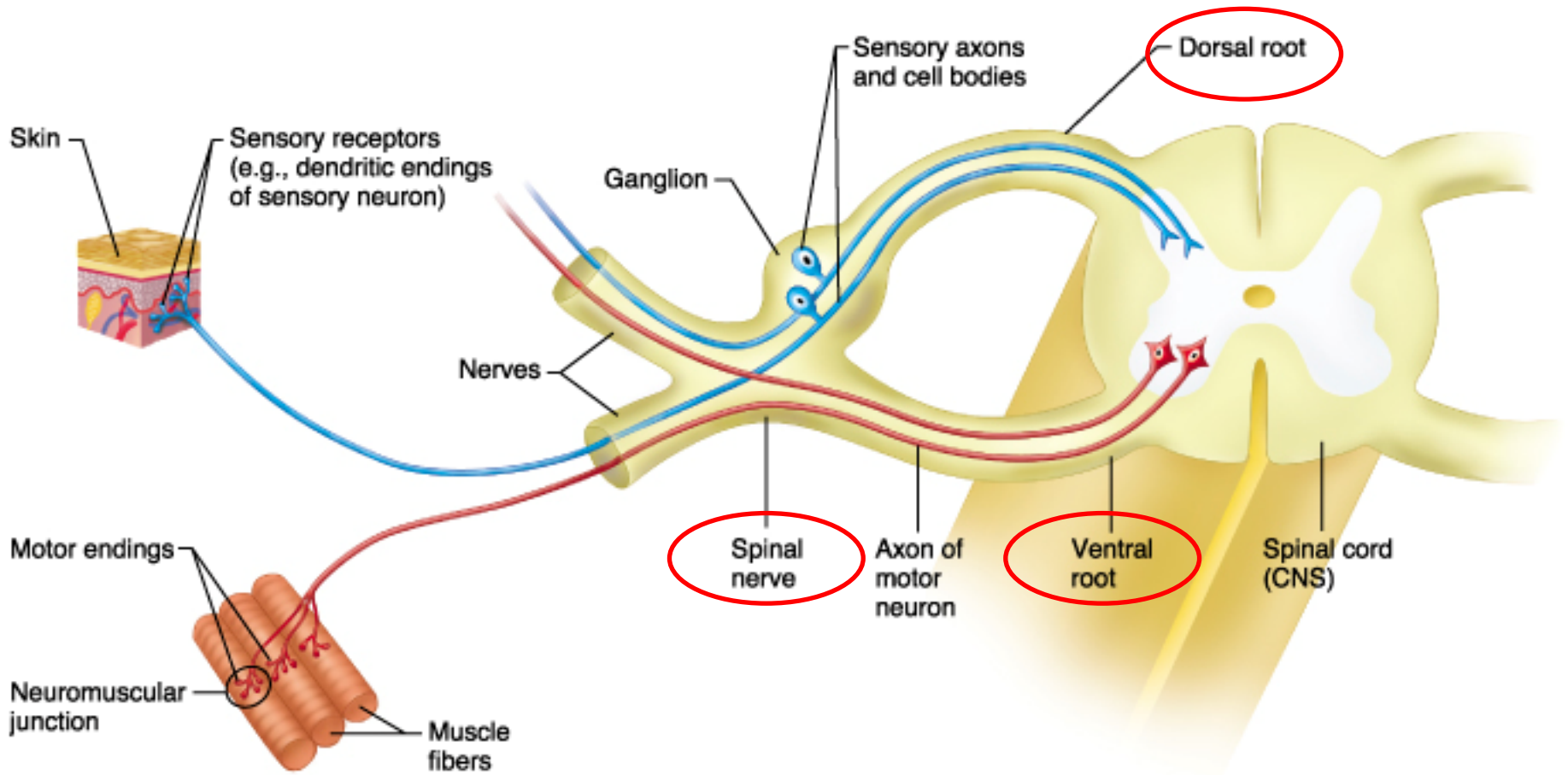
(c)

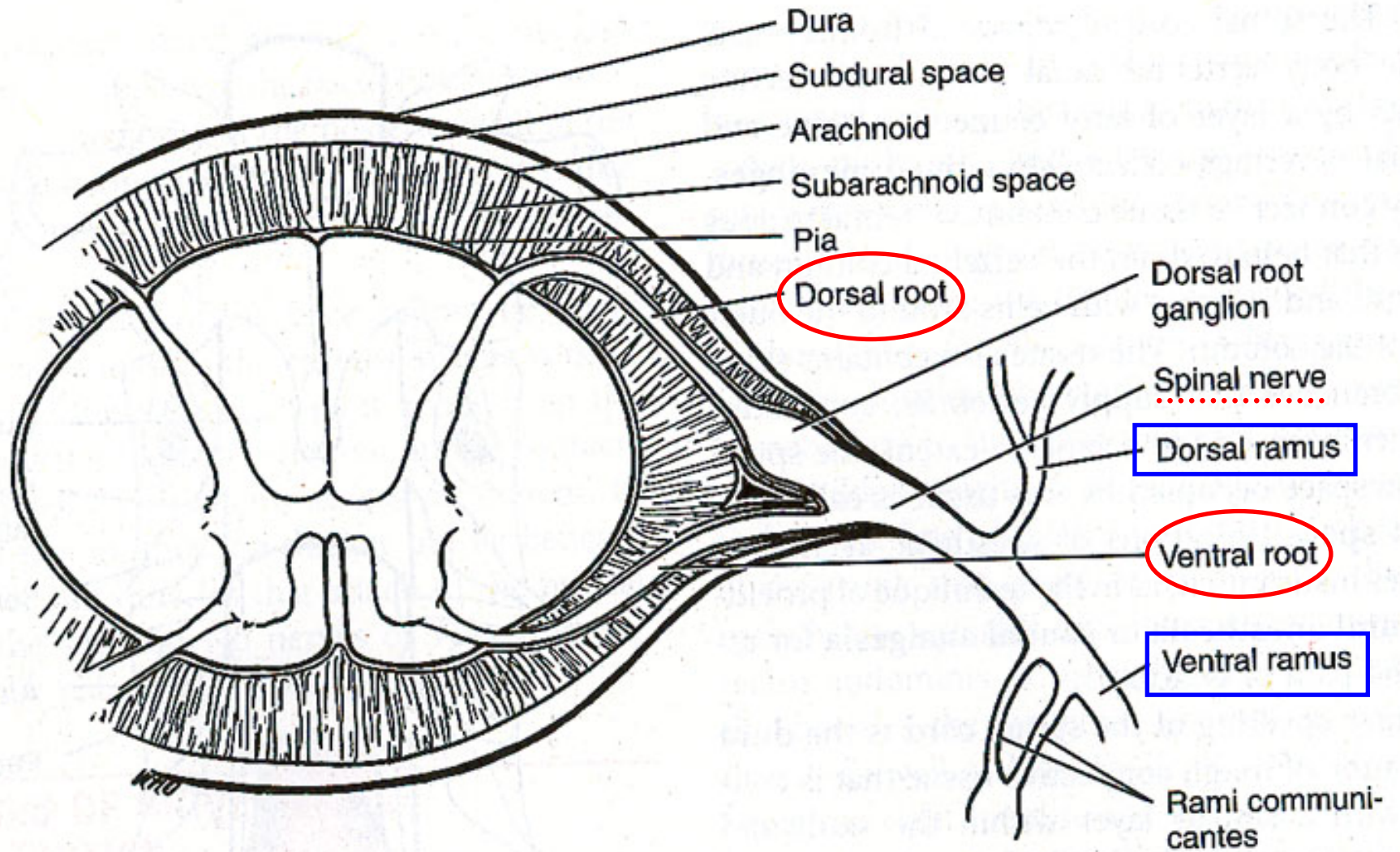
Short lateral rotators of the thigh

- **Common function:** assist lateral rotation of the femur
- **Oriented** like the fascicles of the gluteus maximus
- Most of those muscles lie posterior to the neck of the femur

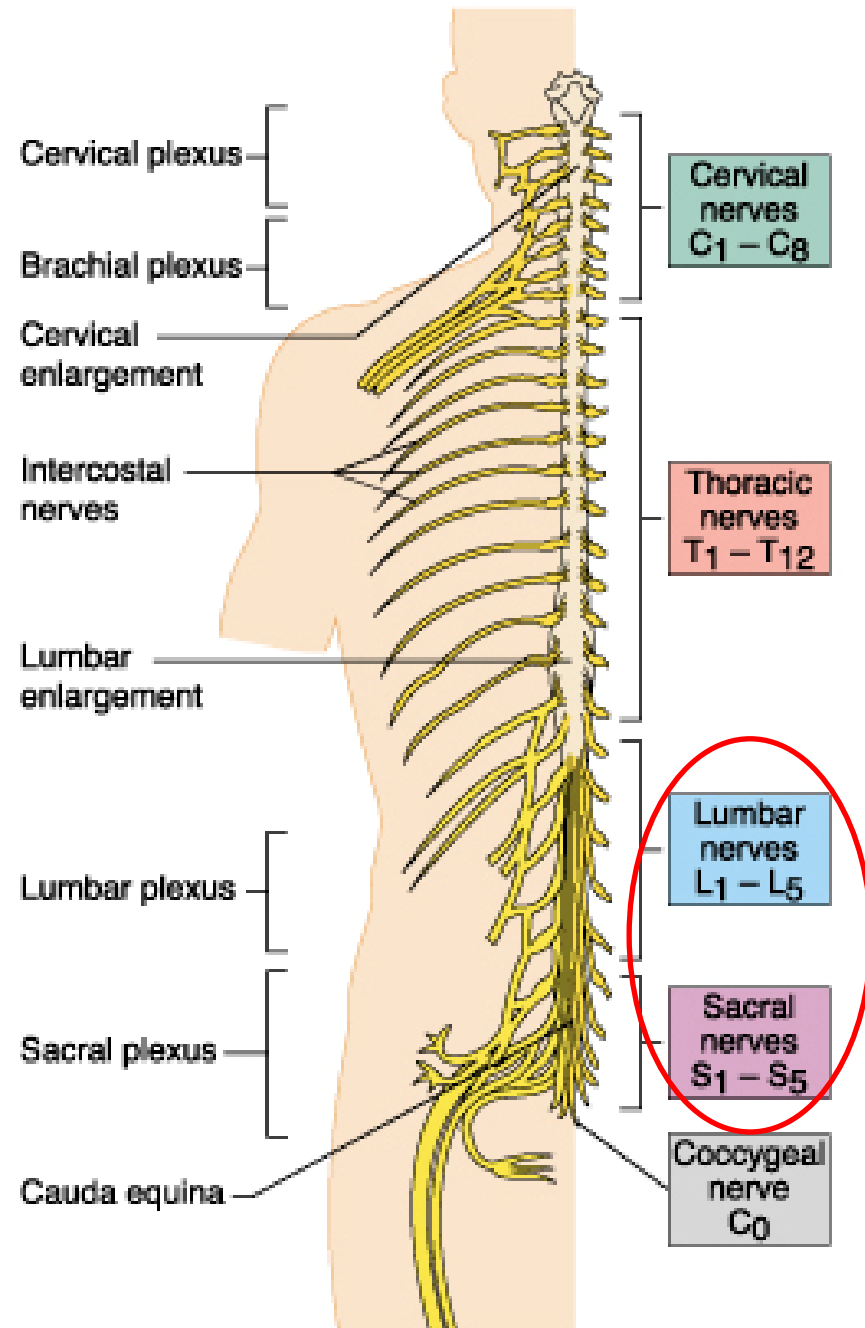
What is the strongest lateral rotator of the thigh?

Structure of spinal nerves

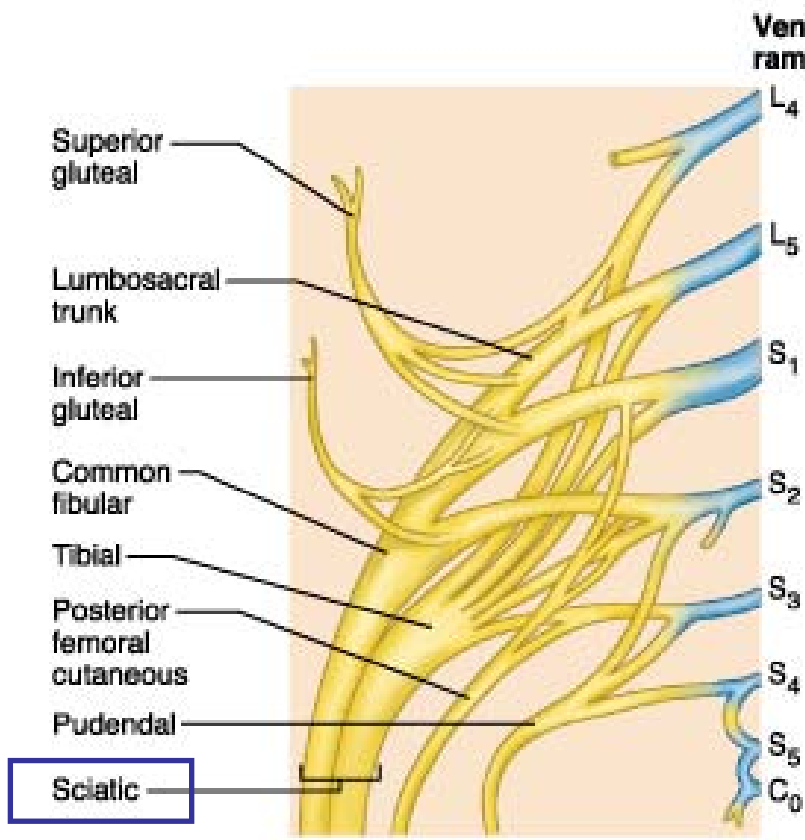




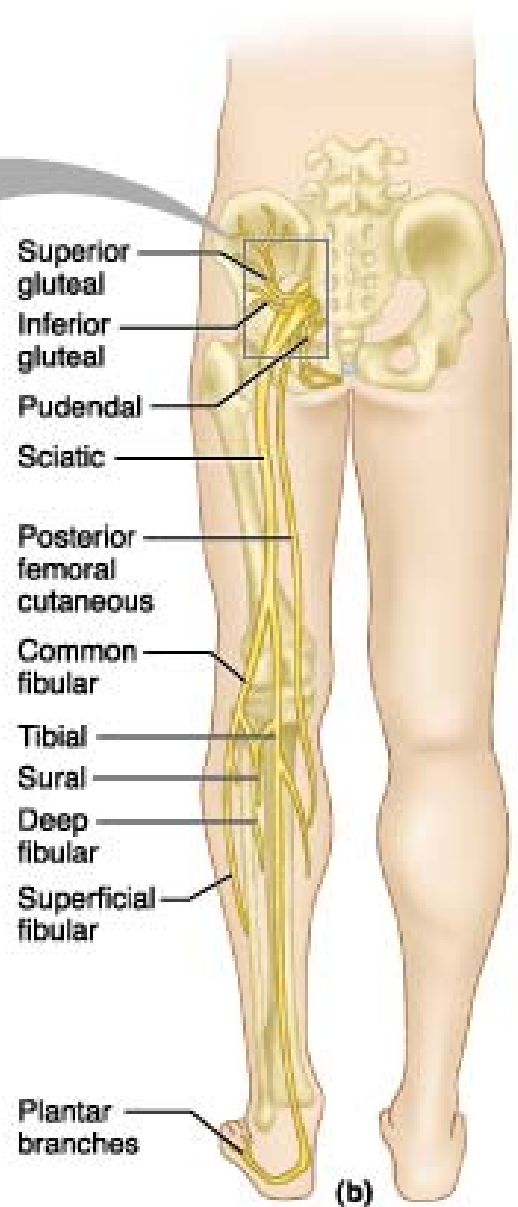
Spinal nerves



Sacral Plexus



(a)



(b)

Key:

 = Ventral rami

Spinal cord & Nerve roots

- **Dermatome** = the area of skin supplied by a single nerve root
- **Myotome** = group of muscles supplied by a single nerve root
- **Sclerotome** = an area of bone or fascia supplied by a single nerve root

Neurological testing

- **Dermatome:** may exhibit sensory changes for light touch and pin prick
- **Myotome:** assessed by performing isometric resisted tests held for 3-5 seconds
(L1-L2: hip flexion, L3: knee extension, L4: ankle dorsiflexion & inversion, L5: extension of big toe, S1-S2: plantar flexion & knee flexion, S3-S4: muscles of the pelvic floor & bladder)

Neurological testing

- **Reflexes:**
- The quadriceps reflex
 - L3
- The achilles tendon reflex
 - S1

Referred Pain

- Pain felt in a part of the body that is usually far from the tissue that have caused it.
- May be due to misinterpretation by the brain as to the source of the painful stimulus.
- Indicates that one of the structures innervated by a nerve root is causing signs & symptoms in other tissues supplied by that same nerve root.

Radiating (radicular) Pain

= Pain felt in a dermatome, myotome, or sclerotome because of direct involvement of a spinal nerve root.