



The Upper Limb I



Anatomy

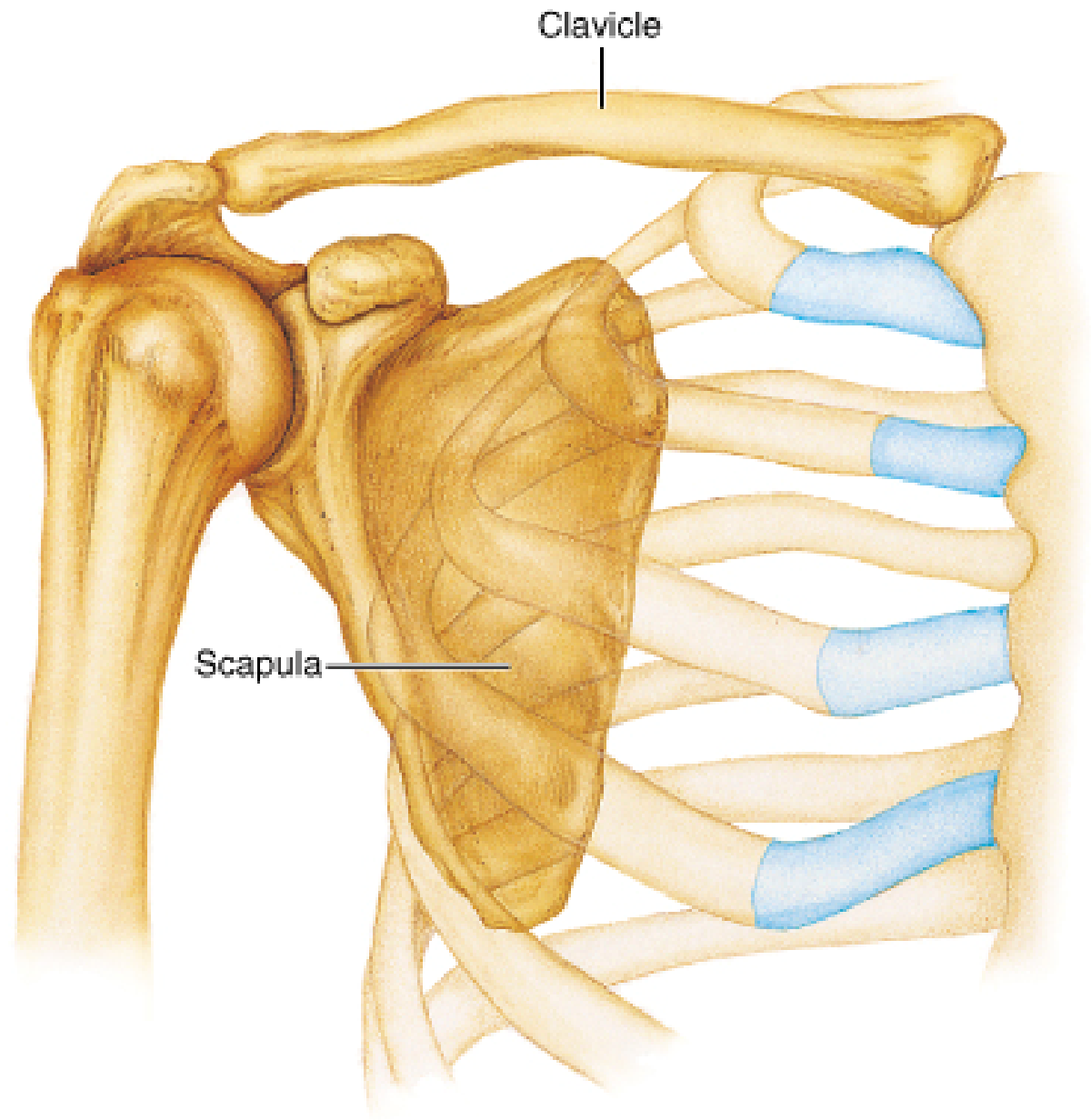
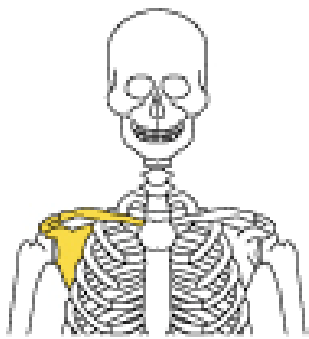
RHS 241

Lecture 10

Dr. Einas Al-Eisa

Osteology

- The major neurovascular structures that enter or leave the upper limb do so **by crossing the superior surface of rib 1**



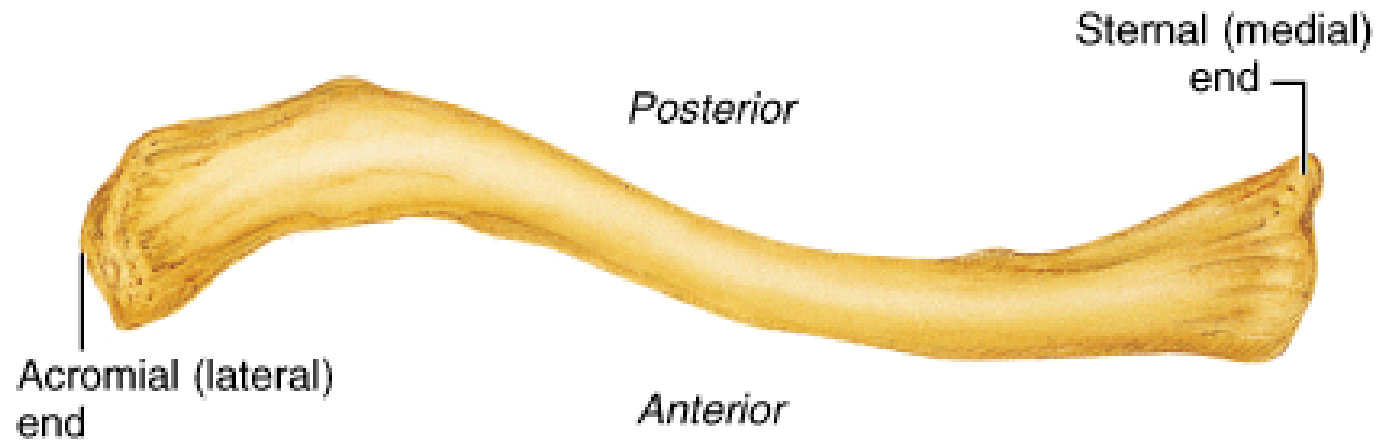
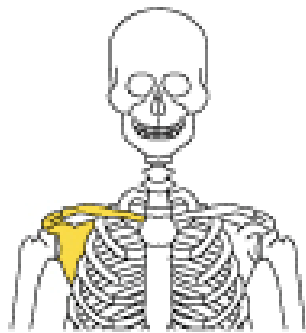
(a) Articulated pectoral girdle

Clavicles

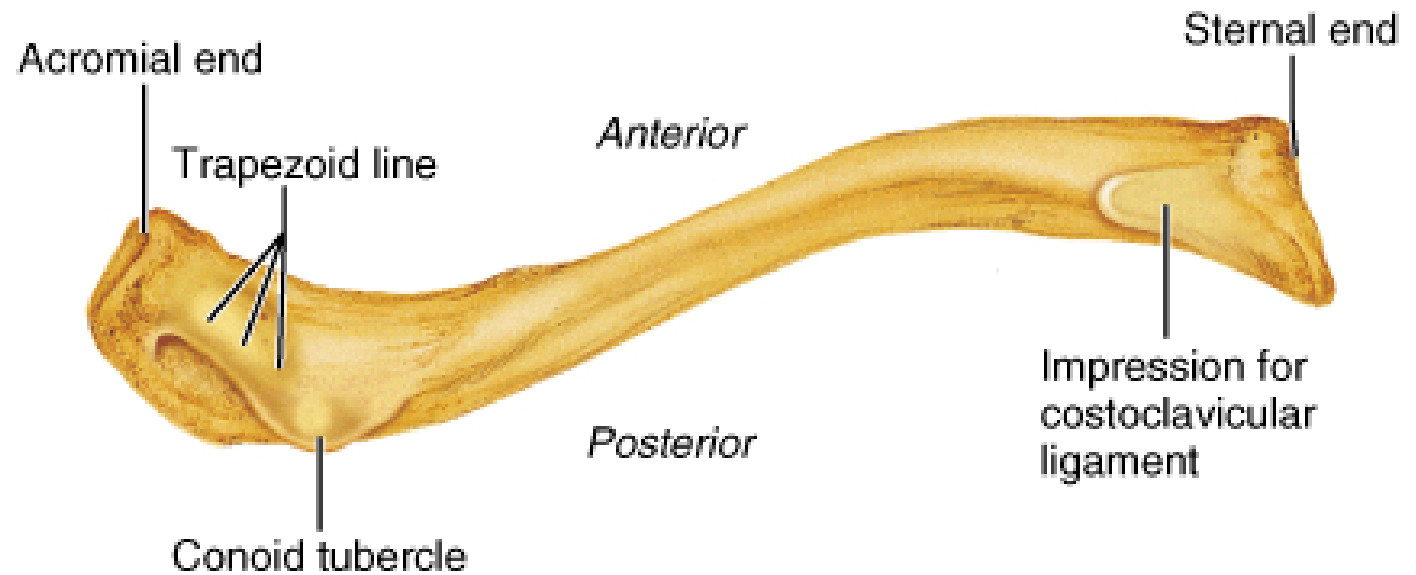
- Provide the only osseous link between the skeleton of the upper limb and the axial skeleton
- Articulate with the sternum to form the **“sternoclavicular joint”**
- Articulate laterally with the scapula to form the **“acromioclavicular joint”**

Clavicles

- Curvature:
 - medial curvature (concave posteriorly)
 - lateral curvature (concave anteriorly / shorter)
- Ends:
 - large medial (**sternal**) end
 - smaller lateral end



(b) Right clavicle, superior view



(c) Right clavicle, inferior view

Surface anatomy

- **Jugular (suprasternal) notch**: deepened by the large medial ends of the clavicles
- The **midclavicular point** (the brachial plexus courses just medial to this point as it enters the axilla)

Scapula

- Location:
 - on the posterolateral part of the thoracic wall (normally **ribs 2 to 7**)
 - has **no** direct articulation with the bony components of the thoracic wall

Scapula

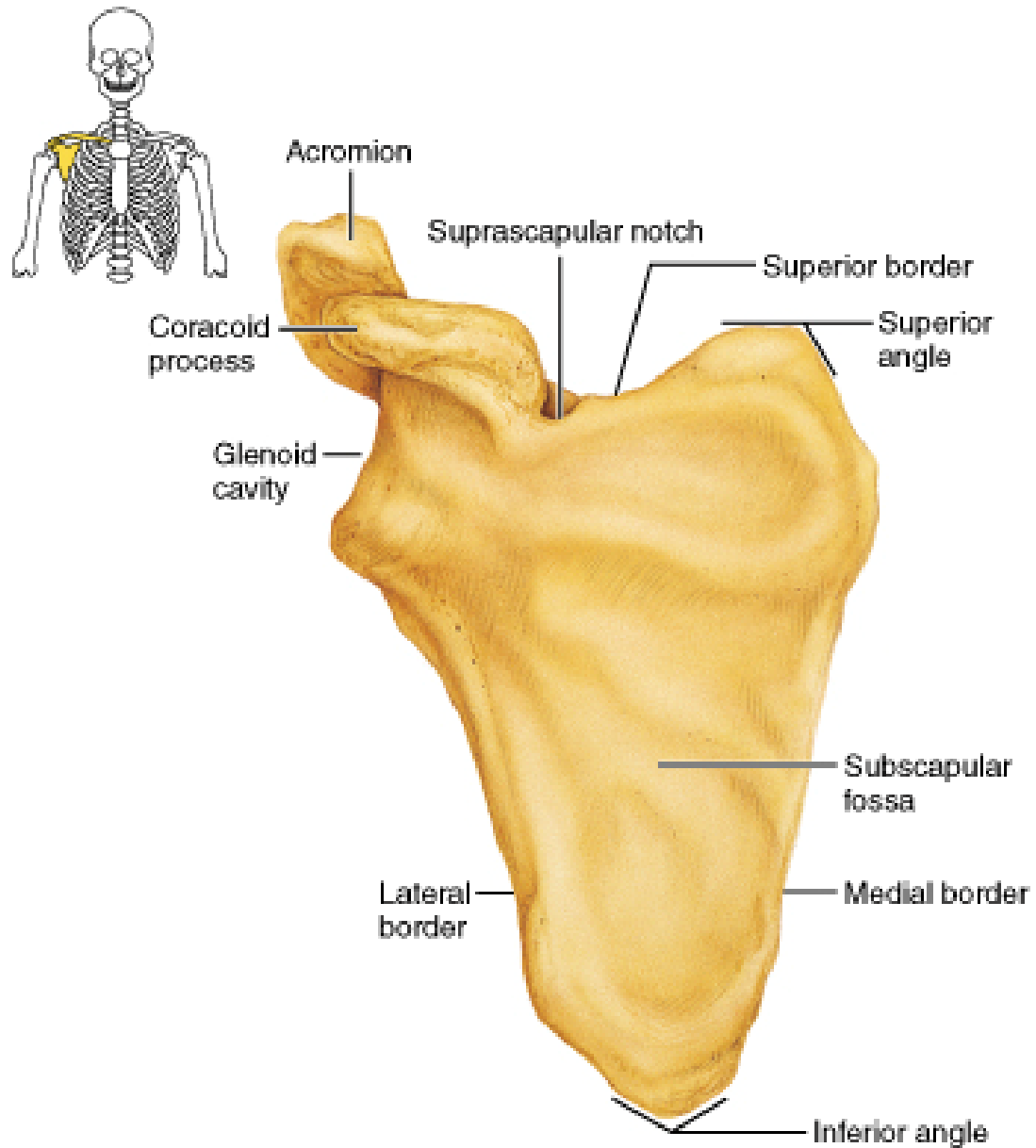
- Basic shape:
 - **two surfaces** (costal & dorsal)
 - **three borders** (superior, medial or vertebral, lateral)
 - **three angles** (superior, inferior, lateral)

Scapula

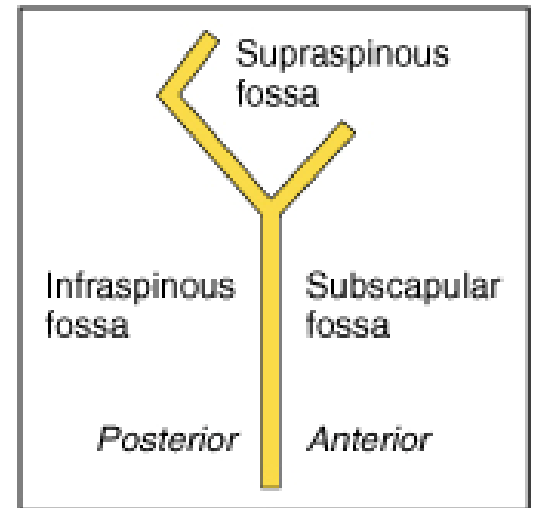
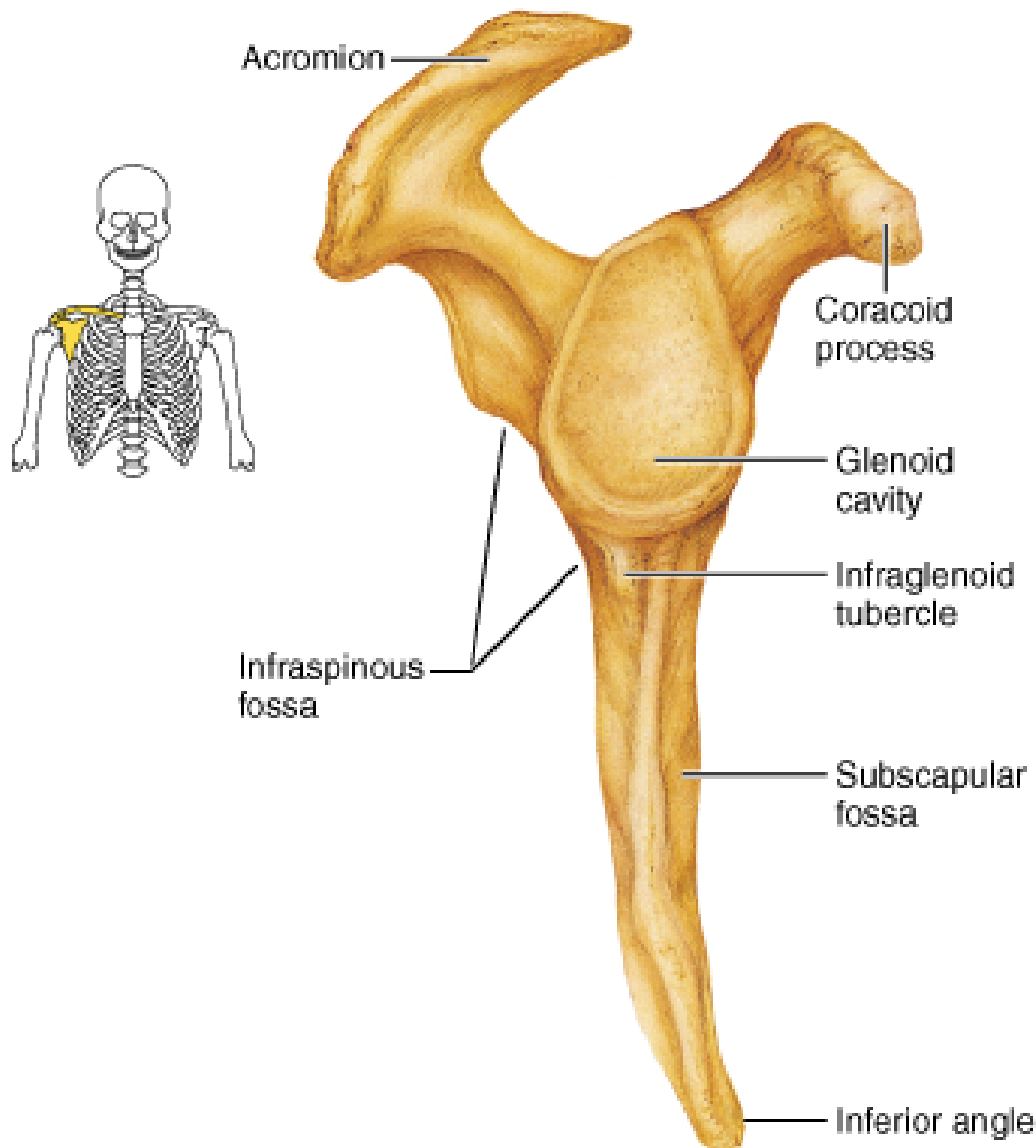
- **Spine:** extends laterally and upward from the scapula medial border
- **Acromion:** forms the prominent bony point of the shoulder

Scapula

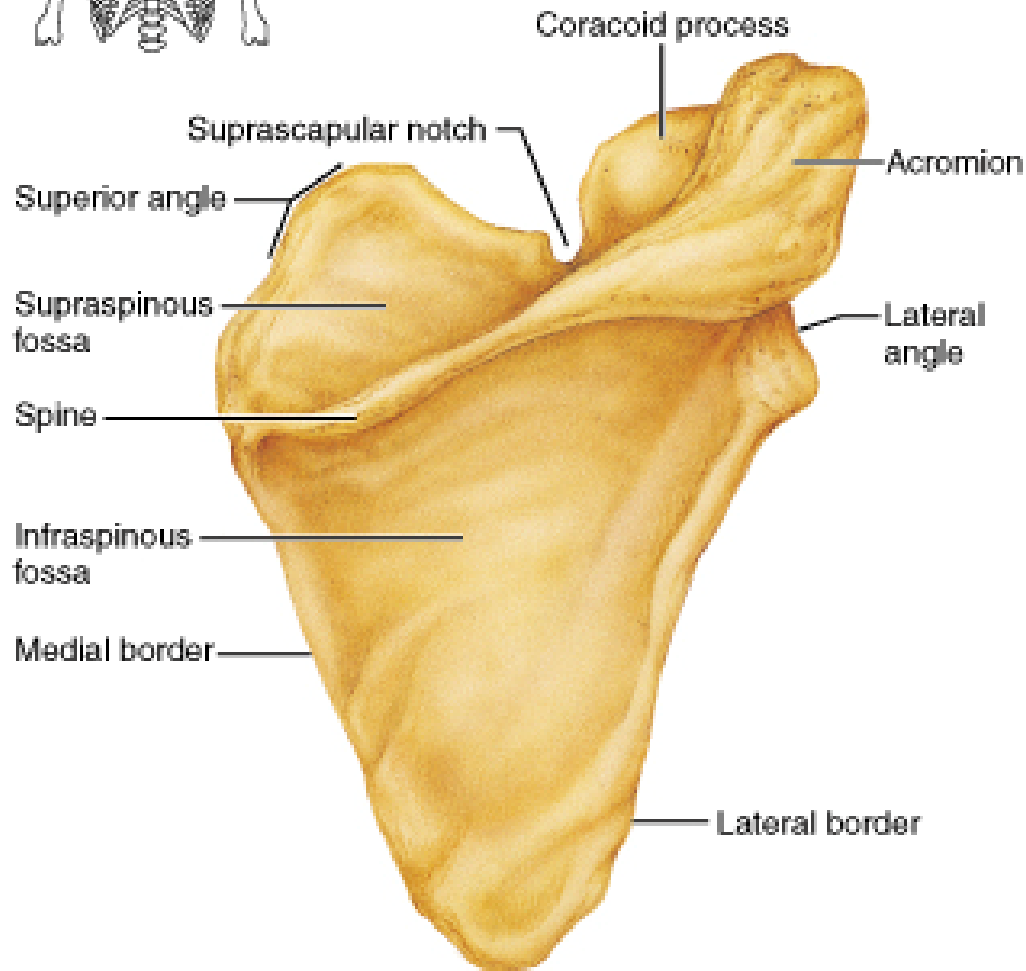
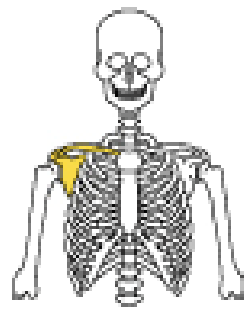
- **Coracoid process:** extends forward and laterally (curved, beak-like)
- **Glenoid surface or cavity:** articulates with the humerus to form the shoulder joint



(a) Right scapula, anterior aspect



(c) Right scapula, lateral aspect




(b) Right scapula, posterior aspect

Scapular movement

- **Elevation** (superior trapezius, levator scapulae, rhomboids)
- **Depression** (inferior trapezius, serratus anterior, pectoralis minor)

Scapular movement

- **Lateral rotation (elevation of glenoid fossa):** superior & inferior trapezius, inferior part of serratus anterior
- **Medial rotation (depression of glenoid fossa):** levator scapulae, rhomboids, latissimus dorsi, pectoralis minor



(b)
Copyright © 2001 Benjamin Cummings, an imprint of Addison Wesley Longman, Inc.

Trapezius:
Superior part
Inferior part

Deltoid muscle

Posterior
median furrow

Erector spinae

Supracristal
line at L₄

C₇ ◦

T₁ ◦

T₂ ◦

T₃ ◦

T₇ ◦

L₃ ◦

L₅ ◦

Acromion

Spine of scapula

Medial border of scapula

Teres major

Inferior angle of scapula

Triangle of auscultation

Latissimus dorsi (superior border)

Trapezius (lateral border)

Most superior point
of iliac crest

(a)

Copyright © 2001 Benjamin Cummings, an imprint of Addison Wesley Longman, Inc.

Triceps brachii:

Lateral head

Long head

Tendon

Medial head

Dimple in which
head of radius is felt

Head of ulna

