

## The Protective Effect of Vitamin C Against Toxicity Induced by Lead-Acetate on Liver and Spleen in Swiss Albino Mice

Badr Abdullah Aldahmash<sup>1</sup> and Doaa M. El-Nager<sup>2\*</sup>

<sup>1</sup>Zoology Department, College of Sciences, King Saud University, Riyadh, Saudi Arabia

<sup>2</sup>Faculty of Science and Humanity, Hotat bani Tamim, Salman University, Saudi Arabia

**Abstract.-** The present study was carried out to investigate the protective effect of vitamin C as antioxidant to reduce hepatotoxicity and spleen toxicity induced by lead. Lead acetate administered at 20 mg/kg intake caused severe alterations in liver and spleen manifested by hepatocytes degeneration and leucocytes infiltration and fibrosis in liver, ill-defined architecture and large macrophages in the spleen. Vitamin C administered at 500 mg/kg of vitamin C one hour prior to lead reduced hepatotoxicity but did not affect liver fibrosis. Moreover, Vitamin C reduced the toxicity in spleen characterized by well-defined spleen architecture.

**Key words:** Mice-vitamin C, lead, liver, spleen.

### INTRODUCTION

Lead is the metal, which has been associated with human activities from the past and is considered as one of the major environmental pollutants (Ghorbe *et al.*, 2001). Levels of lead content in various media have been coupled with data for lead intake and absorption in the human body, for both children and adults are affected not only morphologically but also anatomically and histologically. Various organs also show critical damage (Pizzol *et al.*, 2010). The ingested and absorbed lead stored primarily in soft tissues and bone, but the highest concentration of lead occur within the bone, teeth, liver, lung, kidney, brain and spleen (Mudipalli, 2007). All sources of lead such as the manufacture of batteries, painting, printing, pottery glazing and lead smelting processes contribute to an increase in permissible exposure limit for metallic lead, lead oxide and lead salts and soaps that has set by WHO and other health organizations (Harbison, 1998). Lead is a non-threshold multi-targeted toxicant that causes alterations in different organs of the body (Jarrar, 2001, 2003; Jarrar and Mahmoud, 2000). It causes corpuscular necrosis and amyloidosis in kidney, also alveolar emphysema, peribronchitis in lungs (Muselin *et al.*, 2010). The absorbed lead is

conjugated in the liver and passed to the kidney, where a small quantity is excreted in urine and the rest accumulates in various body organs and interferes with their function (Jarrar *et al.*, 2006; Taib *et al.*, 2004).

Vitamin C is a water-soluble vitamin that is essential for all humans and a few other mammals. The term vitamin C refers to both ascorbic acid and dehydroascorbic acid (DHA). The biological functions of ascorbic acid are based on its ability to provide reducing equivalent for a variety of biochemical reactions, because of its reducing power the vitamin can reduce most physiologically relevant reactive oxygen species (Buettner, 1993). Vitamin C also acts as a cosubstrate for some hydroxylase and oxygenase enzymes, maintaining their active center metal ions in a reduced state for optimal enzyme activity (Carr and Frei, 1999). Ascorbic acid is well known for its antioxidant activity, acting as a reducing agent to reverse oxidation in liquids. When there are more free radicals (reactive oxygen species, ROS) in the human body than antioxidants, the condition is called oxidative stress (McGregor and Biesalski, 2006) and has an impact on cardiovascular disease, hypertension, chronic inflammatory diseases, diabetes as well as on critically ill patients and individuals with severe burns (Kelly, 1998; Mayne, 2003; Tak *et al.*, 2000; Goodyear-Bruch and Pierce, 2002).

The present work was aimed at evaluating the protective effect of vitamin C to reduce the toxicity induced by lead acetate in liver and spleen, also to

\* Corresponding author: [elnagard1@yahoo.com](mailto:elnagard1@yahoo.com)

0030-9923/2014/0005-1425 \$ 8.00/0

Copyright 2014 Zoological Society of Pakistan

study its the effect against liver fibrosis due to toxicity induced.

## MATERIALS AND METHODS

### *Design of experiment*

Male mice of the Swiss albino strain weighing  $25 \pm 1$  g were used for the experiment. The animals were acclimated to  $22 \pm 1^\circ\text{C}$  and maintained under conditions of 12-h periods of light and dark, with free access to clean water and commercial mice food (Alarifi *et al.*, 2012; El-Nager and Aldahmash, 2013).

The mice were divided into five groups, each consisting of six animals as following; (1) Control mice received clean water, (2) Mice received oral administration of 20 mg/kg of lead acetate; and (3) Mice received oral administration of 500mg/kg of vitamin C one hour prior to administration of 20mg/kg of lead acetate.

Oral administration took place by gavage. The experimental duration was five days and mice were dissected on the sixth day.

### *Liver and spleen index*

At the end of the experimental period, each mouse was weighed, liver and spleen were then removed and weighed. Finally, the liver and spleen indices were calculated by dividing the liver or spleen by the body weight and then multiplying by 100 and Correlation analysis of the means was done by linear regression analysis using Microsoft excel, SEM calculated by SPSS 6 and represented by linear regression analysis of Microsoft excel.

### *Histological examination*

Livers and spleens were collected and cut into small pieces, fixed in 10% neutral buffered formalin. Following fixation, specimens were dehydrated, embedded in wax and then sectioned to 5  $\mu\text{m}$  thickness. Sections were stained with hematoxylin and eosin. Also, other sections were stained with Masson trichrome stain according to Drury and Wallington (1980).

## RESULTS AND DISCUSSION

### *Liver and spleen indices*

Table I shows an increase ( $P < 0.05$ ) in the

liver index after administration of lead, whereas, the liver index of the third group that received vitamin C before lead administration showed an insignificant increase over the group that received lead only.

**Table I.- Liver index and spleen index in control, group receiving lead and group received lead and vitamin C.**

	Control	Lead group	Vitamin C + Lead group
Liver index	$3.99 \pm 0$	$6.33 \pm 2.33$	$6.5 \pm 0.5$
Spleen index	$0.5 \pm 0$	$0.6 \pm 0.17$	$0.6 \pm 0.1$

The data are expressed as mean  $\pm$  SEM ( standard error of mean)

$P < 0.05$  when compare liver index in control group versus lead groups (significant difference) and insignificant difference when compare liver index in lead group versus lead and vitamin C group. Insignificant difference between control, lead and lead + vitamin c groups in spleen index.

The significant increase in liver index in mice receiving lead may be due to the enlargement of liver because of aggregation of inflammatory cells (Allouche *et al.*, 2011). Spleen index showed slight increase, though insignificant when compared with the control group. This may be due to congestion of red pulp.

### *Effect on liver*

Non-treated mice liver showed normal structure represented by hepatic lobules with semi circular central vein in the center, hepatic cells arranged in strands, blood sinusoids in between the hepatic cells and portal canals at the periphery of hepatic lobules. The portal canal comprises branches of the portal vein, hepatic artery and bile duct, often also with a lymphatic vessel lying in a small amount of connective tissue (Fig. 1).

Mice livers treated with oral administration of 20 mg/kg/bw of lead acetate showed marked changes in the hepatic tissue represented by congested central veins, dilatation in blood sinusoids with abundant kupffer cells hepatic cells suffered from degeneration, its nuclei looked swollen and some of them have fragmented chromatin, whereas others showed absence of chromatin (Fig. 2A,B), large aggregations of

leucocytic infiltration (Fig.2C), and precipitation of collagenous fibers around dilated central vein stained blue by Masson'trichrome (Fig. 2D).

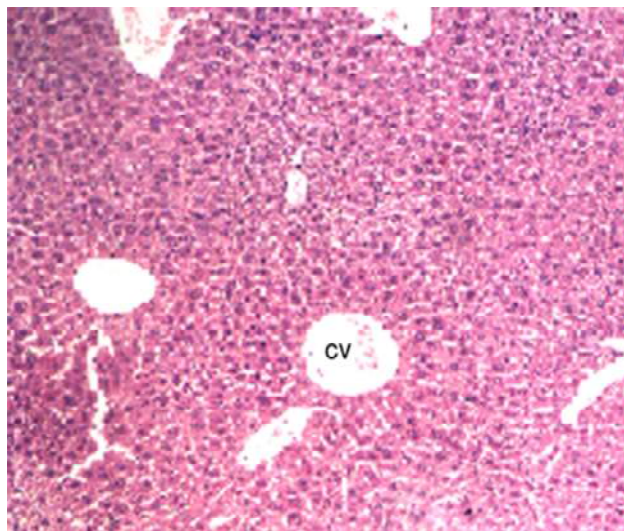


Fig. 1. Normal structure of liver showed normal central vein (CV) and normal hepatocytes(Mag x100 Hx&E)

Histological investigations revealed that lead acetate exposure resulted in marked changes in liver these findings agreed with those of Jankeer and El-Nouri (2009) and Suradkar *et al.* (2010). They stated that rats exposure to lead acetate caused hepatotoxicity characterized by engorgement of blood vessels along with sinusoidal hemorrhage, infiltration, dilatation of central veins and vacuolar degeneration of hepatocytes. In the present study, lead seemed to have accumulated in the liver tissue causing severe alterations characterized by congested and dilated portal veins and degeneration in hepatic cells. Most of the orally ingested lead is excreted, but a portion is absorbed and is transferred to the blood where it binds to hemoglobin in the erythrocytes. Lead is carried through the circulatory system by erythrocytes, virtually to all tissues in the body particularly hematopoietic and immune system (Goering, 1993; Gidlow, 2004).

Vitamin C before oral administration of lead, maintained the normal histological structure of liver. However, necrotic foci were present and different kinds of leucocytes were scattered in the blood

sinusoids besides kupfer cells, concentric layers of collagenous fibers were abundant in the liver tissue (Figs. 3A,B).

There are many proofs that vitamin C had hepatoprotective effects against many hazardous chemicals as carbon tetrachloride, paracetamol and malathion induced hepatotoxicity, it is also as well effective against radiation induced hepatotoxicity (Ademuyiwa *et al.*, 1994; Suna *et al.*, 2010; Ahn *et al.*, 2004). In addition, Hamadouche *et al.* (2012) reported that vitamin C could reduce hepatotoxicity induced by lead and diminished most of histopathological changes induced by lead. All previous findings run in full agreement with the present study results that vitamin C had hepatoprotective effect when it was received before lead treatment 1 hour prior according to the study plan, it might be due to the ability of vitamin C to chelate reactive oxygen species there by reduced oxidative stress and related complications. Low levels of vitamin C [ascorbic acid] are strongly linked to high lead levels. Individuals who consume more than 340 mg of vitamin C tend to have lower blood lead levels than those who consume less than 110 mg. Consumption of 1000 mg a day has been shown to significantly decrease lead levels in some, though not all, cases - apparently more through reduced absorption rather than increased excretion (Taylor, 2010). However, no antifibrotic effect was recorded that bundles of collagenous fibers appeared in the liver tissue.

#### *Effect on spleen*

Non treated spleen sections showed normal spleen structure composed of white pulp and red pulp, besides fibrous capsule which covered the spleen. White pulp consists mainly of B-lymphocytes arranged into two zones, marginal zone (outer rim of loose lymphocytes) that contains macrophages and mantle zone (inner rim of lymphocytes). The red pulp is the area of spleen in between white pulp and consists of open sinuses and cellular cords. Splenic sinuses are open vascular spaces lined by a discontinuous layer of endothelial cells and supported by a fenestrated basal lamina and reticular fibers. The surrounding cellular splenic cords provide a tissue frame work maintaining the network of sinuses (Fig. 4).

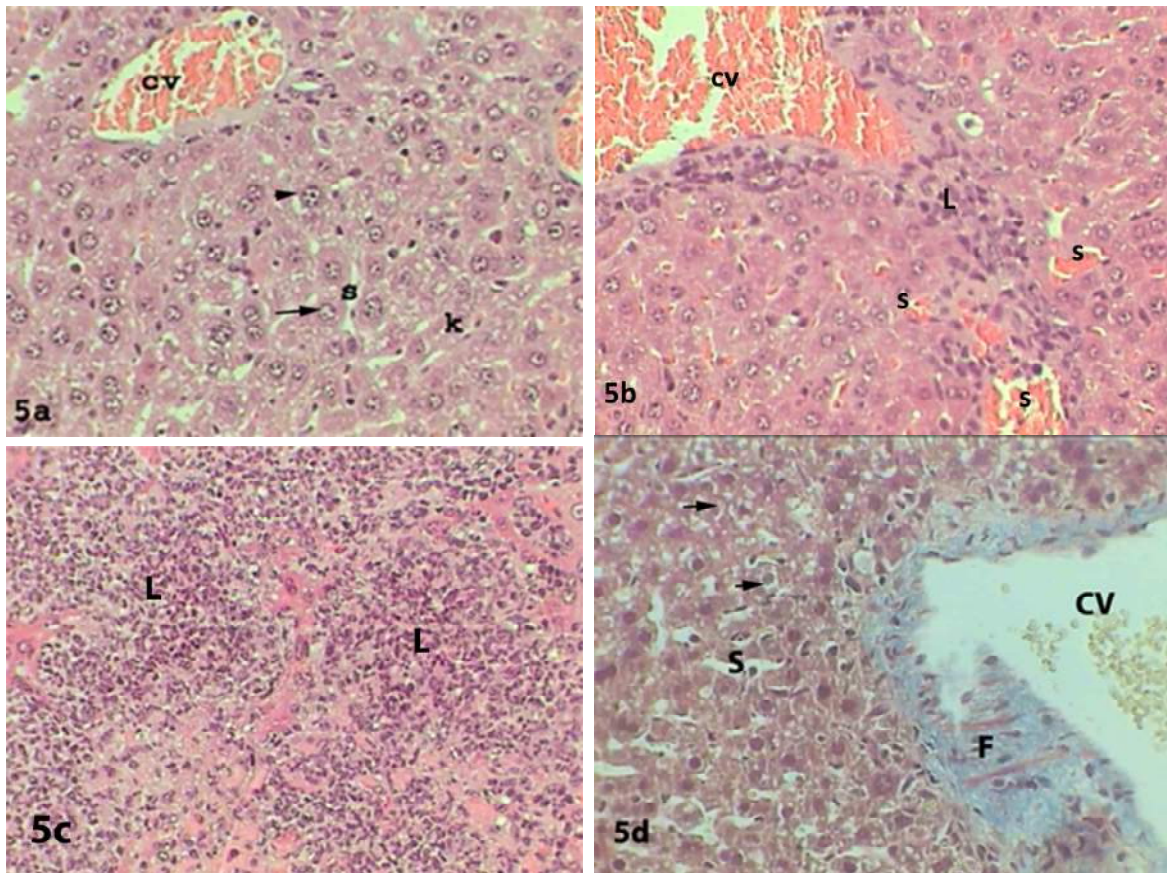


Fig. 2. Livers of mice received 20 mg/kg of lead acetate showed congested central vein (CV), swollen nuclei of hepatocytes (small arrows), nuclear degeneration (long arrows), dilated blood sinusoids – Kupfer cells (K) (A), lymphocytic infiltration (L) (B,C) (Mag x 400 Hx&E)- dilated central vein (CV), collagenous fibers (F) and degenerated cells (arrows) (D) (Mag x 400 MTr.)

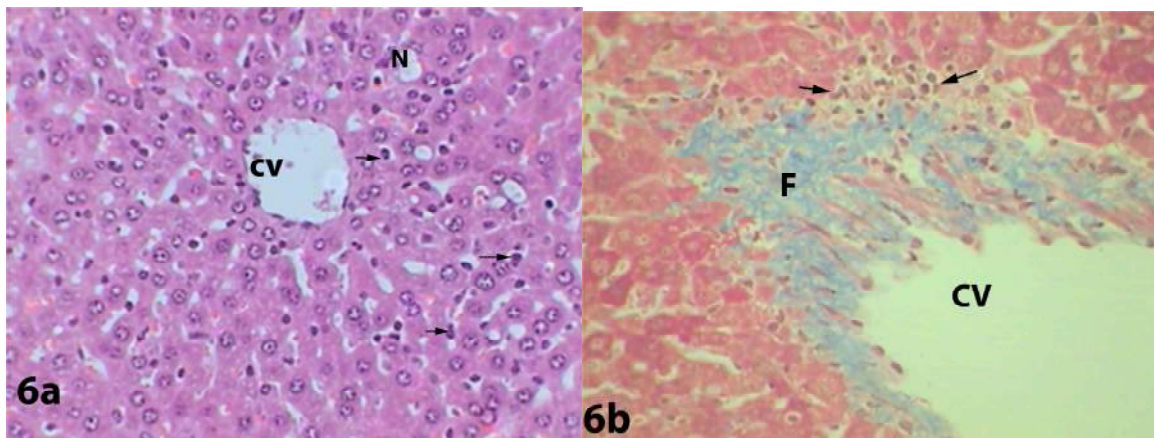


Fig. 3. Livers of mice received 500 mg/kg of vitamin C before lead treatment showed normal central vein (CV), to some extent healthy hepatocytes, necrotic foci (N), kuffer cells (arrows) (A) (Mag x 400 Hx&E) – collagenous fibers (F) (B) (Mag x 400 Hx&E).

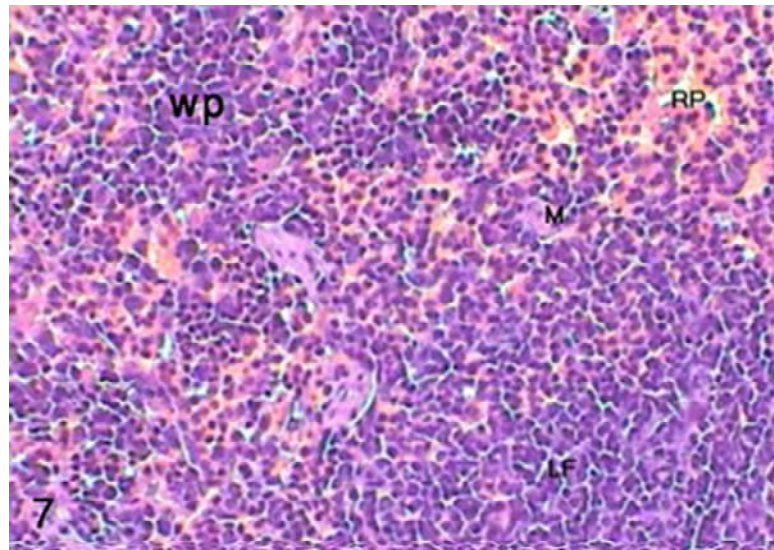


Fig. 4. Normal mice spleen showed white pulp (WP), lymphoid follicles (arrows), red pulp (RP) (Mag x 100 Hx&E)

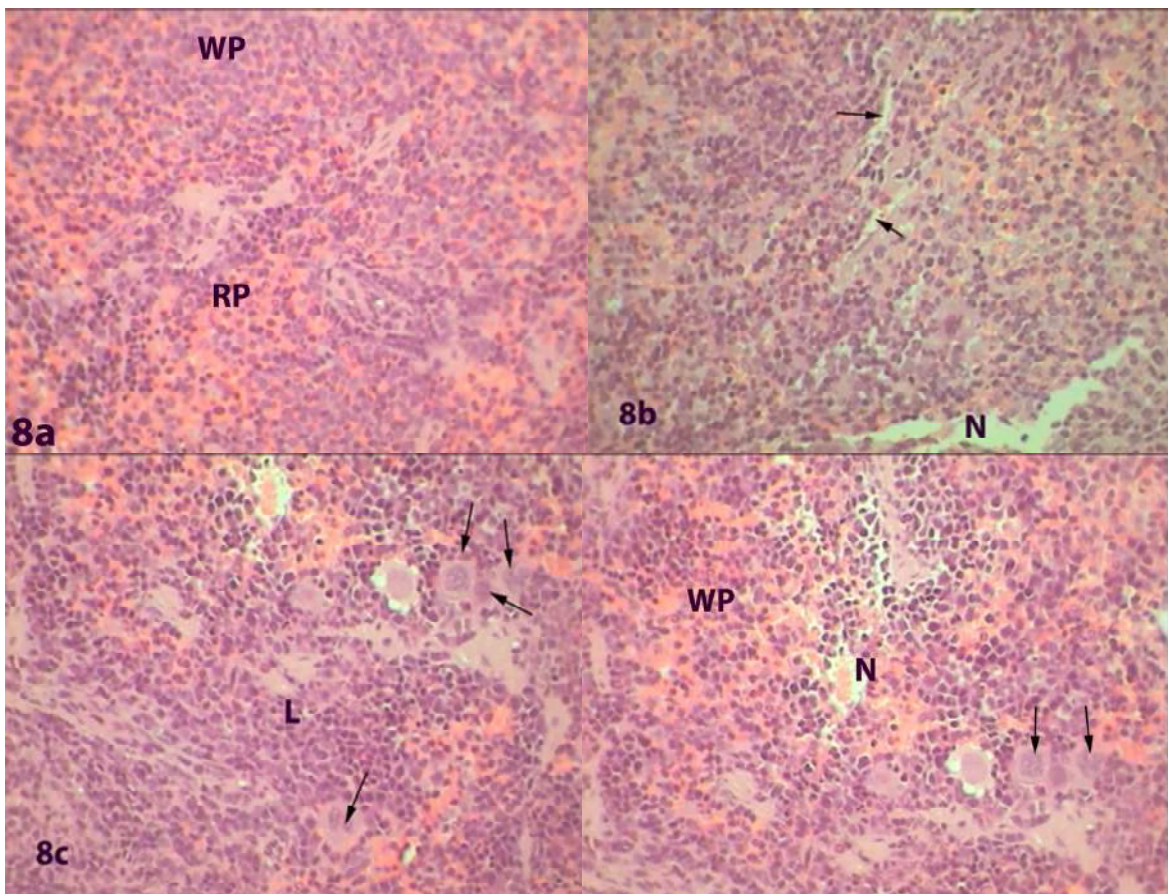


Fig. 5. Spleens of mice received 20 mg/kg of lead showed diffusion of red pulp (RP) in white pulp (WP), (A), necrotic foci (N); (B), large macrophages (arrows) and necrotic foci (N) (C,D) (Mag x 400 Hx&E).

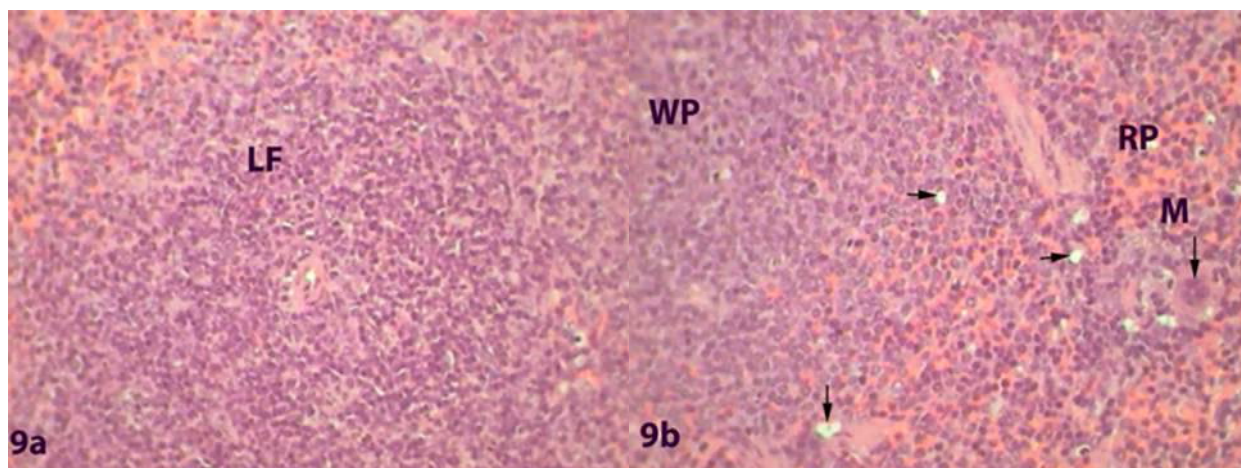


Fig. 6. Spleens of mice received 500 mg/kg of vitamin C before lead treatment showed normal lymphoid follicle (LF) (A), small necrotic foci (arrows), macrophages (M), white pulp (WP), red pulp (RP); (B) (Mag x 400 Hx&E).

Spleen of mice treated with lead acetate showed marked changes represented by distorted spleen architecture, that it was ill-defined due to diffusion of white pulp into the red pulp in addition to appearance of necrotic foci (Figs. 5A,B), large macrophages were seen in the tissue with great number (Figs. 5C,D).

In the spleen, phagocytes (macrophages and polymorphonuclear cells) are responsible for slowing the propagation of an invading pathogen, while an antigen-specific adaptive immune response (antibody- or cell-mediated) is being established. Lead was reported to inhibit macrophage function (Kowolenko *et al.*, 1988; Mauel *et al.*, 1989) possibly by overloading macrophages with cellular debris and inhibiting macrophage production of nitric oxide (Tian and Lawrence, 1995). In the context of adaptive humoral and cellular immune responses, lead increased both B-cell and T-cell *in vitro* proliferation (Warner and Lawrence, 1986; Razani-Bordoujerdi *et al.*, 1999). In the present study, administration of lead resulted in severe changes in the spleen represented by diffusion of white pulp into the red pulp and appearance of large macrophages due to the production of debris of dead cells.

Spleen sections of mice received vitamin C before treatment with lead acetate showed relative improvement when compared with control sections manifested by well-defined sections, healthy lymphoid follicle was abundant, moreover other

section showed scattered necrotic foci besides normal sized macrophages (Fig. 5A,B)

The results of the present study agreed with those of Aly *et al.* (2009) who showed that vitamin C had protective effect against lead toxicity in spleen.

#### ACKNOWLEDGEMENT

The authors would like to extend their sincere appreciation to the Deanship of Scientific Research at King Saud University for its funding this research group No (RG-1435-030).

#### REFERENCES

- ADEMUYIWA, O., ADESANYA, O. AND AJUWON, O.R., 1994. Vitamin C in CC14 hepatotoxicity-a preliminary report. *Hum. Exp. Toxicol.*, **13**: 107-9.
- AHN, K., PARK, S., CHO, H., KANG, K., CHUNG, D., KANGAND, J. AND CHAI, G., 2004. The protective effects of Vitamin C on hepatotoxicity induced by radiation. *J. Korean Soc. Therap. Radiol. Oncol.*, **22**: 280-287.
- ALARIFI, S., ALDAHMAH, B., EL-NAGAR, D. AND DKHIL, M., 2012. Effect of corn oil, flaxseed oil and black seed oil on lead acetate-induced hepatic tissue damage: A histological study. *J. med. Pl. Res.*, **6**: 4128-4134
- ALLOUCHE, L., HAMADOUCHE, M., TOUABTI, A. AND KHENNOUF, S., 2011. Effect of long-term exposure to low or moderate lead concentrations on growth, lipid profile and liver function in albino rats. *Adv. Biol. Res.*, **5**: 339-347.

- ALY, F., DONYA, M. AND ABO-ZEID, M., 2009. The protective role of folic acid, vitamin B12 and vitamin C on the mutagenicity of the anticancer drug daunorubicin. *Researcher*, **1**:16-26.
- BUETTNER, G., 1993. The pecking order of free radicals and antioxidant : Lipid peroxidation, alpha-tocopherol and ascorbate. *Arch. Biochem. Biophys.*, **300**: 535-543.
- CARR, A. AND FREI, B., 1999. Does vitamin C act as a pro-oxidant under physiological conditions? *FASEB. J.*, **13**:1007-1024.
- DRURY, R. AND WALLINGTON, E., 1980. *Carleton's histological technique*, 5<sup>th</sup>edn. Oxford University Press, Oxford New York Toronto, Pp. 188-189, 237-240, 290-291.
- EL-NAGER, D. AND ALDAHMAH, B., 2013. Effect of corn oil, flaxseed oil and black seed oil on testicular damage induced by lead acetate in albino mice: A histological study. *Pakistan J. Zool.*, **45**:1083-1089.
- GHORBE, F., BOUJELBENE, M., MAKNI-AYADI, F., GUERMAZI, F., KAMMOUM, A. AND MURAT, J., 2001. Effect of chronic lead exposure on kidney function in male and female rats: determination of a lead exposure biomarker. *Arch. Physiol. Biochem.*, **109**: 457-463.
- GIDLOW, D., 2004. Lead toxicity. *Occup. Med.*, **54**:76-81.
- GOERING, P., 1993. Lead-protein interactions as a basis for lead toxicity. *Neurotoxicology*, **14**:45-60.
- GOODYEAR-BRUCH, C. AND PIERCE, J., 2002. Oxidative stress in critically ill patients. *Am. J. Crit. Care*, **11**: 543-551.
- HAMADOUCHE, N., SLIMANI, M. AND AOUES, A., 2012. Beneficial effect administration of vitamin C in amelioration of lead hepatotoxicity. *Sci. Biol.*, **4**:07-13.
- HARBISON, R.D., 1998. Lead. In: *Hamilton & Hardy's Industrial Toxicology* (ed. R.D. Harbison), 5th ed, Mosby, Philadelphia, pp. 70-76.
- JANKEER, M. AND EL-NOURI, A., 2009. Histological study of the liver and kidney of albino mice *Mus musculus* exposed to lead. *J. Raf. Sci.*, **20**: 42- 51.
- JARRAR, B., 2001. Ultrastructural alterations in proximal tubule cells induced by lead. *Pakistan J. Biol. Sci.*, **4**: 1281-84.
- JARRAR, B., 2003. Histological and histochemical alterations in the kidney induced by lead. *Annl. Saudi Med.*, **23**: 10-15.
- JARRAR, B. AND MAHMOUD, Z., 2000. Histochemical characterization of the lead intranuclear inclusion bodies. *Biol. Tr. Elem. Res.*, **74**: 1-7.
- JARRAR, B.M., MAHMOUD, Z., AL-ENAZI, M. AND TAIB, N., 2006. Histochemical alterations in the activities of hepatic dehydrogenases induced by lead in male albino rats. *Egypt. J. Zool.*, **46**:217-225
- KELLY, F., 1998. Use of antioxidants in the prevention and treatment of disease. *J. Int. Fed. Clin. Chem.*, **10**: 21-23
- KOWOLENKO, M., TRACY, L., MUDZINSKI, S. AND LAWRENCE, D., 1988. Effect of lead on macrophage function. *J. Leukoc. Biol.*, **3**:357-364.
- MAUEL, J., RANSIJN, A. AND BUCHMULLER, Y., 1989. Lead inhibits intracellular killing of leishmania parasites and extracellular cytolysis of target cells by macrophages exposed to macrophage activating factor. *J. Leukoc. Biol.*, **45**: 401-409.
- MAYNE, S., 2003. Antioxidant nutrients and chronic disease: Use of biomarkers of exposure and oxidative stress status in epidemiologic research. *J. Nutr.*, **3**: 933-940.
- MCGREGOR, G. AND BIESALSKI, H., 2006. Rationale and impact of vitamin C in clinical nutrition. *Curr. Opin. Clin. Nutr. Metab. Care*, **9**: 697-703.
- MUDIPALLI, A., 2007. Lead hepatotoxicity and potential health effects. *Indian J. med. Res.*, **126**:518-527.
- MUSELIN, F., TRIF, A., BREZOVAN, D., STANCU, A. AND SNEJANA, P., 2010. The consequences of chronic exposure to lead on liver, spleen, lungs and kidney architecture in rats. *Lucrări Stiințifice Med. Vet.*, **2**: 123-127.
- PIZZOL, M., THOMSEN, M. AND ANDERSON, M., 2010. Long-term human exposure to lead from different media and intake pathways. *Sci. Total Environ.*, **408**: 5478-5488.
- RAZANI-BORDOUJERDI, S., EDWARDS, B. AND SOPORI, A., 1999. Lead stimulates lymphocyte proliferation through enhanced T cell-B-cell interaction. *J. Pharm. exp. Therap.*, **288**:714-719.
- SUNA, K., GOKCEUZUN, F., DURAK, D., DEMIR, D. AND KALENDER, Y., 2010. Malathion-induced hepatotoxicity in rats: The effects of vitamins C and E. *Fd. Chem. Toxicol.*, **48**: 633-638.
- SURADKAR, S., VIHOL, P., PATEL, J., GHODASARA, D., JOSHI, B. AND PRAJAPATI, K., 2010. Pathomorphological changes in tissues of Wistar rats by exposure of lead acetate. *Vet. World*, **3**: 82-84.
- TAIB, N., JARRAR, B. AND MUBARAK, M., 2004. Ultrastructural alterations in hepatic tissues of white rats (*Rattus norvegicus*) induced by lead experimental toxicity. *Saudi J. Biol. Sci.*, **11**: 11-20.
- TAK, P., ZVAIFLER, N., GREEN, D. AND FIRESTEIN, G., 2000. Rheumatoid arthritis and p53: how oxidative stress might alter the course of inflammatory diseases. *Immunol. Today*, **21**: 78-82.
- TAYLOR, R., 2010. Nutrition to fight lead poisoning. *Lead Action News*, **10**:1324-6011.
- TIAN, L. AND LAWRENCE, D., 1995. Lead inhibits nitric oxide production in vitro by murine splenic macrophages. *Toxicol. appl. Pharmacol.*, **132**:156-163
- WARNER, G. AND LAWRENCE, D., 1986. Stimulation of murine lymphocyte responses by cations. *Cell Immunol.*, **101**:425-439.

(Received 6 May 2014, revised 31 July 2014)