

Full Length Research Paper

Experimental *Cassia senna* intoxication in Lohmann broiler chicks

Sawsan A. Omer^{1*}, Ebtessam M. Al-Olayan¹, Maha H. El-Amin¹, Zeinab K. Hassan¹,
Maha H. Daghestani¹ and Osama B. Mohammed²

¹Department of Zoology, College of Science, King Saud University, University Centre for Women Students,
P. O. Box 22452, Riyadh 11495, Saudi Arabia.

²Department of Zoology, College of Science, King Saud University, P. O. Box 2455, Riyadh 11451, Saudi Arabia.

Accepted 17 January, 2012

The aim of this study was to evaluate the toxic effects of *Cassia senna* fruits in Lohman broiler chicks. Chicks fed with diet containing 2 and 5% *C. senna* fruit for 4 weeks, thereafter the chicks in the two groups were fed with control diet for 2 weeks. Depression in body weight, weight gain, inefficiency of feed utilization and anaemia was observed in chicks fed with 2 and 5% *C. senna* compared with the control diet. There were significant increase in the serum values of sorbitol dehydrogenase, lactate dehydrogenase, glutamate dehydrogenase, glutamate oxaloacetate transaminase, acid phosphatase uric acid and significant decrease in the blood values of haemoglobin concentration (Hb), packed cell volume (PCV) and red blood corpuscle (RBC) in test chicks were compared to those of the control group. Liver showed vacuolation of the centrilobular hepatocytes in the two groups. Kidneys showed degeneration and or necrosis of the epithelial cells of the tubules, scattered lymphoid nodules and shrinkage of the glomerular tufts. Catarrhal enteritis and focal degeneration of the intestinal mucosa were observed in test groups. At the end of the period following withdrawal of senna meals the damage to the vital organs was reduced but neither the hepatocytes nor the cells of the renal tubules had completely reverted to normal.

Key words: *Cassia senna*, toxicity, chicks, haematology and biochemistry.

INTRODUCTION

Some plants used in traditional medicine have such narrow therapeutic index that their use is toxic. The use of *Indigofera hochstetteri* and *Indigofera spitata* (Leguminosae) cause varying degrees of fatty change in the liver of young ruminants and birds (Kingbury, 1964). *Citrullus colocynthis* produce catarrhal enteritis and degeneration of centerlobular hepatocytes and renal tubular epithelium in goats, calves and mice (Barri, 1980).

Cassia senna is locally known as Senna Mekka and is widely distributed in the plains of Central and Northern Sudan. This plant and derived products play an important role in the primary health care of Sudan (UNIDO, 1996). The plant is also found in different parts of Saudi Arabia. *C. senna* is used in traditional medicine as antifungal,

antibacterial, anti-constipation (laxative), fever antihelmintic (against round worms) and in the treatment of eruptive skin condition (Ageel et al., 1987). It contains anthraquinones and anthrones (Al-Yahya et al., 1990; Yagi, 1997). These are the main constituents that stimulate the peristaltic movement of the large intestines, hence, (senna) purgative effect of this plant (Ageel et al., 1987; Al-Yahya et al., 1990). In many African countries, toxicoses with medicinal plants are encountered among the village population who depend only on traditional medicine. Most cases of poisoning result from over dosage is because, in general, there is no standardized dose system in traditional medical practical practice.

The Genus *Cassia* comprises more than 40 species amongst which some are economically important in the production of timber, gum, tanning, dying materials and fish poisons. In the Sudan, the genus is represented by at least 13 species (Andrews, 1952). *C. senna* and *Cassia italica* (Leguminosae) were the first *Cassia* species

*Corresponding author. sawsanaomer@gamil.com. Tel: 00966504140713. Fax: 0096614678514.

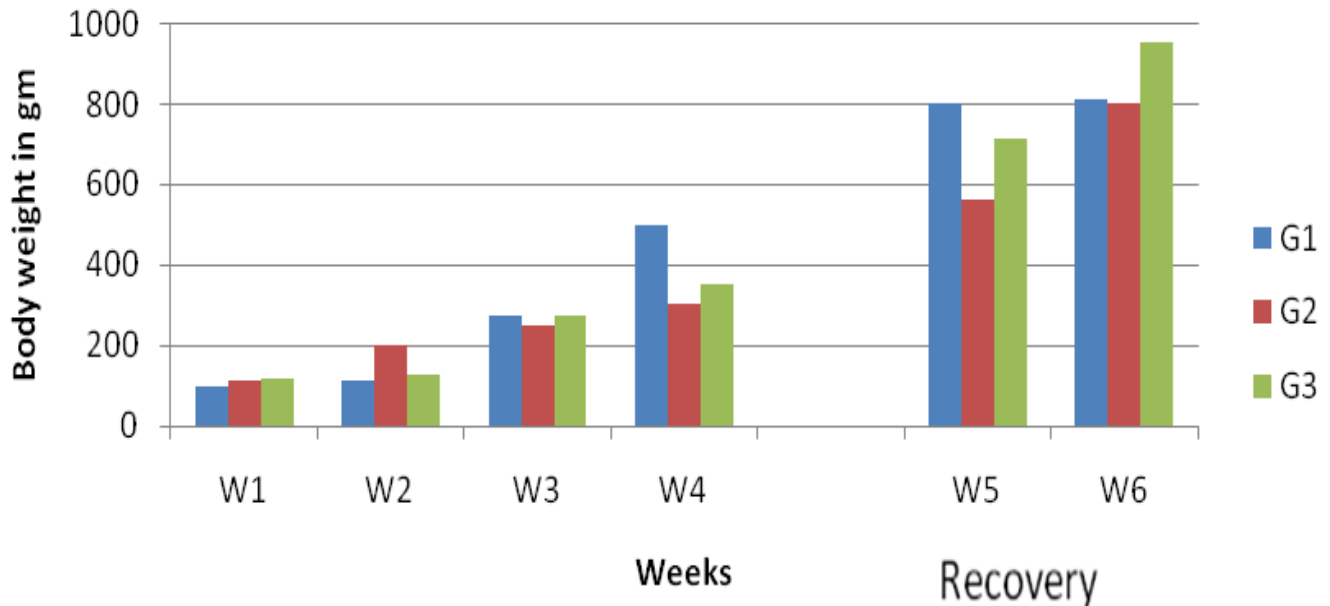


Figure 1. Body weight changes in *C. senna* feed chicks and control.

recorded in the literature for their therapeutic effect.

The phytochemistry of *Cassia* species, *Ambrosiamaritima*, *Geigeria alata*, *Cymbopogon nervatus* and *Cymbopogon schoenathus* has received considerable interest (Modawi et al., 1984).

The present study was undertaken to evaluate the possible toxicity of *C. senna* to chicken through detecting changes in the haematological and serochemical parameters; histological alterations, as well as effect of withdrawal of the feed containing *C. senna* fruits.

MATERIALS AND METHODS

Experimental design

Forty five 1-day old Lohmann commercial broiler chicks of either sex were kept in cages in the poultry house at the Faculty of Veterinary Medicine, University of Khartoum, under illumination at night and early morning. Feed and water were provided *ad libitum*. At day 7, the chicks were allotted at random to three groups of 15 each. Chicks in group 1 were controls or fed a starter diet. *C. senna* ripe fruits were purchased from Omdurman central market and the plant was authenticated by Professor Ekhlal MM Abdelbari, Department of Botany, Faculty of Science, University of Khartoum. Fruits of *C. senna* were cleaned and then added to the starter mash to give the formulations with dietary concentrations of 2% (group 2) or 5% (group 3). The experimental diets were fed to chicks for 4 weeks after that time they were withdrawn and replaced by the control feed for a 2-week recovery period.

Three chicks from each group were slaughtered weekly for pathological examination. Blood samples were collected at each slaughter for haematology and serum chemistry analysis. At necropsy all chicken were examined for gross lesions. Representative samples of each of the liver, kidneys, heart, and intestine were fixed in neutral buffer formalin, embedded in paraffin, sectioned and stain in haematoxylin and eosin (H&E).

Evaluation of body weights, haematological and serochemical parameters

Mean body weights, weight gains and feed conversion ratios (kg feed consumed/kg weight gain) were determined for each group weekly. Blood samples were examined for packed cell volume (PCV), haemoglobin concentration (Hb), red blood corpuscle (RBC) count and red corpuscle indices including mean corpuscular volume (MCV) and mean corpuscular haemoglobin concentration (MCHC) according to the standard methods (Jain, 1986). Serum samples were analysed for the activities of glutamate dehydrogenase (GDH), sorbitol dehydrogenase (SDH), acid phosphatase (ACP), Lactate dehydrogenase (LDH), glutamate oxaloacetate transaminase (GOT) and for the concentrations of total protein, uric acid and calcium using commercial kits (Linear Chemicals sl, Joaquim Costa, 18 to 2a planta, 08390 Montgat, Spain).

Statistical analysis was assessed using student t-test (Sokal and Rohlf, 1981) on the computer program Sigmastat (sigmastat statistical software, version 2.03, SPSS Inc). A value of $p \leq 0.05$ was considered to be significant for statistical tests.

RESULTS

The effect of dietary *C. senna* in concentration of 2% (group 2) and 5% (group 3) of the basic diet on body weight, weight gain and feed conversion ratios given in Figures 1, 2 and 3. Statistical analysis reveal that Senna fed in diet in concentration of 2 and 5% for 4 weeks significantly depressed body weights ($p < 0.05$), weight gains ($p < 0.05$) and feed efficiency ($p < 0.05$) compared to control chicks in group 1. At the end of 2 weeks recovery period, the body weight of birds in group 3 were higher and statistically significant ($p < 0.05$) than that of birds in groups 1 and 2. Efficiency of feed utilization in control groups was significantly higher ($p < 0.05$) than the

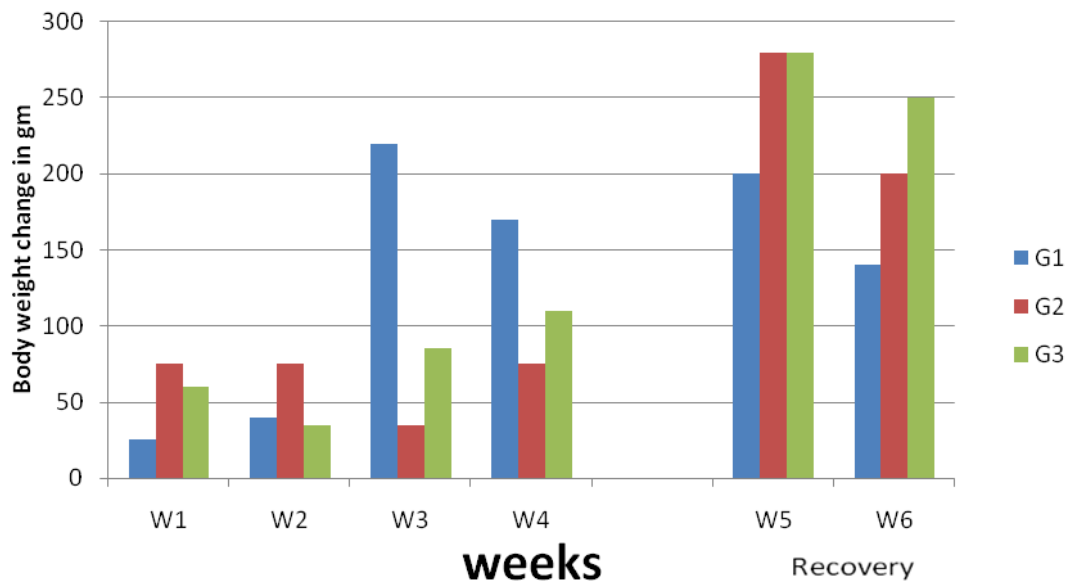


Figure 2. Weight gain change in control and *C. senna* fed chicks.

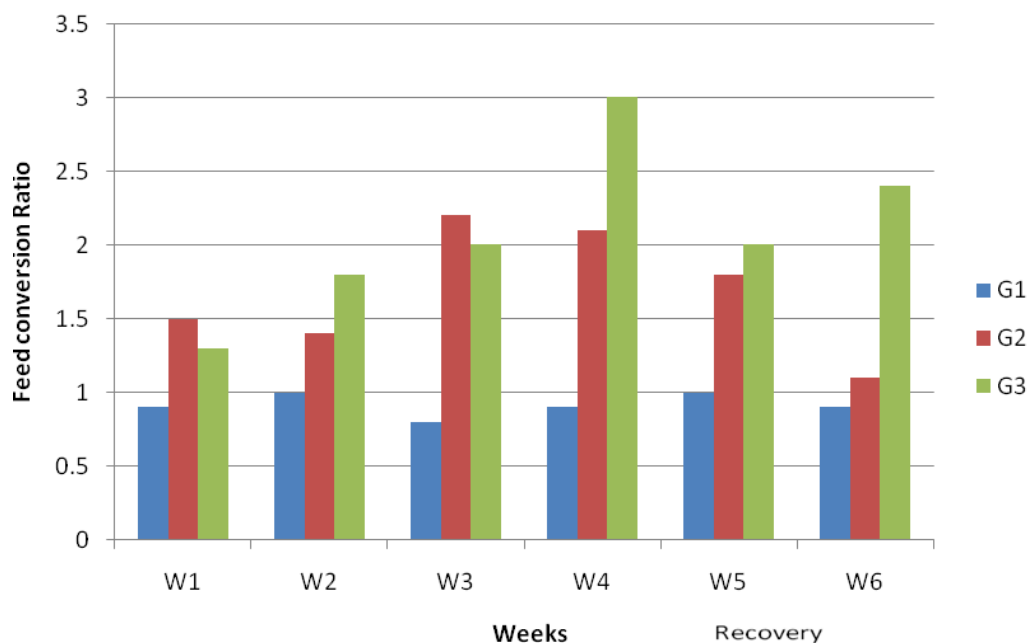


Figure 3. Changes in feed conversion ratio in *C.senna* chicks and control.

test groups 2 weeks after withdrawal of the experimental diets.

During the feeding of *C. senna* diet period, haemorrhages and or congestion were most frequently seen in the heart, intestines, liver and kidneys and less frequently in the spleen. Congestion and haemorrhages were more marked in group 3 than group 2. The liver showed vacuolation of the centrilobular hepatocytes, numerous lymphocytic nodules and focal necrosis. The

kidneys showed degeneration and or necrosis of the epithelial cells of the proximal convoluted tubules, scattered lymphoid nodules and shrinkage of the glomerular tufts. Catarrhal enteritis and focal degeneration and or necrosis of the cardiac muscle fibers were observed. At the end of the period following withdrawal of senna meals the damage to the vital organs was reduced but neither the hepatocytes nor the cells of the renal tubules had completely reverted to normal. No

Table 1. Changes in serum enzymes activities and concentrations of calcium, uric acid, and total protein in Lohmann chicks fed various levels of dietary *C. senna*. G1 = Controls; G2 = 2% Senna; G3 = 5% Senna. N.S. = Not Significant.

Parameter	Senna feeding			Senna withdrawal (recovery)		
	Group			Group		
	1	2	3	1	2	3
LDH (IU)	191.3 ±11.3	225.7±115.8 (p<0.05)	426.5±51.2 (p<0.05)	175.5±7.3	258±53.7 (p<0.05)	513±32.5 (p<0.05)
SDH (IU)	12.3 ± 4.2	85.6±49.6 (p<0.05)	166±33.9 (p<0.05)	15±2.9	123±22.4 (p<0.05)	174±27.2 (p<0.05)
GDH (IU)	9.4±3.8	9.3±5.1 ^{NS}	9.55±3.2 ^{NS}	11±0.03	11.5±1.8 ^{NS}	14.5±2.1 (p<0.05)
ACP (IU)	27.2±2.8	50.1±15 (p<0.05)	69.1±18.4 (p<0.05)	48.7±18.1	80.5±12.4 (p<0.05)	70.4±13 (p<0.05)
GOT (IU)	24± 2.3	41±14.3 (p<0.05)	43.6±10.8 (p<0.05)	24.13±1.3	41.24±11.3 (p<0.05)	45±7.9 (p<0.05)
TP (g/l)	34.4±2.9	38.5±3.8 (p<0.05)	38.3±0.9 (p<0.05)	36.5±1.4	38.3±2.8 (p<0.05)	38.7±0.7 (p<0.05)
UA (mmol/l)	356±8.3	672±165.9 (p<0.05)	495±98.1 (p<0.05)	357±42.8	446±38.7 (p<0.05)	529±85.1 (p<0.05)
Ca (mmol/l)	2.2±0.03	1.8±0.2 (p<0.05)	1.8±0.2 (p<0.05)	2.1±0.3	1.9±0.2 (p<0.05)	1.7±0.2 (p<0.05)

Table 2. Haematological changes in Lohmann broiler chicks fed *C. Senna* for 4 weeks. Values are mean ±S.D for the 3 groups. G1 = Control chicks; G2 = 2% Senna; G3 = 5% Senna. N.S. = Not Significant.

Parameter	Senna feeding			Senna withdrawal (recovery)		
	Group			Group		
	1	2	3	1	2	3
Hb (g/dl)	8.8±0.06	7.1±0.1 (p<0.05)	6.5±0.090 (p<0.05)	8.1±0.5	9±0.5 ^{N.S}	8±0.01 ^{N.S}
PCV (%)	28.5±1.3	22.9±0.3 (p<0.05)	21.3±0.60 (p<0.05)	24±0.5	30±2.40 (p<0.05)	27±1.20 (p<0.05)
RBC (X10 ⁶ /μl)	2.1±0.1	1.75±0.09 (p<0.05)	1.7±0.08 (p<0.05)	1.8±0.5	2.1±0.5 (p<0.05)	1.9±0.05 ^{N.S}
MCV (fl)	135.5±1.7	130.6±3.3 (p<0.05)	125.3±3.4 (p<0.05)	133.3±0.5	142.3±3.8 (p<0.05)	142.6±2.4 (p<0.05)
MCHC (%)	30.9±1.4	31±1.4 ^{N.S}	30.5±2.50 ^{N.S}	33.8±0.5	30±0.50 (p<0.05)	29.6±1.1 (p<0.05)

histopathological changes were seen in control chicks.

During the toxicity period, the values of SDH, LDH, GDH, GOT and ACP in the serum of senna-fed chicks in groups 2 and 3 were significantly elevated ($p < 0.05$) compared to the control chicks (group 1). In both test groups, the activity of serum ALP was significantly higher ($p < 0.05$) than the controls, 3 weeks after the commencement of senna feeding and it remained higher at the end of the recovery period (Table 1). In groups 2 and 3, uric acid concentration was significantly higher ($p < 0.05$) than the control group at week 1 through week 4. In

group 3, control values have not been attained 2 weeks after withdrawal of the experimental diet. In the test chicks, the concentration of serum calcium was significantly lower ($p < 0.05$) than the control group at week 2 or week 3 but value return to normal at the end of recovery period. In the test chicks, the concentration of serum total protein fluctuated above control value throughout the experiment. The haematological changes in the test groups were shown by significantly lower Hb, PCV, and RBC values ($p < 0.05$) compared to those of the control groups (Table 2). However, the value of those

parameters together with those of MCV and MCHC in the test group was different ($p < 0.05$) from those in the control group 2 weeks after withdrawal, but the experimental ration remained the same within the normal range.

DISCUSSION

C. senna fruit were non-lethal to Lohmann-type broiler chicks when fed at 2 or 5% in the feed for 4 weeks. Depression in weight gain probably due to fact that feed intake was progressively reduced as the percentage of seeds in feed increased. This is in agreement with Page and others, who found that feed consumption was decreased for birds fed *Cassia obtusifolia* at 2% in diet (Page et al., 1977). In this study, the body weights of Lohmann broiler chicks began to increase and values reached levels comparable to control 2 weeks after exposure to *C. senna* was ended. The consumption of *C. senna* by Lohmann chicks resulted in lesions typical of intoxication by other *Cassia* species. It well known that *C. senna*, *C. occidentalis* cause a variety of lesions in animals among which are skeletal and or myocardial degeneration and congestion in the kidney and enteritis (Mercer et al., 1967; Barri et al., 1983; Galal and Adam, 1983). Enterohepatonephropathy which indicated by reduction in growth and impairment of the excretory rate of liver and kidney explain that the plant contain toxic constituents. The values of SDH, LDH, GDH, GOT and uric acid in the serum of senna -fed chicks in groups 2 and 3 were found to be significantly higher ($p < 0.05$) than the control chicks (group 1) and this contribute to hepatorenal damage. *C. senna* fed fruit at 10% in normal diet in Wistar rats caused enterohepatonephrotoxicity associated with changes in serum ALT, AST, ALP activities and in urea, total protein, albumin, globulin and calcium concentrations (Adam et al., 2001).

The concentration of serum calcium in test chick was significantly lower than control chicks at week 2 and 3 but the value return to normal at the end of the recovery period. The pathogenesis of hypocalcaemia has been described by Cornelius (1989).

The values of Hb, PCV and RBC were lower ($p < 0.05$) than the control group. However the value of these parameters and of MCV and MCHC in a test groups were different ($p < 0.05$ to 0.01) from those in the control group 2 weeks after withdrawal of *C. senna* containing food these suggest that one of plant constituent may have depressant effect in the hemopoietic organs.

We have shown that 2 and 5% of *C. senna* fruits in the basic diet are toxic to Lohmann broiler chicks and damage to the vital organs can persist for 2 weeks after *C. senna* containing food is withdrawn. Additive Toxic effect has been seen in the goats given a dietary mixture

of *Aristolochia bracteolate* and *Cadaba rotundifolia* (El-Dirdiri et al., 1987). Further investigations are required to evaluate the mode of actions of the active constituents of the plant since humans and animals are continuously exposed to this plant and its extracts.

ACKNOWLEDGEMENTS

The authors extend their appreciation to the Deanship of Scientific Research at King Saud University for funding the work through the Research Group Project No.RGP-VPP-074.

REFERENCES

- Adam SEI, Al-Yahya MA, Al-Farhan AH (2001). Combined toxicity of *Cassia senna* and *Citrullus colocynthis* in rats. *Vet. Hum. Toxicol.*, 43: 70-72.
- Ageel AM, Tariq M, Mossa JS, Al-Yahya MA, Saied MS (1987). Plants used in Saudi Folk Medicine. King Abdulaziz for Science and Technology (KACST), King Saud University Press, Riyadh, p. 106.
- Al-Yahya MA, Al-Al-Meshal IA, Mossa JS, Al-Badr M, Tariq M (1990). Saudi Plants: A Phytochemical and Biological Approach, King Abdulaziz City for Science and Technology. King Saud University Press, Riyadh, p. 186.
- Andrews FW (1952). The flowering plants of Anglo-Egyptian Sudan. Vol 2., T. Buncle Co. Ltd., Abroath, Scotland, p. 485.
- Barri MES (1980). The effects of *Citrullus colocynthis* and *Crotalaria saltina* on calves, Goats and mice. M.V.Sc. Thesis, University of Khartoum, Sudan. p. 167.
- Barri ME, Onsa TO, Elawad AA, Elsayed NY, Wasfi IA, Abdel Bari EM, Adam SEI (1983). Toxicity of five Sudanese plants to young ruminants. *J. Comp. Pathol.*, 93: 559-675.
- Cornelius CE (1989). Liver functions. In: *Clinical Biochemistry of Domestic Animals*. (Ed) Kaneko JJ. Academic Press Inc, San Diego, pp. 364-397
- El-Dirdiri N, Barakat SEM, Adam SEI (1987). The combined toxicity of *Aristolochia bracteolate* and *Cadaba rotundifolia* to goats. *Vet. Hum. Toxicol.*, 29: 133-137.
- Galal M, Adam SEI (1983). Experimental *Chrozophra plicata* poisoning in goats and sheep. *Vet. Hum. Toxicol.*, 30: 447-450.
- Jain NC (1986). *Schalm's Veterinary Haematology*. 4th Ed. Philadelphia: Lea and Febiger, p. 1221.
- Kingbury JM (1964). *Poisonous Plants of the United States and Canada*. Prentice-Hall, Englewood, Cliffs, NJ, USA, p. 145.
- Mercer HD, Neal FC, Himes JA, Edds GT (1967). *Cassia occidentalis* toxicosis in cattle. *J. Am. Vet. Med. Assoc.*, 51: 735-741.
- Modawi BM, Magar HRY, Satti AM, Duprey RJH (1984). Chemistry of Sudanese Flora: *Cymbopogon nervatus*. *Nat. Prod. J.*, 47: 167-169.
- Page RK, Vezey S, Charles OW, Hallifield T (1977). Effects on food consumption and egg production of coffee bean seed (*C. obtusifolia*) fed to white Leghorn hens. *Avian Dis.*, 1: 90-96.
- Sokal RR, Rohlf FJ (1981). *The Principles and Practice of Statistics in Biological Research*, 2nd ed. W.H. Freeman and Company, New York, p. 859.
- UNIDO (1996). Project for the Government of Sudan prepared by UNIDO industrial utilization of medicinal and aromatic plants in Sudan (Draft) Sudan, P. 354.
- Yagi SMA (1997). Phytochemical and Toxicological studies of some *Senna* species. PhD Thesis, University of Khartoum. Sudan, p. 179.