

Mandibular fractures

311 MDS

Dr Hesham Khalil

Embryology

The cartilage of the first arch (Meckel's cartilage) forms the lower jaw in primitive vertebrates. In humans it has a close positional relationship to the developing mandible but makes no contribution to it. At 6 weeks of development this cartilage extends as a solid hyaline cartilaginous rod surrounded by a fibrocellular capsule, from the developing ear to the midline of the fused mandibular processes. The two cartilages of each side do not meet at the midline but are separated by a thin band of mesenchyme. The mandibular branch of the trigeminal nerve has a close relationship to Meckel's cartilage, beginning two thirds of the way along the length of the cartilage. At this point the mandibular nerve divides into lingual and inferior alveolar branches, which run along the medial and lateral aspects of the cartilage, respectively. The inferior alveolar nerve further divides into incisive and mental branches more anteriorly.

On the lateral aspect of Meckel's cartilage, during the sixth week of embryonic development, a condensation of mesenchyme occurs in the angle formed by the division of the inferior alveolar nerve and its incisive and mental branches. At 7 weeks intramembranous ossification begins in this condensation, forming the first bone of the mandible. From this center of ossification, bone formation spreads rapidly anteriorly to the midline and posteriorly toward the point where the mandibular nerve divides into its lingual and inferior alveolar branches. This spread of new bone formation occurs anteriorly along the lateral aspect of Meckel's cartilage, forming a trough that consists of lateral and medial plates that unite beneath the incisor nerve. This trough of bone extends to the midline, where it comes into close approximation with a similar trough formed in the adjoining mandibular process.

Fate of meckel's cartilage:

- 1- Malleus of the inner ear
- 2- Sphenomandibular ligament

Muscles of mastication

▪ **Temporalis**

It is fan-shaped muscle.

Origin: from temporal fossa of the skull and temporal fascia.

Insertion into:

- 1) Tip, anterior margin and medial surface of the coronoid process of the mandible.
- 2) Anterior border of ramus of mandible.

Nerve supply: mandibular nerve.

Action:

- 1) Anterior vertical fibers: elevate the mandible (to close the mouth).
- 2) Posterior horizontal fibers: retract (pull backward) the mandible after its protraction

▪ **Masseter Muscle**

Origin: from the lower border and medial surface of the zygomatic arch.

Insertion: into the lateral surface of the ramus of the mandible.

Nerve supply: mandibular nerve.

Action:

- 1) The deep vertical fibers: elevate the mandible (to close the mouth).
- 2) The superficial oblique fibers help to protract (pull forward) the mandible.

▪ **Lateral Pterygoid Muscle**

Origin: by 2 heads

- 1) Upper head: from the infratemporal surface of greater wing of sphenoid.
- 2) Lower head: from the lateral surface of lateral pterygoid plate.

Insertion: the 2 heads unite to be inserted into

- 1) The anterior surface of the neck mandible (pterygoid fovea).
- 2) The articular disc of temporomandibular joint through its capsule.

Nerve supply: mandibular nerve.

Action:

- 1) The right and left muscles: pull the neck of the mandible and the articular disc forwards to open the mouth
- 2) One muscle acting with the medial pterygoid of the same side: protrudes the chin towards the opposite side as in chewing.

▪ **Medial Pterygoid Muscle**

Origin: by 2 heads

- 1) Superficial head: from the maxillary tuberosity.

2) Deep head: from the medial surface of lateral pterygoid plate.

Insertion: the 2 heads unite to be inserted into the medial surface of the ramus between the mandibular foramen and the angle of the mandible.

Nerve supply: mandibular nerve

Action:

- 1) The right and left muscles: when they act alternately they produce chewing movement.
- 2) One muscle acting with lateral pterygoid of the same side: elevates the mandible and helps to protrude the chin to the opposite side.

Classification of mandibular fractures

There are several ways to classify the mandibular fractures.

- General classification
- Anatomical locations
- Relation of the fracture to the site of injury
- Completeness
- Depending on the mechanism
- Number of fragments
- The shape or area of the fracture
- According to the direction of fracture or favorability for the treatment
- According to presence or absence of teeth

Kruger's general classification

- *Simple or closed*

The linear fracture which does not have communication with the exterior. Such a fracture do not produce a wound open to the external environment either through the skin, mucosa or periodontal membrane. It may or may not be displaced. Examples Fractures in the region of the condyle, coronoid process, ascending ramus, etc.

- *Compound or open*

This fracture has communication with the external environment through skin, mucosa or periodontal membrane. All the fractures involving the tooth bearing area of the mandible or where an external or intraoral wound is present involving the fracture line.

- *Comminuted*

A fracture in which the bone is splintered or crushed into multiple pieces. These types are generally due to a greater degree of violence or high velocity impact. Gunshot wounds, where missiles are traveling at a high velocity can produce these fractures.

- *Complicated or complex*

Fractures associated with the damage to the important vital structures complicating the treatment as well as prognosis.

Example Fractures with injury to the inferior alveolar vessels or nerve, facial nerve or its branches, facial vessels, condylar fractures with associated injuries to middle cranial fossa, etc.

- *Impacted*

Rarely seen in mandibular fractures. More commonly seen in maxilla. This is a fracture in which one fragment is firmly driven into the other fragment and clinical movement is not appreciable.

- *Greenstick*

A fracture in which one cortex of the bone is broken with the other cortex being bent. It is an incomplete fracture seen in young children because of inherent resiliency of the growing bone.

- *Pathological*

Spontaneous fracture of the mandible occurring from mild injury or as a result of a normal degree of muscular contraction. This is because of weakness caused due to the pre-existing bone pathology.

Areas of structural weakness may result from the following:

- *Generalized skeletal disease*
 - i. Endocrinal disorders—hyperparathyroidism or postmenopausal osteoporosis.
 - ii. Developmental disorders—osteopetrosis, osteogenesis imperfecta
 - iii. Systemic disorders—,Paget's disease, osteomalacia and severe anaemia.
- *b. Localized skeletal disease* various cysts, odontomes, tumors, osteomyelitis, osteoradionecrosis affecting the local region.

Anatomical Location

- *Rowe and Killey's classification*

A. Fractures not involving the basal bone—are termed as dentoalveolar fractures.

B. Fractures involving the basal bone of the mandible.

Subdivided into following:

- i. Single unilateral
- ii. Double unilateral
- iii. Bilateral
- iv. Multiple.

- *Dingman and Natvig's classification by anatomic region*

A. Symphysis fracture (midline fracture).

B. Canine region fracture.

C. Body of the mandible between canine and angle.

- D. Angle region—triangular region bounded by the anterior border of the masseter to the posterosuperior attachment of the masseter.
- E. Ramus region—bounded by the superior aspect of the angle to two lines forming an apex at the sigmoid notch.
- F. Coronoid region.
- G. Condylar fractures.
- H. Dentoalveolar region.

Relation of the Fracture to the Site of Injury

- i. Direct fractures,
- ii. Indirect fractures.

Completeness

Complete and incomplete fractures.

Depending on the Mechanism

- i. Avulsion fracture
- ii. Bending fracture
- iii. Burst fracture

Number of Fragments

- Single, multiple, comminuted, etc.

Shape or Area of the Fracture

- Transverse, oblique, butterfly, oblique surfaced.

According to the Direction of Fracture and

Favorability for Treatment

- a. Horizontally favorable fracture
- b. Horizontally unfavorable fracture
- c. Vertically favorable fracture
- d. Vertically unfavorable fracture.

This classification is aimed toward the angle fractures. Here, the direction of fracture line is important for resisting the muscle pull. When the muscle pull resists the displacement of the fragments then the fracture line is considered as *favorable*. If the muscle pull distracts the fragments away from each other, resulting in displacement, then the fracture line is considered as *unfavorable*.

The elevator group of muscles exert an upward, forward and medial pull, while depressor group of muscles exert a downward and backward pull in an intact mandible. Whenever there is a break in the continuity at the angle region, then these two muscle groups lose their coordinated movements and have independent action. In unilateral angle fracture, posterior ramus fragment is the lesser fragment, while the body of the mandible bearing the teeth becomes the greater fragment. The

greater fragment's position is stabilized to certain extent by the occlusion of the teeth, while posterior ramus fragment can show displacement independently.

Signs and symptoms:

- Pain
- Swelling
- Trismus
- Derangement of occlusion
- Sublingual hematoma
- Step deformity
- Deviation
- Loss of sensation due t nerve damage
- Bleeding
- Ecchymosis
- TMJ problems
- Tenderness
- Movement restriction
- Open bite
- Crepitus

Examination:

- 1- inspection
- 2- palpation

Radiographs

- 1- OPG
- 2- Lateral oblique
- 3- Postero-anterior
- 4- Reverse Townes
- 5- Intraoral films (periapical, occlusal)

- 6- CT
- 7- 3D CT
- 8- MRI (TMJ, CSF leak)

Treatment of fractures

- 1- Reduction
- 2- Fixation

Reduction

Reduction of a fracture means the restoration of a functional alignment of the bone fragments. In the dentate mandible reduction must be anatomically precise when teeth, which were previously in good occlusion, are involved. Less precise reduction may be acceptable if part of the body of the mandible is edentulous or there are no opposing teeth. The presence of teeth provides an accurate guide in most cases by which the related bony fragments can be aligned. The teeth are used to assist the reduction, check alignment of the fragments and assist in the immobilization.

Whenever the occlusion is used as an index of accurate reduction it is important to recognize any pre-existing occlusal abnormalities such as an anterior or lateral open bite. Widely displaced, multiple or extensively comminuted fractures may be impossible to reduce by means of manipulation of the teeth alone, in which case open operative exploration becomes necessary.

Immobilization (Fixation)

Following accurate reduction of the fragments, the fracture site must be immobilized to allow bone healing to occur. The speed of repair of the weight-bearing skeleton is of paramount importance in the eventual rehabilitation of an injured patient. When semi-

rigid fixation is used a fracture heals by secondary intention, which involves the formation and subsequent organization of callus. This is a relatively slow process and weight-bearing must be delayed until full bone replacement has occurred. Even apparently rigid fixation by means of non-compression plating or pinning leaves a gap between the bone ends and bony union requires organization of a primary callus.

Methods of immobilization

The methods of immobilization can be summarized as follows:

1. Osteosynthesis without intermaxillary fixation:

- (a) non-compression small plates;
- (b) compression plates;
- (c) miniplates;
- (d) lag screws;
- (e) resorbable plates and screws.

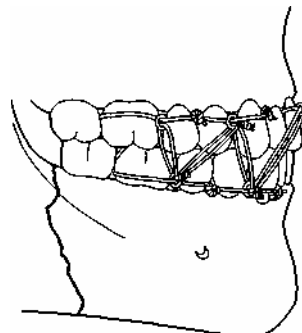
2. Intermaxillary fixation:

- (a) bonded brackets;
- (b) dental wiring:
 - (i) direct;
 - (ii) eyelet
- (c) arch bars;
- (d) cap splints;

3. Intermaxillary fixation with Osteosynthesis:

- (a) transosseous wiring;
- (b) circumferential wiring;
- (c) external pin fixation;
- (d) bone clamps;
- (e) transfixation with Kirschner wires.

Intermaxillary fixation (IMF)

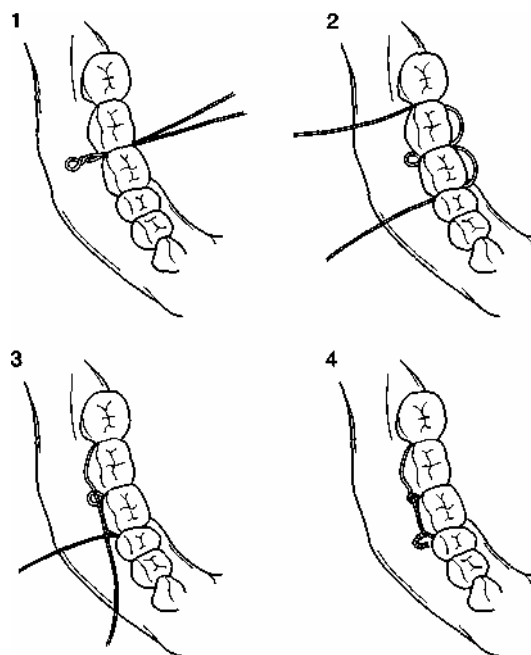


In the presence of sufficient numbers of teeth, simple fractures of the tooth-bearing part of the mandible may be adequately immobilized by intermaxillary fixation alone. Clinical union can be expected within 4 weeks in nearly all cases, and the fixation can

often be established without resorting to general anaesthesia. Intermaxillary fixation is most frequently now used to maintain the correct occlusion temporarily while some form of direct osteosynthesis is applied. A number of methods are available:

- 1-Bonded modified orthodontic brackets
- 2-Direct wiring
- 3- Interdental eyelet wiring
- 4- Arch bars
- 5- Cap splints

The IMF duration varies according to the condition of the fracture and an average of 6 weeks is usually used.

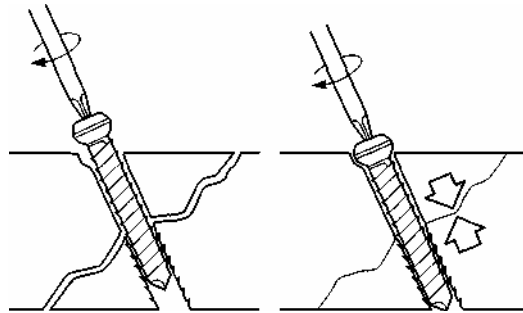


This diagram shows the eyelet wiring

Lag screws

A few oblique fractures of the mandible can be rigidly immobilized by inserting two or more screws whose thread engages only the inner plate of bone. The hole drilled in the outer cortex is made to a slightly larger diameter than the threaded part of the screw. When tightened the head of the screw engages in the outer plate and the

oblique fracture is compressed. At least two such lag screws are necessary to achieve rigid immobilization.

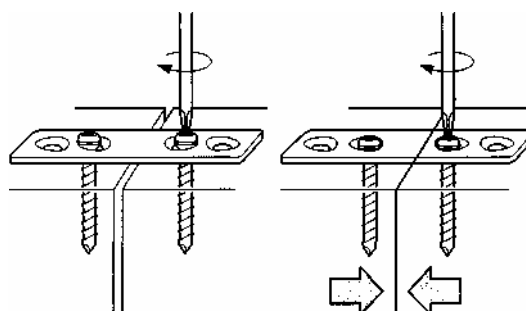


Resorbable plates and screws

The advantage of a small bone plate fashioned in a biocompatible resorbable material has been clear for some time and a number of materials have been investigated. In order to be useful for mandibular fractures these plates need to be both adaptable to the complex surface of the bone and strong enough to stabilize the reduced fracture until bone healing has advanced to the stage of stable union. The mechanical requirements for the fixation of fractures of the upper and mid-facial skeleton are less but the plates need to be smaller than those which can be applied to the mandible.

Compression plates

Compression osteosynthesis of mandibular fractures is based on the firm biological principles established for the treatment of fractures of weight-bearing long bones. However, non-union or delayed union is rarely a problem in fractures of the mandible or other facial bones. On the other hand, precise reduction is essential in the dentate mandible and precise reduction is difficult to achieve with compression plating techniques. It is probably true to say that compression plates have now been abandoned by the majority of maxillofacial treatment centers



Teeth in the fracture line

Teeth in the fracture line are a potential impediment to healing for the following reasons:

1. The fracture is compound into the mouth via the opened periodontal membrane.
2. The tooth may be damaged structurally or lose its blood supply as a result of the trauma so that the pulp subsequently becomes necrotic.
3. The tooth may be affected by some preexisting pathological process, such as an apical granuloma.

The fracture line can become infected as a result of any of the above - either from the oral cavity via the disrupted periodontium or directly from an infected pulp or apical granuloma. Infection of the fracture line will result in greatly protracted healing of the fracture or even non-union.

Fractures at the angle of the mandible with teeth in the fracture line are more likely to become infected than at other sites

Absolute indications for removal of a tooth from a mandibular fracture line:

1. Longitudinal fracture involving the root.
2. Dislocation or subluxation of the tooth from its socket.
3. Presence of periapical infection.
4. Infected fracture line.
5. Acute pericoronitis.

Relative indications for removal of a tooth from the fracture line:

1. Functionless tooth which would eventually be removed.
2. Advanced caries.
3. Advanced periodontal disease.
4. Doubtful teeth which could be added to existing dentures.
5. Teeth involved in untreated fractures presenting more than 3 days after injury.

It is desirable that all teeth not covered by these conditions should be retained.

Children

Some modifications of the foregoing principles of treatment of the fractured mandible are necessary when the fracture occurs in a child. Fractures of the mandible are uncommon in children owing to the fact that the bone is resilient at this period of life and

considerable force is required to cause fracture. The line of demarcation between the medulla and cortex is less well defined than in adults, whereas the ratio of bone to tooth substance is high. Incomplete dysjunction in the form of a 'greenstick' fracture is therefore more likely and there is a greater risk of damage to developing teeth than in later years. The treatment of mandibular fractures in children before puberty is generally of a conservative nature because of the rapidity of healing and the adaptive potential of the bone and its contained dentition. If the severity and displacement of the fracture are of sufficient degree to warrant immobilization of the mandible, some modification of technique is required because of the presence of unerupted or partially erupted teeth of the permanent dentition and deciduous teeth of variable mobility.

In patients below the age of 9 or 10 years the body of the mandible is congested with developing teeth. It is unsafe to apply transosseous wires or to insert bone pins or plates in these circumstances. In exceptional instances, such as gross displacement of a symphysis or angle fracture, the lower border may be either wired with caution, or a small miniplate applied with the shortest possible screws.