

Yield and complications of flexible fiberoptic bronchoscopy in a teaching hospital

Abdulaziz H. Alzeer, FRCP, Hadil A. Al-Otair, MRCP(UK), Mohammed S. Al-Hajjaj, FRCP.

ABSTRACT

الهدف: تقييم مدى فعالية تنظير القصبات بالمنظار القصبي الليفي المرن في تشخيص الحالات المرضية وتقييم الاختلاطات الناجمة عن هذا الفحص في مستشفى الملك خالد الجامعي (مستشفى كبير في الرياض - المملكة العربية السعودية).

الطريقة: مراجعة لتقارير تنظير القصبات مع ما يوافقها من نتائج المرضى الذين خضعوا للتنظير خلال ثلاث سنوات من كانون الثاني (يناير) ٢٠٠٤م وحتى كانون أول (ديسمبر) ٢٠٠٦م، حيث تتضمن هذه المراجعة أستطبابات التنظير التشخيصي المحتمل ، التشخيصي النهائي و الاختلاطات التي سجلت أثناء وبعد التنظير.

النتائج: تم إجراء الدراسة على ٧٠٧ مريض. ٥٩٢ (٨٣,٧ %) خضعوا لتنظير القصبات بهدف تشخيصي ، ١١٥ (١٩,٣ %) خضعوا لتنظير القصبات بهدف علاجي ، متوسط العمر ٤٢+ - ١٨ عام ، الخمج (الأنتان) بالتفطرات السلية (الدرن) والسرطان كانا أهم الاستطبابات لإجراء التنظير (٣٥,٩ % و ٢٥,٩ %) بالترتيب والنتيجة الإجمالية لقدرة التشخيصي كانت ٥٨,٠ % . تم تأكيد تشخيصي التدرن (السل) في ٦٧,٠ % من الحالات المشتبه بها ، ذات الرئة الجرثومية تأكيد تشخيصي ٤٠,٥ % ، وتم تأكيد الأورام السرطانية في ٦١,٢ % من الحالات المشتبه بها باستخدام إجراءات تنظيرية مختلفة . وتم تشخيص ٣٧ (٤٣,٣ %) مريض من أصل ٨٦ مريض مصاب بأمراض الرئة الخلالية ، حيث تم تشخيص الداء الفرواوي (الساركويتد) بنسبة ٥٧,٠ % أو ذات الرئة الخلالية العادية بنسبة ٤٠,٠ % بينما تم تأكيد مرض (Boop) بنسبة ٨٨,٠ % والنسبة الإجمالية للاختلاطات كانت ٥,٠ % حيث لوحظ حدوث تراوح الصدر بنسبة ٠,٥٦ % وكان حدوثه بشكل خاص فقط مع أخذ الخزعة عبر القصبات ، معدل الوفيات كان صفر بالمئة .

خاتمة: يعتبر استخدام المنظار القصبي الليفي المرن لتنظير القصبات وسيلة تشخيصية ناجحة ، وبنسبة اختلاطات منخفضة القدرة لتشخيصه في مركزنا كانت مماثلة لتلك في المراكز الغربية .

Objective: To assess the diagnostic yield and safety of flexible fiberoptic bronchoscopy (FFB).

Methods: A retrospective review of bronchoscopy reports and corresponding patients' charts over 3 years from January 2004 - December 2006 in King Khalid University Hospital, Riyadh, Kingdom of Saudi Arabia. Indication for procedure, suspected diagnosis, final diagnosis, and complications were reported.

Results: Out of 720 patients, 707 (98.2%) patients had a full follow up. Five hundred and ninety-two (83.7%) underwent FFB for diagnostic purposes and 115 (16.3%) for therapeutic purposes. The mean age was 42 ± 18 years. Infection, including mycobacterium tuberculosis, and malignancy were the 2 main indications for FFB (35.9% and 25.9%). The overall diagnostic yield was 58%. Tuberculosis was diagnosed in 67% of suspected cases, whereas bacterial pneumonia was diagnosed in 40.5%. Malignancy was confirmed in 61.2% of suspected cases. Bronchoscopy diagnosed 37 (43%) of 86 patients with interstitial lung disease. The diagnostic yield was 57% for sarcoidosis, 40% for usual interstitial pneumonia and 88% for bronchiolitis obliterans organizing pneumonia. The overall complication rate was 5%; pneumothorax occurred in 0.56% and was associated exclusively with transbronchial biopsy. No mortality was observed.

Conclusion: Flexible fiberoptic bronchoscopy is a useful diagnostic tool with a low rate of complications. The diagnostic yield in our institution is similar to that reported in Western series.

Saudi Med J 2008; Vol. 29 (1):

From the Pulmonary Division, Department of Medicine, King Khalid University Hospital, Riyadh, Kingdom of Saudi Arabia.

Received 22nd April 2007. Accepted 12th August 2007.

Address correspondence and reprint request to: Dr. Abdulaziz H. Alzeer, Associate Professor, Department of Medicine (38), King Khalid University Hospital, PO Box 18321, Riyadh 11415, Kingdom of Saudi Arabia. Tél. +966 (1) 4672698. E-mail: alzeerahm@yahoo.com

Flexible fiberoptic bronchoscopy (FFB) is a well established procedure in pulmonary medicine. It is considered an important tool in the diagnosis, staging, and the therapy of lung cancer and many other varieties of pulmonary diseases.¹⁻³ Its safety and diagnostic yield have been reported before.²⁻⁴ Complications are well known but rare.^{4,5} Several medical centers all over the world have discussed their experience using this technique. Their diagnostic yield varied due to differences in techniques, patient's recruitment, and local laboratory experience.⁶⁻⁹ In the Middle East however, there have been few reports of using bronchoscopy as a diagnostic procedure.^{10,11} These reports are either descriptive or had a relatively small number of patients. Therefore, we decided to assess the diagnostic yield of routine bronchoscopy in patients with different pulmonary diseases in a large university hospital in Riyadh, Saudi Arabia.

Methods. All consecutive FFB were retrospectively reviewed using bronchoscopy reports and corresponding patient's charts over 3 years from January 2004 - December 2006 in King Khalid University Hospital, Riyadh, Saudi Arabia. The study was approved by the hospital's ethical committee and consent was obtained from each patient prior to procedure. Each FFB was completed by a pulmonary physician or a fellow under a consultant's supervision. Demographic data were recorded including: age, gender, indication for procedure, pre-medication, radiographic findings, suspected diagnosis, bronchoscopy findings, final diagnosis, and complications of bronchoscopy. Suspected diagnosis was based on clinical and radiographic findings whereas final diagnosis was based on microbiological and histopathological diagnosis. The procedure was performed using a fiberoptic bronchoscopy (Olympus BF type 1 T260) in an equipped endoscopy suite. In the case of unstable or intubated patients, the procedure was performed in the intensive care unit (ICU). Pre-medication consisted of administration of inhaled and liquid xylocaine to the oropharynx and nostrils. Midazolam and other pre-medications were left to the discretion of the pulmonary physician. All patients were supplemented with oxygen through nasal cannula and were continuously monitored with electro-cardiogram and pulse oximetry. Bronchoscopy was performed in supine position. Liquid xylocaine 2% was administered through the bronchoscope directly to the vocal cords and the bronchial tree as needed. Bronchial brushing, bronchoalveolar lavage (BAL), bronchial biopsy (BB) were performed as international recommendations.¹² Transbronchial biopsy (TBB) was performed blindly.

Statistical analysis. Data collected were encoded into MS Excel 2003 for windows XP professional. Age was presented as mean \pm standard deviation. Due to

the descriptive nature of this study, all other data were presented as percentages (%).

Results. A total of 720 patients underwent FFB procedures. Thirteen patients (1.8%) were excluded due to incomplete follow up data. The remaining 707 patients were studied. Their mean age was 42 ± 18 years and 452 (63.9%) were males. Of 707 bronchoscopies, 592 (83.7%) were diagnostic and 115 (16.3%) were therapeutic. A total of 540 BAL, 267 cytobrushing, 129 TBB, and 78 BB were performed. Indications for bronchoscopy are shown in Table 1. The overall diagnostic yield was 344 (58%). Infection including TB was suspected in 35.9%, followed by malignancy in 25.9%. Active TB was suspected in 91 (35.8%) while 163 (64.2%) had unresolved pneumonia (Figure 1). Bacterial pneumonia was diagnosed microbiologically in 66 (40.5%), pneumocystis carinii pneumonia in 3 (1.8%) and Candida species in 10 (6.1%). In 10 (4.9%) patients alternative diagnosis was confirmed, mainly TB and 2 patients had bronchiolitis obliterans organizing pneumonia (BOOP). In the remaining 74 (45.4%) samples no organisms were isolated. Overall, FFB was diagnostic of pulmonary TB in 61 (67%) patients. Bronchoalveolar lavage of 23 (37.7%) samples with 3 smear-negative sputum where positive with AFB stain whereas, BAL culture was positive in 50 (54.9%) samples. Transbronchial biopsy revealed granule in 11 (9.9%). Tuberculosis was excluded in 30 patients, out of which 19 patients were treated for pneumonia. Of 183 patients, suspected to have malignancy, 112 (61.2%) patients were confirmed using various bronchoscope procedures, BB were positive in 68 (37.2%), cytobrushing in 53 (29%), and BAL in 56 (30.6%). Surgical biopsy proved malignancy in 24 (13.1%) patients. The

Table 1 - Indications of bronchoscopy of all patients (n=707).

Indications	No. of patients (%)	
<i>Diagnostic</i>		
Suspected infection	254	(35.9)
Tuberculosis	91	(35.8)
Pneumonia	163	(64.2)
Suspected malignancy	183	(25.9)
Suspected interstitial lung disease	86	(12.2)
Hemoptysis	69	(9.8)
<i>Therapeutic</i>		
Retained secretion	102	(14.4)
Foreign body	3	(0.4)
Others	10	(1.4)

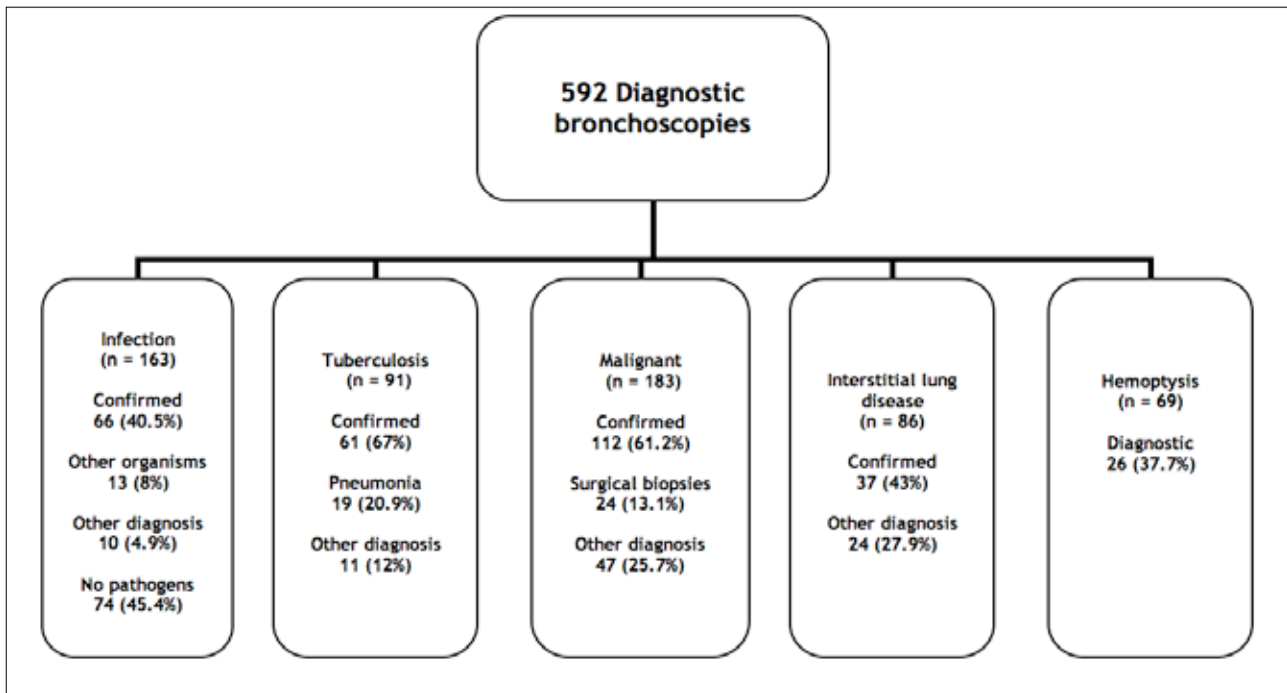


Figure 1 - Diagnostic yield of Flexible fiberoptic bronchoscopy in 592 patients.

Table 2 - Percentage of complications of bronchoscopy (n=707).

Complications	No. of patients (%)
Hypoxia	14 (2.0)
Minor bleeding	10 (1.4)
Pneumothorax	4 (0.6)
Bronchospasm	3 (0.4)
Massive bleeding	2 (0.3)
Bradycardia	2 (0.3)
Total	35 (5.0)

remaining 47 (25.7%) patients alternative diagnosis was confirmed; mainly bronchiectasis, infection, and interstitial fibrosis. Endobronchial malignancies were diagnosed in 65 patients (94.2%) out of 69 who had a macroscopically visible tumor. Interstitial lung disease was confirmed in 37 (43%) patients with TBB. Out of 21 patients with sarcoidosis, 12 (57%) were diagnosed by TBB and endobronchial biopsy. The other 6 patients were diagnosed on the basis of CT scan of the lung and/or skin and liver biopsy, and the remaining 3 patients by open lung biopsies. In 20 UIP patients, 8 were diagnosed (40%) by TBB, 6 patients by CT scan, and 6 patients underwent open lung biopsy. Out of 4 patients with non specific interstitial pneumonitis, 2 were diagnosed by TBB. Bronchiolitis obliterans

organizing pneumonia was diagnosed in 8 of 9 patients by TBB. The rest of TBB revealed extrinsic allergic alveolitis in 2, eosinophilic pneumonia in 4 and radiation pneumonitis in one. Only 26 (37.7%) patients with hemoptysis were confirmed to have existing pathology, 5 with malignancy, 10 with pneumonia, 7 with chronic bronchitis and 4 due to post nasal discharge (one of them had allergic rhinitis and 3 had nasal polyps). Complications are shown in Table 2.

Discussion. The study confirms the importance of FFB in the diagnosis of different pulmonary diseases. Our main finding is that, the yield from bronchoscopy in our institution is in keeping with recent published data from other parts of the world.⁶⁻⁹ Although the indication for bronchoscopy remained the same, different regions may have different priorities. Our findings are in agreement with recent reports from neighboring countries where infection was the most common indication for bronchoscopy, and was confirmed in 31-51% of cases.^{9,10} Reports from other Asian countries such as Malaysia and Ceylon confirmed that infection was the most common diagnosis made by bronchoscopy^{13,14} contrary to reports from Western countries, where infections ranked second after malignancy.^{7,8} The utility of FFB in the diagnosis of pulmonary TB is well established. Previous reports from different countries obtained a yield of 7.5-27% of BAL in smear-negative sputum.¹⁵⁻¹⁸ Our results are in

agreement with these reports, with overall diagnostic yield of 67%. However, our results are less than the study carried out by Anderson et al,¹⁹ where 19/20 (95%) had a positive culture of BAL. The discrepancy we thought was due to their performance of bronchoscopy after one single smear negative sputum sample, whereas in our study, there were 3 negative sputum samples obtained before bronchoscopy. Recently, Al-Zahrani et al²⁰ showed that multiple tests improved the diagnostic yield of induced sputum testing. We believe our results reflect the practice of our institution and are in keeping with previous major reports.^{16,21} In the present study, 163 bronchoscopies were performed due to pneumonia, and 87 bronchoscopies performed in ICU. Recent studies by Jain et al²² and Von Eiff et al²³ had shown usefulness of FFB in immunocompromised patients and they had a yield of 53-59%. The rates of positive finding in our study were 48.5% and for immunocompromised patients were 38%, which is lower than those of Jain et al.²² Many of our patients had received antibiotics before bronchoscopy. This could have reduced our diagnostic yield of pneumonia.²⁴ Flexible fiberoptic bronchoscopy is the procedure of choice in the diagnosis of bronchial malignancies. In our series, the diagnostic yield was 61.2% and for macroscopically visible malignancy, the diagnostic yield was 94.2%. These results were in agreement with the recent published review articles²² which tested the performance characteristics of various modalities for diagnosis of suspected lung cancer and has showed a 74% sensitivity of FFB in endoscopically visible tumor, followed by cytobrushing 59%, washing 48%, and combined modalities was 88%.²² The overall diagnostic yield for malignancy in our study is lower than that reported in western countries.²⁵ This can be explained by the low yield of satisfactory aspirates from peripherally located tumours, and the low positive confirmation from suspected malignancy cases due to a number of false-positive results.^{26,27} Transbronchial biopsy is important in the diagnosis of interstitial lung disease. It can exclude diseases such as sarcoidosis, lymphangitic carcinomatosis, and infection. In this study, sarcoidosis was diagnosed in 57% of cases and UIP was confirmed in 40%. Our results confer with a recent report by Berbescu et al, who confirmed the pathological changes of UIP on TBB in 9 of 22 patients with interstitial lung disease and concluded that TBB may be more useful in confirming UIP than was previously recognized.²⁸ The risk inherent in the bronchoscopy examination itself appears slight. It can virtually be eliminated by careful screening and proper preparation of the patients and skillful bronchoscopic technique.²⁹ The mortality in our study was nil and the complication rate was 5%. Previous studies gave a mortality rate ranging between 0.01% and 5%.²⁹ Our rate of major complications is more favorable than previous reports.¹⁰ This can be related to better

patient selection, highly experienced bronchoscopists and to close adherence to ATS recommendations in performing TBB and BB.²⁹ Pneumothorax occurred in 0.56% which was associated exclusively with TBB. The low rate of pneumothorax in our study supports the recent publication which concluded that TBB without fluoroscopy is a safe procedure particularly in sarcoidosis and diffuse neoplasm.³⁰ Previous reports had shown that the rate of pneumothorax varied between 0.08 and 5%.³¹

The retrospective nature of this study caused its limitations such as data maybe biased selection. Furthermore, future studies may concentrate on the new diagnostic and therapeutic bronchoscopic interventions. In summary, this study confirmed that, FFB is a safe and useful diagnostic tool. The yield of our study is similar to that of Western series and in concordance with the recent reports from this region that infection remains the leading indication for FFB.

References

1. Gasparini S. Bronchoscopic biopsy techniques in the diagnosis and staging of lung cancer. *Monaldi Arch Chest Dis* 1997; 52: 392-398.
2. Elston WJ, Whittaker AJ, Khan LN, Flood-Page P, Ramsay C, Jeffery PK, Barnes NC. Safety of research bronchoscopy, biopsy and bronchoalveolar lavage in asthma. *Eur Respir J* 2004; 24: 375-377.
3. Ouellette DR. The safety of bronchoscopy in a pulmonary fellowship program. *Chest* 2006; 130: 1185-1190.
4. Trouillet JL, Guiguet M, Gibert C, Fagon JY, Dreyfuss D, Blanchet F, Chastre J. Fiberoptic bronchoscopy in ventilated patients. Evaluation of cardiopulmonary risk under midazolam sedation. *Chest* 1990; 97: 927-933.
5. Colt HG, Prakesh UBS, Offord KP. Bronchoscopy in North America: survey by the American Association for Bronchology, 1999. *Journal of Bronchology* 2000; 7: 8-25.
6. Ortqvist A, Kalin M, Lejdeborn L, Lundberg B. Diagnostic fiberoptic bronchoscopy and protected brush culture in patients with community-acquired pneumonia. *Chest* 1990; 97: 576-582.
7. Dreis RB, Albert RK, Talley PA, Kryger MH, Scoggin CH, Zwillich CW. Flexible fiberoptic bronchoscopy in the teaching hospital. Yield and complications. *Chest* 1978; 74: 144-149.
8. Honeybourne D. Survey of flexible fiberoptic bronchoscopy in UK. *Eur Respir J* 2002; 20: 789.
9. Mak VH, Johnston ID, Hetzel MR, Grubb C. Value of washings and brushings at fiberoptic bronchoscopy in the diagnosis of lung cancer. *Thorax* 1990; 45: 373-6.
10. Alamoudi OS, Attar SM, Ghabrah TM, Kassimi MA. Bronchoscopy, indications, safety and complications. *Saudi Med J* 2000; 21: 1043-1047.
11. Sawy MS, Jayakrishnan B, Behbehani N, Abal AT, El-Shamy A, Nair MG. Flexible fiberoptic bronchoscopy. Diagnostic yield. *Saudi Med J* 2004; 25: 1459-1463.
12. British Thoracic Society Bronchoscopy Guidelines Committee, a Subcommittee of Standards of Care Committee of British Thoracic Society. British Thoracic Society guidelines on diagnostic flexible bronchoscopy. *Thorax* 2001; 56 Suppl 1: i1-i21.

13. Yaacob I, Harun Z, Ahmad Z. Fibreoptic bronchoscopy--a Malaysian experience. *Singapore Med J* 1991; 32: 26-28.
14. Jayasundera C. Experience with flexible fibreoptic bronchoscopy. *Ceylon Med J* 1996; 41: 131-134.
15. Liam CK, Chen YC, Yap SF, Srinivas P, Poi PJ. Detection of Mycobacterium tuberculosis in bronchoalveolar lavage from patients with sputum smear-negative pulmonary tuberculosis using a polymerase chain reaction assay. *Respirology* 1998; 3: 125-129.
16. Charoenratanakul S, Dejsomritrutai W, Chaiprasert A. Diagnostic role of fiberoptic bronchoscopy in suspected smear negative pulmonary tuberculosis. *Respir Med* 1995; 89: 621-623.
17. Wong CF, Yew WW, Chan CY, Au LY, Cheung SW, Cheng AF. Rapid diagnosis of smear-negative pulmonary tuberculosis via fiberoptic bronchoscopy: utility of polymerase chain reaction in bronchial aspirates as an adjunct to transbronchial biopsies. *Respir Med* 1998; 92: 815-819.
18. Tueller C, Chhajed PN, Buitrago-Tellez C, Frei R, Frey M, Tamm M. Value of smear and PCR in bronchoalveolar lavage fluid in culture positive pulmonary tuberculosis. *Eur Respir J* 2005; 26: 767-772.
19. Anderson C, Inhaber N, Menzies D. Comparison of sputum induction with fiber-optic bronchoscopy in the diagnosis of tuberculosis. *Am J Respir Crit Care Med* 1995; 152 (5 Pt 1): 1570-1574.
20. Al-Zahrani K, Al Jahdali H, Poirier L, René P, Menzies D. Yield of smear, culture and amplification tests from repeated sputum induction for the diagnosis of pulmonary tuberculosis. *Int J Tuberc Lung Dis* 2001; 5: 855-860.
21. Conde MB, Soares SL, Mello FC, Rezende VM, Almeida LL, Reingold AL, et al. Comparison of sputum induction with fiberoptic bronchoscopy in the diagnosis of tuberculosis: experience at an acquired immune deficiency syndrome reference center in Rio de Janeiro, Brazil. *Am J Respir Crit Care Med* 2000; 162: 2238-2240.
22. Jain P, Sandur S, Meli Y, Arroliga AC, Stoller JK, Mehta AC. Role of flexible bronchoscopy in immunocompromised patients with lung infiltrates. *Chest* 2004; 125: 712-722.
23. von Eiff M, Zühlsdorf M, Roos N, Thomas M, Büchner T, van de Loo J. Pulmonary infiltrates in patients with haematologic malignancies: clinical usefulness of non-invasive bronchoscopic procedures. *Eur J Haematol* 1995; 54: 157-162.
24. Weyers CM, Leeper KV. Nonresolving pneumonia. *Clin Chest Med* 2005; 26: 143-158.
25. Schreiber G, McCrory DC. Performance characteristics of different modalities for diagnosis of suspected lung cancer: summary of published evidence. *Chest* 2003; 123 (1 Suppl): 115S-128S.
26. Baaklini WA, Reinoso MA, Gorin AB, Sharafkaneh A, Manian P. Diagnostic yield of fiberoptic bronchoscopy in evaluating solitary pulmonary nodules. *Chest* 2000; 117: 1049-1054.
27. Chhajed PN, Bernasconi M, Gambazzi F, Bubendorf L, Rasch H, Kneifel S, et al. Combining bronchoscopy and positron emission tomography for the diagnosis of the small pulmonary nodule < or = 3 cm. *Chest* 2005; 128: 3558-3564.
28. Berbescu EA, Katzenstein AL, Snow JL, Zisman DA. Transbronchial biopsy in usual interstitial pneumonia. *Chest* 2006; 129: 1126-1131.
29. Bolliger CT, Mathur PN, Beamis JF, Becker HD, Cavaliere S, Colt H, et al. ERS/ATS statement on interventional pulmonology. European Respiratory Society/American Thoracic Society. *Eur Respir J* 2002; 19: 356-573.
30. Anders GT, Johnson JE, Bush BA, Matthews JI. Transbronchial biopsy without fluoroscopy. A seven-year perspective. *Chest* 1988; 94: 557-560.
31. Pue CA, Pacht ER. Complications of fiberoptic bronchoscopy at a university hospital. *Chest* 1995; 107: 430-432.

Dear Author, please read through your article carefully, make a critical review and highlight any changes you require to be made, please also list these clearly on a separate sheet. **Please pay particular attention to all authors' names (in English and Arabic if applicable [No changes are allowed after the signed final-galley proof]),** the running title and the footer of the first page. Check the accepted and received dates in this footer. Carefully check all legends to figures and all column headings in tables, ensuring that total numbers in tables are correct and correspond to results in the text of your article. Accuracy of all references are the sole responsibility of the author. Please also pay particular attention to the spelling of all medical and non-medical words.

This is extremely important as mistakes not corrected prior to publication can cause embarrassment, more so to the authors than the publisher. After you have signed and returned the galley proof of your article, the Journal will not be held responsible for any errors that appear in the final print. Although erratum notices may be published, this will only be carried out when the error is the fault of the publisher and not the author.

Please then sign on each and every page of your manuscript and return it to our office together with an indication of whether to you wish to order re-prints of your article (see below).

Please do not hesitate to call if you have any further queries.

Not following the instructions will result in a delay in the publication of your manuscript.

Many thanks.

OFFPRINTS REQUIRED	YES	NO
(Please tick relevant box)		
MS#	20070470	
<u>IF YES IS TICKED THEN PLEASE ENSURE</u> <u>THAT YOU COMPLETE THE ENCLOSED</u> <u>OFFPRINT FORM OTHERWISE OFFPRINTS</u> <u>CANNOT BE ORDERED</u>		

Saudi Medical Journal

Off-Prints (Original/Review/Case Report)

PLEASE COMPLETE THIS SECTION AND RETURN WITH PROOF TO
SAUDI MEDICAL JOURNAL, RIYADH MILITARY HOSPITAL
PO BOX 7897, RIYADH 11159, KINGDOM OF SAUDI ARABIA

INSTRUCTIONS FOR ORDER REPRINTS

NUMBER OF MANUSCRIPT: NO. OF PAGES:

TITLE OF MANUSCRIPT:

CORRESPONDING AUTHOR:

Address:

(of delivery) Tel. No.

.....

..... Fax No.

.....

I confirm that I wish to purchase _____ off-prints of the above manuscript (minimum is 50).

Offprint Prices

No. of pages	Number of Offprints requested	50	100	200	300	400
1-4 pages	Price in SR	250	500	1000	1500	2000
Over 4 pages	Price in SR	500	1000	2000	3000	4000
Minimum purchase is 50						

METHOD OF PAYMENT

*I enclose a payment ofSR, total amount in words

(1) Cash

(2) Cheque payable to Saudi Medical Journal