

VIDEOS IN CLINICAL MEDICINE

Central Venous Catheterization — Subclavian Vein

Dana A.V. Braner, M.D., Susanna Lai, M.P.H., Scott Eman, B.S.,
and Ken Tegtmeyer, M.D.

From the Department of Pediatrics, Oregon Health & Science University, Portland. Address reprint requests to Dr. Tegtmeyer at the Department of Pediatrics, Oregon Health & Science University, 707 SW Gaines St., MC: CDRC-P, Portland, OR 97239, or at tegtmeye@ohsu.edu.

N Engl J Med 2007;357:e26.

Copyright © 2007 Massachusetts Medical Society.

INDICATIONS

Central venous catheterization provides for the administration of caustic and critical medications as well as allowing sampling of blood and measurement of central venous pressure. Recent evidence and Institute for Healthcare Improvement bundled guidelines¹ suggest that the subclavian vein is the preferred choice for placement of a central venous catheter.

CONTRAINDICATIONS

General contraindications for placement of a central venous catheter include infection of the area overlying the target vein and thrombosis of the target vein. Specific contraindications to the subclavian approach include fracture of the ipsilateral clavicle or anterior proximal ribs, which can distort the anatomy and make placement difficult. Greater caution should be used when placing a central venous catheter in coagulopathic patients. The location of the artery (beneath the clavicle) makes application of direct pressure nearly impossible in attempts to control bleeding.

EQUIPMENT

Most of the necessary equipment can be found in commercially available kits. These kits typically include skin-preparation solution and a drape, lidocaine, sterile gauze, non-Luer lock syringes, a scalpel, a catheter, a dilator, several needles, and a guide-wire. You will also need a sterile gown, sterile gloves, a surgical cap, a mask with a face shield, and drapes to cover the patient's entire body. Flush solution is also not commonly found in the kits. Determine the catheter length and depth of placement by referring to the patient's external landmarks. The tip of the catheter should reach the junction of the superior vena cava and the right atrium. Common catheters used range from 4-French catheters for infants to 7-French catheters for adults; 11.5-French catheters may be used for dialysis. Because the risk of infection increases with an increasing number of lumens, a catheter with the fewest number of lumens required should be used.

PREPARATION

Explain the procedure to the patient and obtain written informed consent. Wear a sterile gown and gloves, a mask with face shield, and a surgical cap. Examine the patient to be sure that there are no contraindications. Place the patient in the 15-degree Trendelenburg position, which will engorge the vein. If you place a rolled towel or similar object under the spine to help identify the patient's external landmarks, be aware that propping the shoulder or turning the head has been shown to decrease the size of the vein on ultrasonography.² Scrub the area thoroughly with chlorhexidine. Drape the area, covering the patient's entire body.

Next, identify anatomic landmarks, beginning with the middle third of the clavicle. Follow this laterally to the point where the clavicle deviates from the proximal ribs (Fig. 1). Just medial to this point, the subclavian vein and artery run just inferior to the clavicle. This is where most successful catheterization occurs. The insertion site should be somewhat remote from the clavicle, so that the path of the needle ultimately stays parallel to and just under the clavicle. Typically, the point of insertion is 2 cm lateral to and 2 cm caudal to the middle third of the clavicle (Fig. 2). Local anesthesia with 1 to 2 ml of 1 percent lidocaine or equivalent should be used in this area.

ULTRASOUND GUIDANCE

Several recent articles suggest that ultrasonography can increase the likelihood of successful placement of a subclavian catheter, despite the presence of bony landmarks.^{3,4} Because of the greater difficulty in identifying the vein by compression, Doppler flow should be used to distinguish between the artery and the vein.

THE PROCEDURE

Starting 2 cm lateral to the bend of the clavicle and approximately 2 cm caudal, insert the catheterization needle through the skin at a 30-degree angle toward the sternal notch. Place a finger of your nondominant hand in the sternal notch to help find the landmark. Once the needle is under the skin, lower the needle and syringe to run parallel to but beneath (posterior to) the clavicle (Fig. 3). Access to the vein typically occurs just beneath the clavicle, but it may involve a depth of several centimeters under the skin.

Once you have obtained venous access, carefully stabilize the needle and remove the syringe. Introduce the J-tipped end of the guidewire into the needle. The wire should thread easily and without resistance until well beyond the end of the needle. If you notice ectopic cardiac beats on the monitor, pull the wire back until the ectopic beats disappear. Then remove the needle, leaving the wire in place. Maintain control of the wire. A small, 1-to-2-mm incision should be made in the skin at the insertion point to facilitate dilator passage. Advance the dilator over the wire into and through the skin and then into the vessel. Once the vessel is dilated, the dilator can be removed. Use a gauze pad to control increased bleeding, which usually occurs after dilation. Advance the line over the guidewire, maintaining control of the wire before passing the catheter into the skin. Remove the guidewire, check for blood return from all ports, flush all ports, and secure the catheter in place. Apply a sterile dressing before removing the drapes (Fig. 4).

COMPLICATIONS

Specific complications associated temporally with placement of a subclavian line include hemothorax and pneumothorax, air embolism, inadvertent arterial puncture, and aortic perforation. Obtain a chest radiograph after placement to assess for complications and for correct placement of the catheter. Common malplacement locations include placement transverse to the contralateral subclavian vein, retrograde into the ipsilateral internal jugular vein, or potentially the contralateral internal jugular vein.

Longer-term complications include thrombosis of the vein and infection. Data suggest that subclavian placement mitigates but does not eliminate the risk of infection. Adherence to the Institute for Healthcare Improvement guidelines, including the use of proper hand hygiene, the use of maximal barrier precautions during placement, the use of chlorhexidine skin antisepsis, and daily review of need for the catheter, will help to decrease the risk of infection.¹

No potential conflict of interest relevant to this article was reported.

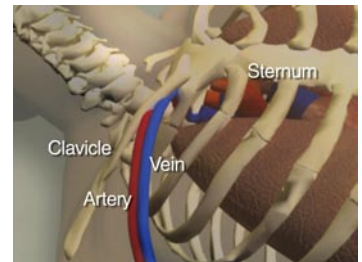


Figure 1. Anatomic Landmarks.

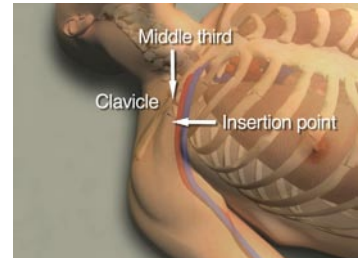


Figure 2. Point of Insertion.

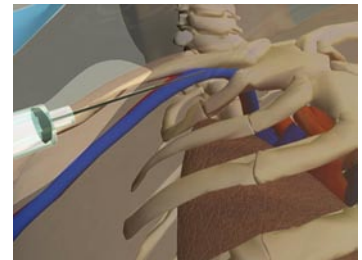


Figure 3. Placement of the Needle.

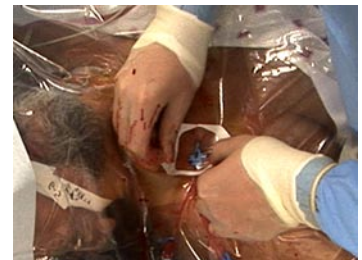

Figure 4. Application of the Dressing.

REFERENCES

1. Implement the central line bundle. Cambridge, MA: Institute for Healthcare Improvement. (Accessed November 16, 2007, at <http://www.ihc.org/ihc/topics/criticalcare/intensivecare/changes/implementthecentrallinebundle.htm>.)
2. Fortune JB, Feustel P. Effect of patient position on size and location of the subclavian vein for percutaneous puncture. *Arch Surg* 2003;138:996-1000.
3. Orihashi K, Imai K, Sato K, Hamamoto M, Okada K, Sueda T. Extrathoracic subclavian venipuncture under ultrasound guidance. *Circ J* 2005;69:1111-5.
4. Pirotte T, Veyckemans F. Ultrasound-guided subclavian vein cannulation in infants and children: a novel approach. *Br J Anaesth* 2007;98:509-14.

Copyright © 2007 Massachusetts Medical Society.