

*Medical Progress*

## IDIOPATHIC PULMONARY FIBROSIS

THOMAS J. GROSS, M.D.,  
AND GARY W. HUNNINGHAKE, M.D.

**I**DIOPATHIC pulmonary fibrosis is characterized by radiographically evident interstitial infiltrates predominantly affecting the lung bases and by progressive dyspnea and worsening of pulmonary function. No therapy has been clearly shown to prolong survival.<sup>1</sup> The current strict definition of idiopathic pulmonary fibrosis provides a new focus for basic and clinical research that will improve insight into the pathogenesis of this disorder and stimulate the development of novel therapies.

## DEFINITION

Idiopathic pulmonary fibrosis, also known as cryptogenic fibrosing alveolitis, is one of a family of idiopathic pneumonias sharing the clinical features of shortness of breath, radiographically evident diffuse pulmonary infiltrates, and varying degrees of inflammation, fibrosis, or both on biopsy (Table 1). Many older studies included several forms of idiopathic interstitial pneumonia under the term "idiopathic pulmonary fibrosis," but today the clinical label "idiopathic pulmonary fibrosis" should be reserved for patients with a specific form of fibrosing interstitial pneumonia referred to as usual interstitial pneumonia.<sup>2-4</sup> Historical grouping of disparate disorders under the heading of idiopathic pulmonary fibrosis makes it difficult to compare current and older studies. This observation also explains the discrepancies between older and newer investigations of idiopathic pulmonary fibrosis in reported natural history and response to therapy. Many forms of idiopathic interstitial pneumonia other than idiopathic pulmonary fibrosis have a more favorable prognosis and response to therapy than does idiopathic pulmonary fibrosis. The idiopathic interstitial pneumonias can be classified in pathologically distinct categories: usual interstitial pneumonia, desquamative

interstitial pneumonia—respiratory bronchiolitis interstitial lung disease, acute interstitial pneumonia, non-specific interstitial pneumonia, and cryptogenic organizing pneumonia—bronchiolitis obliterans organizing pneumonia.<sup>2,5,6</sup>

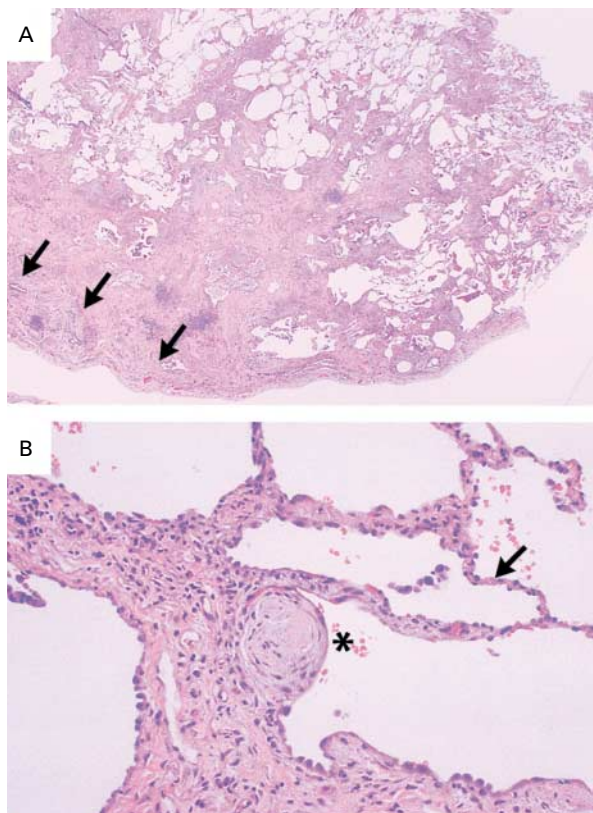
The pathologic changes that characterize idiopathic pulmonary fibrosis are distinguished by variation in the location and age of the lesions, with a predilection for the peripheral subpleural parenchyma. Fibrotic zones with associated honeycombing alternate with areas of relatively unaffected lung tissue. Fibrotic areas characteristically vary in age and activity. Regions of chronic lung injury with scarring and honeycombing contrast with regions of acute injury with foci of actively proliferating fibroblasts and myofibroblasts (Fig. 1). These focal zones of fibroblast proliferation ("fibroblast foci") occur at sites of recent alveolar injury. The exuberant cellular response at these sites is similar to healing patterns observed in skin and other tissues.<sup>7-9</sup> The interstitial inflammation of idiopathic pulmonary fibrosis is mild and generally associated with fibrosis.<sup>2</sup> Thus, idiopathic pulmonary fibrosis is characterized by sequential acute lung injury that results in a progressive accumulation of fixed fibrosis with architectural distortion.

A full pathological description of the other idiopathic interstitial pneumonias is outside the province of this article. However, it is important to acknowledge histologic features that distinguish these disorders from idiopathic pulmonary fibrosis.<sup>2</sup> Desquamative interstitial pneumonitis—respiratory bronchiolitis interstitial lung disease is characterized by a relatively uniform thickening or thickening centered on the bronchioles of the alveolar septa, accompanied by a striking accumulation of pigment-laden intraalveolar macrophages. Fibroblast foci are rarely found, and honeycombing is a minor component. Alveolar macrophage accumulation and pneumocyte hyperplasia lend a cellular appearance to the biopsy specimens.<sup>10</sup> Acute interstitial pneumonia involves a diffuse fibroproliferative response to synchronous alveolar injuries. The histologic findings reflect recent diffuse lung injury. There are proliferating type 2 pneumocytes; widened interstitial spaces formed by the collapse of alveolar septa denuded of epithelial cells; incorporation of alveolar exudates, including remnant hyaline membranes; and diffuse proliferation of fibroblasts and myofibroblasts.<sup>11</sup> Nonspecific interstitial pneumonia is manifested as varying degrees of inflammation and fibrosis that are uniformly distributed within the interstitium of the lung.<sup>12</sup> Areas of acute lung injury are not typical of nonspecific interstitial pneumonia. Inflammation tends to be a more prominent feature than in usual interstitial pneu-

From the Division of Pulmonary, Critical Care, and Occupational Medicine, Department of Internal Medicine, University of Iowa College of Medicine and Veterans Affairs Medical Center, Iowa City. Address reprint requests to Dr. Hunninghake at the Division of Pulmonary, Critical Care, and Occupational Medicine, Department of Internal Medicine, Room C33-GH, University of Iowa Health Care, Iowa City, IA 52242, or at gary-hunninghake@uiowa.edu.

**TABLE 1.** IDIOPATHIC INTERSTITIAL PNEUMONIAS.

CLINICAL TERMINOLOGY	PATHOLOGICAL FINDINGS
Idiopathic pulmonary fibrosis	Usual interstitial pneumonia
Desquamative interstitial pneumonia–respiratory bronchiolitis interstitial lung disease	Desquamative interstitial pneumonia, respiratory bronchiolitis interstitial lung disease
Acute interstitial pneumonia	Diffuse alveolar damage
Nonspecific interstitial pneumonia	Nonspecific interstitial pneumonia
Cryptogenic organizing pneumonia–bronchiolitis obliterans organizing pneumonia	Organizing pneumonia, peribronchiolar inflammation



**Figure 1.** Histopathological Features of Idiopathic Pulmonary Fibrosis.

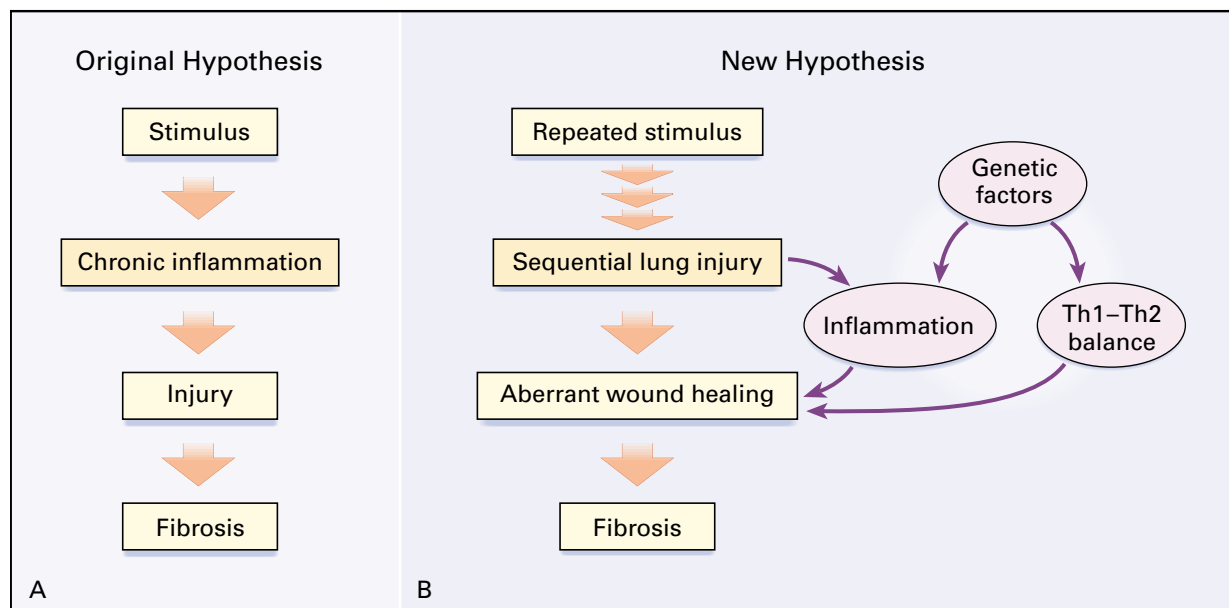
The figure shows a hematoxylin-and-eosin preparation of an open-lung biopsy specimen from a patient presenting with progressive dyspnea and diffuse parenchymal infiltrates. In Panel A, a low-power magnification ( $\times 15$ ), dense subpleural fibrosis (arrows), with collapse and obliteration of alveolar air spaces, is readily apparent. Pathological heterogeneity, exemplified by dense scarring adjacent to relatively spared alveoli, is characteristic of usual interstitial pneumonia. There is no necrosis or substantial inflammation. In Panel B, a high-power magnification ( $\times 150$ ), a fibroblast focus (asterisk) is visible as a nodule of spindle cells arranged in linear fashion against a pale-staining extracellular matrix. The adjacent alveolar septa show little histologic abnormality (arrow). (Histologic sections kindly provided by Dr. Thomas Colby.)

monia, with dense mononuclear-cell infiltrates within alveolar septa. In cryptogenic organizing pneumonia–bronchiolitis obliterans organizing pneumonia, inflammation is centered on the peribronchial interstitium and alveolar ducts. Characteristic plugs of granulation tissue occlude the distal air spaces.<sup>13</sup> Thus, the hallmark of usual interstitial pneumonia is a geographically and temporally heterogeneous parenchymal fibrosis against a background of mild inflammation.

#### PATHOGENESIS

Recognition of idiopathic pulmonary fibrosis as a distinct entity with lesions that vary in age and location raised important questions about the established view that idiopathic pulmonary fibrosis was a disease in which parenchymal fibrosis was directly caused by chronic inflammation.<sup>1,2</sup> This prior hypothesis suggested that an unidentified insult initiated a cycle of chronic inflammatory injury leading to fibrosis (Fig. 2A). An important assumption was that if the inflammatory cascade was interrupted before irreversible tissue injury occurred, fibrosis might be avoided. Thus, this theory explains the initial enthusiasm for corticosteroid and cytotoxic therapy for idiopathic pulmonary fibrosis. However, it is now clear that current antiinflammatory therapy for idiopathic pulmonary fibrosis provides no benefit. Therefore, a new hypothesis seems in order.

The hallmark lesions of idiopathic pulmonary fibrosis are the fibroblast foci.<sup>2</sup> These sites feature vigorous replication of mesenchymal cells and exuberant deposition of fresh extracellular matrix. Such foci are typical of alveolar epithelial-cell injury, with endoluminal plasma exudation and collapse of the distal air space.<sup>8,9,14</sup> Mediators normally associated with wound healing, such as transforming growth factor  $\beta_1$  and connective-tissue growth factor, are also expressed at these sites.<sup>15,16</sup> The driving force for this focal acute lung injury and wound repair is unknown and probably will not be identified until a cause of idiopathic pulmonary fibrosis is elucidated. Thus, a more current hypothesis for the causation of idiopathic pulmonary



**Figure 2.** Original and New Hypotheses for the Pathogenesis of Idiopathic Pulmonary Fibrosis.

Originally (Panel A), idiopathic pulmonary fibrosis was viewed as a smoldering inflammatory response that ultimately led to chronic lung injury with subsequent fibrosis. Therapies that focused solely on trying to interrupt chronic inflammation have provided no benefit for patients. Newer insights (Panel B) suggest that idiopathic pulmonary fibrosis results from sequential acute lung injury. The resultant wound-healing response to this injury culminates in pulmonary fibrosis. Several interacting factors that modify the fibrotic response include the genetic background of the patient, the predominant inflammatory phenotype (Th1 or Th2), and environmental inflammatory triggers, such as cigarette smoking, viral infection, and respirable toxins.

fibrosis suggests that a still-unidentified stimulus produces repeated episodes of acute lung injury (Fig. 2B). Wound healing at these sites of injury ultimately leads to fibrosis, with loss of lung function. Therefore, one effective therapeutic strategy might be to modify fibroblast replication and matrix deposition.

There are several factors that are thought to modify wound healing and, ultimately, the degree of parenchymal fibrosis (Fig. 2B). First, the type of inflammatory response may modulate tissue injury, fibrosis, or both during the evolution of idiopathic pulmonary fibrosis. The inflammatory response in idiopathic pulmonary fibrosis is thought to resemble closely a Th2-type immune response. There are eosinophils, mast cells, and increased amounts of the Th2 cytokines interleukin-4 and interleukin-13.<sup>17-21</sup> In murine models of lung disease, animals whose response to tissue injury is predominantly of the Th2 type are more prone to pulmonary fibrosis after lung injury than those with a predominantly Th1 response.<sup>19</sup> Although the Th2 and Th1 phenotypes are not as well defined in idiopathic pulmonary fibrosis as they are in asthma and animal models, their potential importance is one rationale for undertaking trials of immunomodulators such as interferon gamma in an attempt to switch the inflammatory response to a more Th1-like phenotype.<sup>22</sup>

Up to 3 percent of cases of idiopathic pulmonary fibrosis appear to cluster in families, suggesting a genetic susceptibility in some patients.<sup>23-26</sup> Although polymorphisms have been observed in interleukin-1-receptor antagonist, tumor necrosis factor  $\alpha$ , and major-histocompatibility-complex loci, there is as yet no clear evidence of a genetic basis for idiopathic pulmonary fibrosis.<sup>27,28</sup>

It has been suggested that superimposed environmental insults may be important in the pathogenesis of idiopathic pulmonary fibrosis. In most reported case series, up to 75 percent of index patients with idiopathic pulmonary fibrosis are current or former smokers. In large epidemiologic studies, cigarette smoking has been strongly associated with idiopathic pulmonary fibrosis. In addition, many of the inflammatory features of idiopathic pulmonary fibrosis are more strongly linked to smoking status than to the underlying lung disease. Thus, cigarette smoking may be an independent risk factor for idiopathic pulmonary fibrosis.<sup>29-32</sup> Latent viral infections, especially those of the herpesvirus family, have also been reported to be associated with idiopathic pulmonary fibrosis. To date, however, no candidate virus has been convincingly shown to cause idiopathic pulmonary fibrosis.<sup>33,34</sup> Finally, given the similarity between asbestosis and id-

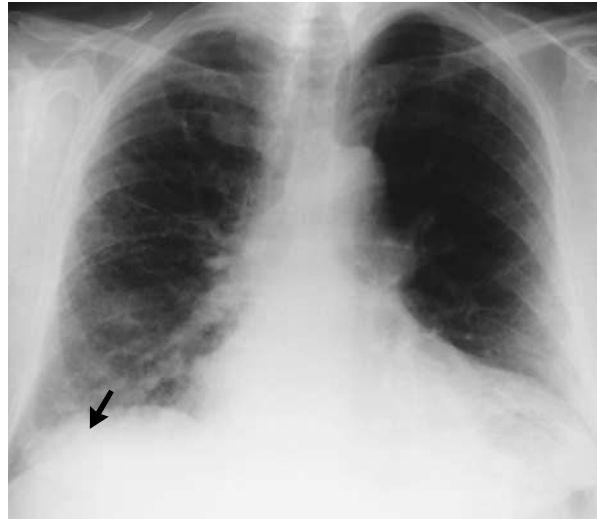idiopathic pulmonary fibrosis, many authors have sought a causative respirable environmental agent. Despite some weak associations with exposure to metal and organic dusts, no workplace or environmental factor has been clearly linked to the development of idiopathic pulmonary fibrosis.<sup>35,36</sup>

### DIAGNOSIS

Patients with idiopathic pulmonary fibrosis typically present with exertional dyspnea and a nonproductive cough.<sup>37-39</sup> The disorder generally presents in the fifth and sixth decades and is slightly more common in men than women. Patients are often evaluated and treated for other ailments (bronchitis, asthma, or heart failure) before diagnosis. Associated systemic symptoms, such as low-grade fever and myalgia, may be present but are not common. A detailed occupational history, with attention to exposure to asbestos, silica, or other respirable toxins, is critical to rule out a pneumoconiosis that may mimic idiopathic pulmonary fibrosis. The physical examination in most patients reveals fine bibasilar inspiratory crackles (“Velcro rales”). Clubbing is seen in up to 50 percent of patients.<sup>38</sup> The rest of the physical examination is unremarkable until late in the course of the disease, when severe pulmonary hypertension and cor pulmonale may become apparent. Frank findings of collagen vascular disease (such as rashes, inflammatory arthritis, and myositis) suggest an alternative diagnosis.

Laboratory abnormalities are mild and nonspecific. Mild anemia, increases in markers of systemic inflammation (erythrocyte sedimentation rate or C-reactive protein level), and nonspecific increases in rheumatoid factor and antinuclear antibodies are observed in up to 30 percent of patients.<sup>37-39</sup> In the absence of other findings of a systemic illness, the presence of autoantibodies does not imply an underlying collagen vascular disorder. Pulmonary-function tests typically reveal a parenchymal restrictive ventilatory defect, with reduction in total lung capacity, functional residual capacity, and residual volume due to decreased lung compliance.<sup>40</sup> However, patients who smoke may also have a concurrent obstructive ventilatory defect.<sup>30</sup> Impairments in gas exchange may be demonstrated by a decrease in the carbon monoxide diffusing capacity or by hypoxemia with graded exercise testing.<sup>41</sup>

The typical chest radiograph in idiopathic pulmonary fibrosis reveals bilateral reticular opacities that are most prominent in the periphery of the lungs and in the lower lobes (Fig. 3).<sup>39,42</sup> Progressive fibrosis leads to cystic dilatation of the distal air spaces, which is visible as peripheral “honeycombing.” Decreased parenchymal compliance may lead to traction bronchiectasis, which is visible as thickened and dilated airways. Although virtually all patients will have an abnormal chest radiograph on presentation, unusual cases of biopsy-proved idiopathic pulmonary fibrosis have been reported with normal radiographic studies.<sup>4</sup>



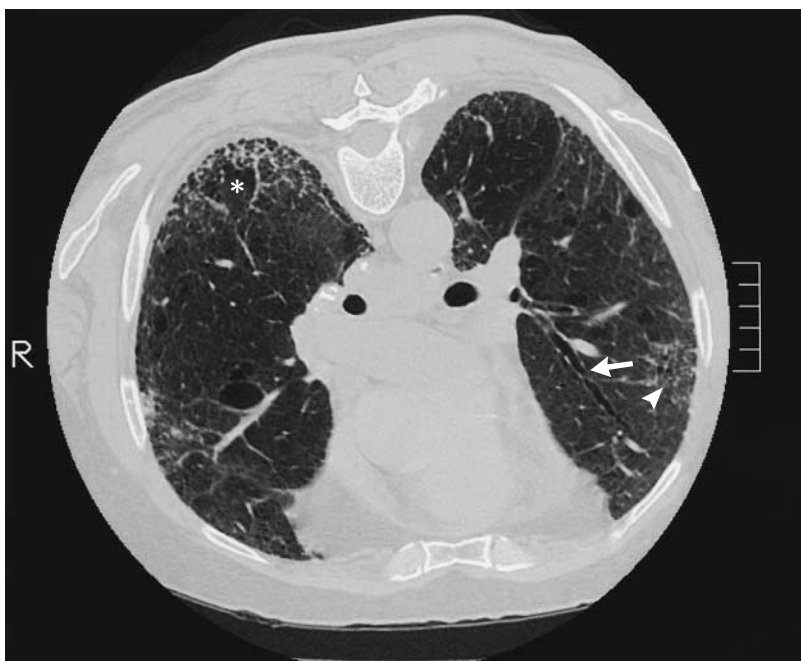**Figure 3.** Chest Radiograph of a Patient with Idiopathic Pulmonary Fibrosis.

A chest radiograph reveals bilateral reticular infiltrates. There is subpleural (arrow) and lower-lobe predominance. Open-lung biopsy confirmed pathological changes typical of usual interstitial pneumonia.

The presence of pleural effusions, air bronchograms, confluent shadows, or hilar adenopathy strongly suggests an alternative diagnosis or superimposed complicating illness.

Computed tomography (CT) has greatly enhanced the evaluation of interstitial lung diseases. Thin-section or high-resolution CT increases spatial resolution, facilitating visualization of parenchymal detail to the level of the pulmonary lobule. This improved imaging allows experienced readers to characterize anatomical patterns in interstitial lung diseases. The typical CT features of idiopathic pulmonary fibrosis include patchy peripheral reticular abnormalities with intralobular linear opacities, irregular septal thickening, subpleural honeycombing, and traction bronchiectasis (Fig. 4). These findings are always most prominent in the lower lung zones, but they may involve all lobes in advanced disease. The extent of disease on high-resolution CT correlates with fibrosis on biopsy and with physiological impairment.<sup>43</sup>

A study examined the ability of physicians expert in the diagnosis of interstitial lung diseases to identify correctly high-resolution CT scans from patients with biopsy-proved idiopathic pulmonary fibrosis.<sup>44</sup> When the expert group made a confident diagnosis of idiopathic pulmonary fibrosis from the CT scan and basic clinical data, they were correct in over 80 percent of the cases. However, over half the patients with proved idiopathic pulmonary fibrosis had an uncertain diag-



**Figure 4.** Chest CT Scan in a Patient with Idiopathic Pulmonary Fibrosis.

A representative high-resolution chest CT image from the patient whose radiograph is depicted in Figure 3 is shown. High-resolution CT images of the lung parenchyma are best obtained with the patient lying prone to reduce gravitational effects on lower-lobe lung density. There is prominent irregular septal thickening (arrowhead), subpleural honeycombing (asterisk), and a dilated airway, representing traction bronchiectasis (arrow). Open-lung biopsy confirmed pathological changes typical of usual interstitial pneumonia.

nosis on the basis of high-resolution CT and clinical evaluation. Thus, experienced clinicians can make a confident diagnosis of idiopathic pulmonary fibrosis in many patients without the need for biopsy.<sup>44,45</sup> When the diagnostic studies do not support a confident diagnosis of idiopathic pulmonary fibrosis or the clinician is less experienced, a lung biopsy is needed for diagnosis.

Lung biopsy remains the standard for identifying specific idiopathic interstitial pneumonias. Because the diagnosis relies on grading lesions that vary in both age and location, a large piece of lung parenchyma is required. Therefore, transbronchial biopsies are used only to rule out other disorders that mimic idiopathic pulmonary fibrosis. These smaller biopsies are not adequate to establish a pathological diagnosis of idiopathic pulmonary fibrosis. Surgical lung biopsy can be performed either by thoracotomy or by less invasive video-assisted or thoracoscopic techniques. Preoperative high-resolution CT scans direct the surgeon to specific abnormal regions of the lung.<sup>46</sup> Optimal evaluation requires biopsies from several sites. This procedure can be safely performed even in patients undergoing ventilation, but it may be associated with substantial complications, including prolonged bronchopleural fistulas and post-thoracotomy pain.<sup>47,48</sup>

Other techniques, such as gallium lung scanning and bronchoalveolar lavage, have been used to study patients with idiopathic pulmonary fibrosis.<sup>49,50</sup> Although these are important in excluding alternative causes and yield valuable material for basic investigations into the mechanisms of pulmonary inflammation, there is little evidence that they provide practical information to support a diagnosis of idiopathic pulmonary fibrosis, to monitor disease activity, or to predict the response to therapy.

#### NATURAL HISTORY

Idiopathic pulmonary fibrosis is a progressive illness. Increasing parenchymal fibrosis leads to decreased lung compliance, with a progressive increase in the work of breathing.<sup>41,51</sup> Although approximately 40 percent of patients eventually die of respiratory failure, disease progression can be difficult to predict. In many patients with idiopathic pulmonary fibrosis, death is triggered by a complicating illness, mainly coronary artery disease and infections.<sup>52</sup> Traction bronchiectasis, poor clearance of mucus, and perhaps an increased incidence of gastroesophageal reflux predispose patients with idiopathic pulmonary fibrosis to lower respiratory tract infections.<sup>53</sup> The risk of such infections may be magnified by the concurrent use of corticosteroids or

other immunomodulatory therapy. End-stage disease is characterized by severe pulmonary hypertension with cor pulmonale that often does not improve with oxygen therapy. Left ventricular dysfunction is found in less than 10 percent of patients with severe idiopathic pulmonary fibrosis, and when present, it is often due to coexisting right-sided heart failure with ventricular interdependence (in 66 percent of patients).<sup>54</sup> Thus, traditional therapies aimed at diuresis and afterload reduction are unlikely to benefit these patients and may further compromise a preload-dependent right ventricle. The incidence of bronchogenic carcinoma is increased in patients with idiopathic pulmonary fibrosis. Whether this results from the effects of scarring and chronic inflammation or from an interaction between cigarette smoking and occupational exposure remains controversial.<sup>55</sup>

Even in the absence of a complicating disease, the median survival after the diagnosis of biopsy-confirmed idiopathic pulmonary fibrosis is less than three years.<sup>56</sup> Previous studies suggesting longer survival were complicated by the inclusion of types of idiopathic interstitial pneumonias other than usual interstitial pneumonia, which have a better prognosis. Factors associated with shortened survival include older age, poor pulmonary function at presentation, recent deterioration in the results of pulmonary-function tests, and advanced fibrosis.<sup>57-60</sup> Thus, true idiopathic pulmonary fibrosis is a grave diagnosis that should prompt early evaluation for lung transplantation, if appropriate, and timely end-of-life discussions with all patients.

### THERAPY

At present, there are no proven therapies for idiopathic pulmonary fibrosis. Given the newer insights into the pathogenesis of idiopathic pulmonary fibrosis, novel approaches must be aimed at minimizing the sequelae of repeated acute lung injury.

#### Antiinflammatory Agents

Based on early observations demonstrating inflammatory cells in the distal air space, numerous studies have investigated the use of corticosteroids and cytotoxic agents in the management of idiopathic pulmonary fibrosis. Early reports found response rates of 10 to 40 percent.<sup>38,61-63</sup> Correlative studies have suggested that corticosteroids reduce so-called ground-glass opacities seen on high-resolution CT in some patients with idiopathic interstitial pneumonias, and that this reduction parallels improvement in pulmonary function.<sup>64</sup> A similar study found that although ground-glass attenuation on high-resolution CT decreased in response to corticosteroids, the progression to irreversible honeycomb fibrosis was not altered.<sup>65</sup> However, in all of these studies, it is clear that idiopathic interstitial pneumonias other than idiopathic pulmonary fibrosis, such as nonspecific interstitial pneumonia, were not excluded.

When antiinflammatory agents were given only to patients with a secure diagnosis of idiopathic pulmonary fibrosis, there was no evidence of a meaningful response.<sup>3,66-68</sup> Furthermore, high-dose prednisone therapy is associated with serious side effects, including hyperglycemia requiring insulin, myopathy, exacerbation of hypertension, and accelerated osteoporosis. Cytotoxic agents also have limiting side effects, including myelosuppression, secondary cancers, and drug-induced interstitial pneumonia, which further complicate clinical decision making. Although antiinflammatory drugs are often used to treat idiopathic pulmonary fibrosis, current evidence does not support their routine use.<sup>4</sup> A trial of antiinflammatory therapy may be rational if an idiopathic interstitial pneumonia other than idiopathic pulmonary fibrosis is suspected. In this instance, a trial of prednisone should be limited to three to six months, with rigorous assessment for objective improvement in physiological measures, radiographic findings, and clinical symptoms. Longer trials of prednisone or the prolonged use of cytotoxic agents remains controversial. In the absence of objective improvement, therapy with these agents, in most instances, should be discontinued.

#### Antifibrotic Agents

Therapies designed to inhibit fibrogenesis have also been used in patients with idiopathic pulmonary fibrosis. Useful agents might interfere with matrix synthesis, fibroblast proliferation, or profibrotic cell-cell signaling.

*In vitro*, colchicine interferes with intracellular collagen processing, increases the expression of collagen-degrading enzymes, and suppresses release of fibroblast growth factors by macrophages. Because of the extensive clinical experience with colchicine in the treatment of gout and its established safety profile, colchicine has been tried in patients with idiopathic pulmonary fibrosis. Initial studies seemed promising, with trends toward improved outcomes.<sup>69</sup> However, follow-up studies that incorporated strict diagnostic criteria for idiopathic pulmonary fibrosis have failed to show any benefit of colchicine over no therapy at all.<sup>70,71</sup> Similarly, no beneficial effect was seen for the collagen cross-link inhibitor penicillamine.<sup>71</sup>

Pirfenidone is a pyridone molecule reported to block *in vitro* growth factor-stimulated collagen synthesis, extracellular matrix secretion, and fibroblast proliferation.<sup>72,73</sup> In addition, in a mouse model of lung injury, pirfenidone ameliorated cyclophosphamide-induced pulmonary fibrosis.<sup>74</sup> In a small trial, daily pirfenidone was reasonably well tolerated by very ill patients with end-stage idiopathic pulmonary fibrosis.<sup>75</sup> The results of pulmonary-function tests appeared to become stable. Clearly, a larger study is needed to confirm these observations. However, a larger, controlled study of pirfenidone in idiopathic pulmonary fibrosis may not be feasible, because the

agent is not available for clinical use in the United States at this time.

Other agents with the capacity to block fibrogenesis may be useful in idiopathic pulmonary fibrosis. Relaxin is a peptide that circulates during the later phases of gestation and contributes to remodeling of the pubic ligaments.<sup>76</sup> It has also been shown to decrease collagen production by cultured fibroblasts and alter the proteinase-antiproteinase balance to favor matrix breakdown.<sup>77</sup> Relaxin inhibited fibrosis in a murine model of drug-induced injury.<sup>77</sup> In one human trial, administration of relaxin over 24 weeks resulted in improved skin texture and pulmonary-function test results in patients with progressive systemic sclerosis.<sup>78</sup> Suramin is a synthetic compound that has been used for a number of years to treat nematode infestations. In the laboratory, it has been found to inhibit the effect of numerous profibrotic growth factors.<sup>79</sup> In rabbits, it delays wound healing and prevents hypertrophic scarring after eye surgery.<sup>80</sup> These features make it an intriguing potential agent for future trials in patients with idiopathic pulmonary fibrosis.

Endothelin-1 is a mitogenic and vasoactive peptide synthesized and secreted by vascular endothelium and airway epithelium.<sup>81</sup> This mediator has been found in association with fibroblast foci in lung biopsies and can be recovered from the distal air space by bronchoalveolar lavage.<sup>82</sup> In animal models, inhibition of endothelin-1 prevents pulmonary scarring after lung injury.<sup>83</sup> Angiotensin II is another vasoactive peptide with fibroblast mitogenic effects.<sup>84,85</sup> Angiotensin II-mediated fibroblast proliferation appears to be linked to autocrine production of transforming growth factor  $\beta_1$ .<sup>84</sup> Given the availability of effective inhibitors of angiotensin II receptors, these agents will probably be evaluated for the treatment of idiopathic pulmonary fibrosis.

#### Immune Modulators

Both in vitro studies and investigations in animals suggest that modification of the inflammatory response to wound healing may ultimately affect the degree of fibrosis after lung injury.<sup>19</sup> Interferon gamma, a Th1 cytokine, down-regulates the expression of transforming growth factor  $\beta_1$ , a mediator strongly implicated in fibroblast proliferation and collagen deposition.<sup>86</sup> Furthermore, interferon gamma may suppress established Th2-type inflammatory responses. One trial examined the use of interferon gamma-1b in idiopathic pulmonary fibrosis.<sup>22</sup> In a group of 18 patients, half received subcutaneous injections of interferon gamma-1b three times weekly and low-dose prednisone for 12 months; the other half received prednisone alone. After one year of follow-up, all study participants were alive, and small improvements in lung volumes, gas exchange, and symptoms were seen only in the interferon-treated group. These improvements were accompanied by a reduction in the expres-

sion of genes for transforming growth factor  $\beta_1$  and connective-tissue growth factor in lung tissue.<sup>22</sup>

Although patients had influenza-like symptoms during the early phases, all were able to complete the experimental protocol. However, given the small number of patients, the small amount of physiological improvement, and the unusually good survival in the untreated group, a larger confirmatory trial is necessary to ascertain how applicable these results are to patients with idiopathic pulmonary fibrosis in general.

Other promising targets of the Th2 inflammatory response include the cytokines interleukin-4 and interleukin-13 and the pluripotent growth factor transforming growth factor  $\beta_1$ . In animal models of lung injury, inhibition of these profibrotic mediators has been demonstrated to decrease fibrosis.<sup>19,87,88</sup>

#### Lung Transplantation

Lung transplantation has emerged as a viable option for some patients with idiopathic pulmonary fibrosis.<sup>89-91</sup> Many patients show improvement with single-lung transplantation, a result that facilitates better utilization of this scarce resource. Patients under the age of 55 years without complicating medical illnesses are best served by early referral to regional transplantation centers, since the waiting period for transplantation is generally around two years. Unfortunately, most patients are not eligible, because of older age or complicating medical conditions.

#### SUMMARY

Idiopathic pulmonary fibrosis is a rapidly progressive illness of unknown cause characterized by sequential acute lung injury with subsequent scarring and end-stage lung disease. Treatment at present remains largely supportive, with evidence that patients' satisfaction and survival may be improved by referral to centers specializing in the evaluation of interstitial lung diseases.<sup>92</sup> Although no drug therapy has clearly been demonstrated to benefit patients with idiopathic pulmonary fibrosis, a number of novel investigational agents hold promise for future study. Given the poor prognosis associated with idiopathic pulmonary fibrosis, patients should be referred to regional centers of expertise for enrollment in therapeutic clinical trials or for lung transplantation.

Supported in part by the Specialized Centers of Research program on interstitial lung disease of the National Heart, Lung, and Blood Institute.

#### REFERENCES

1. Mason RJ, Schwartz MI, Hunninghake GW, Musson RA. Pharmacological therapy for idiopathic pulmonary fibrosis: past, present, and future. *Am J Respir Crit Care Med* 1999;160:1771-7.
2. Katzenstein A-L, Myers JL. Idiopathic pulmonary fibrosis: clinical relevance of pathologic classification. *Am J Respir Crit Care Med* 1998;157:1301-15.
3. Ryu JH, Colby TV, Hartman TE. Idiopathic pulmonary fibrosis: current concepts. *Mayo Clin Proc* 1998;73:1085-101.
4. Idiopathic pulmonary fibrosis: diagnosis and treatment: international consensus statement. *Am J Respir Crit Care Med* 2000;161:646-64.

5. Müller NL, Colby TV. Idiopathic interstitial pneumonias: high resolution CT and histologic findings. *Radiographics* 1997;17:1016-22.
6. Nagai S, Kitaichi M, Izumi T. Classification and recent advances in idiopathic interstitial pneumonia. *Curr Opin Pulm Med* 1998;4:256-60.
7. Myers JL, Katzenstein A-L. Epithelial necrosis and alveolar collapse in the pathogenesis of usual interstitial pneumonitis. *Chest* 1988;94:1309-11.
8. Kuhn C III, Boldt J, King TE Jr, Crouch E, Vartio T, McDonald JA. An immunohistochemical study of architectural remodeling and connective tissue synthesis in pulmonary fibrosis. *Am Rev Respir Dis* 1989;140:1693-703.
9. Fukuda Y, Basset F, Ferrans VJ, Yamanaka N. Significance of early intra-alveolar fibrotic lesions and integrin expression in lung biopsy specimens from patients with idiopathic pulmonary fibrosis. *Hum Pathol* 1995;26:53-61.
10. Yousem SA, Colby TV, Gaensler EA. Respiratory bronchiolitis-associated interstitial lung disease and its relationship to desquamative interstitial pneumonia. *Mayo Clin Proc* 1989;64:1373-80.
11. Katzenstein A-L, Myers JL, Mazur MT. Acute interstitial pneumonia: a clinicopathologic, ultrastructural, and cell kinetic study. *Am J Surg Pathol* 1986;10:256-67.
12. Katzenstein A-L, Fiorelli RF. Nonspecific interstitial pneumonia/fibrosis: histologic features and clinical significance. *Am J Surg Pathol* 1994;18:136-47.
13. Epler GR. Heterogeneity of bronchiolitis obliterans organizing pneumonia. *Curr Opin Pulm Med* 1998;4:93-7.
14. Kasper M, Haroske G. Alterations in the alveolar epithelium after injury leading to pulmonary fibrosis. *Histol Histopathol* 1996;11:463-83.
15. Brockelmann TJ, Limper AH, Colby TV, McDonald JA. Transforming growth factor beta 1 is present at sites of extracellular matrix gene expression in human pulmonary fibrosis. *Proc Natl Acad Sci U S A* 1991;88:6642-6.
16. Allen JT, Knight RA, Bloor CA, Spiteri MA. Enhanced insulin-like growth factor binding protein-related protein 2 (connective tissue growth factor) expression in patients with idiopathic pulmonary fibrosis and pulmonary sarcoidosis. *Am J Respir Cell Mol Biol* 1999;21:693-700.
17. Furuie H, Yamasaki H, Suga M, Ando M. Altered accessory cell function of alveolar macrophages: a possible mechanism for induction of Th2 secretory profile in idiopathic pulmonary fibrosis. *Eur Respir J* 1997;10:787-94.
18. Hancock A, Armstrong L, Gama R, Millar A. Production of interleukin 13 by alveolar macrophages from normal and fibrotic lung. *Am J Respir Cell Mol Biol* 1998;18:60-5.
19. Kunkel SL, Lukacs NV, Strieter RM, Chensue SW. Th1 and Th2 responses regulate experimental lung granuloma development. *Sarcoidosis Vasc Diffuse Lung Dis* 1996;13:120-8.
20. Martinez JA, King TE Jr, Brown K, et al. Increased expression of the interleukin-10 gene by alveolar macrophages in interstitial lung disease. *Am J Physiol* 1997;273:L676-L683.
21. Romagnani S. Th1/Th2 cells. *Inflamm Bowel Dis* 1999;5:285-94.
22. Ziesche R, Hofbauer E, Wittman K, Petkov V, Block L-H. A preliminary study of long-term treatment with interferon gamma-1b and low-dose prednisolone in patients with idiopathic pulmonary fibrosis. *N Engl J Med* 1999;341:1264-9. [Erratum, *N Engl J Med* 2000;342:524.]
23. Baecher-Allan CM, Barth RK. PCR analysis of cytokine induction profiles associated with mouse strain variation in susceptibility to pulmonary fibrosis. *Reg Immunol* 1993;5:207-17.
24. Mageto YN, Raghu G. Genetic predisposition of idiopathic pulmonary fibrosis. *Curr Opin Pulm Med* 1997;3:336-40.
25. Marshall RP, McAnulty RJ, Laurent GJ. The pathogenesis of pulmonary fibrosis: is there a fibrosis gene? *Int J Biochem Cell Biol* 1997;29:107-20.
26. Marshall RP, Puddicombe A, Cookson WO, Laurent GJ. Adult familial cryptogenic fibrosing alveolitis in the United Kingdom. *Thorax* 2000;55:143-6.
27. Briggs DC, Vaughan RW, Welsh KI, Myers A, duBois RM, Black CM. Immunogenetic prediction of pulmonary fibrosis in systemic sclerosis. *Lancet* 1991;338:661-2.
28. Whyte M, Hubbard R, Meliconi R, et al. Increased risk of fibrosing alveolitis associated with interleukin-1 receptor antagonist and tumor necrosis factor-alpha gene polymorphisms. *Am J Respir Crit Care Med* 2000;162:755-8.
29. Hanley ME, King TE Jr, Schwarz MI, Watters LC, Shen AS, Cherniak RM. The impact of smoking on mechanical properties of the lungs in idiopathic pulmonary fibrosis and sarcoidosis. *Am Rev Respir Dis* 1991;144:1102-6.
30. Schwartz DA, Merchant RK, Helmers RA, Gilbert SR, Dayton CS, Hunninghake GW. The influence of cigarette smoking on lung function in patients with idiopathic pulmonary fibrosis. *Am Rev Respir Dis* 1991;144:504-6.
31. Schwartz DA, Helmers RA, Dayton CS, Merchant RK, Hunninghake GW. Determinants of bronchoalveolar lavage cellularity in idiopathic pulmonary fibrosis. *J Appl Physiol* 1991;71:1688-93.
32. Wells AU, King AD, Rubens MB, Cramer D, du Bois RM, Hansell DM. Lone cryptogenic fibrosing alveolitis: a functional-morphologic correlation based on extent of disease on thin-section computed tomography. *Am J Respir Crit Care Med* 1997;155:1367-75. [Erratum, *Am J Respir Crit Care Med* 1997;156:676-7.]
33. Turner-Warwick M. In search of a cause of cryptogenic fibrosing alveolitis (CFA): one initiating factor or many? *Thorax* 1998;53:Suppl 2:S3-S9.
34. Ferri C, La Civita L, Fazzi P, et al. Interstitial lung fibrosis and rheumatic disorders in patients with hepatitis C virus infection. *Br J Rheumatol* 1997;36:360-5.
35. Baumgartner KB, Samet JM, Coultas DB, et al. Occupational and environmental risk factors for idiopathic pulmonary fibrosis: a multicenter case-control study. *Am J Epidemiol* 2000;152:307-15.
36. Mullen J, Hodgson MJ, DeGraff CA, Godar T. Case-control study of idiopathic pulmonary fibrosis and environmental exposures. *J Occup Environ Med* 1998;40:363-7.
37. Michaelson JE, Aguayo SM, Roman J. Idiopathic pulmonary fibrosis: a practical approach for diagnosis and management. *Chest* 2000;118:788-94.
38. Turner-Warwick MB, Burrows B, Johnson A. Cryptogenic fibrosing alveolitis: clinical features and their influence on survival. *Thorax* 1980;35:171-80.
39. Crystal RG, Fulmer JD, Roberts WC, Moss ML, Line BR, Reynolds HY. Idiopathic pulmonary fibrosis: clinical, histologic, radiographic, physiologic, scintigraphic, cytologic, and biochemical aspects. *Ann Intern Med* 1976;85:769-88.
40. Nava S, Rubini F. Lung and chest wall mechanics in ventilated patients with end stage idiopathic pulmonary fibrosis. *Thorax* 1999;54:390-5.
41. Marciniuk DD, Gallagher CG. Clinical exercise testing in interstitial lung disease. *Clin Chest Med* 1994;15:287-303.
42. Mathieson JR, Mayo JR, Staples CA, Müller NL. Chronic diffuse infiltrative lung disease: comparison of diagnostic accuracy of CT and chest radiography. *Radiology* 1989;171:111-6.
43. Xaubet A, Agusti C, Luburich P, et al. Pulmonary function tests and CT scan in the management of idiopathic pulmonary fibrosis. *Am J Respir Crit Care Med* 1998;158:431-6.
44. Hunninghake G, Schwartz D, King T, et al. Open lung biopsy in IPF. *Am J Respir Crit Care Med* 1998;157:Suppl:A277. abstract.
45. Raghu G, Mageto YN, Lockhart D, Schmidt RA, Wood DE, Godwin JD. The accuracy of the clinical diagnosis of new-onset idiopathic pulmonary fibrosis and other interstitial lung disease: a prospective study. *Chest* 1999;116:1168-74.
46. Kazerooni EA, Martinez FJ, Flint A, et al. Thin-section CT obtained at 10-mm increments versus limited three-level thin-section CT for idiopathic pulmonary fibrosis: correlation with pathologic scoring. *AJR Am J Roentgenol* 1997;169:977-83.
47. Rizzato G. The role of thoracic surgery in diagnosing interstitial lung disease. *Curr Opin Pulm Med* 1999;5:284-6.
48. Ayed AK, Raghunathan R. Thoracoscopy versus open lung biopsy in the diagnosis of interstitial lung disease: a randomized controlled trial. *J R Coll Surg Edinb* 2000;45:159-63.
49. The BAL Cooperative Group Steering Committee. Bronchoalveolar lavage constituents in healthy individuals, idiopathic pulmonary fibrosis, and selected comparison groups. *Am Rev Respir Dis* 1990;141:S169-S202.
50. Bitterman PB, Rennard SI, Keogh BA, Wewers MD, Adelberg S, Crystal RG. Familial idiopathic pulmonary fibrosis: evidence of lung inflammation in unaffected family members. *N Engl J Med* 1986;314:1343-7.
51. Martinez TY, Pereira CA, dos Santos ML, Ciconelli RM, Guimaraes SM, Martinez JA. Evaluation of the short-form 36-item questionnaire to measure health-related quality of life in patients with idiopathic pulmonary fibrosis. *Chest* 2000;117:1627-32.
52. Panos RJ, Mortenson RL, Niccoli SA, King TE Jr. Clinical deterioration in patients with idiopathic pulmonary fibrosis: causes and assessment. *Am J Med* 1990;88:396-404.
53. Tobin RW, Pope CE II, Pellegrini CA, Emond MJ, Sillery J, Raghu G. Increased prevalence of gastroesophageal reflux in patients with idiopathic pulmonary fibrosis. *Am J Respir Crit Care Med* 1998;158:1804-8.
54. Vizza CD, Lynch JP, Ochoa LL, Richardson G, Trulock EP. Right and left ventricular dysfunction in patients with severe pulmonary disease. *Chest* 1998;113:576-83.
55. Samet JM. Does idiopathic pulmonary fibrosis increase lung cancer risk? *Am J Respir Crit Care Med* 2000;161:1-2.
56. Bjoraker JA, Ryu JH, Edwin MK, et al. Prognostic significance of histopathologic subsets in idiopathic pulmonary fibrosis. *Am J Respir Crit Care Med* 1998;157:199-203.
57. Gay SE, Kazerooni EA, Toews GB, et al. Idiopathic pulmonary fibrosis: predicting response to therapy and survival. *Am J Respir Crit Care Med* 1998;157:1063-72.

58. Mapel DW, Hunt WC, Utton R, Baumgartner KB, Samet JM, Coultas DB. Idiopathic pulmonary fibrosis: survival in population based and hospital based cohorts. *Thorax* 1998;53:469-76.
59. Schwartz DA, Van Fossen DS, Davis CS, et al. Determinants of progression in idiopathic pulmonary fibrosis. *Am J Respir Crit Care Med* 1994;149:444-9.
60. Schwartz DA, Helmers RA, Galvin JR, et al. Determinants of survival in idiopathic pulmonary fibrosis. *Am J Respir Crit Care Med* 1994;149:450-4.
61. Turner-Warwick MB, Burrows B, Johnson A. Cryptogenic fibrosing alveolitis: response to corticosteroid treatment and its effect on survival. *Thorax* 1980;35:593-9.
62. Baughman RP, Lower EE. Use of intermittent, intravenous cyclophosphamide for idiopathic pulmonary fibrosis. *Chest* 1992;102:1090-4.
63. Johnson MA, Kvan S, Snell NJC, Nunn AJ, Darbyshire JH, Turner-Warwick M. Randomised controlled trial comparing prednisolone alone with cyclophosphamide and low dose prednisolone in combination in cryptogenic fibrosing alveolitis. *Thorax* 1989;44:280-8.
64. Lee JS, Im JG, Ahn JM, Kim YM, Han MC. Fibrosing alveolitis: prognostic implication of ground-glass attenuation at high-resolution CT. *Radiology* 1992;184:451-4.
65. Akira M, Sakatani M, Ueda E. Idiopathic pulmonary fibrosis: progression of honeycombing at thin-section CT. *Radiology* 1993;189:687-91.
66. Kolb M, Kirschner J, Riedel W, Wirtz H, Schmidt M. Cyclophosphamide pulse therapy in idiopathic pulmonary fibrosis. *Eur Respir J* 1998;12:1409-14.
67. Dayton CS, Schwartz DA, Helmers RA, et al. Outcome of subjects with idiopathic pulmonary fibrosis who fail corticosteroid therapy: implications for future studies. *Chest* 1993;103:69-73.
68. Zisman DA, Lynch JP III, Toews GB, Kazerooni EA, Flint A, Martinez FJ. Cyclophosphamide in the treatment of idiopathic pulmonary fibrosis: a prospective study in patients who failed to respond to corticosteroids. *Chest* 2000;117:1619-26.
69. Douglas WW, Ryu JH, Swensen SJ, et al. Colchicine versus prednisone in the treatment of idiopathic pulmonary fibrosis: a randomized prospective study. *Am J Respir Crit Care Med* 1998;158:220-5.
70. Douglas WW, Ryu JH, Schroeder DR. Idiopathic pulmonary fibrosis: impact of oxygen and colchicine, prednisone, or no therapy on survival. *Am J Respir Crit Care Med* 2000;161:1172-8.
71. Selman M, Carrillo G, Salas J, et al. Colchicine, D-penicillamine, and prednisone in the treatment of idiopathic pulmonary fibrosis: a controlled clinical trial. *Chest* 1998;114:507-12.
72. Nicod LP. Pirfenidone in idiopathic pulmonary fibrosis. *Lancet* 1999;354:268-9.
73. Iyer SN, Gurujeyalakshmi G, Giri SN. Effects of pirfenidone on pro-collagen gene expression at the transcriptional level in bleomycin hamster model of lung fibrosis. *J Pharmacol Exp Ther* 1999;289:211-8.
74. Kehrer JP, Margolin SB. Pirfenidone diminishes cyclophosphamide-induced lung fibrosis in mice. *Toxicol Lett* 1997;90:125-32.
75. Raghu G, Johnson WC, Lockhart D, Mageto Y. Treatment of idiopathic pulmonary fibrosis with a new antifibrotic agent, pirfenidone: results of a prospective, open-label phase II study. *Am J Respir Crit Care Med* 1999;159:1061-9.
76. Bani D. Relaxin: a pleiotropic hormone. *Gen Pharmacol* 1997;28:13-22.
77. Unemori EN, Pickford LB, Salles AL, et al. Relaxin induces an extracellular matrix-degrading phenotype in human lung fibroblasts in vitro and inhibits lung fibrosis in a murine model in vivo. *J Clin Invest* 1996;98:2739-45.
78. Seibold JR, Korn JH, Simms R, et al. Recombinant human relaxin in the treatment of scleroderma: a randomized, double-blind, placebo-controlled trial. *Ann Intern Med* 2000;132:871-9.
79. Klijn JG, Setyono-Han B, Bakker GH, et al. Growth factor-receptor pathway interfering treatment by somatostatin analogs and suramin: pre-clinical and clinical studies. *J Steroid Biochem Mol Biol* 1990;37:1089-95.
80. Mietz H, Chevez-Barrios P, Feldman RM, Lieberman MW. Suramin inhibits wound healing following filtering procedures for glaucoma. *Br J Ophthalmol* 1998;82:816-20.
81. Teder P, Noble PW. A cytokine reborn? Endothelin-1 in pulmonary inflammation and fibrosis. *Am J Respir Cell Mol Biol* 2000;23:7-10.
82. Mutsaers SE, Foster ML, Chambers RC, Laurent GJ, McAnulty RJ. Increased endothelin-1 and its localization during the development of bleomycin-induced pulmonary fibrosis in the rat. *Am J Respir Cell Mol Biol* 1998;18:611-9.
83. Park SH, Saleh D, Gaid A, Michel RP. Increased endothelin-1 in bleomycin-induced pulmonary fibrosis and the effect of an endothelin receptor antagonist. *Am J Respir Crit Care Med* 1997;156:600-8.
84. Marshall RP, McAnulty RJ, Laurent GJ. Angiotensin II is mitogenic for human lung fibroblasts via activation of the type 1 receptor. *Am J Respir Crit Care Med* 2000;161:1999-2004.
85. Wang R, Ramos C, Joshi I, et al. Human lung myofibroblast-derived inducers of alveolar epithelial apoptosis identified as angiotensin peptides. *Am J Physiol* 1999;277:L1158-L1164.
86. Lawrence DA. Transforming growth factor-beta: a general review. *Eur Cytokine Netw* 1996;7:363-74.
87. McCormick LL, Zhang Y, Tootell E, Gilliam AC. Anti-TGF-beta treatment prevents skin and lung fibrosis in murine sclerodermatous graft-versus-host disease: a model for human scleroderma. *J Immunol* 1999;163:5693-9.
88. Chiamonte MG, Donaldson DD, Cheever AW, Wynn TA. An IL-13 inhibitor blocks the development of hepatic fibrosis during a T-helper type 2-dominated inflammatory response. *J Clin Invest* 1999;104:777-85.
89. Nonn RA, Garrity ER Jr. Lung transplantation for fibrotic lung diseases. *Am J Med Sci* 1998;315:146-54.
90. Meyers BF, Lynch J, Trulock EP, Guthrie T, Cooper JD, Patterson GA. Single versus bilateral lung transplantation for idiopathic pulmonary fibrosis: a ten-year institutional experience. *J Thorac Cardiovasc Surg* 2000;120:99-107.
91. *Idem*. Lung transplantation: a decade of experience. *Ann Surg* 1999;230:362-70.
92. Lok SS. Interstitial lung disease clinics for the management of idiopathic pulmonary fibrosis: a potential benefit to patients. *J Heart Lung Transplant* 1999;18:884-90.

Copyright © 2001 Massachusetts Medical Society.