

Angiotensin-converting enzyme inhibitor-induced unilateral tongue angioedema

A. MLYNAREK, MD, A. HAGR, MD, and K. KOST, MD, Montreal, Quebec, Canada

Angioedema, also known as angioneurotic edema or Quincke's disease, is a localized transient swelling of sudden onset that can occur in the face, lips, tongue, hands, feet, and gastrointestinal system. Angiotensin-converting enzyme (ACE) inhibitors have been implicated in multiple cases of angioedema, with the oral region being the most common site of presentation.^{1,2} Tongue edema has been reported to be one of the risk factors leading to airway compromise.³ In this article we present a case of unilateral tongue angioedema induced by Vasotec (enalapril) and review the literature pertaining to this disease. To our knowledge, there are no reported cases in the English literature describing this unilateral form of tongue edema.

CASE REPORT

A 73-year-old white woman presented to the emergency department at the Montreal General Hospital with a 5-hour history of asymmetric tongue swelling. Her past medical history included diabetes mellitus, hypertension, hypothyroidism, and Bell's palsy. The patient also had previous rectal surgery for rectal cancer, with no adjuvant chemotherapy or radiotherapy. She was taking multiple medications, including nifedipine, lorazepam, clonidine, levothyroxine, aspirin, enalapril, and hydrochlorothiazide. She had been taking enalapril 20 mg twice a day for at least 3 years. The patient had no known allergies, smoked about 15 cigarettes per day, and did not drink alcohol.

On her arrival to the emergency department, she complained of a sudden onset of slowly increasing swelling of the left side of the tongue. She was unable to swallow but had no pain, respiratory difficulties, stridor, or fever. There was no history of a previous occurrence or trauma and no association with meals. The patient denied changing any habits such as soap, toothpaste, or food, and there was no recent change with her medications. On examination, the patient had a diffuse, soft, and nontender swelling of the left tongue and floor of mouth (Fig 1). Mild left submandibular tenderness was noticed. There was no cervical lymphadenopathy. The remainder of the examination was normal. The patient was stable and afebrile with no respiratory distress. All blood tests were within normal limits with a white blood cell count of $13 \times 10^9/L$.

Computed tomography scan (Fig 2) was obtained and showed a homogeneous edema of the left tongue and floor of mouth. The submandibular glands were normal, there were no masses and no abscesses. The diagnosis of angioedema was made, and the patient was started on Solu-Medrol (methylprednisolone), Benadryl (diphenhydramine), and penicillin. She improved markedly overnight and was discharged home with a follow-up in the ENT clinic.

Three weeks after discharge, the patient presented again to the emergency department with an identical problem. At that time a possible connection between the angioedema and enalapril was postulated. The ACE inhibitor was then discontinued, and the patient was treated with prednisolone, Benadryl, and clindamycin and discharged home the same day. On follow-up at 1, 3, and 12 months, the patient was well.

DISCUSSION

Although there are many different causes of angioedema, most agree that there are 4 main causes²: 1) allergic reaction to food, drug, or environmental exposure due to an IgE-dependent type 1 hypersensitivity reaction; 2) congenital or

From the Department of Otolaryngology-Head and Neck Surgery, Montreal General Hospital, McGill University.

Reprint requests: Karen M. Kost, MD, FRCSC, Department of Otolaryngology-Head and Neck Surgery, McGill University, Montreal General Hospital, 1650 Cedar Ave, Montreal, Quebec H3G 1A4 Canada; e-mail, kmkost@yahoo.com.

Otolaryngol Head Neck Surg 2003;129:593-5.

Copyright © 2003 by the American Academy of Otolaryngology-Head and Neck Surgery Foundation, Inc.

0194-5998/2003/\$30.00 + 0

doi:10.1016/S0194-5998(03)00724-1

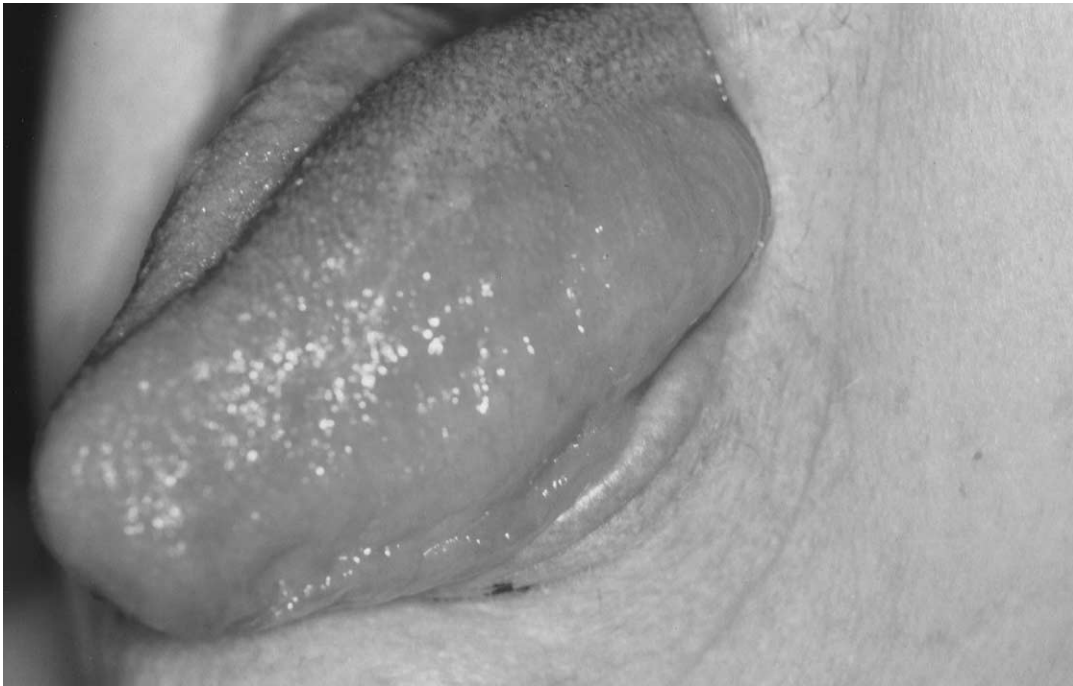

Fig 1. Angioedema of the left tongue and floor of mouth.

acquired loss of C1 esterase inhibitor due to a complement-mediated reaction; 3) ACE inhibitors; and 4) idiopathic.

ACE inhibitors are widely used medications for treatment of essential hypertension and chronic heart disease. They are considered to be efficacious and safe drugs. However, it has been shown that ACE inhibitors can cause interstitial edema. Some even consider these medications to be the number 1 cause of acute angioedema.¹ Several studies report that 25% to 35% of head and neck angioedema is caused by ACE inhibitors¹ and that the incidence of the disease in patients who are taking the medication is 0.1% to 0.2%.

The pathophysiology of ACE inhibitor-induced angioedema is thought not to be immunologic, because there are no antibodies to ACE inhibitors,⁴ but rather related to accentuated bradykinin activity. The edema can occur with any ACE inhibitor, regardless of the structure of the drug. ACEs convert angiotensin I to angiotensin II, but they also metabolize bradykinins. Therefore if these enzymes are inhibited by medication, there is an increase in kinins.⁴ Kinins, together with histamines and complement components, cause extravasation of fluid into interstitial space and

thus lead to localized, nonpitting edema. It has been postulated that a local increase in bradykinins causes vasodilatation, increases vascular permeability, and leads to interstitial edema.⁴

There has been much debate over the association between the length of use of ACE inhibitors and the development of angioedema.⁵ The incidence appears to be highest when the medication is first begun. Nonetheless, it has been shown that the edema can occur after days, months, and even years of taking the ACE inhibitors.

Moreover, there is some controversy about predicting the severity of the disease. It usually occurs suddenly with no precipitating factors and progresses very rapidly. Then, it can either regress spontaneously or the patient may need medical therapy or may need airway intervention. About 20% of patients with head and neck angioedema require such an intervention.² Several authors believe that the etiology is an important predicting factor and that angioedema caused by the ACE inhibitors leads to the extreme type.⁵ Other studies have noted that predilection for the tongue and oropharynx leads to a more severe form.^{1,2} Ishoo et al³ proposed a staging system by which airway risk may be predicted from the anatomic site of

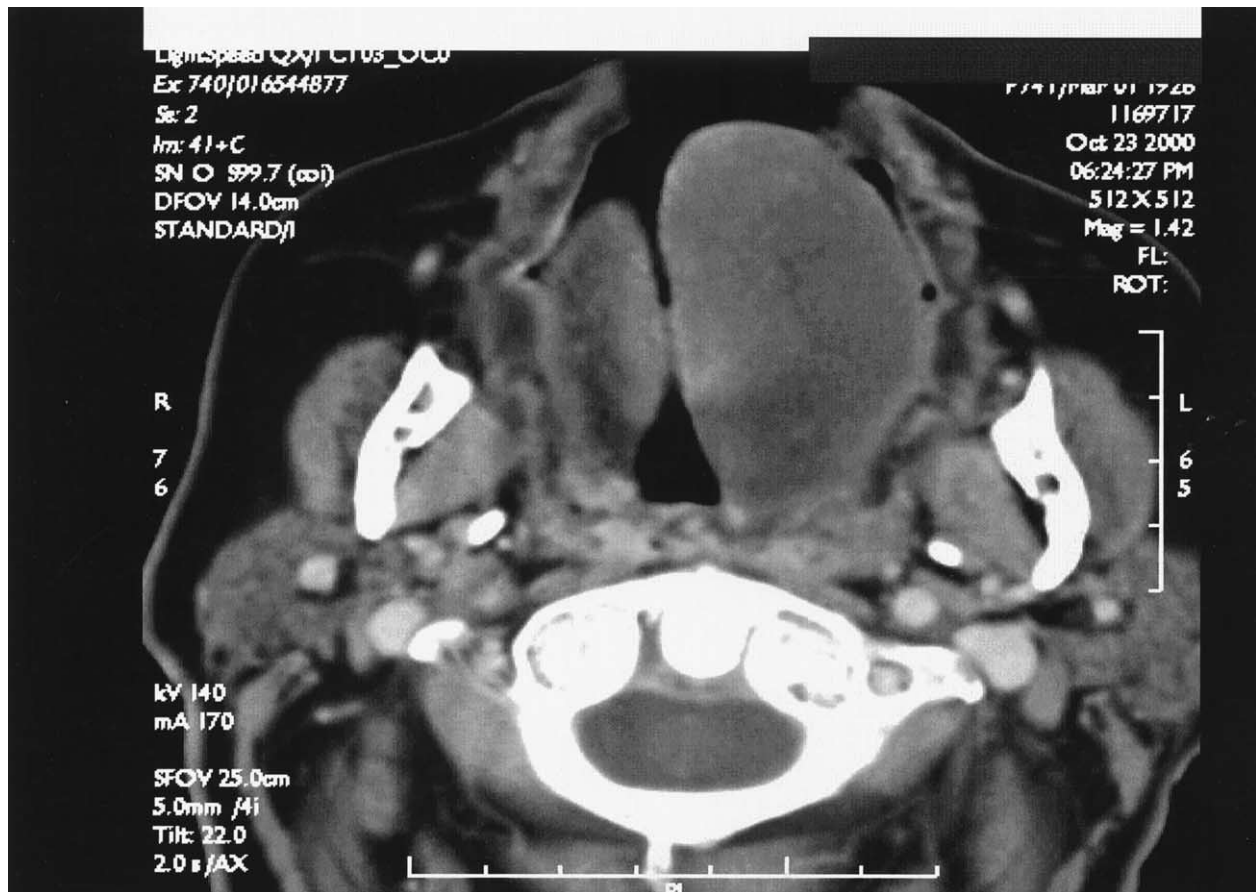


Fig 2. Computed tomography scan showing a homogeneous edema of left tongue and floor of mouth.

presentation: stage I, facial rash, facial and lip edema; patients can be treated as outpatients; stage II, soft palate edema; patients also can be treated as outpatients; stage III, lingual edema; patients usually require intensive care unit admission or very close monitoring and 7% required airway intervention; and stage IV: laryngeal edema; patients always require intensive care unit admission and very close supervision and 24% required airway intervention.

Nevertheless, most agree that once a diagnosis of ACE inhibitor-induced angioedema is made, the drug should be stopped, and the patient should receive oxygen, intravenous histamine blockers, steroids, and subcutaneous epinephrine (if not contraindicated).² Monitoring for at least 24 hours is mandatory. If the edema progresses very rapidly

or is unresponsive to medical therapy, the patient should be transferred to an intensive care unit for closer observation and possible airway intervention.

REFERENCES

1. Agah R, Bandi V, Guntupalli KK. Angioedema: the role of ACE inhibitors and factors associated with poor clinical outcome. *Intensive Care Med* 1997;23:793-6.
2. Zirkle M, Bhattacharyya N. Predictors of airway intervention in angioedema of the head and neck. *Otolaryngol Head Neck Surg* 2000;123:240-5.
3. Ishoo E, Shah UK, Grillone GA. Predicting airway risk in angioedema: Staging system based on presentation. *Otolaryngol Head Neck Surg* 1999;121:263-8.
4. Kyrmizakis DE, Papadakis CE, Fountoulakis EJ, et al. Tongue angioedema after long-term use of ACE inhibitors. *Am J Otolaryngol* 1998;19:394-6.
5. Thompson T, Frable MAS. Drug-induced, life-threatening angioedema revisited. *Laryngoscope* 1993;103:10-2.