



CASE PRESENTATION

DEN 491


Presented by:
Hussam Al-Salem



Demographic Data

- Age : 61
 - Gender : male
 - Social status : married
 - Education level : none
- 

Other information

- Diet : 3 meals / day
 - Oral hygiene : never brush his teeth
 - Heavy smoker (20 cigarettes / day)
- 

Patient interview

- Cc : I need upper and lower dentures
- History of Cc : the patient started losing his teeth twenty years ago due to neglecting his oral care.
- Dental History : the patient did several extractions and endo treatment without any complications.
- Medical History : The patient is not aware of any medical problems.

Clinical examination

```
graph TD; A[Clinical examination] --> B[Extra-oral]; A --> C[Intra-oral];
```

The diagram is a simple tree structure. At the top is a blue rounded rectangle containing the text 'Clinical examination'. A vertical line descends from the bottom center of this box and meets a horizontal line. From the left end of this horizontal line, a vertical line goes down to a second blue rounded rectangle containing the text 'Extra-oral'. From the right end of the horizontal line, a vertical line goes down to a third blue rounded rectangle containing the text 'Intra-oral'. The background is black with some faint blue decorative lines and dots in the lower-left corner.

Extra-oral

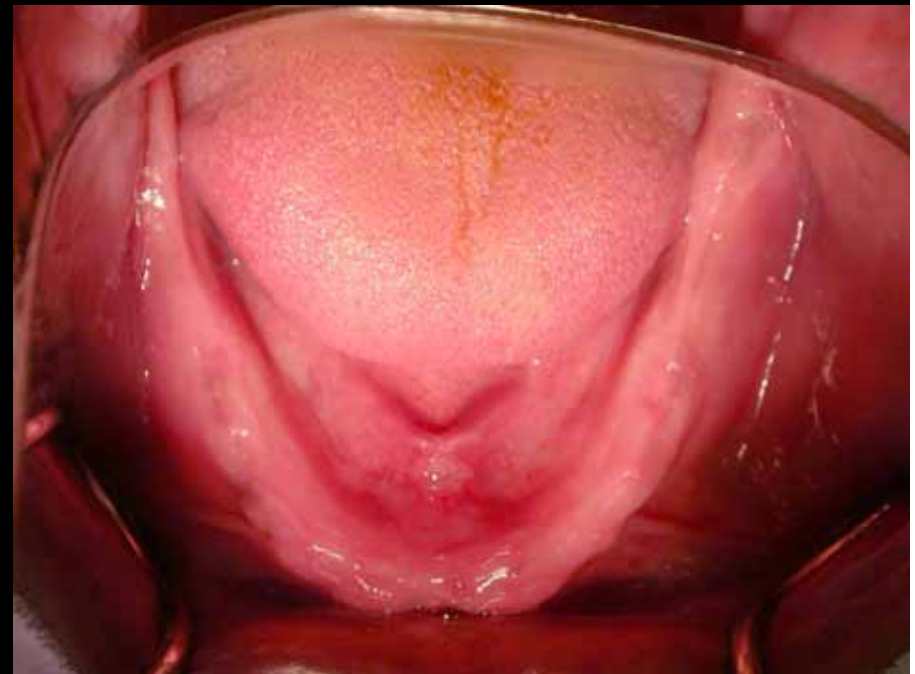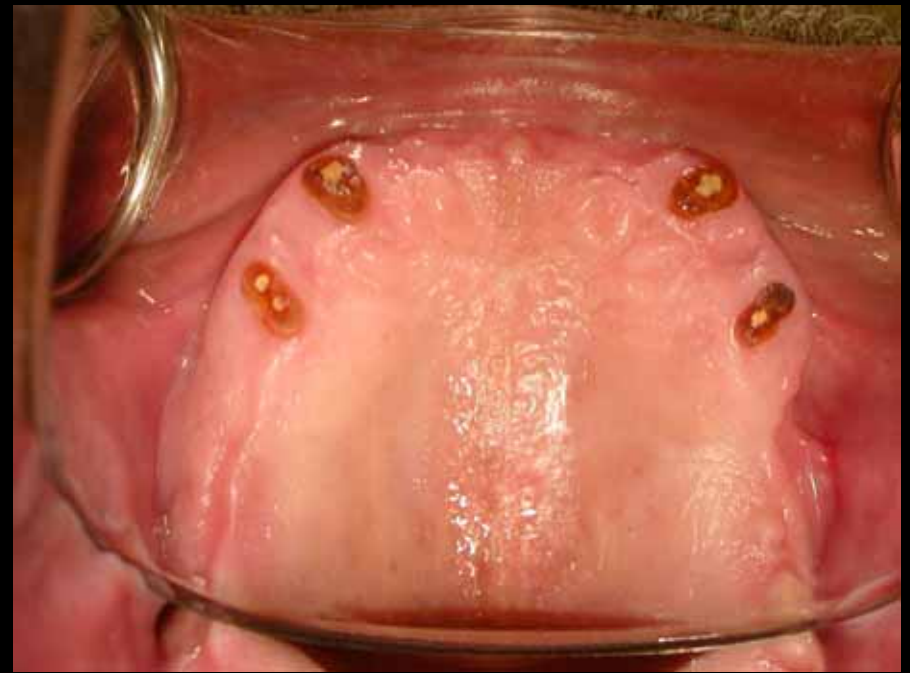Intra-oral

Extra-oral Examination

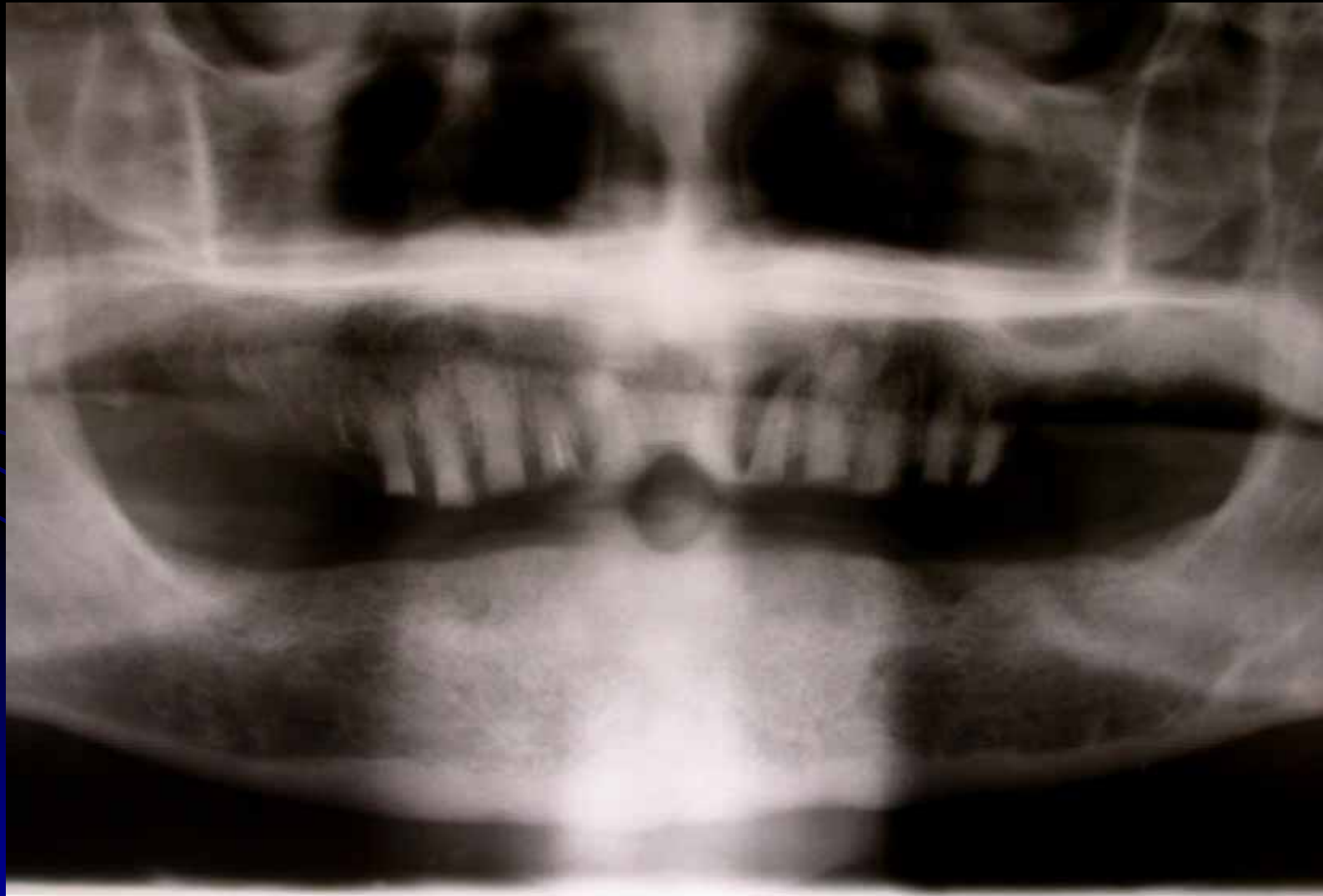
- TMJ : No clicking or deviation during opening and closing
- Hair, Eyes, nose, skin within normal
- Dry lips
- Lymph nodes : within normal (non palpable)
- Symmetrical face
- Ethnic body status

Intra-oral examination

- Labial & Buccal mucosa : within normal
- Floor of the mouth & tongue : within normal
- hard palate : Nicotine stomatitis
- Soft palate : within normal



Radiographic Examination



Treatment Plan

- Emergency phase:

The patient doesn't need any emergency treatment.

- Phase I (preventive):

Patient education and motivation, Oral Hygiene instructions.

Treatment plan presentation to the patient.

Prosthodontic, Periodontic and Endodontic consultations.

- Phase II (perio-surgery):

Re-evaluating the previous phase and planning for crown lengthening.

- Phase III (Restorative):

Endo treatment for the future abutments (#13, 15, 23, 25) + extraction of #11,12,14,21,22,24

- Phase IV (Definitive):

Treatment options:

1- Implant-supported fixed dentures.

2- Implant-supported removable dentures.

3- Upper over denture and lower complete denture.

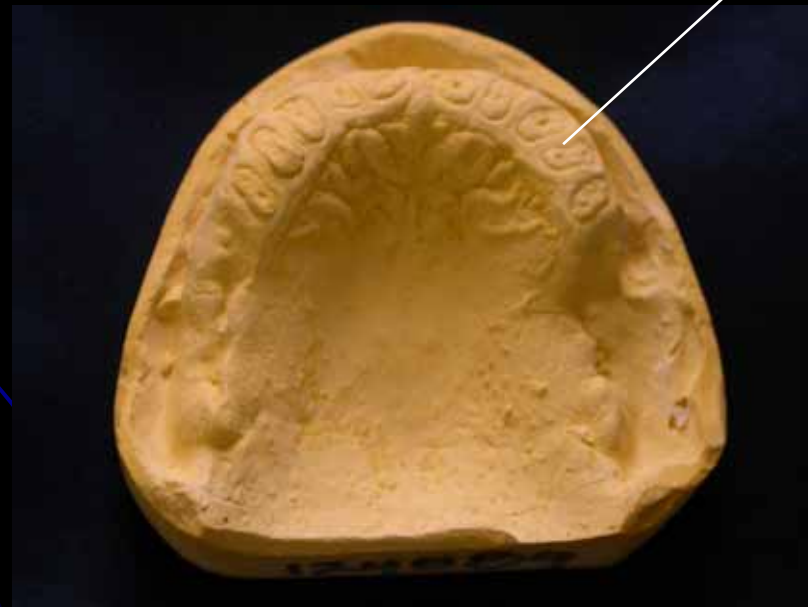
And due to the patient economic status, the 3rd option was chosen.

- Phase V (Maintenance):

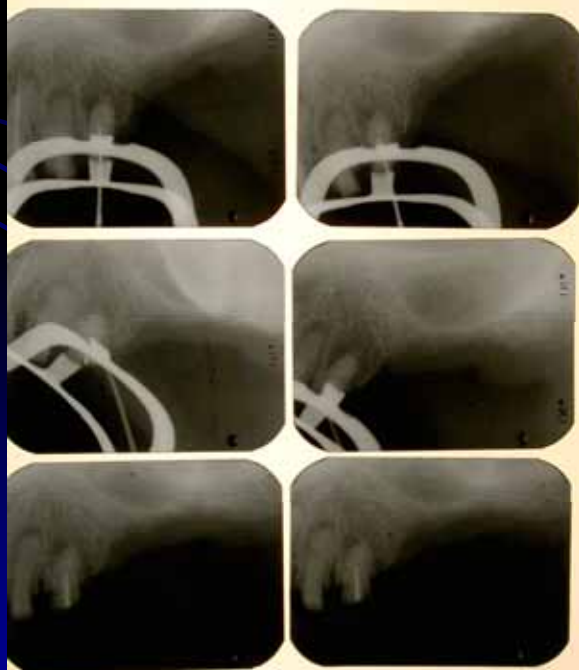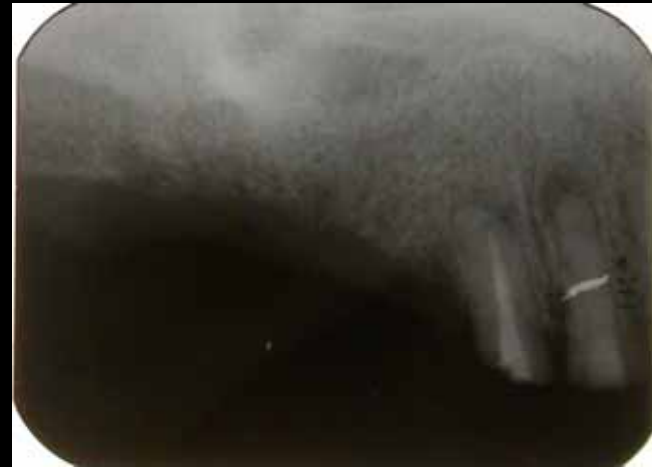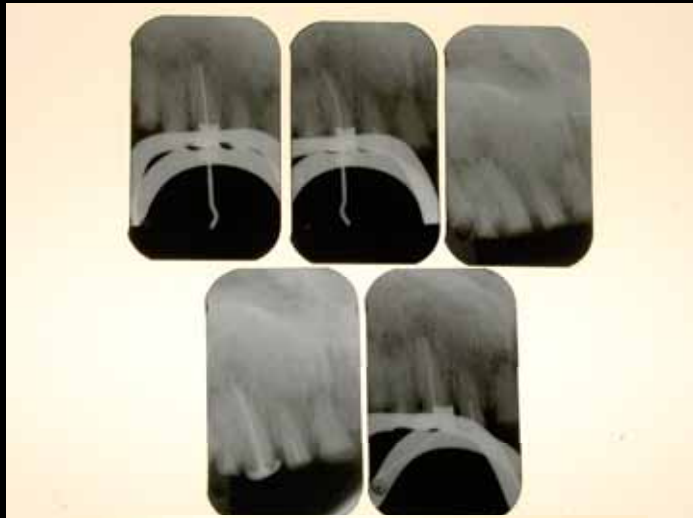Every 3-6 months.

Treatment procedures

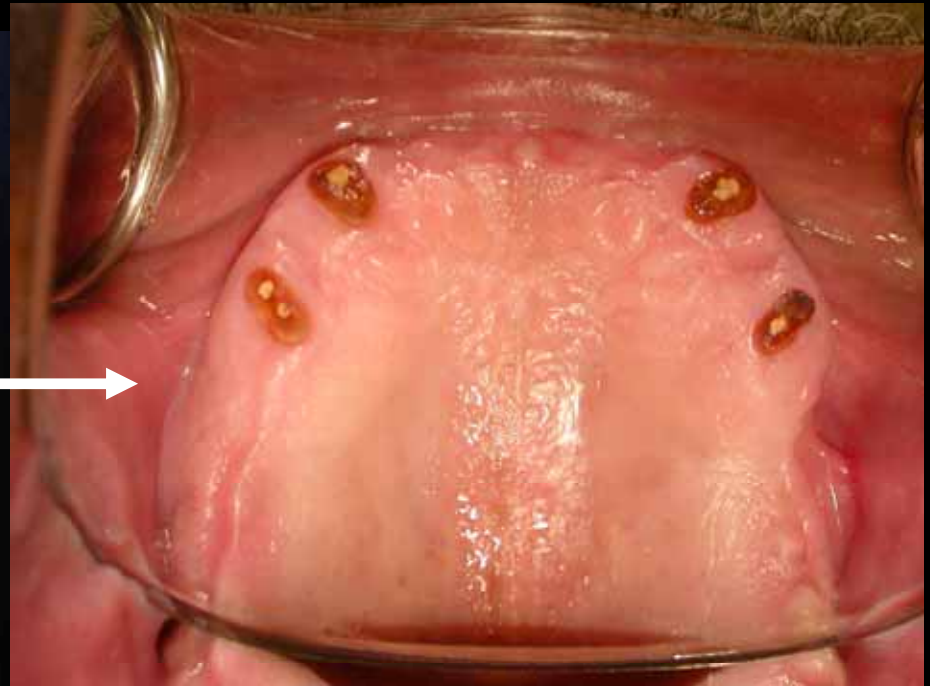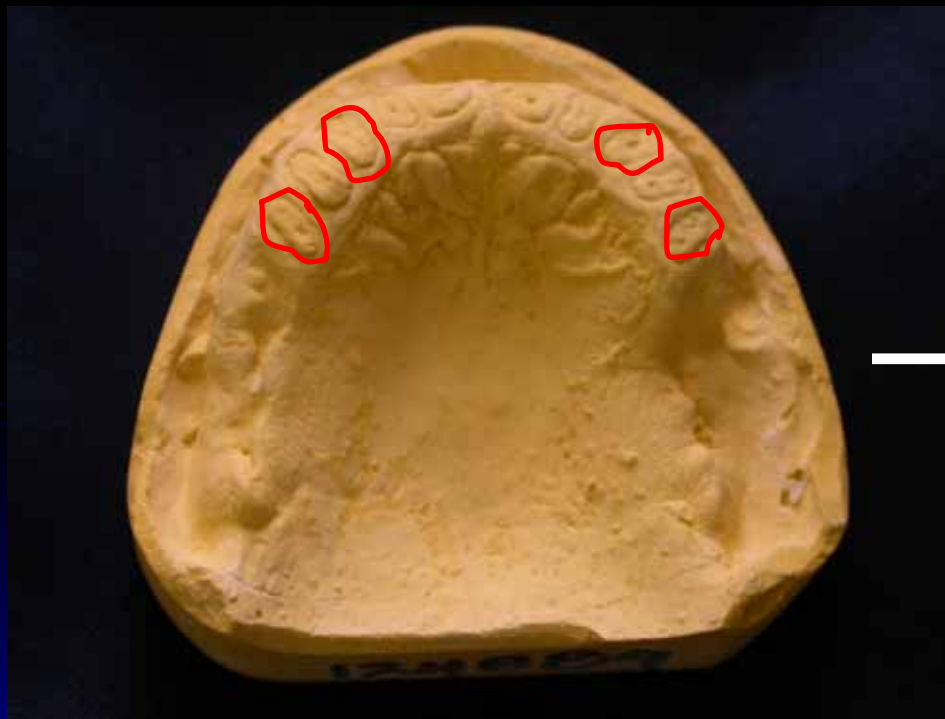1- Crown lengthening



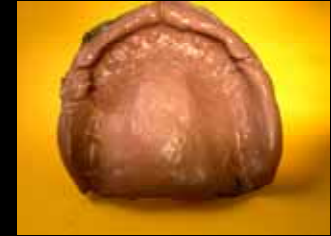- 2- Endo treatment



- 3- Extraction

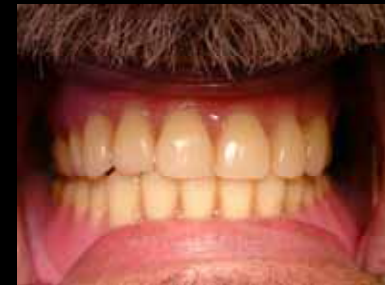

- Border molding & final impression

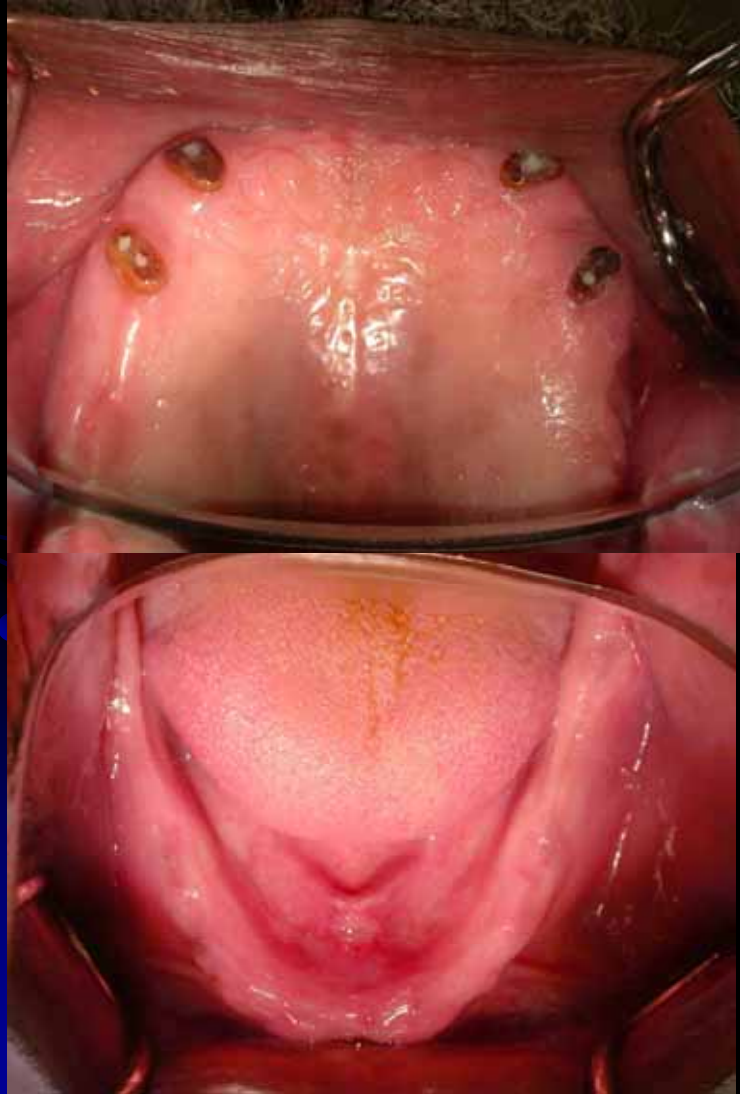


- Jaw relation and face-bow record

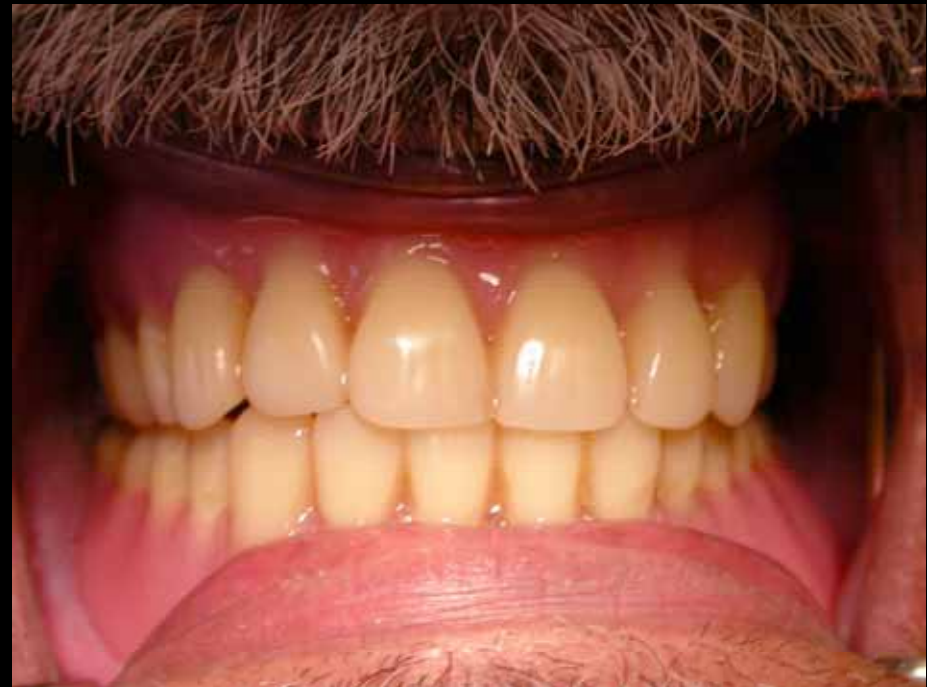- Upper and lower denture try-in



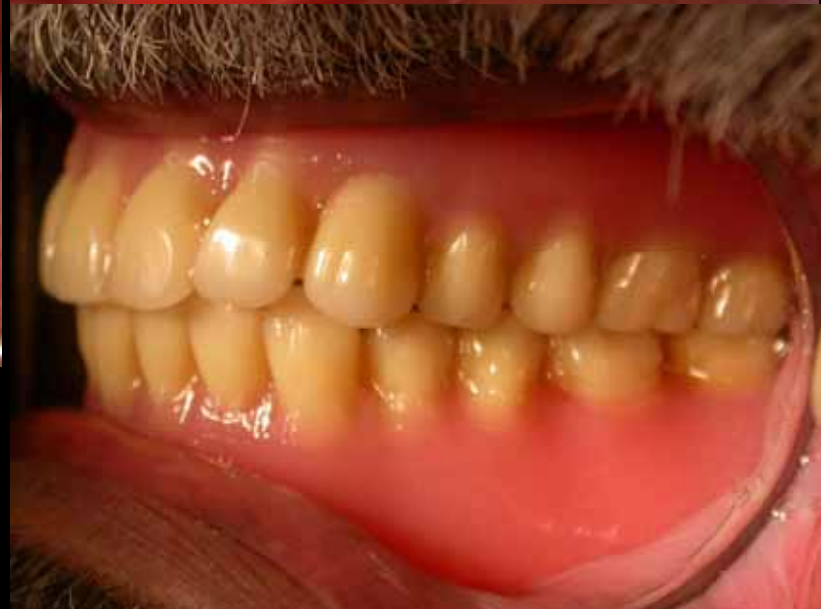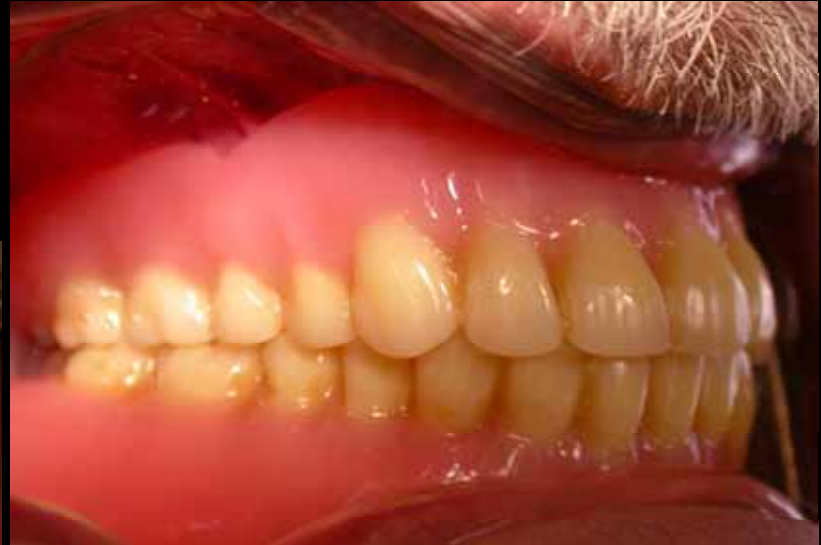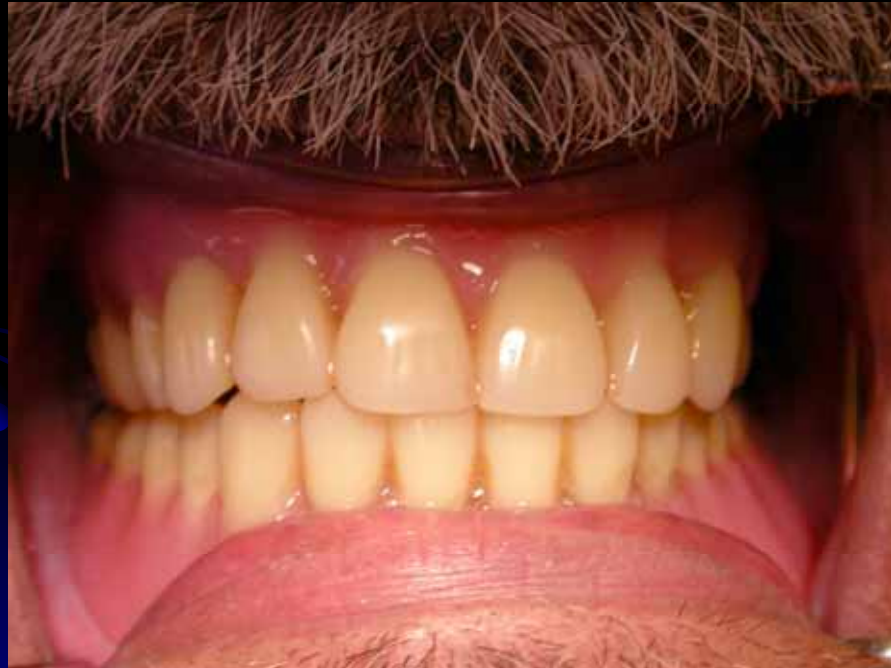Before



After



The Final Result



Thank you for listening

Any Questions ?

