



بِسْمِ اللَّهِ الرَّحْمَنِ الرَّحِيمِ

491 presentation

Done by :

Abdullah Bin Saeed

422000478

Supervised by :

Dr. Khalil Ali

Course director :

Prof. Khalid Alwazzan



INFORMATION GATHERING

A- Demographic data :

Age : 67

Gender : male

Nationality : Saudi

Socioeconomic : middle

Marital status : married

Occupation : retired



continue

B- Chief complaint : I want to replace my loose upper denture .

C- History c.c : I noticed it 3 months ago .

D- Medical history : diabetes type II and hypertension Dx
10 years ago and on medication .

E- Past dental history : several restoration and extraction
w/o complication last visit was 6 months ago .

F- Dental care/ habits : toothbrush : no
miswak : sometimes dental floss : no
mouthwash : no smoking : no

G- Dietary habit : 3 meals a day .



CLINICAL EXAMINATION

A- Extra oral :

Within normal extra oral feature .

No lymphadenopathy , no TMJ pain or clicking .

Symmetrical face , obese body build .

B- Intra oral :

1- soft tissue :

Palate red and inflammed

The rest are within normal.

continue

2- periodontium:

Generalized accumulation of plaque.

Inflamed gingiva # 21, 33 and 43 .

Generalized gingival recession .

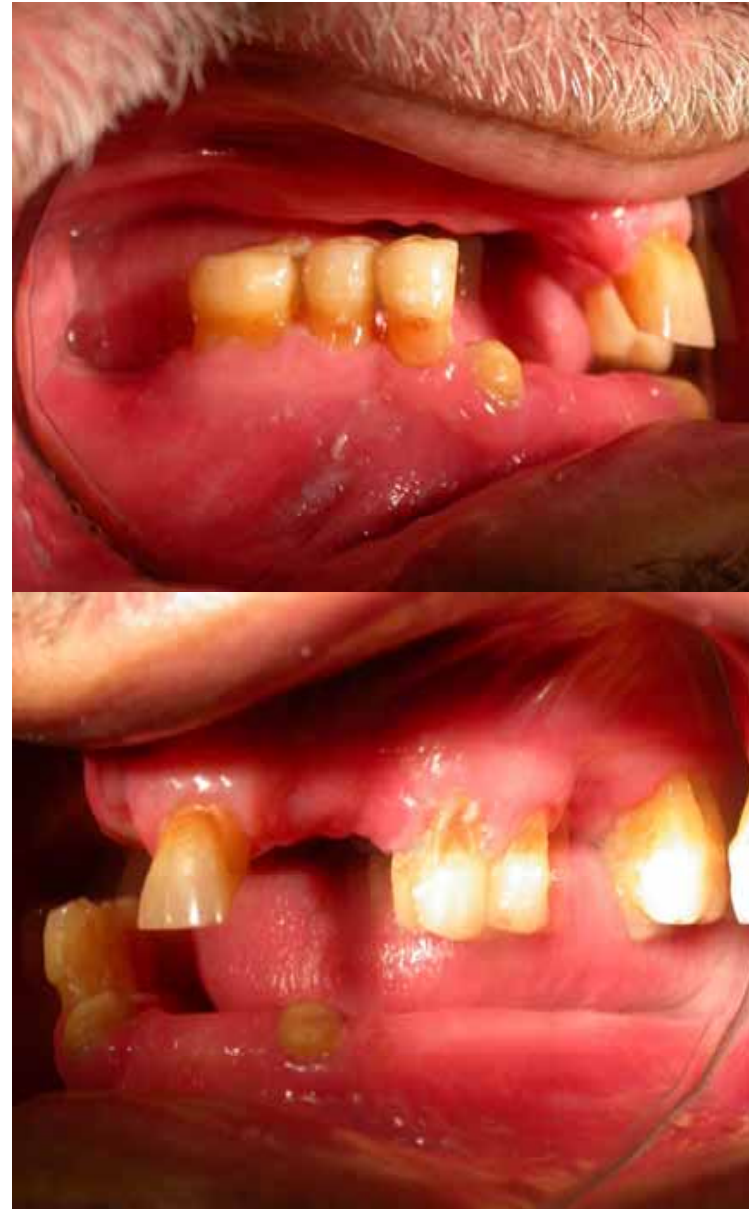Slight calculus accumulation .

3- oral hygiene:

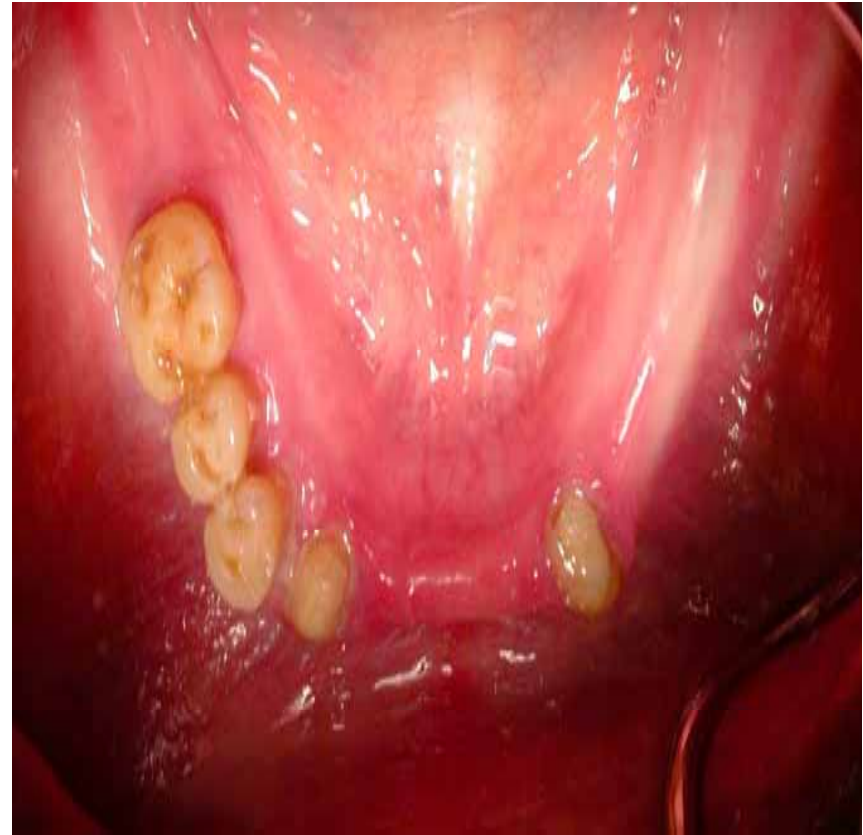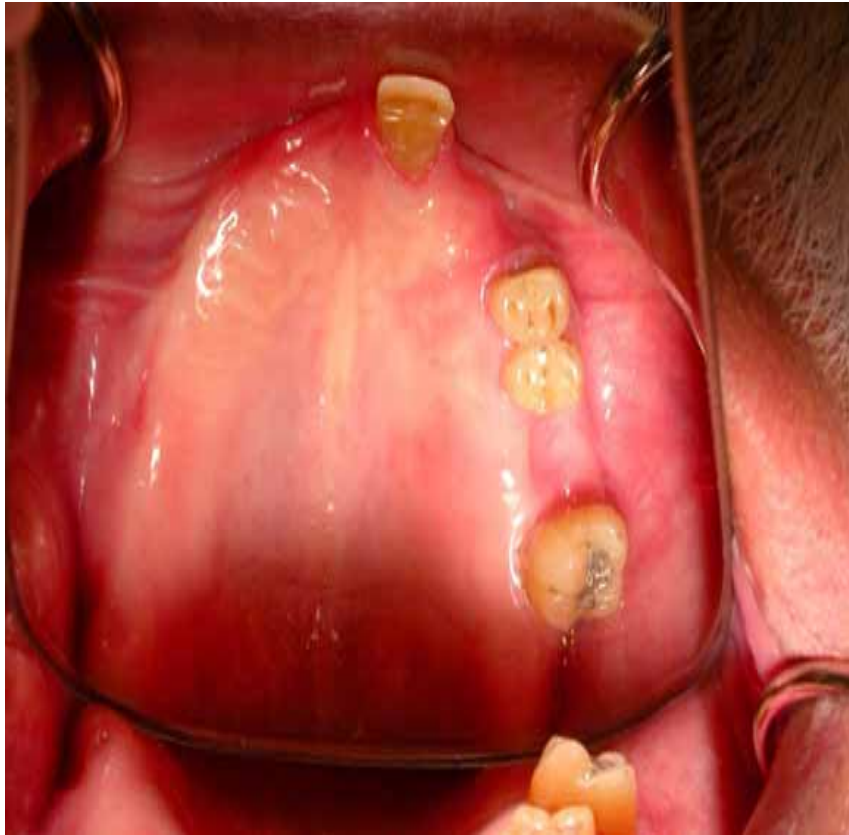
Fair.

PI : 50%

BI : 40%



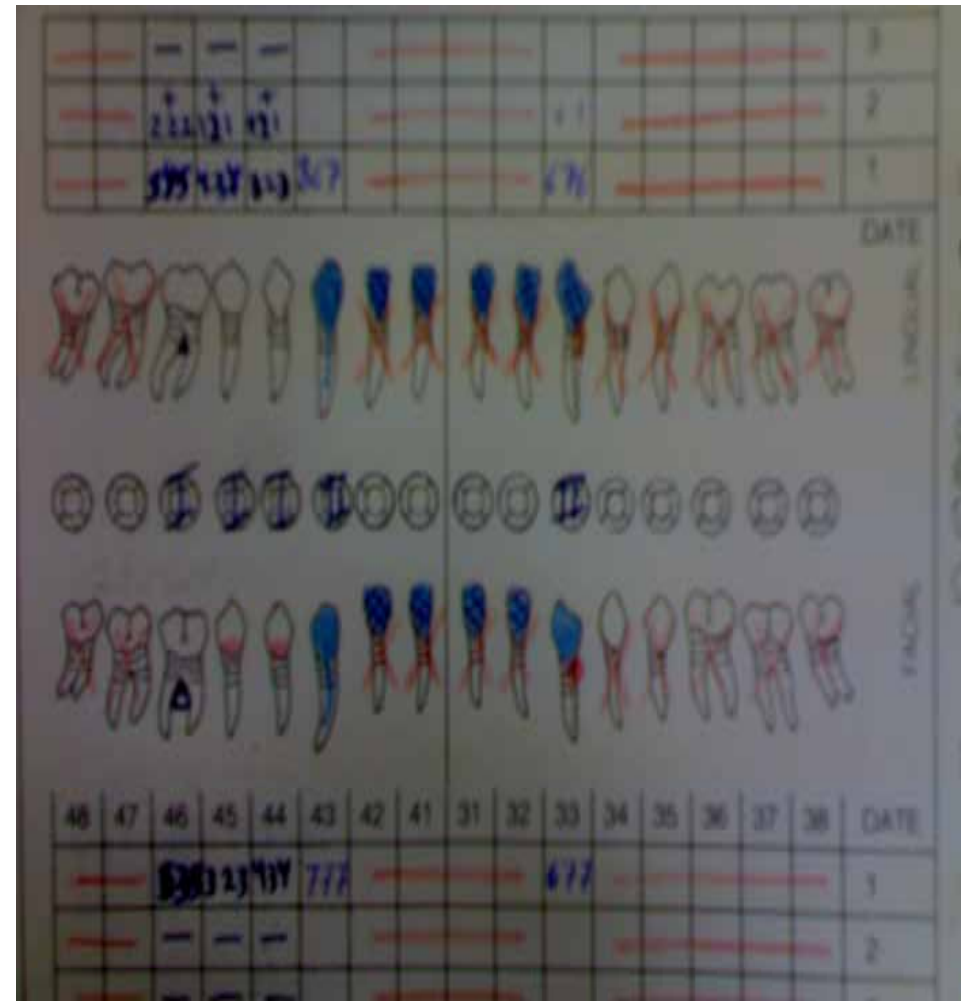
continue



CHARTING

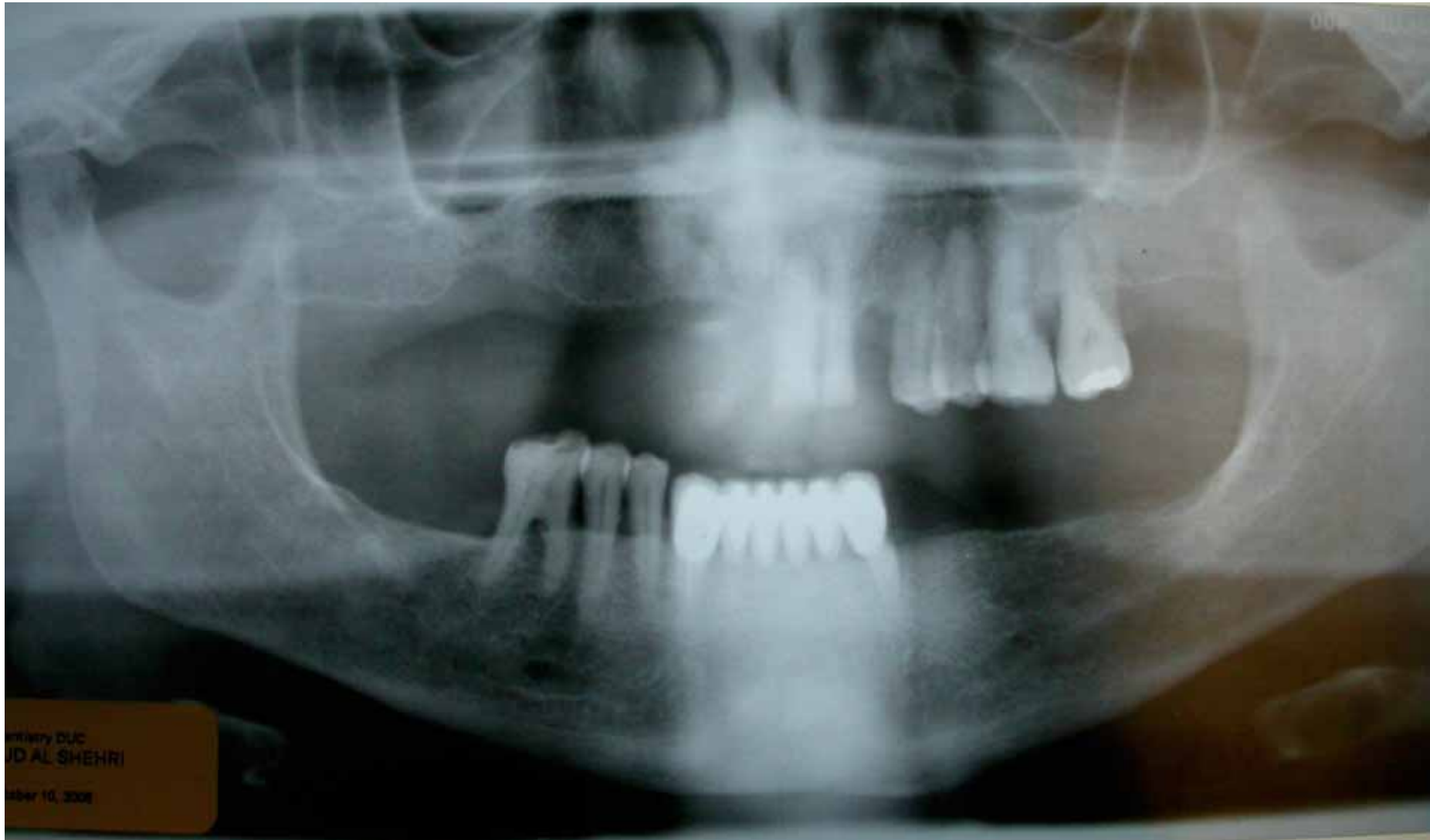

UPPER



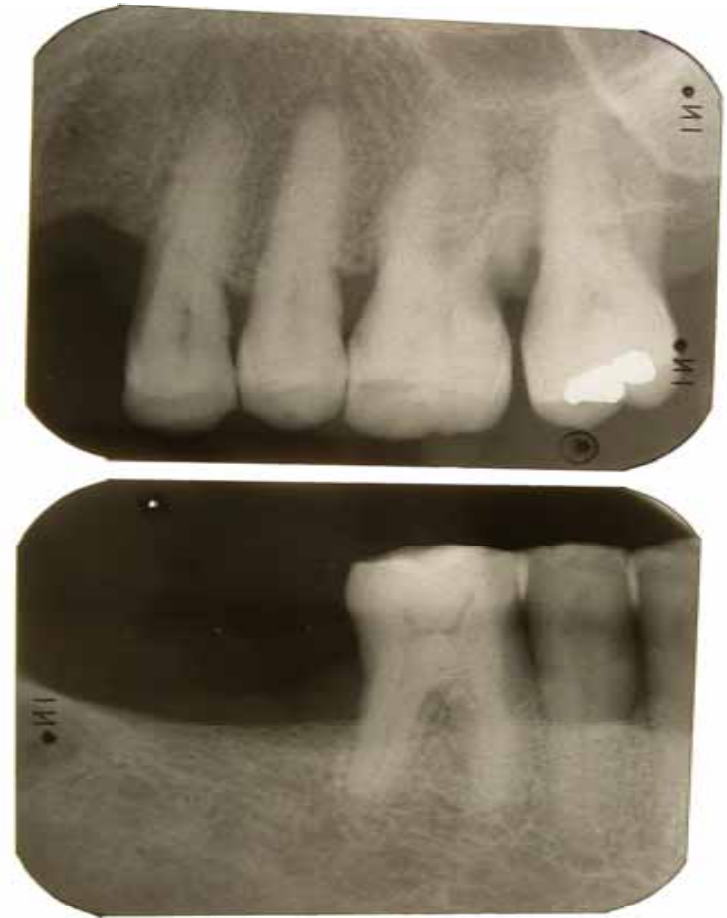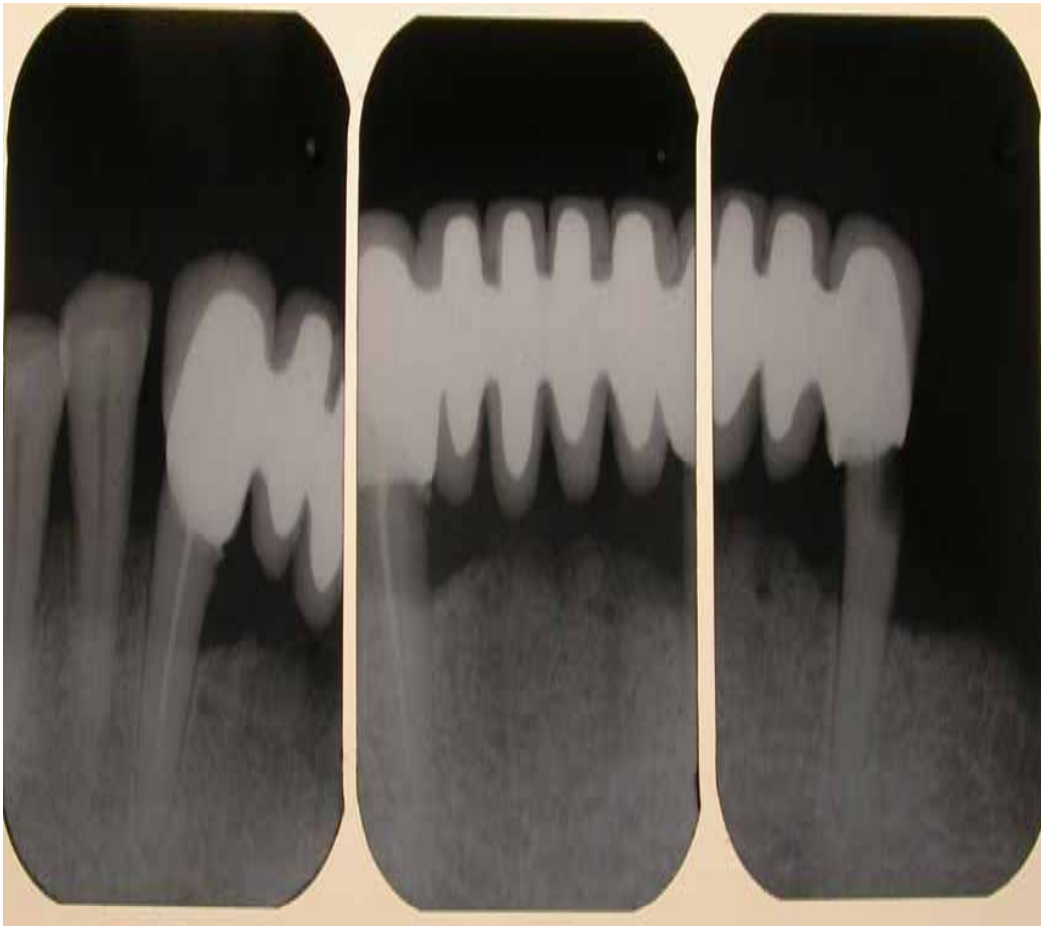
LOWER

RADIOGRAPHIC EXAMINATION



PANORAMIC

continue



Peri apical



Diagnosis

- 1- Palatal inflammation .
- 2- Localized plaque induced gingivitis # 21, 33 and 43.
- 3- Generalized severe chronic periodontitis .
(modified by systemic disease diabetes)
- 4- Generalized gingival recession .
- 5- Dental caries .
class V caries on teeth # 24, 25, 44 and 45 / distal root caries tooth # 26 .
- 6- Faulty RCT teeth # 33 and 43 .
- 7- Grade III mobility on teeth # 22 and 26 .



Treatment objective

- 1- modify the behavior by motivating the patient to improve his oral hygiene and dietary habit .
- 2- eliminate active diseases .
- 3- restore function .
- 4- restore phonetic .
- 5- restore esthetic .



Treatment options

1- Implant .

2- Implant supported FPD .

3- conventional RPD . 

Prognosis :

Good if the patient maintain excellent oral hygiene .



Treatment plan

Phase 1: (emergency)

Remove the upper transitional denture .

Chlorohexidine mouth wash .

Phase 2: (preventive)

Case presentation .

Motivation and education .

TX need and longevity .

Oral hygiene instruction .

Toothbrush type and brushing technique discussed .



Continue Tx plan

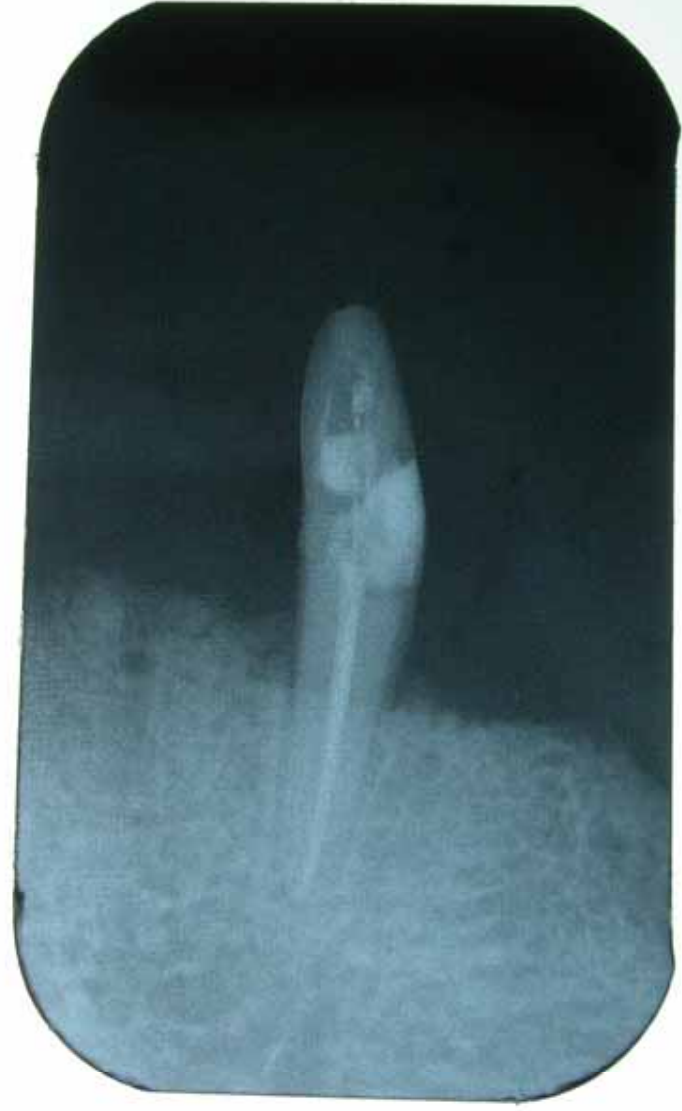
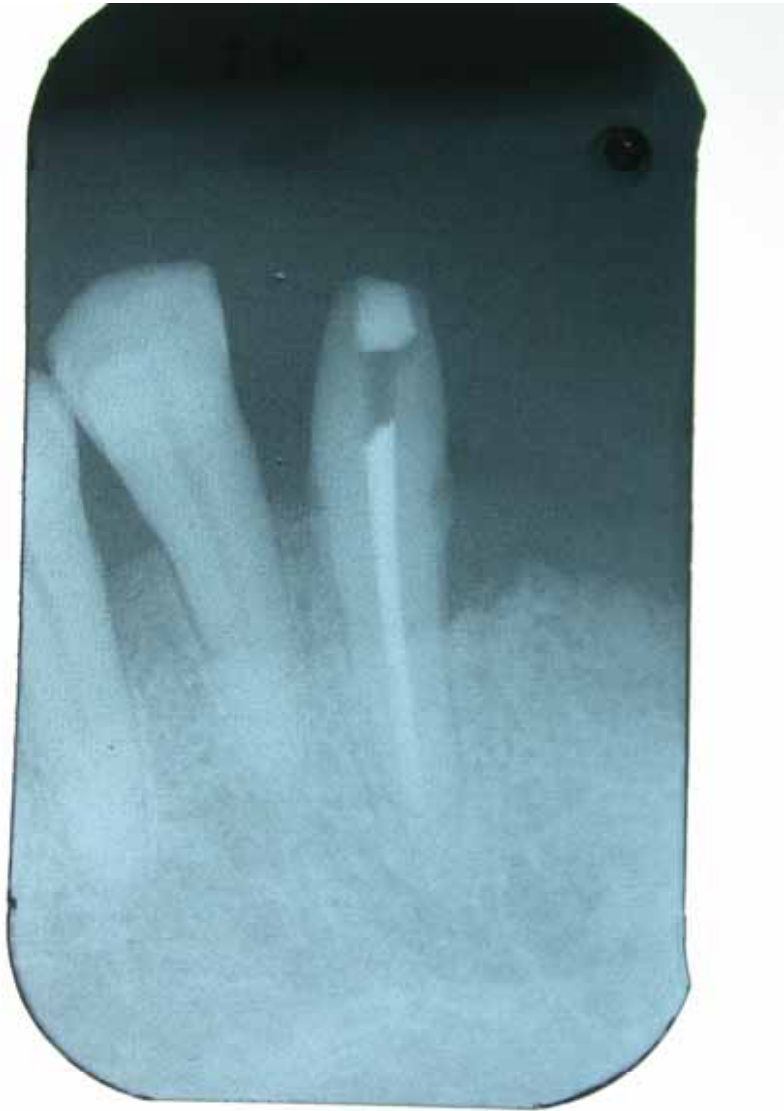Phase 3: (disease elimination)

Periodontal therapy (scaling , root planning)

Root canal retreatment teeth # 33 and 43 .

Restorative treatment class V sandwich technique on teeth
24, 25, 44 and 45 .

Extraction of tooth # 22 and 26 .





Continue Tx plan

Phase 4: (definitive)

Construct upper conventional RPD .

Construct lower RPD / over denture on teeth # 33 and 43 .

Gingival graft .

Bone augmentation in the upper right molar area .

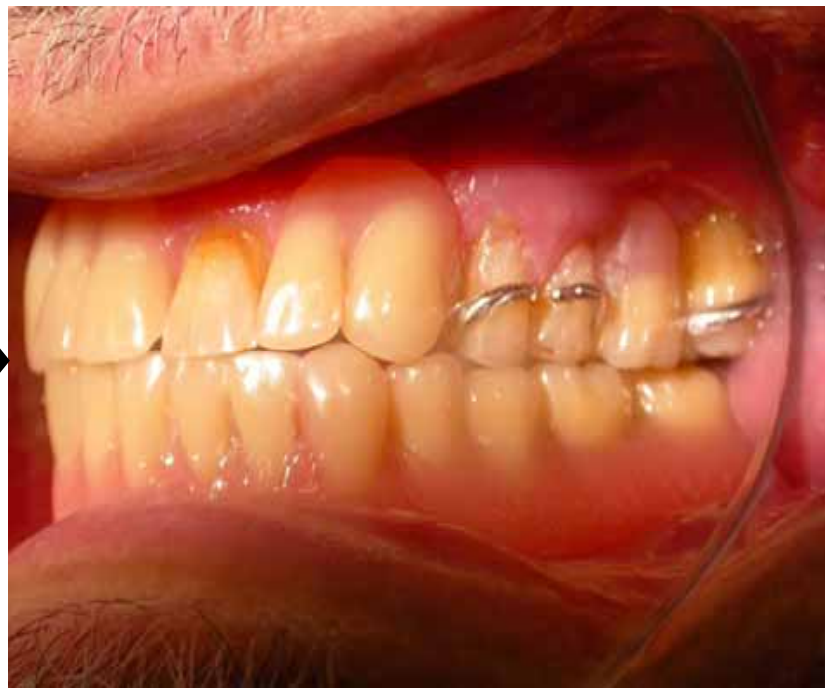
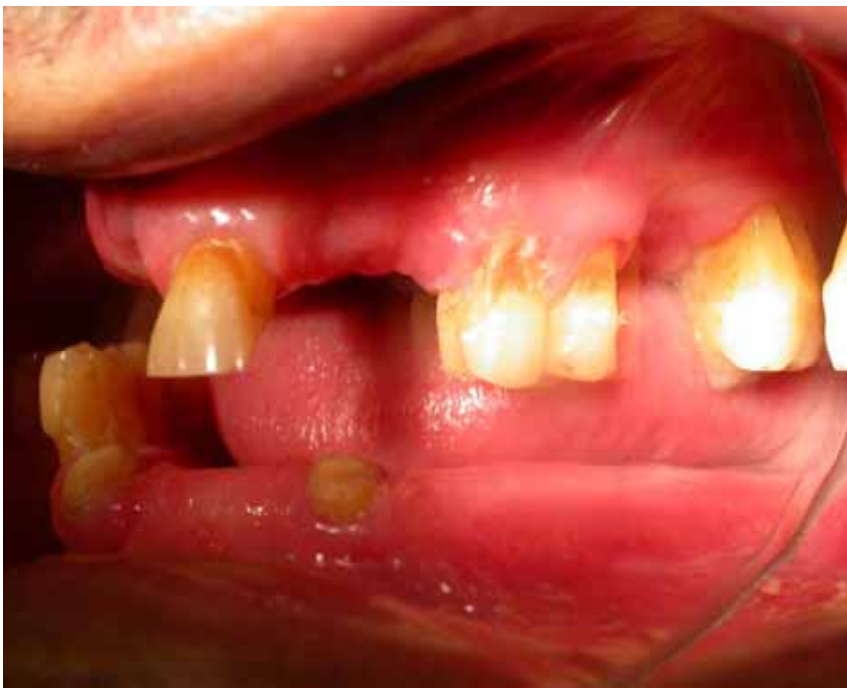
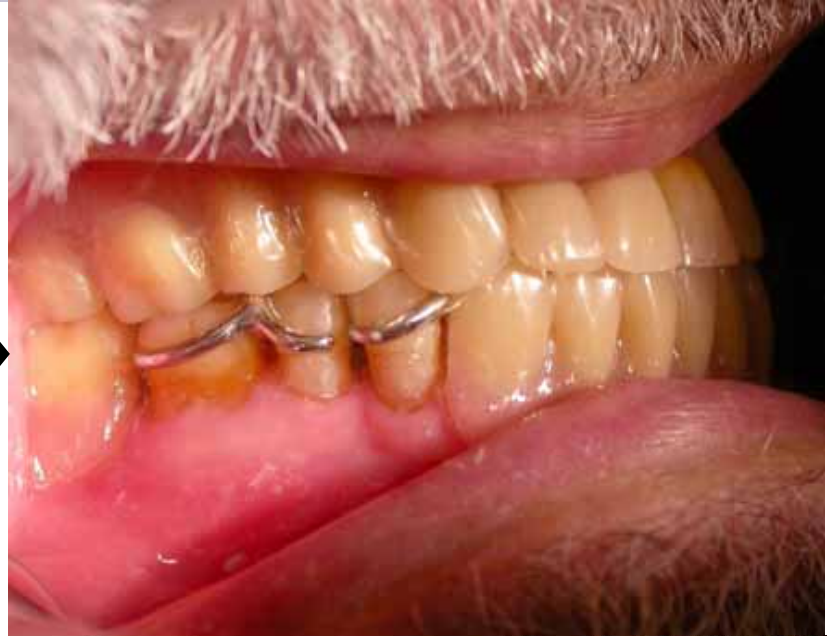
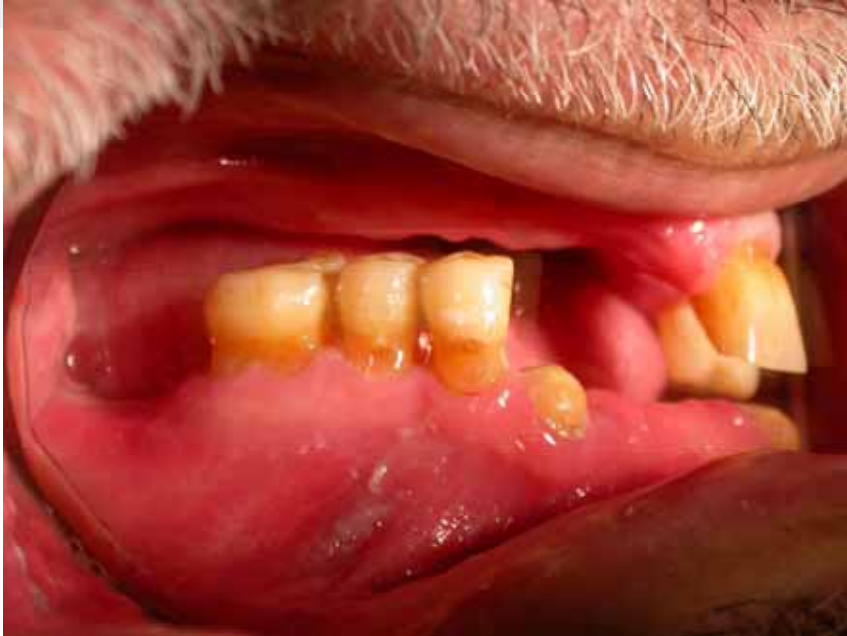Continue Tx plan

Phase 5: (maintenance and recall)

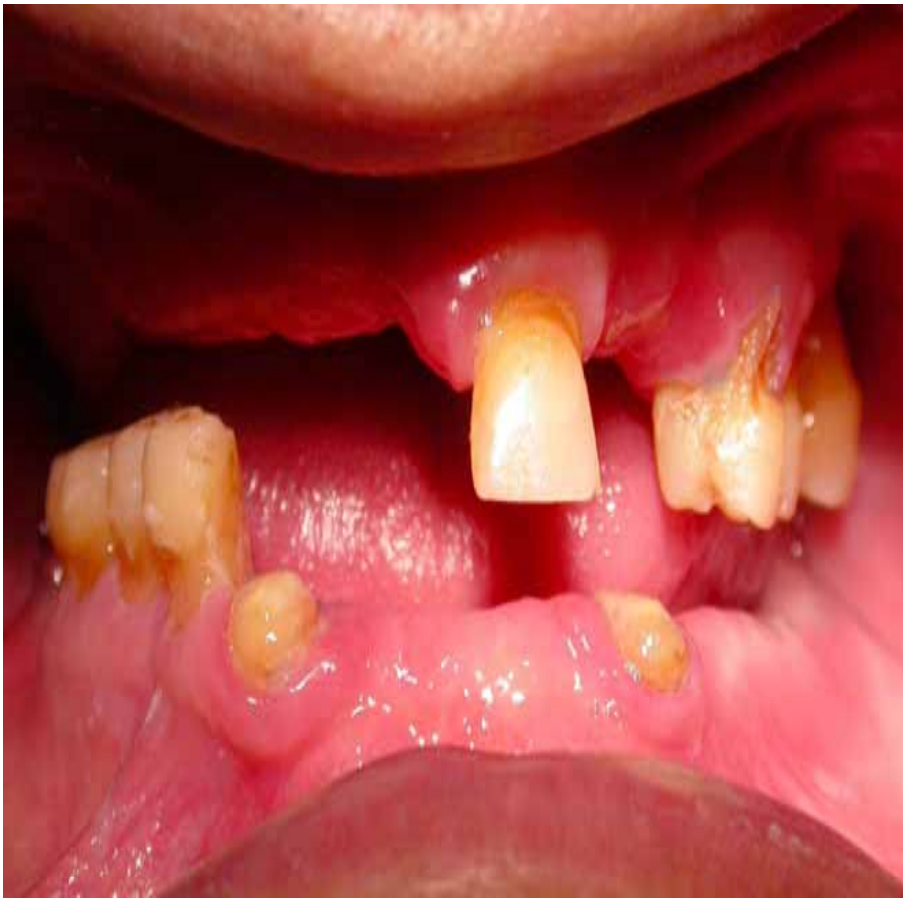Post insertion instruction .

Recall after 1 day , 1 week , 1 month and every 6 month .

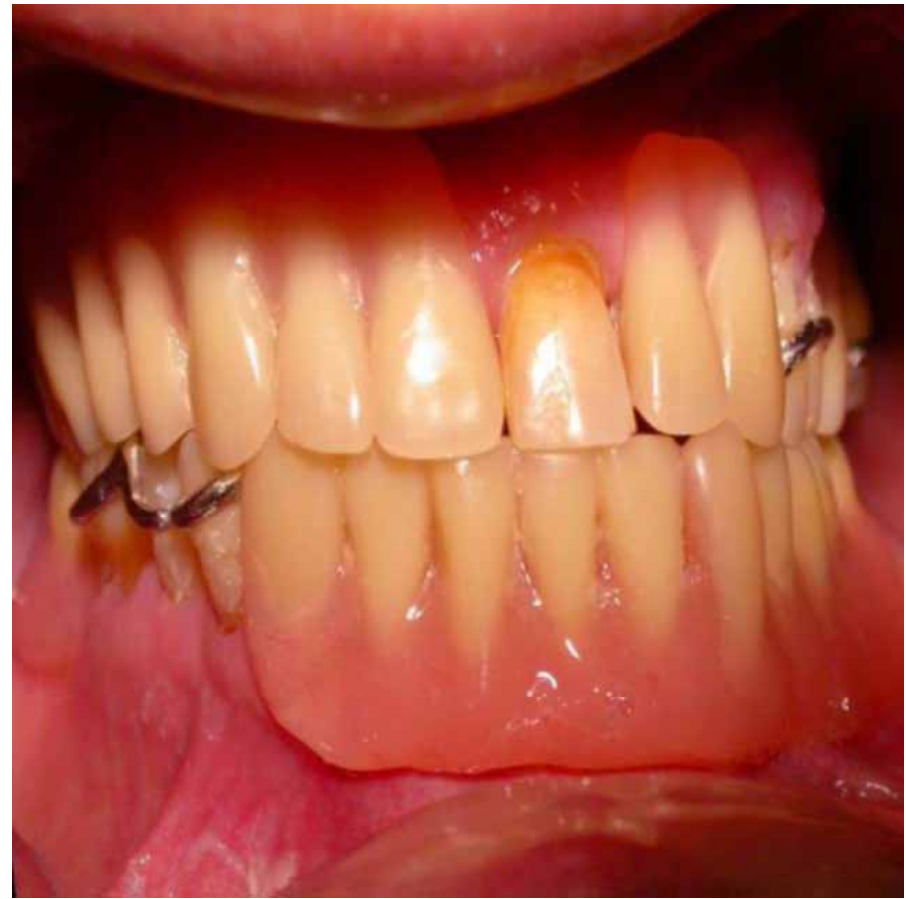



BEFOR



AFTER





THANK YOU

ANY

QUESTION

