



491 case presentation

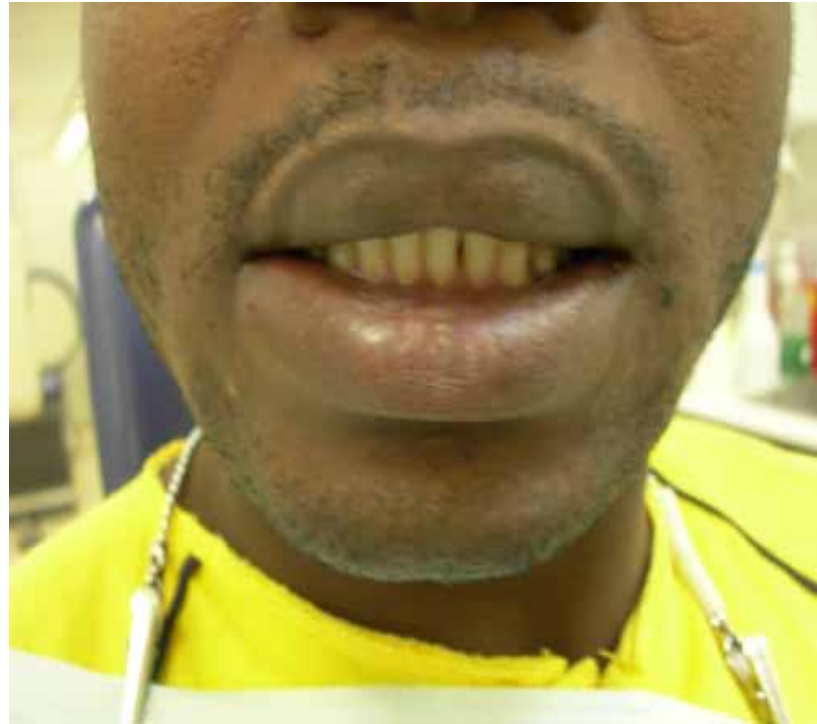Supervised by :dr.samer eljtaliy

Personal data

- Patient age: 26 years
- Gender: Male
- Nationality: African
- Level of education :uneducated

Chief complaint

- Long standing swelling under the upper lip
- Discolored anterior teeth



History of chief complaint

- This swelling was raised after a direct trauma to the anterior part of the maxilla 8years ago

Dental history

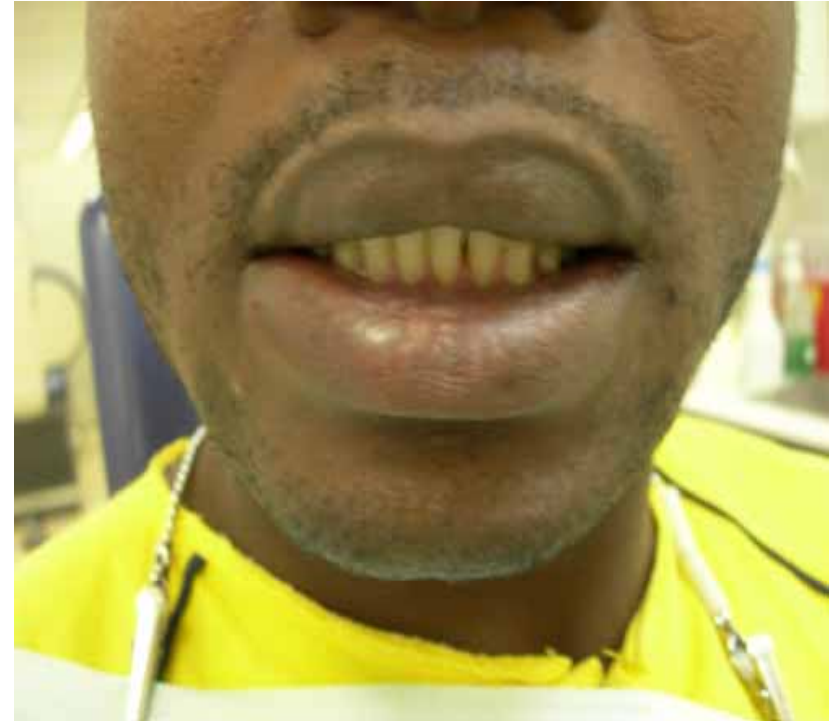- He didn't visit the dental clinic in his life
- He is not aware about any problem in his teeth

Medical history

- He didn't receive any treatment for the accident
- And he is not aware of any medical problem

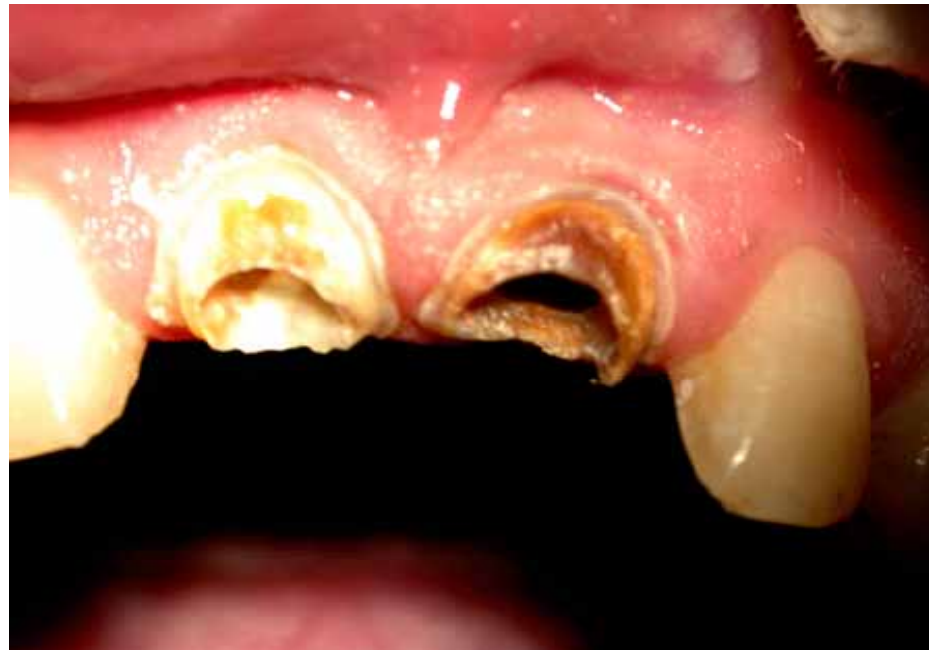Extra oral examination

- Multiple scars on the skin
- Dry lips with scars
- With no abnormalities detected in his lymph nodes and TMJ



Intra oral examination

- buccal mucosa fistula rising from tooth 21#
- Alveolar mucosa: racial pigmentation



➤ Gingiva:

Contour : Rolled gingival margin

Color : red to dark pink

enlarged inter dental papilla

Texture: loss of stippling

Bleeding index=60%

Plaque index =86%

- Generalized accumulation of plaque
- Slight calculus deposits on lower anterior
- Generalized plaque induce gingivitis

Occlusion

Class I molar relationship

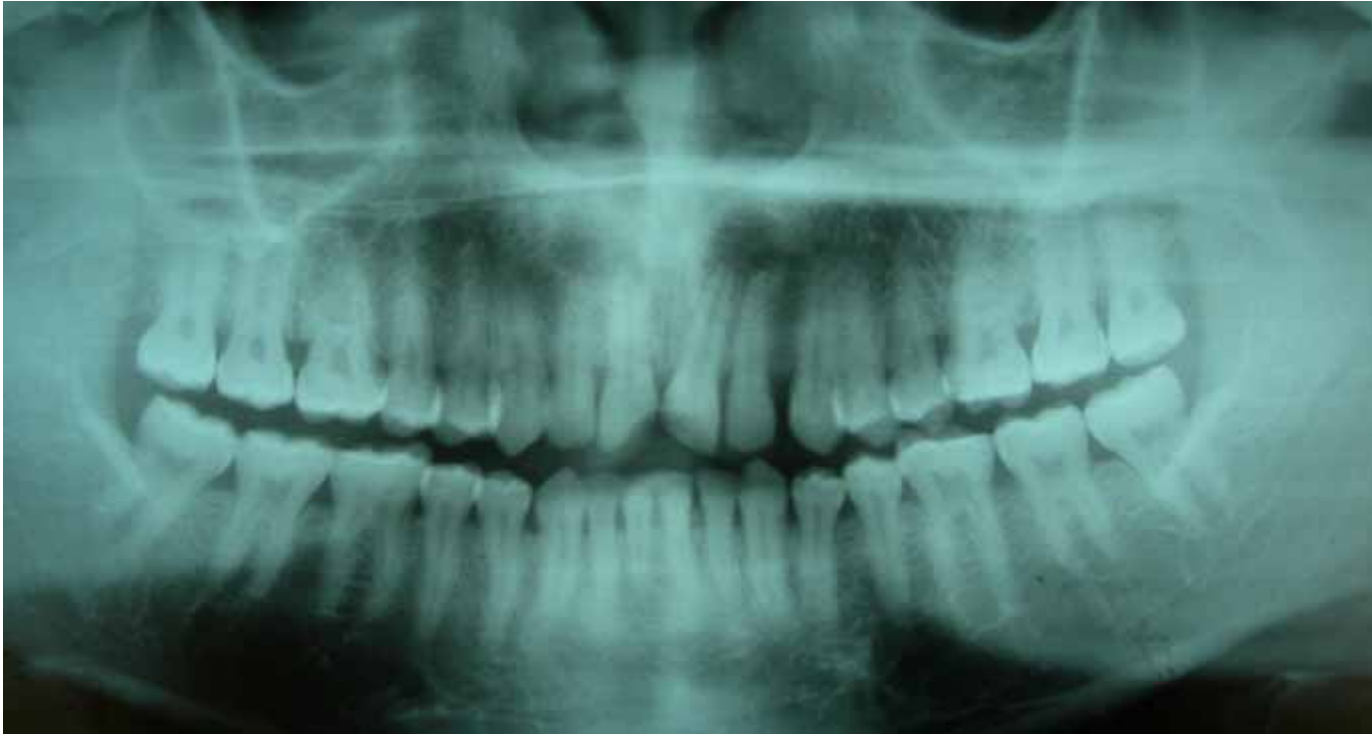Class I canine relationship

The patient has fair oral hygiene

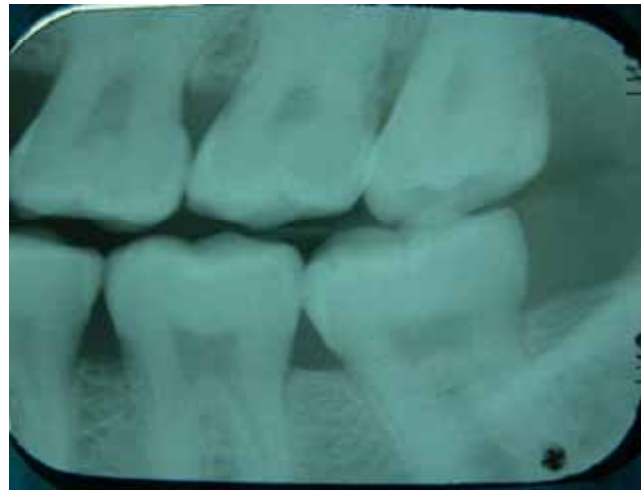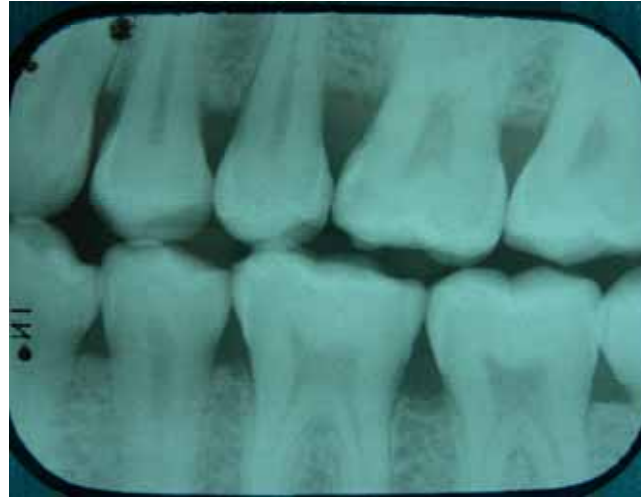Wear teeth due to attrition

patient practices heavy occlusion

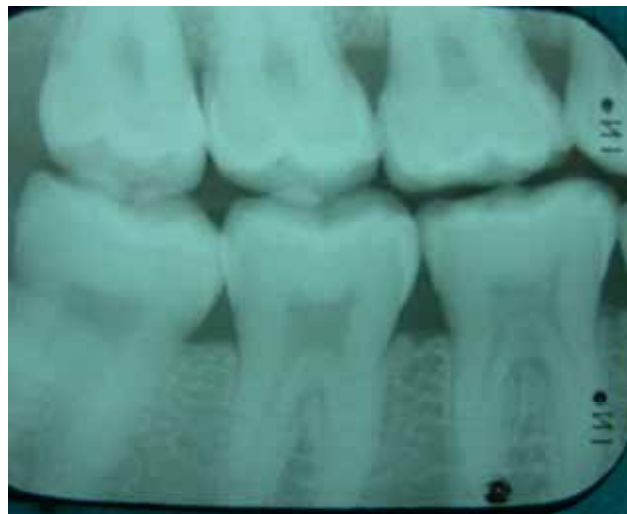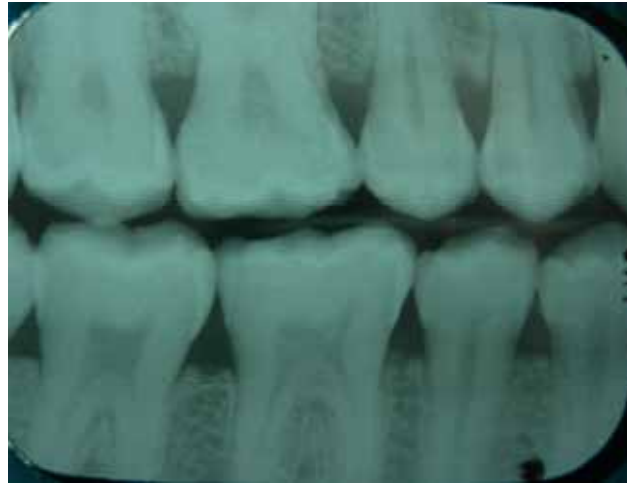
Radiographic examination



Radiographic examination



Radiographic examination



Radiographic examination



Supplementary examination

- Not tender to perception
- Small hard swelling above 21# on palpation
- No response to thermal and electrical pulp testing

etiology

Trauma

Diagnosis

- Endo-perio lesion related to tooth 21#
- Non vital teeth (11#,21#)
- Internal resorbtion 21#

Problem lists

- 11# necrotic pulp
- 21#necrotic pulp (internal resorption)
- 26#mesial proximal caries
- 35 incipient occlusal caries

Treatment option

- Fiber post
- Coated post
- All ceramic crown
- Metal ceramic crown

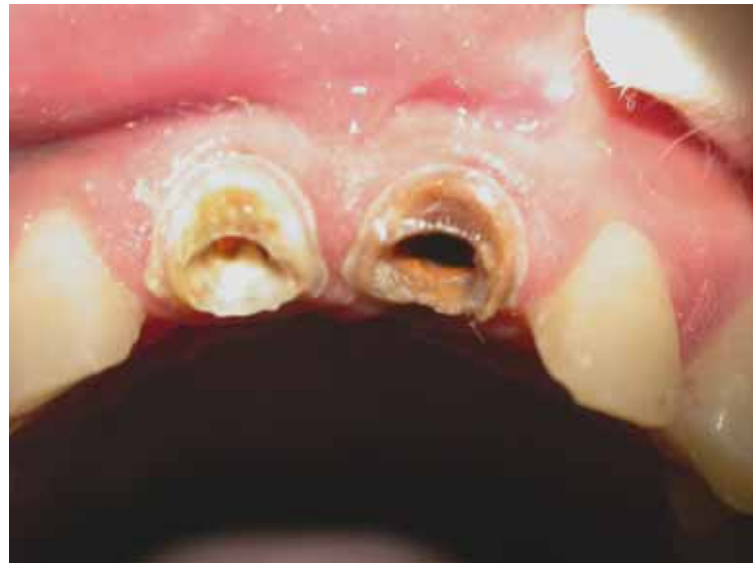Prognosis

Fair

Treatment planning

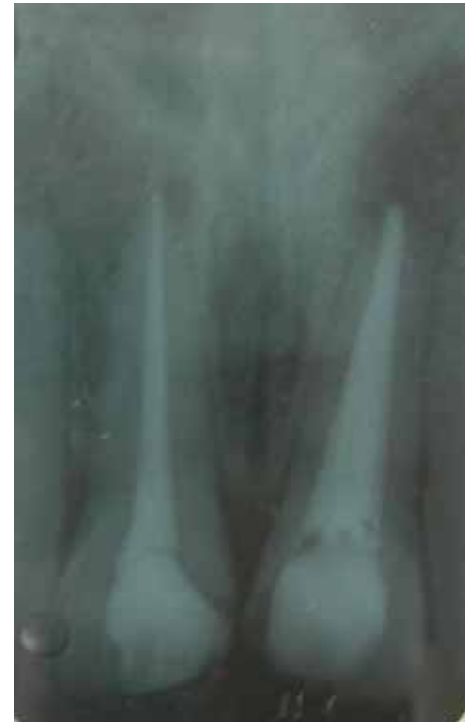I emergency phase

- Removal of caries on 11#,21#
- Access opening ,and drainage of priapical abscess ware no bus was found
- 24 hour dringe



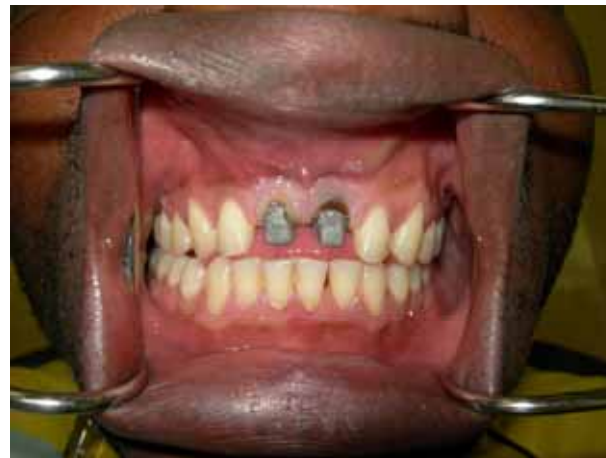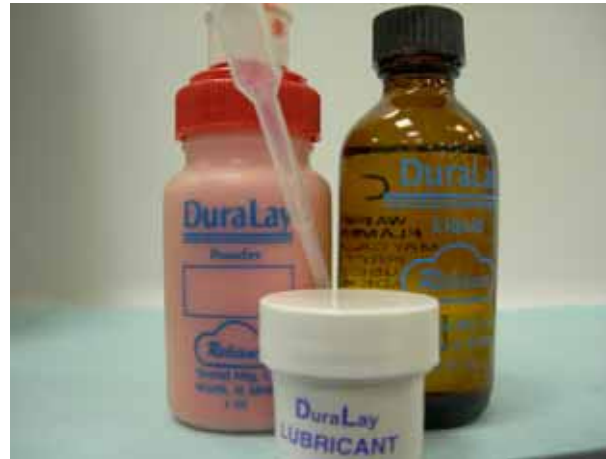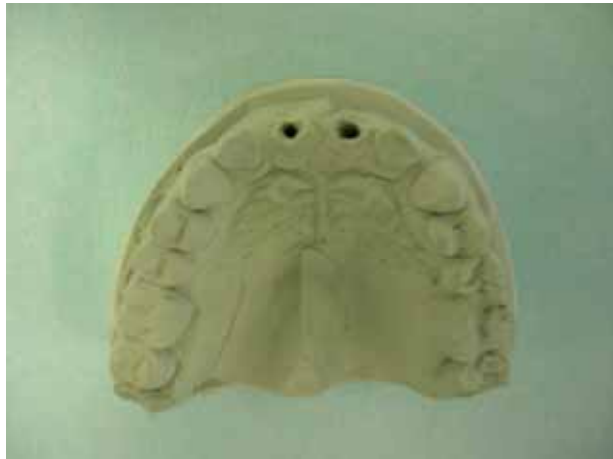II disease control

- Patient motivation & education
- Scaling & prophylaxis
- 11# RCT
- 21# RCT
- 26# MO class II amalgam
- 35# class I amalgam



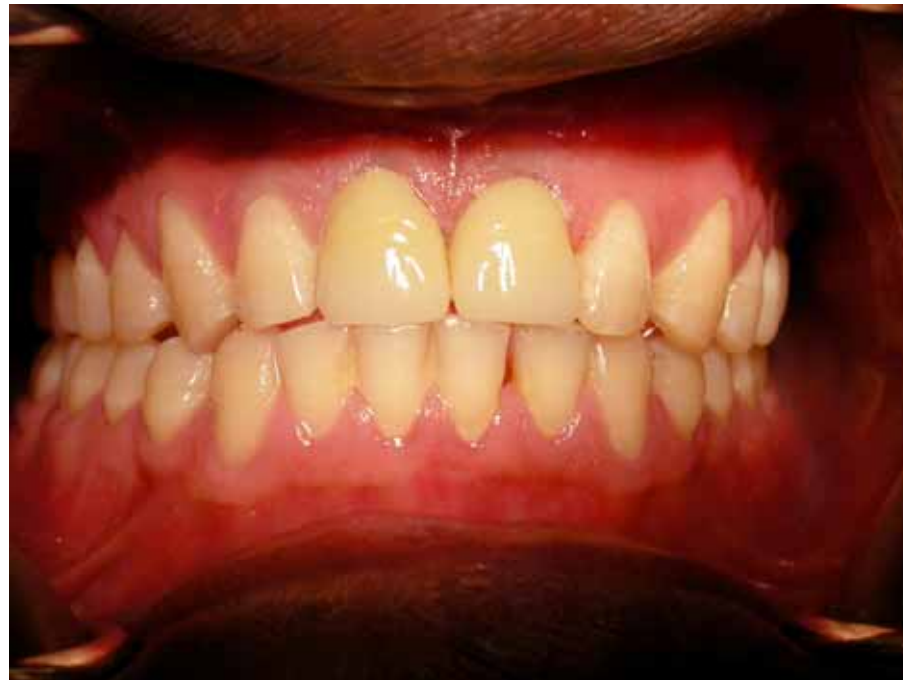III definitive treatment

- Post fabrication & cementation



III definitive treatment

- Final impression
- All ceramic crown fabrication
- Cementation



V maintenance phase

- Recall every 3month

Thank you