

Propionyl-L-carnitine prevents the progression of cisplatin-induced cardiomyopathy in a carnitine-depleted rat model

Abdulhakeem A. Al-Majed, Mohamed M. Sayed-Ahmed*, Abdulaziz A. Al-Yahya, Abdulaziz M. Aleisa, Salim S. Al-Rejaie, Othman A. Al-Shabanah

Department of Pharmacology, College of Pharmacy, King Saud University, P.O. Box 2457, Riyadh 11451, Saudi Arabia

Accepted 16 December 2005

Abstract

This study has been initiated to investigate whether endogenous carnitine depletion and/or carnitine deficiency is a risk factor during development of cisplatin (CDDP)-induced cardiomyopathy and if so, whether carnitine supplementation by propionyl-L-carnitine (PLC) could offer protection against this toxicity. To achieve the ultimate goal of this study, a total of 60 adult male Wistar albino rats were divided into six groups. The first three groups were injected intraperitoneally with normal saline, PLC (500 mg kg⁻¹), and D-carnitine (500 mg kg⁻¹) respectively, for 10 successive days. The 4th, 5th, and 6th groups were injected intraperitoneally with the same doses of normal saline, PLC and D-carnitine, respectively, for 5 successive days before and after a single dose of CDDP (7 mg kg⁻¹). On day 6 after CDDP treatment, animals were sacrificed, serum as well as hearts were isolated and analyzed. CDDP resulted in a significant increase in serum creatine phosphokinase isoenzyme (CK-MB) and lactate dehydrogenase (LDH), thiobarbituric acid reactive substances (TBARS) and total nitrate/nitrite (NO(x)) and a significant decrease in reduced glutathione (GSH), total carnitine, and adenosine triphosphate (ATP) content in cardiac tissues. In the carnitine-depleted rat model, CDDP induced dramatic increase in serum cardiomyopathy enzymatic indices, CK-MB and LDH, as well as progressive reduction in total carnitine and ATP content in cardiac tissue. Interestingly, PLC supplementation resulted in a complete reversal of the increase in cardiac enzymes, TBARS and NO_x, and the decrease in total carnitine, GSH and ATP, induced by CDDP, to the control values. Moreover, histopathological examination of cardiac tissues confirmed the biochemical data, where PLC prevents CDDP-induced cardiac degenerative changes while D-carnitine aggravated CDDP-induced cardiac tissue damage. In conclusion, data from this study suggest for the first time that carnitine deficiency and oxidative stress are risk factors and should be viewed as mechanisms during development of CDDP-related cardiomyopathy and that carnitine supplementation, using PLC, prevents the progression of CDDP-induced cardiotoxicity.

© 2005 Elsevier Ltd. All rights reserved.

Keywords: Cisplatin; Carnitine deficiency; Cardiomyopathy; D-carnitine; Propionyl-L-carnitine

1. Introduction

Cisplatin, *cis*-diamminedichloroplatinum II (CDDP), is an inorganic platinum compound with a broad-spectrum antineoplastic activity against various types of animal and human tumours [1]. Unfortunately, the optimal usefulness of CDDP as an important anticancer drug is usually limited secondary to its dose related nephrotoxicity [2,3]. It is well known that CDDP-induced nephrotoxicity is the most important dose-limiting factor in cancer chemotherapy [2,3].

Earlier studies have reported that CDDP therapy is usually associated with cardiotoxicity [4,5]. Cardiac events, reported in many case reports, may include electrocardiographic changes, arrhythmias, myocarditis, cardiomyopathy and congestive heart failure [6–8]. CDDP-induced cardiotoxicity was reported to be due to its disposition in the sinoatrial-node area, which may lead to bradycardia [9]. Combinations of CDDP with other anticancer drugs as methotrexate, 5-fluorouracil, bleomycin and doxorubicin are associated with lethal cardiomyopathy [10–13].

CDDP is a well-known renal tubular toxin, leading to increased excretion of a number of vital endogenous substances including L-carnitine [14,15]. Under normal physiological conditions, L-carnitine is highly conserved since 90% of the filtered L-carnitine is reabsorbed at the proximal tubular level [16]. It has been reported that CDDP inhibited carnitine reabsorption

* Corresponding author. Tel.: +966 506065734; fax: +966 1 467 7200.
E-mail address: mmsayedahmed@hotmail.com (M.M. Sayed-Ahmed).

with the consequent increase in urinary excretion of carnitine that represents an early marker of CDDP-induced nephrotoxicity [15]. Recent study in our laboratory have demonstrated the progression of CDDP-induced nephrotoxicity under condition of carnitine deficiency and that carnitine supplementation could protect against this toxicity [17].

However, the effects of CDDP on the cardiac function under condition of carnitine depletion and the role of carnitine in CDDP-related cardiomyopathy are not studied yet. Therefore, the present study have selected the natural short chain derivative of L-carnitine, Propionyl-L-carnitine (PLC), which proved efficacy in treatment of many forms of cardiomyopathies and have several therapeutic advantages over L-carnitine or acetyl-L-carnitine. First, PLC has a higher transport rate into cardiac myocytes than L-carnitine, thus increasing myocardial carnitine content and substrates oxidation rates [18–20]. Second, PLC has higher affinity for muscular carnitine transferase, thus PLC is highly specific to cardiac and skeletal muscles [18,21]. Third, PLC stimulates with a better efficiency of the krebs cycle by providing it with a very easily usable substrate, propionate, which is rapidly transformed into succinate without energy consumption (anaplerotic pathway) [18,20]. Furthermore, PLC suppresses the formation of hydroxyl radicals, thus acting as a free radical scavenger [22]. Finally, due to the particular structure of the molecule with a long lateral tail, PLC has a specific pharmacological action independently of its effect on metabolism resulting in peripheral dilatation and positive inotropism [23].

Up to date, in the literature, we could not find any study investigating the effects of CDDP on the myocardium under condition of endogenous carnitine depletion and the role of L-carnitine supplementation in CDDP-induced cardiomyopathy. Therefore, this study has been initiated to investigate whether endogenous carnitine depletion and/or carnitine deficiency is a risk factor and should be viewed as a mechanism during development of CDDP-induced cardiomyopathy and if so, whether carnitine supplementation by PLC could offer protection against this toxicity.

2. Materials and methods

2.1. Animals

Adult male Wistar albino rats, weighing 230–250 g, were obtained from the Animal Care Center, College of Pharmacy, King Saud University, Riyadh, Saudi Arabia and were housed in metabolic cages under controlled environmental conditions (25 °C and a 12 h light/dark cycle). Animals had free access to pulverized standard rat pellet food and tap water unless otherwise indicated. The protocol of this study has been approved by Research Ethics Committee of College of Pharmacy, King Saud University (KSU), Riyadh, Kingdom Saudi Arabia (KSA).

2.2. Materials

Cisplatin (cisplatyl 50 mg, Laboratoire Roger Bellon, France) was purchased from King Khalid University Hospital drug

store, KSU, KSA. PLC and D-carnitine (products of Sigma-Tau Pharmaceuticals, Pomezia, Italy) were kindly supplied by Dr. Menotti Calvani, Sigma-Tau, Pomezia, Italy. All other chemicals used were of the highest analytical grade.

2.3. Carnitine-depleted model

Experimental animal models of carnitine deficiency were developed by Paulson and Shug [24], Whitmer [25]; and Tsoko et al. [26]. In the current study, carnitine deficiency was induced in rats by daily intraperitoneal (i.p.) injection of D-carnitine, the inactive isomer, at dose level of 500 mg kg⁻¹ for 10 successive days according to Sayed-Ahmed et al. [17]. Depletion of L-carnitine by D-carnitine occurs via an exchange of the D- and L-isomers across the cell membrane where the intracellular L-carnitine was shown to exchange with the extracellular D-carnitine. Moreover, D-carnitine possesses an inhibitory effect upon carnitine transferase enzymes and competitive inhibitory effect upon L-carnitine uptake [24–26].

2.4. Experimental design

A total of 60 adult male Wistar albino rats were used and divided at random into 6 groups of 10 animals each. The first three groups were injected with normal saline (0.5 ml 200 gm⁻¹ body weight, i.p.), PLC (500 mg kg⁻¹, i.p.), and D-carnitine (500 mg kg⁻¹, i.p.) respectively, for 10 successive days. The 4th, 5th, and 6th groups were injected with the same doses of normal saline, PLC and D-carnitine, respectively for 5 successive days before a single dose of CDDP (7 mg kg⁻¹, i.p.) and continued for 5 successive days after CDDP treatment. On day 6 after CDDP administration, animals were anesthetized with ether, and blood samples were obtained by heart puncture. Serum was separated for measurement of lactate dehydrogenase (LDH), creatine phosphokinase iso-enzyme (CK-MB) and total carnitine. Animals were then sacrificed by decapitation after exposure to ether in a dessicator kept in a well-functioning hood and heart was quickly excised, washed with saline, blotted with a piece of filter paper and homogenized, in normal saline or 6% perchloric acid as indicated in the procedures of measurement of each parameter, using a Branson sonifier (250, VWR Scientific, Danbury, Conn., USA). Heart specimens from each group were removed to be examined histopathologically, they were fixed in 10% neutral buffered formalin, sectioned at 3 μm and stained with Hematoxylin and Eosin (H&E) stain for light microscopic examination to evaluate the following parameters: (1) muscle fiber damage; (2) cytoplasmic damage; (3) hemorrhage. The marking system used was according to the following scale: (A) no degenerative change: 0+; (B) mild degenerative change: 1+; (C) moderate degenerative change: 2+; (D) severe degenerative change: 3+.

2.5. Assessment of cardiac enzymes

Serum activities of LDH and CK-MB were determined according to the methods of Buhl and Jackson [27] and Wu and Bowers [28], respectively.

2.6. Determination of reduced glutathione and lipid peroxidation in cardiac tissues

The tissue levels of the acid soluble thiols, mainly GSH, were assayed spectrophotometrically at 412 nm, according to the method of Ellman [29], using a Shimadzu (Tokyo, Japan) spectrophotometer. The contents of GSH were expressed as $\mu\text{mol g}^{-1}$ wet tissue. The degree of lipid peroxidation in cardiac tissues was determined by measuring thiobarbituric acid reactive substances (TBARS) in the supernatant tissue from homogenate [30]. The homogenates were centrifuged at 3500 rpm and supernatant was collected and used for the estimation of TBARS. The absorbance was measured spectrophotometrically at 532 nm and the concentrations were expressed as nmol TBARS g^{-1} wet tissue.

2.7. Determination of total nitrate/nitrite ($\text{NO}(x)$) concentrations in cardiac tissues

Total nitrate/nitrite ($\text{NO}(x)$) was measured as stable end product, nitrite, according to the method of Miranda et al. [31]. The assay is based on the reduction of nitrate by vanadium trichloride combined with detection by the acidic griess reaction. The diazotization of sulfanilic acid with nitrite at acidic pH and subsequent coupling with *N*-(10 naphthyl)-ethylenediamine produced an intensely colored product that is measured spectrophotometrically at 540 nm. The levels of NO_x were expressed as $\mu\text{mol g}^{-1}$ wet tissue.

2.8. Determination of total carnitine levels in serum and cardiac tissues

Heart homogenate was prepared in ice-cold 6% perchloric acid and centrifuged at $8000 \times g$ for 10 min. The supernatant was used for the estimation of free carnitine, whereas the remaining pellet was used for determination of long chain acyl carnitine after hydrolysis in 1 M KOH at 65°C for 1 h according to Alhomida [32]. Carnitine was determined in serum and the so-obtained tissue samples using HPLC after precolumn derivatization with L-aminoanthracene as previously described by Longo et al. [33]. The mobile phase was prepared by mixing 700 ml of 0.1 M ammonium acetate pH 3.5 with 300 ml of acetonitrile. Chromatographic separation was performed at a flow rate of 1.3 ml min^{-1} , using a Kromasil C18, $250 \times 4.6 \text{ mm i.d. } 5 \mu\text{m}$ column (Saulentechnik Knayer, Berlin, Germany). The excitation and emission wavelengths of the spectrofluorimeter were 248 and 418 nm, respectively.

2.9. Determination of adenosine triphosphate in cardiac tissues

Adenosine triphosphate was determined in heart tissues using HPLC according to Botker et al. [34]. In brief, heart tissue was homogenized in ice-cold 6% perchloric acid, centrifuged at 1000 rpm for 15 min at 0.5°C , and the supernatant fluid was injected into HPLC after neutralization to pH 6–7. Chromatographic separation was performed at a flow rate of 1.2 ml min^{-1} ,

using ODS-Hypersil, $150 \times 4.6 \text{ mm i.d.}, 5 \mu\text{m}$ column (Supelco SA, Gland, Switzerland) and 75 mM ammonium dihydrogen phosphate as mobile phase. The peak elution was followed at 254 nm.

2.10. Statistical analysis

Differences between obtained values (mean \pm S.E.M., $n=10$) were carried out by one way analysis of variance (ANOVA) followed by the Tukey–Kramer multiple comparison test. A p -value of 0.05 or less was taken as a criterion for a statistically significant difference.

3. Results

Fig. 1 shows the effects of CDDP on serum cardiac enzymes, LDH (A) and CK-MB (B), in PLC-supplemented and carnitine-

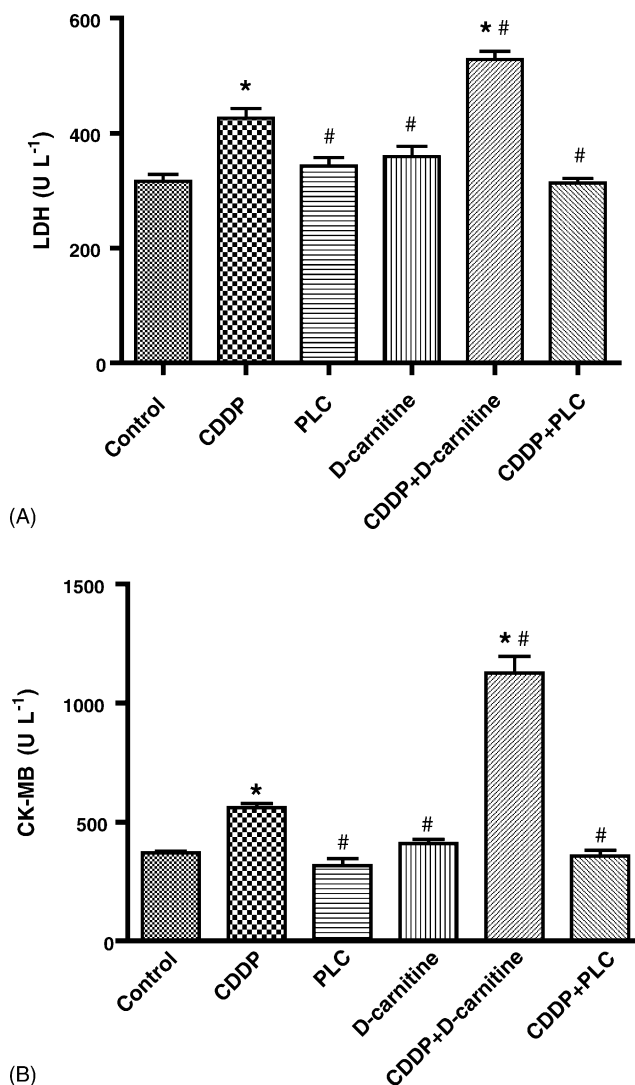
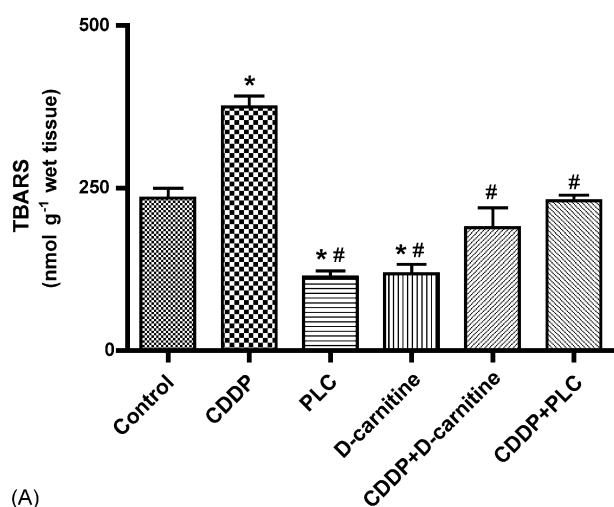
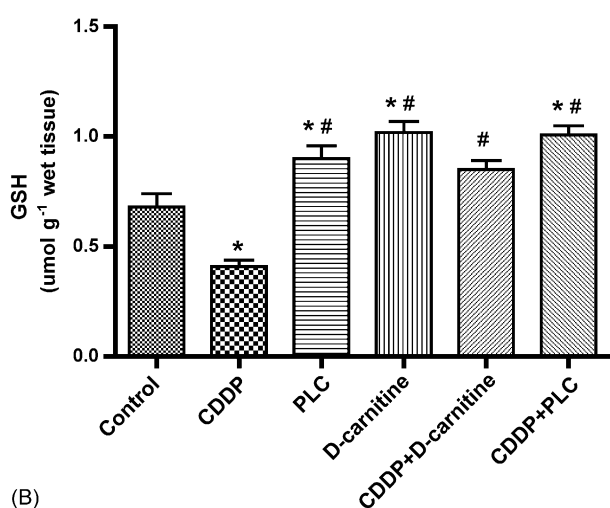


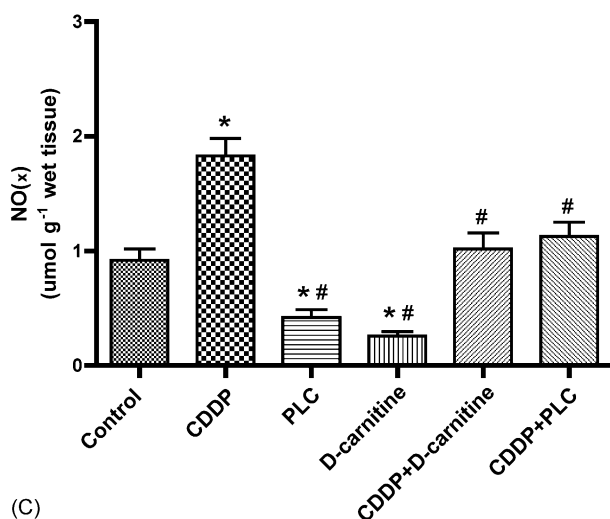
Fig. 1. Effect of CDDP, PLC, D-carnitine and their combination on serum cardiomyopathy enzymatic indices, LDH (A) and CK-MB (B) in rats. Data are presented as mean \pm S.E.M. ($n=10$). (*) and (#) indicate significant change from control and CDDP, respectively, at $p < 0.05$ using ANOVA followed by Tukey–Kramer as a post ANOVA test.



(A)



(B)

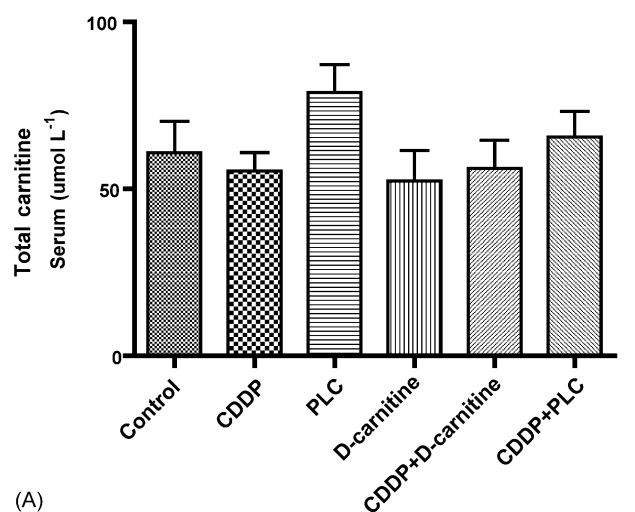


(C)

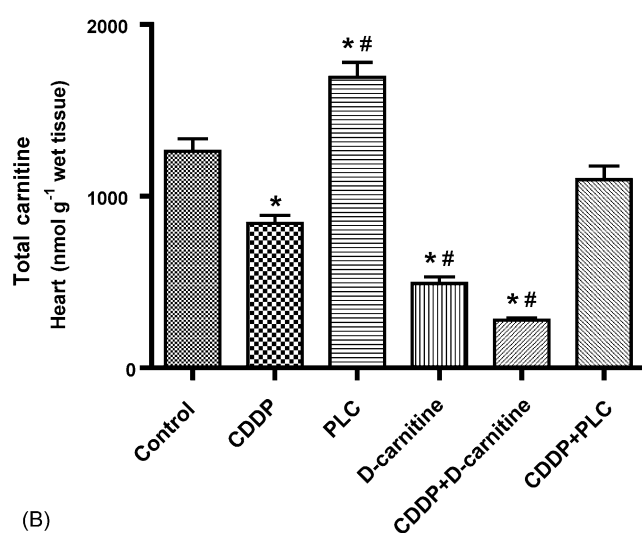
Fig. 2. Effect of CDDP, PLC, D-carnitine and their combination on the levels of thiobarbituric acid reactive substances (A), reduced glutathione (B), and total nitrate/nitrite (C) in rat cardiac tissues. Data are presented as mean \pm S.E.M. ($n = 10$). (*) and (#) indicate significant change from control and CDDP, respectively, at $p < 0.05$ using ANOVA followed by Tukey–Kramer as a post ANOVA test.

depleted rats. Six days after treatment, a single dose of CDDP (7 mg kg^{-1}) resulted in a significant 35 and 51% increase in serum LDH and CK-MB, respectively, as compared to the control group. Administration of either PLC or D-carnitine alone for 10 successive days showed non-significant change. Combined treatment with CDDP and D-carnitine resulted in a significant 24 and 100% increase in serum LDH and CK-MB, respectively, as compared to CDDP alone. Interestingly, administration of PLC in combination with CDDP resulted in a complete reversal of CDDP-induced increase in serum LDH and CK-MB to the control values.

Fig. 2 shows the effects of CDDP, PLC, D-carnitine and their combination on oxidative stress biomarkers namely TBARS (A), GSH (B), and NO_x (C) in cardiac tissues. CDDP resulted in a significant 40% decrease in GSH and a significant 60 and 99% increase in TBARS and NO_x , respectively, as compared to



(A)



(B)

Fig. 3. Effect of CDDP, PLC, D-carnitine and their combination on total carnitine levels in serum (A) and cardiac tissues (B) in rats. Data are presented as mean \pm S.E.M. ($n = 10$). (*) and (#) indicate significant change from control and CDDP, respectively, at $p < 0.05$ using ANOVA followed by Tukey–Kramer as a post ANOVA test.

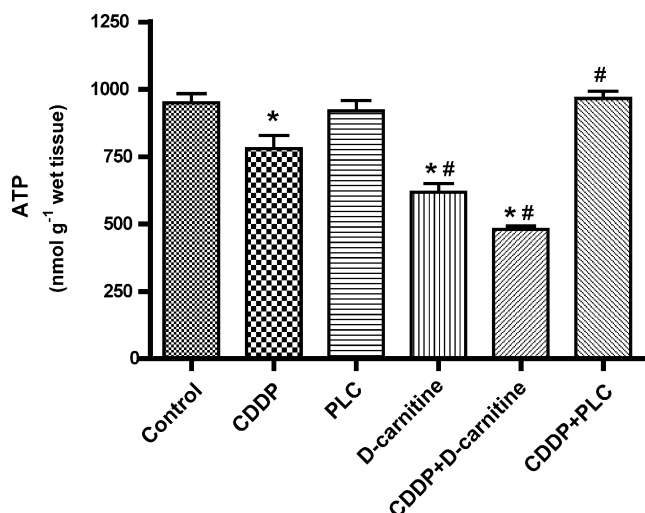


Fig. 4. Effect of CDDP, PLC, D-carnitine and their combination on adenosine triphosphate level in rat cardiac tissues. Data are presented as mean \pm S.E.M. ($n = 10$). (*) and (#) indicate significant change from control and CDDP, respectively, at $p < 0.05$ using ANOVA followed by Tukey–Kramer as a post ANOVA test.

the control group. Treatment with PLC for 10 successive days showed a significant 32% increase in GSH and a significant 52 and 54% decrease in TBARS and NO_x , respectively. Similarly, D-carnitine alone induced a significant 50% increase in GSH

and a significant 50 and 72% decrease in TBARS and NO_x , respectively. Administration of either PLC or D-carnitine for 5 days before and after a single dose of CDDP, resulted in a complete reversal of CDDP-induced decrease in GSH and increase in TBARS and NO_x levels in heart tissues to the control values.

Fig. 3 shows the effects of CDDP, PLC, D-carnitine and their combination on total carnitine levels in serum (A) and cardiac tissues (B). Treatment with CDDP resulted in a significant 33% decrease in total carnitine level in heart tissues, whereas D-carnitine resulted in a significant 61% decrease as compared to the control group. Combination of D-carnitine with a single dose of CDDP induced a significant 44, 67 and 78% decrease of total carnitine content in cardiac tissues compared to the results of D-carnitine, CDDP and control, respectively. Administration of PLC for 5 days before and after a single dose of CDDP resulted in a complete reversal of cisplatin-induced decrease in total carnitine content in cardiac tissues to the control values. Worth mentioning is that none of these treatments showed any significant changes in total carnitine levels in serum.

The effects of CDDP on ATP level in cardiac tissues from carnitine-depleted and supplemented rats are shown in Fig. 4. CDDP resulted in a significant 18% decrease of ATP level in cardiac tissues relative to the values of the control group. Administration of D-carnitine for 10 successive days showed 35% decrease, whereas PLC resulted in non-significant change, as

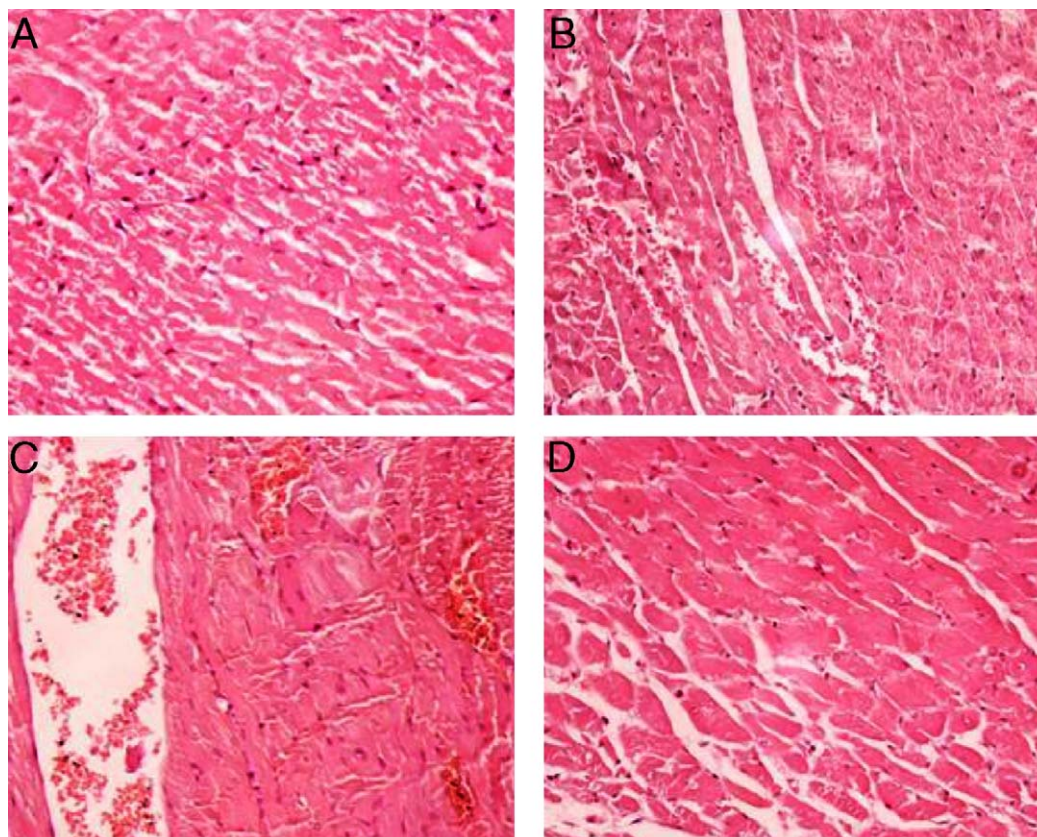


Fig. 5. A photomicrographs of the heart specimen stained with hematoxylin and eosin (H&E X 200). (A) Heart from control rat showing normal bundles of muscle fibers and homogenous acidophilic cytoplasm. (B) Heart of rat treated with CDDP showing vacuolated cytoplasm of many muscle cells, blood vessels are engorged with blood. (C) Heart of rat treated with CDDP and D-carnitine showing extensive vacuolation of the cytoplasm of cardiac muscle fibers, blood cells in-between the bundles indicate massive bleeding. (D) Heart of rat treated with CDDP and PLC in which the cardiac muscle fibers appear as control with minimal sign of toxicity in small restricted foci in the vicinity of normal muscle fibers.

compared to the control group. In carnitine-depleted rats, CDDP resulted in a significant 50 and 38% decrease in ATP level as compared to the control and CDDP groups, respectively. Conversely, administration of PLC for 5 days before and after a single dose of CDDP resulted in a complete reversal of CDDP-induced decrease in ATP level in cardiac tissues to the control values.

Fig. 5 shows the histopathological changes in cardiac tissues induced by CDDP in carnitine-depleted and supplemented rats. Sections from cardiac tissues of control rats showed bundles of normal muscle fibers and the cytoplasm appears homogeneous acidophilic with central nucleus (Fig. 5A). On the other hand, animals treated with CDDP alone showed degenerative changes, vacuolated cytoplasm of many muscle cells and blood vessels are engorged with blood (score 2, Fig. 5B). This tissue injury was aggravated in cardiac sections of rats treated with CDDP plus D-carnitine, where they showed massive degenerative changes. The muscle fibers appeared markedly vacuolated in wide areas, beside the bleeding where the blood cells were scattered in-between bundles of cardiac muscle (score 3, Fig. 5C). Interestingly, heart specimens from rats treated with CDDP and PLC (Fig. 5D) revealed minimal degenerative changes in which the cardiac muscle fibers appear as control with minimal sign of toxicity in small restricted foci in the vicinity of normal muscle fibers.

4. Discussion

It has been reported that increased urinary excretion of L-carnitine is an early marker in CDDP-induced nephrotoxicity [15]. Under such condition, CDDP may induce a secondary carnitine deficiency that might enhance CDDP-induced other organs toxicity. Recent study in our laboratory have demonstrated the progression of CDDP-induced nephrotoxicity under condition of carnitine deficiency [17]. However, the effects of CDDP on the heart under condition of carnitine depletion and the role of carnitine in CDDP-induced cardiotoxicity are not studied yet. This study has been initiated to investigate whether endogenous carnitine depletion and/or carnitine deficiency is a risk factor during development of CDDP-induced cardiomyopathy and if so, whether carnitine supplementation by PLC could offer protection against this toxicity.

Data presented here demonstrate that CDDP increased serum cardiotoxicity enzymatic indices (LDH and CK-MB) and caused severe histopathological lesions in cardiac tissues (Fig. 5B). This effect could be a secondary event following CDDP-induced lipid peroxidation of cardiac membranes with the consequent increase in the leakage of LDH and CK-MB from cardiac myocytes. Increased release of LDH by CDDP has been previously reported [35]. Fascinatingly, PLC prevented the increase in LDH and CK-MB induced by CDDP, suggesting that PLC may have potential protective effect against CDDP-induced cardiac damage. This effect could be due to membrane stabilization by the L-carnitine portion of PLC with the consequent decrease in release of cardiac enzymes. Indeed, the interaction of L-carnitine with sarcolemmal phospholipids and mitochondrial membranes has been previously reported [36]. On the other hand, administra-

tion of CDDP to carnitine-depleted rats produced a progressive increase in the activities of LDH and CK-MB as well as massive bleeding and degenerative changes in cardiac tissues (Fig. 5C).

Data from this study revealed that CDDP significantly increased NO_x and TBARS and decreased GSH in cardiac tissues, suggesting that oxidative stress induced by CDDP may play a role in CDDP-induced cardiac damage. It seems that the heart is the most susceptible organ to oxidative stress since cardiac tissues has very low level of antioxidant enzymes such as catalase and superoxide dismutase [37]. However, no previous studies are available on the role of oxidative stress exerted by CDDP in cardiac-induced damage. Recent studies have reported that beside kidney, CDDP-induced oxidative stress damage to liver and lens tissues in rats secondary to the formation of both reactive oxygen and nitrogen species [38,39]. Moreover, Lee et al. [40] reported that the degeneration of the auditory system of mice by CDDP was due to CDDP-induced increase in hydroxyl radical, a marker for lipid peroxidation, and nitrotyrosine, a marker for protein peroxidation. The contribution of NO_x in CDDP-induced cytotoxicity and organs toxicity has been previously reported [41–43]. Nitric oxide is known to inhibit DNA repair proteins, thereby inhibiting the ability of the cell to repair damaged DNA [42]. Previous studies have demonstrated that increased NO_x concentrations after CDDP was a secondary event following the increase in the inducible nitric oxide synthase [43–45].

In the current study, both PLC and D-carnitine prevented the increase in TBARS and NO_x and the decrease in GSH induced by CDDP in cardiac tissues, suggesting that both compounds have (and/or induce) antioxidant effect. Previous studies have demonstrated that both the D- and L-forms of carnitine and its short chain derivatives have similar non-enzymatic free radical scavenging activity [17,46,47]. Although, both PLC and D-carnitine have similar antioxidant activity, in our study, PLC prevented the progression of CDDP-induced cardiomyopathy and D-carnitine aggravated this toxicity. Therefore, one can anticipate that oxidative stress plays an important role but not the only mechanism by which CDDP-induced its cardiotoxicity.

Data presented here showed that CDDP significantly decreased total carnitine in cardiac tissues. It seems that our results are unique since no available data about the effect of carnitine deficiency or carnitine supplementation on cardiac tissues of rats treated with CDDP. Since it has been reported that renal proximal tubules are severely damaged by CDDP [48], therefore, impaired endogenous synthesis and inhibition of tubular reabsorption of carnitine is the most likely explanation for its decrease after CDDP administration. It was reported that treatment with CDDP is associated with a tenfold increase in renal carnitine excretion, most likely due to inhibition of carnitine reabsorption by the proximal tubule of the nephron [15,49].

Under our experimental conditions, D-carnitine significantly decreased the level of carnitine in cardiac tissues whereas plasma levels were not changed. Our results are in good agreement with those previously reported [24,25]. Although, D-carnitine alone decreased cardiac carnitine content more than CDDP, only CDDP increased LDH and CK-MB. This argues against carnitine deficiency as a risk factor in CDDP-induced cardiac damage.

A possible explanation for this is that D-carnitine, via its anti-lipid peroxidation, causes stabilization of cardiac membranes and prevents the leakage of cardiac enzymes, whereas CDDP, via increasing lipid peroxidation, causes irreversible modification of membrane structures and functions with the consequent leakage of cardiac enzymes.

The marked decrease in total carnitine level in the heart by CDDP in the carnitine-depleted rat model (Fig. 3B), suggests that D-carnitine and CDDP depletes L-carnitine by different mechanisms. D-carnitine-induced carnitine deficiency was reported to be due to the inhibition of carnitine transferase enzyme, inhibition of carnitine transport and competitive inhibition of L-carnitine uptake or exchange with extracellular D-carnitine [24–26]. On the other hand, secondary carnitine deficiency induced by the nephrotoxic effects of CDDP may be attributed to the inhibition of carnitine reabsorption by the proximal tubules of the nephron. Since kidney is the major site for endogenous carnitine biosynthesis in rats, therefore, kidney damage induced by CDDP may lead to inhibition of carnitine synthesis and consequently leading to carnitine deficiency [15,49]. Moreover, hyponatraemia induced by CDDP might hinder the action of sodium-dependent carnitine transporter, which may worsen the condition. This marked decrease (78%) of carnitine level in cardiac tissue after combined treatment of CDDP and D-carnitine was parallel to the marked increase in LDH and CK-MB and the massive degenerative changes in cardiac tissues, which may point to the possible consideration of carnitine deficiency as a risk factor in CDDP-induced cardiomyopathy. Most probably, D-carnitine via its depletion of L-carnitine, and CDDP partly through oxidative stress and partly due to carnitine depletion produced such myocardial damage. This aggravated cardiomyopathy could be explained on the basis of myocardial carnitine deficiency with subsequent impairment of fatty acid oxidation and ATP production. It is well known that L-carnitine is an essential cofactor for mitochondrial transport and oxidation of long chain fatty acids which are the preferred substrates for ATP production in normal, well-oxygenated adult myocardium [50]. Depletion of the heart from carnitine either by CDDP, D-carnitine and both would impair the beta-oxidation of long chain fatty acids with the consequent decrease in ATP production and heart contractile function. This was supported by the marked decrease of ATP levels in heart tissues observed in carnitine-depleted rats, which renders the cardiac cells vulnerable to damage by CDDP. On the other hand, carnitine supplementation by PLC prevented CDDP-induced decrease in ATP by replenishing the myocardium with adequate carnitine for its energy production. The animal model used in this study could reflect the clinical course of CDDP in cachectic patients with malignant tumours whom serum and urinary carnitine profile are altered and developed hypocarnitinaemia after repeated cycles of chemotherapies including CDDP [15,51].

In this study, the protective effect achieved by PLC against CDDP-induced cardiomyopathy is in good agreement with recent results from clinical pilot studies which have demonstrated that acetyl-L-carnitine (ALC) seems to be an effective and well-tolerated agent for the treatment of CDDP and paclitaxel-induced peripheral neuropathy [52,53]. Moreover, in an animal

models of CDDP and paclitaxel-induced neuropathy, recent studies have recommended ALC as a specific protective agent for chemotherapy-induced neuropathy without showing any interference with the antitumour activity of the drugs [54,55]. Worth mentioning is that L-carnitine, ALC and PLC do not interfere with the antitumour activity of anticancer drugs [55–57].

The progression of CDDP-induced cardiomyopathy observed in this study could be secondary to its major dose-limiting nephrotoxicity. This hypothesis is supported by the fact that secondary carnitine deficiency reported in patients with end-stage renal disease undergoing hemodialysis is associated with severe cardiovascular and neuromuscular disorders [58]. Our results are pioneer to studies that will be performed with carnitine and its short chain derivatives to protect from CDDP-induced cardiomyopathy. In conclusion, data from this study suggest for the first time that: (1) endogenous carnitine depletion and/or deficiency is a risk factor and should be viewed as a mechanism during development of CDDP-related cardiomyopathy; (2) oxidative stress plays an important role in CDDP-induced cardiomyopathy; (3) PLC prevents the progression of CDDP-induced cardiotoxicity. It would be worthwhile studying the effects of carnitine supplementation in CDDP-treated cancer patients, in the hope of reducing CDDP-induced nephrotoxicity, neurotoxicity, and cardiomyopathy.

Acknowledgements

The present work was supported by operating grant from Research Center, College of Pharmacy, King Saud University (CPRC154).

References

- [1] Loehrer PJ, Einhorn LH. Cisplatin. *Ann Intern Med* 1984;100:704–13.
- [2] Lieberthal W, Triaca V, Levine J. Mechanisms of death induced by cisplatin in proximal tubular epithelial cells: apoptosis vs necrosis. *Am J Physiol* 1996;240:F700–8.
- [3] Kintzel PE. Anticancer drug-induced kidney disorders. *Drug Saf* 2001;24:19–38.
- [4] Chvetzoff G, Bonotte B, Chauffert B. Anticancer chemotherapy. Prevention of toxicity. *Presse Med* 1998;27:2106–12.
- [5] Pai VB, Nahata MC. Cardiotoxicity of chemotherapeutic agents: incidence, treatment and prevention. *Drug Saf* 2000;22:263–302.
- [6] Berliner S, Rahima M, Sidi Y, Teplitsky Y, Zohar Y, Nussbaum B, et al. Acute coronary events following cisplatin-based chemotherapy. *Cancer Invest* 1990;8:583–6.
- [7] Tassinari D, Sartori S, Drudi G, Panzini I, Gianni L, Pasquini E, et al. Cardiac arrhythmias after cisplatin infusion: three case reports and a review of literature. *Ann Oncol* 1997;8:1263–7.
- [8] Shanmugasundaram S, Bharathithasan R, Elangovan S. 5-fluorouracil induced cardiotoxicity. *Indian Heart J* 2002;54:86–97.
- [9] Schlaeffer F, Tovi F, Leiberman A. Cisplatin-induced bradycardia. *Drug Intell Clin Pharm* 1983;17:899–901.
- [10] Garstin IW, Cooper GG, Hood JM. Arterial thrombosis after treatment with bleomycin and cisplatin. *BMJ* 1990;300:1018–21.
- [11] Tay HN, Yap HK, Murugasu B, Quah TC, Tay SH, Lim JW. Adriamycin-Induced cardiomyopathy aggravated by *cis*-platinum nephrotoxicity requiring dialysis. *J Singapore Paediatr Soc* 1990;32:125–8.
- [12] Igawa M, Kadena H, Ohkuchi T, Ueda M, Usui T, Matsuura H. Myocardial ischemia after treatment with methotrexate, etoposide and cisplatin. *Urol Int* 1993;50:98–100.

- [13] Cheriparambil KM, Vasireddy H, Kuruville A, Gambarin B, Makan M, Sauji BI. Acute reversible cardiomyopathy and thromboembolism after cisplatin and 5-fluorouracil chemotherapy, a case report. *Angiology* 2000;51:873–8.
- [14] Seguro AC, Shimizu MHM, Kudo LH. Renal concentration defect induced by cisplatin. *Am J Nephrol* 1989;9:59–65.
- [15] Heuberger W, Berardi S, Jacky E, Pey P, Krahenbuhl S. Increased urinary excretion of carnitine in patients treated with cisplatin. *Eur J Clin Pharmacol* 1998;54:503–8.
- [16] Bremer J. The role of carnitine in cell metabolism. In: De Simone C, Famularo G, editors. *Carnitine Today*. Texas, USA: Landes Bioscience, Austin; 1997. p. 1–37.
- [17] Sayed-Ahmed MM, Eissa MA, Kenawy S, Mostafa N, Calvani M, Osman AM. Progression of cisplatin-induced nephrotoxicity in a carnitine depleted rat model. *Chemotherapy* 2004;50:162–70.
- [18] Paulson DJ, Traxler J, Schmidt M, Noonan J, Shug AL. Protection of the ischemic myocardium by L-propionylcarnitine: effects on the recovery of cardiac output after ischemia and reperfusion, carnitine transport, and fatty acid oxidation. *Cardiovasc Res* 1986;20:536–41.
- [19] Lango R, Smolenski RT, Narkiewicz M, Suchozewska J, Iysiak-Szydowska W. Influence of L-carnitine and its derivatives on myocardial metabolism and function in ischemic heart disease and during cardiopulmonary bypass. *Cardiovasc Res* 2001;51(1):21–9.
- [20] Ferrari R, Merli E, Cicchitelli G, Mele D, Fucili A, Ceconi C. Therapeutic effects of L-carnitine and propionyl-L-carnitine on cardiovascular diseases: a review. *Ann NY Acad Sci* 2004;1033:79–91.
- [21] Siliprandi N, Di Lisa F, Pivetta A, Miotto G, Siliprandi D. Transport and function of L-carnitine and L-propionylcarnitine: relevance to some cardiomyopathies and cardiac ischemia. *Z Kardiol* 1987;76:34–40.
- [22] Mister N, Noris M, Szymczuk J, Azzollini N, Abbate M, Trochimowicz L, et al. Propionyl-L-carnitine prevents renal function deterioration due to ischemia/reperfusion. *Kidney Int* 2002;61:1064–78.
- [23] Cevese A, Schena F, Cerutti G. Short-term hemodynamic effects of intravenous propionyl-L-carnitine in anesthetized dogs. *Cardiovasc Drugs Ther* 1991;5:45–56.
- [24] Paulson DJ, Shug AL. Tissue specific depletion of L-carnitine in rat heart and skeletal muscle by D-carnitine. *Life Sci* 1981;28:2931–8.
- [25] Whitmer JT. L-carnitine treatment improves cardiac performance and restores high energy phosphate pools in cardiomyopathic syrian hamster. *Circ Res* 1987;61:396–408.
- [26] Tsoko M, Beau-Seigneur F, Greste J, Niot I, Demarquoy J, Biochot J, et al. Enhancement of activities relative to fatty acid oxidation in the liver of rats depleted of L-carnitine by D-carnitine and a γ -butyrobetaine hydroxylase inhibitor. *Biochem Pharmacol* 1995;49:1403–10.
- [27] Buhl SN, Jackson KY. Optimal conditions and comparison of lactate dehydrogenase catalysis of the lactate-to-pyruvate and pyruvate-to-lactate reactions in human serum at 25 30 and 37 degrees C. *Clin Chem* 1978;24:828–31.
- [28] Wu AHB, Bowers CN. Evaluation and comparison of immunoinhibition and immunoprecipitation methods for differentiating MB and BB from macro forms of creatine kinase isoenzymes in patients and healthy individuals. *Clin Chem* 1982;28:2017–21.
- [29] Ellman GL. Tissue sulfhydryl groups. *Arch Biochem Biophys* 1959;82:70–7.
- [30] Ohkawa H, Ohish N, Yagi K. Assay for lipid peroxides in animal tissues by thiobarbituric acid. *Anal Biochem* 1979;95:351–8.
- [31] Miranda KM, Espey MG, Wink DA. A rapid, simple spectrophotometric method for simultaneous detection of nitrate and nitrite. *Nitric Oxide: Biol Chem* 2001;5:62–71.
- [32] Alhomida AS. Study of the effects of theophylline-related changes in total, free short chain acyl and long-chain acyl carnitine concentrations in rat heart. *Toxicology* 1997;121:205–13.
- [33] Longo A, Bruno G, Curti S, Mancinelli A, Miotti G. Determination of L-carnitine, acetyl-L-carnitine and propionyl-L-carnitine in human plasma by high-performance liquid chromatography after pre-column derivatization with I-aminoanthracene. *J Chromatogr B Biomed Appl* 1996;686:129–39.
- [34] Botker HE, Kimose M, Helligso P, Nielsen TT. Analytical evaluation of high-energy phosphate determination by high performance liquid chromatography in myocardial tissue. *J Mol Cell Cardiol* 1994;26:41–8.
- [35] Zhang JG, Lindup WE. Differential effects of cisplatin on the production of NADH dependent superoxide and the activity of antioxidant enzymes in rat renal cortical slices in vitro. *Pharmacol Toxicol* 1996;79:191–8.
- [36] Battelli D, Bellei M, Arrigoni-Martelli E, Muscatello U, Bobyleva V. Interaction of carnitine with mitochondrial cardiolipin. *Biochem Biophys Acta* 1992;1117:33–6.
- [37] Olson RD, Boerth RC, Gerber JG, Nies AS. Mechanism of adriamycin cardiotoxicity: evidence for oxidative stress. *Life Sci* 1981;29:1393–410.
- [38] Naziroglu M, Karaoglu A, Aksoy AO. Selenium and high dose vitamin E administration protects cisplatin-induced oxidative damage to renal, liver, and lens tissues in rats. *Toxicology* 2004;195:221–30.
- [39] Joshi S, Hasan SK, Chandra R, Husain MM, Srivastava RC. Scavenging action of zinc and green tea polyphenol on cisplatin and nickel induced nitric oxide generation and lipid peroxidation in rats. *Biomed Environ Sci* 2004;17:402–9.
- [40] Lee JE, Nakagawa T, Kim TS, Shiga A, Iguchi F, Lee SH, et al. role of reactive radicals in degeneration of the auditory system of mice following cisplatin treatment. *Acta Otolaryngol* 2004;124:1131–5.
- [41] Wink DA, Cook JA, Christodoulou D, Krishna MC, Pacelli R, Kim S, et al. Nitric oxide and some nitric oxide donor compounds enhance the cytotoxicity of cisplatin. *Nitric Oxide* 1997;1:88–94.
- [42] Watanabe K, Hess A, Bloch W, Michel O. Expression of inducible nitric oxide synthase (iNOS/NOS II) in the vestibule of guinea pigs after the application of cisplatin. *Anticancer Drugs* 2000;II:29–32.
- [43] Srivastava RC, Farookh A, Ahmad N, Misra M, Hasan SK, Huain MM. Evidence for the involvement of nitric oxide in cisplatin-induced toxicity in rats. *Biometals* 1996;9:139–42.
- [44] Son K. Cisplatin-based interferon gamma gene-therapy of murine ovarian carcinoma. *Cancer Gene Ther* 1997;4:391–6.
- [45] Son K, Kim YM. In vivo cisplatin-exposed macrophages increase immunostimulant-induced nitric oxide synthesis for tumor cell killing. *Cancer Res* 1995;55:5524–7.
- [46] Arduini A, Mancinelli G, Redatti GL, Dottori S, Molajoni F, Ramsay RR. Role of carnitine and carnitine palmitoyltransferase as integral components of the pathway for membrane phospholipid fatty acid turnover in intact human erythrocytes. *J Biol Chem* 1992;267:12673–81.
- [47] Sayed-Ahmed MM, Khattab MM, Gad MZ, Mostafa N. L-carnitine prevents the progression of atherosclerotic lesions in hypercholesterolemic rabbits. *Pharmacol Res* 2001;44:235–42.
- [48] Arrigoni-Martelli E, Caso V. Carnitine protects mitochondria and removes toxic acyls from xenobiotics. *Drugs Exp Clin Res* 2001;27:27–49.
- [49] Berardi S, Heuberger W, Jacky E, Krahenbuhl S. Renal carnitine excretion is Marker for cisplatin-induced tubular nephrotoxicity (Abstract). *FASEB J* 1996;10:A470.
- [50] Neely JR, Morgan HE. Relationship between carbohydrate and lipid metabolism and the energy balance of heart muscle. *Annu Rev Physiol* 1974;36:413–59.
- [51] Dodson WL, Schan DS, Krauss S, Hanna W. Alterations of serum and urinary carnitine profile in cancer patients: hypothesis of possible significance. *J Am Nut* 1989;8:133–42.
- [52] Maestri A, De Pasquale Ceratti A, Cundari S, Zanna C, Cortesi E, Crino L. A pilot study on the effect of acetyl-L-carnitine in paclitaxel and cisplatin-induced peripheral neuropathy. *Tumori* 2005;91:135–8.
- [53] Bianchi G, Vitali G, Caraceni A, Ravaglia S, Capri G, Cundari S, et al. Symptomatic and neurophysiological responses of paclitaxel- or cisplatin-induced neuropathy to oral acetyl-L-carnitine. *Eur J Cancer* 2005;41:1746–50.
- [54] Ghirardi O, Verteehy M, Vesci L, canta A, Nicolini G, Galbiati S, et al. Chemotherapy-induced allodynia: neuroprotective effect of acetyl-L-carnitine. *In Vivo* 2005;19:631–7.

- [55] Pisano C, Pratesi G, Laccabue D, Zunino F, Lo Giudice P, Bellucci A, et al. Paclitaxel and cisplatin-induced neurotoxicity: a protective role of acetyl-L-carnitine. *Clin Cancer Res* 2003;9:5756–67.
- [56] Sayed-Ahmed MM, Salman TM, Gaballah HE, Abou El-Naga SA, Nicolai R, Calvani M. Propionyl-L-carnitine as protector against adriamycin-induced cardiomyopathy. *Pharmacol Res* 2001;43:513–20.
- [57] Chang B, Nishikawa M, Sato E, Utsumi K, Inoue M. L-carnitine inhibits cisplatin-induced injury of the kidney and small intestine. *Arch Biochem Biophys* 2002;405:55–64.
- [58] Ahmad S, Thomas Robertson H, Golper TA, Wolfson M, Kurtin P, Katz LA, et al. Multicenter trial of L-carnitine in maintenance hemodialysis patients II. Clinical and biochemical effects. *Kid Intern* 1990;38:912–8.