

Outcome of nonoperative management of blunt liver trauma

Hayan A. Bismar, MD, CABS, Mohammed K. Alam, MBBS, FRCS, Mohammed H. Al-Keely, MBBS, CABS, Saleh M. Al Salamah, MBBS, FRCS, Abdulmajeed A. Mohammed, MBBS, FRCS.

ABSTRACT

Objective: To evaluate our experience with the management of blunt liver trauma at Riyadh Central Hospital, Kingdom of Saudi Arabia.

Methods: The hospital records of 68 patients treated for blunt liver trauma at Riyadh Medical Complex over a 5-year period (1997 through to 2002) were reviewed retrospectively. Patients who were hemodynamically unstable or had peritonitis were treated by urgent laparotomy (operative group). The other group of patients were treated conservatively as they were hemodynamically stable (nonoperative group) in the intensive care unit (ICU). All patients had computed tomogram of the abdomen with oral and intravenous contrast. Injuries grades were classified according to American Association for the Surgery of Trauma (AAST). Follow up computed tomogram of the abdomen was performed in 1-2 weeks time.

Results: A total of 68 patients were treated over a 5-year period. Thirty-three patients (49%) were treated by immediate surgery. Hepatorrhaphy was performed in 22 patients, non anatomical resection in 3 patients and

liver packing in 2 patients to control bleeding. No active bleeding was found in 8 patients. Nonoperative group (n=35, 51%) were managed in the ICU for close monitoring. Surgically treated group had more patients with complex liver injury (30% versus 11%), require more units of blood (3.2 versus 2.1) but had a shorter hospital stay (9 days versus 12 days). Two patients from nonoperated group develop complications (biloma: one patient, infected hematoma: one patient), the nonoperative treatment failed in one patient who require laparotomy due to rebleeding from grade IV liver injury with failure rate of 3%. The only mortality (one patient) was in the operated group.

Conclusion: The nonoperative treatment is a safe and effective method in the management of hemodynamically stable patients with blunt liver trauma. The nonoperative treatment should be the treatment of choice in such patients whenever computed tomogram and ICU facilities are available. However, further studies with large number of patients are needed to support our results.

Saudi Med J 2004; Vol. 25 (3): 294-299

The operative intervention was considered the only acceptable treatment of blunt liver injuries until the late 1970s.¹ Since then, treatment of liver injury has changed greatly. The non operative management of blunt hepatic trauma has now become the standard management in hemodynamically stable patients. This change has taken place due to the growing realization that the majority of liver injuries have already stopped

bleeding at the time of surgery.^{2,3} The advent of high quality computed tomogram (CT) scan which has high rate of diagnosing intra and retroperitoneal injuries, and the uncontrollable bleeding during live surgery has further contributed towards the non operative management of liver trauma. Non operative management was first applied in children and subsequently in adults.⁴ This practice is increasing with time and 50% of blunt liver injuries

From the Department of General Surgery, King Khalid University Hospital, University Unit, Riyadh Medical Complex, Riyadh, Kingdom of Saudi Arabia.

Received 15th July 2003. Accepted for publication in final form 29th October 2003.

Address correspondence and reprint request to: Dr. Hayan A. Bismar, Department of General Surgery, King Khalid University Hospital, PO Box 7805, Riyadh 11472, Kingdom of Saudi Arabia. Tel. +966 (1) 4671585. Fax. +966 (1) 4679493. E-mail: habismar@gawab.com

were treated non operatively in a recently published large multicenter study.⁵ In view of this trend, we thought it would be appropriate to analyze our experience with the management of liver injuries at Riyadh Central Hospital, Kingdom of Saudi Arabia, (KSA). This study reports our experience with the management of blunt liver trauma over a 5-year period from 1997 through to 2002.

Methods. The hospital records of 68 patients with blunt liver trauma admitted to Riyadh Medical Complex during the 5-year period (1997 through to 2002) were reviewed retrospectively. Demographic data, mechanism of injury and the nature of definitive treatment offered were recorded in all patients. Thirty-five patients were treated non-operatively and subjected for detailed evaluation for radiological investigation, grade of liver injury, associated injuries, other therapeutic procedures, number of blood transfusion, complications, hospital stay and mortality. All patients were initially resuscitated with crystalloids or blood, or both as indicated. The remaining 33 patients were hemodynamically unstable patients, and either directly taken to surgery or after a positive diagnostic peritoneal lavage (DPL). Abdominal ultrasound and computerized tomography (CT) scan with oral and intra-venous contrast were the main tools for evaluating abdomen in hemodynamically stable patients. The injuries were classified according to American Association for the Surgery of Trauma (AAST)⁶ **Table 1**. Only patients with stable hemodynamic state on admission or stabilized after initial resuscitation and the absence of other indications of laparotomy were selected for nonoperative treatment. Whenever possible, these patients were admitted to the intensive care unit (ICU) for close monitoring. Follow up ultrasound or CT, or both were used to monitor progress.

Results. A total of 68 patients with blunt liver trauma were treated during the study period. There were 53 male and 15 female, the median age was 31.4 + 11.7 years (range between 2-60 years). The injuries were due to road traffic accident in 46 patients (67.5%), fall from height in 12 (17.5%), and other causes in 10 patients (15%): assault (3), sports (3), domestic (2), and industrial (2).

The urgent operative intervention. Emergency laparotomy was performed on 33 patients (49%) for suspected ongoing bleeding or peritonitis. Their hepatic injuries were classified as grade I in 4 patients, grade II in 7 patients, grade III in 12 patients, grade IV in 7 patients and grade V in 3 patients. Bleeding had already stopped in 8 patients, all with grade I and II liver injuries. In 20 patients, hepatorrhaphy successfully controlled bleeding.

Table 1 - Liver injury scale.⁶

Grade	Injury description
Hematoma Laceration	Subcapsular, nonexpanding, <10% surface area Capsular tear, nonbleeding, < 1cm parenchymal depth
Hematoma Laceration	Subcapsular, nonexpanding, 10-50% surface; < 1cm intraparenchymal, nonexpanding, < 2cm in diameter Capsular tear, active bleeding; 1-3 cm parenchymal depth, <10 cm in length
Hematoma Laceration	Subcapsular, >50% surface area or expanding ruptured subcapsular hematoma with active bleeding; intraparenchymal hematoma >5 cm < 3 cm expanding >3 cm parenchymal depth
Hematoma Laceration	Ruptured intraparenchymal hematoma with active bleeding Parenchymal disruption involving 25-50% of hepatic lobe
Laceration Vascular	Parenchymal disruption involving >50% of hepatic Juxtahepatic venous injuries (ie. retrohepatic vena cava/major hepatic veins)
Vascular	Hepatic avulsion

Non-anatomical resection and debridement was performed on 3 patients. Two patients (one with hepatic vein tear which was sutured) needed live packing. The associated intraabdominal injuries were splenic tear (4 patients), mesenteric hematoma (4 patients), retroperitoneal hematoma (3 patients), splenic injuries were treated by splenectomy (3 patients) and splenorrhaphy (one patient), duodena perforation (one patient) and small bowe perforation (one patient). Mesenteric and retroperitoneal hematomas were not expanding and were not explored. The associated extraabdominal injuries were thoracic trauma in 9 patients, head injuries in 6 patients, trauma to extremities in 5 maxillofacial trauma in 5 patients and pelvic fractures in 4 patients. The rate of blood transfusion was 3.5 units/patient (range 2-18 units). Two patients died, one from severe head injury and one due to uncontrollable bleeding from liver injury (grade V) treated by packing, giving a liver related mortality of 3%. The mean hospital stay was 9 days + 4.09 (range 4-28 days).

The nonoperative management. Thirty-five patients (51%), 27 of them hemodynamically stable and 8 stabilized after resuscitation with intravenous fluids and blood transfusion were treated non-operatively. Abdominal ultrasonogram was performed in 7 patients and liver trauma (liver tear and hematomas) were correctly diagnosed in 6 cases. Computed tomogram abdomen was performed on all patients, and the liver injuries were

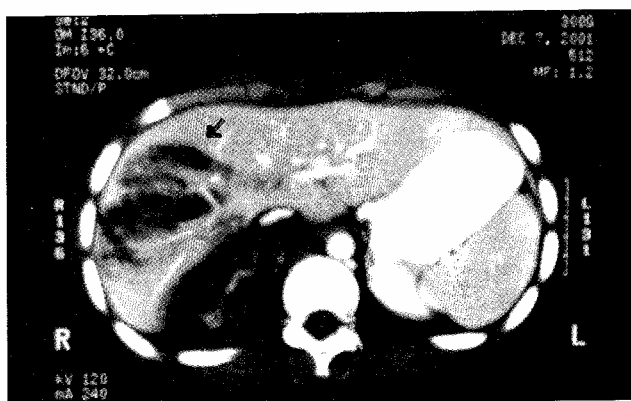

Figure 1 - Computed tomogram of the abdomen showing a radiating laceration of the right hepatic lobe grade IV (Bear Claw type).

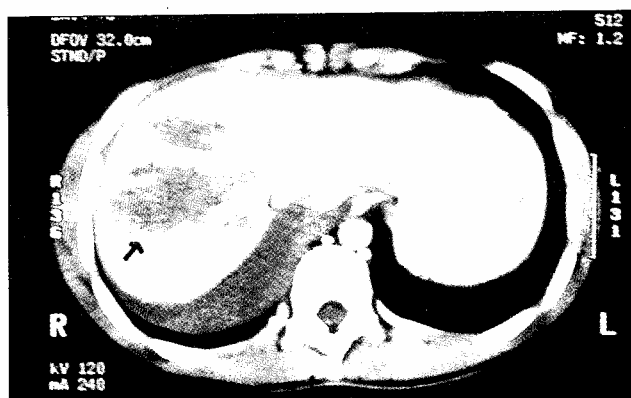


Figure 3 - Computed tomogram of the abdomen showing a deep hepatic laceration grade III.

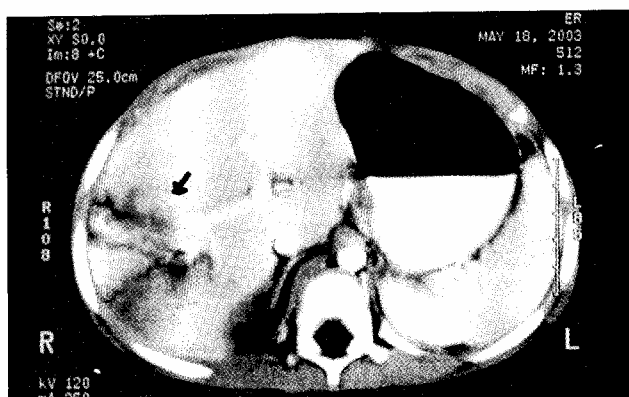


Figure 2 - Computed tomogram abdomen demonstrating intra-hepatic hematomas grade III.

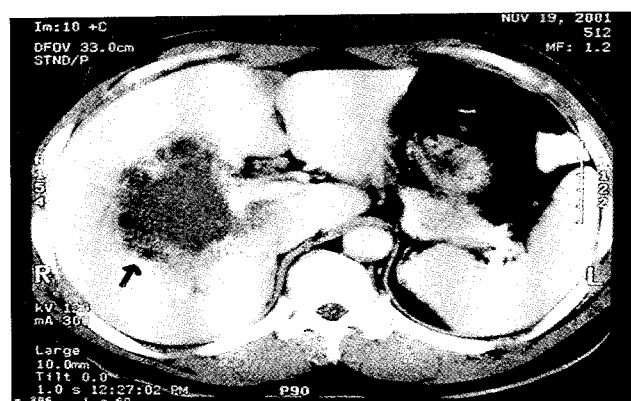

Figure 4 - Follow up computed tomogram of the abdomen after one week showing an unorganized intra-hepatic hematoma (clinically presented as secondary infection of the hematoma).

classified as grade I in 11 patients (31%), grade II in 13 patients (37%), grade III in 7 patients (20%), grade IV in 4 patients (11.4%) **Figures 1, 2 & 3**. There was no grade V injury, and no case of "pooling of contrast" or extravasation. The associated intraabdominal injuries shown on CT were retroperitoneal hematoma in 4 patients, splenic tear in 3 patients and mesenteric hematoma in 2 patients. The associated extra-abdominal injuries were ribs fracture in and pneumothorax in 10 patients, head injuries in 7 patients, injuries to extremities in 6 patients, pelvic fracture in 5 patients and maxillofacial trauma in 5 patients. The majority of the patients (77%) were admitted to ICU for continuous monitoring. Blood transfusion was given to 8 patients (23%) with mean rate of 2.1 units per patient (range 1-4). The nonoperative treatment succeeded in all patients except one who became hemodynamically unstable during observation. He underwent laparotomy and control of active

bleeding from a grade IV liver injury, with failure rate for non-operative treatment of 3%. Two patients (6%) developed complications related to liver trauma during nonoperative management (6%). One patient developed biloma in subhepatic region which was drained percutaneously, the other patient developed fever and leukocytosis after 4 days of admission (possibly due to infected hematoma) which responded to intra-venous antibiotics. Follow up CT abdomen was performed in 23 patients after one week. No significant changes were seen in 21 patients, a biloma in one patient and development of secondary infection of the hematoma in another patient (**Figure 4**). Computerized tomography abdomen was repeated in 2 weeks on 8 patients, 5 patients with grade III, and 3 patients with grade IV liver injury. It revealed some degree of resolution of these injuries and incomplete resolution of the hematoma in the above mentioned patient. Follow up ultrasonogram

was performed in 10 patients (7 patients with grade I and 3 patients with grade II injury) before discharge. There was no mortality in this group. The main hospital stay was 12 days + 5.6 days (range 3-22 days). Twenty-three patients (65%) were discharged within one week, 11 patients (32%) by the second week, and only one patient stayed more than 2 weeks due to associated head injury. All patients were followed up in outpatient clinic for a mean of 2 months (range from 1-8 months). They were all making satisfactory progress.

Discussion. The management of blunt liver injuries in adult has changed with time. This changing trend has been very well documented by Richardson et al⁷ in their own institution over a 25-year period. Initial reports of non-operative management of blunt liver trauma were not taken seriously, but during the later half of the 1980's and 90's, several reports on the successful non-operative management of liver injury have appeared.⁷⁻¹⁰ From a low 30% to a high 85% of blunt liver injuries are now offered this line of treatment.⁹⁻¹¹ During the present study, which covers a 5-year period, 51% of patients with blunt liver injuries due to various causes were selected for nonoperative management which is in line with other reported experience.⁵ Initially, the nonoperative management of liver trauma was restricted to grade I-III liver injury.^{12,13} With increasing experience, more complex liver injuries in patients who remained hemodynamically stable were being included for this mode of treatment.¹⁴⁻¹⁶ In our study, the main criteria for selection for nonoperative management were hemodynamic stability and absence of any other indication for laparotomy. We did not have any patient with grade V liver injury, but 11% of our patients had grade IV liver injury. This figure is close to other study where patients with grade IV and V liver injury comprised 14% of patients treated nonoperatively.⁵ The common worries facing a surgeon treating these patients non-operatively are risk of bleeding, increased demand on blood bank, missing other intra-abdominal injury and development of complications such as bile collection leaking from disrupted canaliculi and infection of hematoma. One patient (3%) in this study rebelled during observation, which needed laparotomy. This patient had grade IV liver injury. Other studies have also reported zero to a low rebleeding rate.^{5,9,17} Inclusion of more complex liver increases the risk of rebleeding. In one study, 66% of all patients who rebelled had grade IV and V injury.⁵ Some of those patients, who rebelled, could avoid laparotomy and be managed by angiographic embolization. We have not used this modality due to its non availability. The fear of increased demand for blood transfusion was not substantiated in the

present study; similar to other reports.^{16,18} The blood unit used per patient in this study was higher in operated group (3.2 units versus 2.1 units, $p=0.00001$). This is probably due to more patients with complex liver injuries in the operated group (30% versus 11%, $p=0.054$).

Missing intra-abdominal injuries could significantly affect the morbidity and mortality. The occult injuries to bowel or pancreas may be missed even with modern CT scan.¹⁹ This could be minimized by frequent clinical evaluation and repeating the investigation as and when clinical suspicions demand it. There was no case of missed abdominal injury in the present study, but an incidence of 0.5-2% missed injuries have been reported in literature.^{5,16}

Less urgent complication such as "biloma" and abscess, formation has been reported. Their incidence varies from 2.8% for biloma¹⁹ and 0.7% for abscess.⁵ We had one case each of biloma (3%) and infected hematoma (3%). Biloma was treated by percutaneous drainage and infected hematoma responded to antibiotics. Other series have also managed these complications mostly without surgical intervention.⁵

There is still a debate regarding the timing of follow up CT scan. Many studies have shown that only little changes are noted on CT scan performed in less than one week from injury and complete resolution occurs by 3 months.⁵ The optimal time for follow up CT scan has been suggested to be between 7 and 10 days from the original injuries.⁵ Another unresolved question remains that should every patient be subjected to routine follow up CT scan or it should be selective, based on severity grade and clinical progress. Many surgeons believe that in patients with less severe injury progressing well a follow up CT scan would not alter the management and therefore do not need it.²⁰ In the present study, 23 patients (66%) had follow up CT scan one week from injury. Only 2 patients, showed significant changes (biloma and infected hematoma) to alter their management. We feel that CT should be used more selectively and dictated by clinical courses in grade I-III injury. However, patients with grade IV or V injury should have at least one follow up CT scan between 7-10 days before discharge to monitor the progress, as they are more likely to develop liver related complication. We also feel that ultrasonogram may be useful in the follow up of less severe liver injury. The other objection to routine nonoperative management of liver trauma is the prolonged hospital stay. In this study, 47% of patients were discharged within one week and the additional 29% were discharged within 2 weeks of admission, with a mean hospital stay of 12 days. A similar finding has been reported by other researchers.⁵ The mean hospital stay in operated group was shorter (9 days) in our study. The longer

hospital stay in nonoperated group reflects the genuine worry of the treating surgeons regarding the risk of delayed hemorrhage. Although rare, there is a real possibility of this complication.¹⁸ This worry is more in our practice, when one realizes that some of these patients will be going back to remote areas. This can explain the longer stay of nonoperated patients in this study.

On comparing the nonoperative group with surgically treated group, the latter had more patients with complex injuries (11% versus 30%, $p=0.054$) required more units of blood transfusion (2.1 versus 3.2 units, $p=0.00001$) but had a shorter hospital stay (9 versus 12 days, $p=0.015$). The only mortality (one patient) was in the operated group.

In conclusion, the present study supports the safety and efficacy of nonoperative management of blunt liver trauma in hemodynamically stable patients, if there are no other indications for laparotomy. The nonoperative treatment should be the treatment of choice in such patients whenever CT scan, and ICU facilities are available. However, further studies with larger number of patients and longer period of follow up are needed.

Acknowledgment. We, the authors, would like to express our sincere thanks to all Consultants, General Surgery Department, Riyadh Medical Complex, for allowing us to review the medical records of their patients for the purpose of this study and Dr. Mohammad Al-Zoom, Radiology Department, for his interpretation of the radiological investigation. Also, extended thanks to Ms. Shyni Paloth for her excellent assistance during the typing of this manuscript.

References

1. Flint L, Mays ET, Aaron WS, Fulton RL, Polk HC. Selectivity in the management of hepatic trauma. *Ann Surg* 1977; 185: 613-618.
2. Cywes BS, Rode H, Millar AJW. Blunt liver trauma in children: Nonoperative management. *J Pediatr Surg* 1985; 20: 14-18.
3. Meredith JW, Ditesheim JA, Stonehouse S, Wolfman N. Computed tomography and diagnostic peritoneal lavage – complimentary roles in blunt trauma. *Am Surg* 1992; 58: 44-48.
4. Federico JA, Horner WR, Clark DE, Isler RJ. Blunt hepatic trauma: Nonoperative management in adults. *Arch Surg* 1990; 125: 905-908.
5. Pachter LH, Knudson MM, Esrig B, Ross S, Hoyt D, Cogbill T et al. Status of nonoperative management of blunt hepatic injuries in 1995: A multicenter experience with 404 patients. *J Trauma* 1996; 40: 31-38.
6. Moore EE, Shackford SR, Pachter HL, McAninch JW, Browner BD, Champion HR et al. Organ injury scaling: Spleen, liver and kidney. *J Trauma* 1989; 29: 1664-1666.
7. Richardson DJ, Franklin GA, Lukan JK, Carrillo EH, Spain DA, Miller FB et al. Evolution in the management of hepatic trauma: A 25-year perspective. *Ann of Surg* 2000; 232: 324-330.
8. Knudson MM, Maull KI. Nonoperative management of solid organ injuries: past, present, and future. *Surg Clin North Am* 1999; 79: 1357-1371.
9. Malhotra AK, Fabian TC, Croce MA, Gravin TJ, Kudsk KA, Minard G et al. Blunt hepatic injury. *Ann Surg* 2000; 231: 804-813.
10. Ochsner MG. Factors of failure for nonoperative management of blunt liver and splenic injury. *J Surg* 2001; 25: 1393-1396.
11. Lucas CE, Ledgerwood AM. Changing times and the treatment of liver injury. *Am Surg* 2000; 66: 337-341.
12. Pachter HL, Spencer FC, Hofstetter SR, Liang HG, Coppa GF. Significant trends in the treatment of hepatic trauma: Experience with 411 injuries. *Ann Surg* 1992; 215: 492-500.
13. Durham RM, Buckley J, Keegan M, Frarell S, Shapiro MJ, Mazuski J. Management of blunt hepatic injuries. *Am J Surg* 1992; 164: 477-481.
14. Hollands MJ, Little JM. Nonoperative management of blunt liver injuries. *Br J Surg* 1992; 78: 968-972.
15. Meredith JW, Young JS, Bowling J, Roboussin D. Nonoperative management of blunt hepatic trauma: The exception or the rule. *J Trauma* 1994; 36: 529-534.
16. Croce MA, Fabian TC, Menke PG, Waddle-Smith L, Minard G, Kudsk KA et al. Nonoperative management of blunt hepatic trauma is the treatment of choice for hemodynamically stable patients: Results of a prospective trial. *Ann Surg* 1995; 221: 744-753.
17. Velmahos GC, Toutouzas K, Radin R, Chan L, Rhee P, Tillou A et al. High success with nonoperative management of blunt hepatic trauma: The liver is a sturdy organ. *Arch Surg* 2003; 138: 475-481.
18. Berman SS, Monney EK, Weireter LJ Jr. Late fatal hemorrhage in pediatric liver trauma. *J Pediatr Surg* 1992; 27: 1546-1548.
19. Pachter HL, Hofstetter SR. The current status of nonoperative management of adult blunt hepatic injuries. *Am J Surg* 1995; 169: 442-454.
20. Ciraulo DL, Nikkanen HE, Palter M, Markowitz S, Gabram S, Cowell V et al. Clinical analysis of the utility of repeat computed tomographic scan before discharge in blunt hepatic trauma. *J Trauma* 1996; 41: 821-824.