

Noncommunicating third branchial cyst

Mohammed H. Al-Akeely, MBBS, CABS,
Youssef A. Al-Suhaibani, CABS, SBS,
Kamran Khalid, FRCSI, FRCSEd.

Third branchial cyst is a rare condition that arises from the embryonic remnants of the third branchial cleft. The cyst may be discovered incidentally, or may present as a lateral neck mass with recurrent infection, tracheal compression, dysphagia, or hoarseness. The awareness of its existence is important for adequate treatment: complete excision, and prevention of recurrence. An extensive Medline search revealed only 19 cases reported in the English literature.^{1,5} We present a case of an infected third branchial cyst presenting clinically as an abscess in the left lower neck.

A 22-year-old Saudi male was admitted to Riyadh Medical Complex, Riyadh, Kingdom of Saudi Arabia, with 2 weeks history of fever, and a rapidly enlarging painful swelling in the left lower neck. There was no history of recent upper respiratory tract infection or tuberculosis. Physical examination revealed a 10 x 8 cm firm, mildly tender, indurated swelling in the lower part of the neck with ill-defined edges, and areas of cellulitis in the overlying skin. Laboratory findings revealed a total white cell count of 10×10^9 , and erythrocyte sedimentation rate of 70 mm. Blood glucose, renal, and liver function tests were normal. Fine needle aspiration revealed pus with squamous, and inflammatory cells. An ultrasound (US) of the neck revealed a 7 x 5 cm cystic mass containing debris with thick edematous walls deep to the lower third of sternomastoid muscle, and the left thyroid lobe

(Figure 1). A computed tomography scan (Figure 2) with intravenous (IV) contrast confirmed the cyst to be posterolateral to the carotid sheath, which was pushed medially. The left thyroid lobe was also compressed medially. The findings were consistent with inflamed left third branchial cyst. The patient was started on intravenous cefuroxime sodium, and surgery was planned. Under general anesthesia, a prior pharyngoscopy by an Ear Nose Throat surgeon did not reveal any pyriform sinus. A lateral neck incision was employed, and the cystic mass was found to extend upwards, and posteriorly adjacent to the left thyroid lobe. Complete excision was carried out, and no definite sinus tract could be identified. Histopathology confirmed the diagnosis of branchial cyst with squamous epithelial lining. The patient was followed up for one year. He is well with no recurrence.

In the 3rd-7th weeks of embryonic life, the branchial apparatus develops, which consists of 5 paired mesodermal arches separated by 4 ectodermal clefts, and endodermal pouches.¹ The 3rd pouch has dorsal, and ventral components. The dorsal component develops into the inferior parathyroid, while the ventral component develops into the thymus. Both the 3rd and 4th pouches are connected to the pharynx by the pharyngobranchial duct, which usually disappears in the 7th week of gestation. Occasionally, this duct persists, and forms a tract communicating with the pyriform fossa.² This explains the cyst formation filled with fluid, and recurrent infection subsequent to upper respiratory tract infection, as well as the high recurrence rate if this communication is not dealt with during surgery.¹ Cystic remnants of the 3rd branchial cleft are extremely rare. The cyst presents in the lower

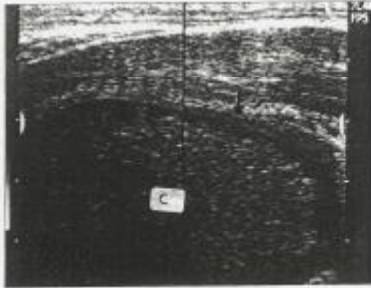


Figure 1 - Ultrasound of the neck showing thick edematous wall of the cyst (arrow) and infected fluid in the cavity (c) with no gas.

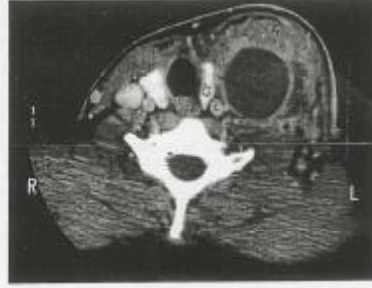

Figure 2 - Computed tomography scan of the neck showing cyst cavity (CC). Left thyroid lobe (LT) compressed medially and carotid sheath (CS) anteromedially. The typical position of third branchial cyst. SM - sternomastoid muscle.

Clinical Notes

neck along the anterior border of the sternomastoid muscle. Anatomically, this is related posteriorly to the carotid sheath, and glossopharyngeal nerve, and overlies the hypoglossal, and the superior laryngeal nerves in close relation to the thyroid lobe. The tract passes above the thyroid cartilage towards the pyriform fossa. The present case exhibits the classical location of the 3rd branchial cyst, confirmed by CT scan. It has been postulated that the sinus of the 3rd branchial cyst opens proximal in the fossa, while that of the 4th branchial cyst opens at the apex (caudal) in the fossa or even in the proximal esophagus.⁴ In spite of the differences in the direction of the tract, and location of the sinus opening in the pyriform fossa, there is a great deal of confusion in the literature regarding the diagnosis of 3rd and 4th branchial cysts. This reflects the increasing reports of both anomalies as one entity.^{4,6} The condition becomes even more confusing in cases of noncommunicating cysts, as in the present case. The cysts are reported to occur at any age from neonate to adulthood.⁴ In neonates, tracheal compression leading to respiratory distress is a serious complication.³ Less dramatic complications include: recurrent neck abscesses, cellulites or thyroid swelling.⁴ It is interestingly noticed that 3rd and 4th branchial cysts are usually occurring on the left side with no definite explanation.³ The present case presented with a left-sided cyst. A combination of US, CT scan, barium swallow, thyroid scan or magnetic resonance imaging may aid in the diagnosis. But, a high index of suspicion is very important for both physicians, and radiologists. Multiple diagnostic modalities are recommended to confirm the diagnosis, as false diagnosis has been frequently reported with a single imaging technique.⁴ Both US and CT are helpful in defining the nature of the cyst, and its relation to the surrounding structures. Presence of gas in the cyst is considered pathognomonic for communication with the pharynx. In the present case, both of these investigations were suggestive of 3rd branchial cyst according to its location, and relation to the carotid sheath, and the thyroid gland, but did not show any evidence of gas in the cyst. Barium swallow using thin barium has been reported to be 80% accurate in identifying sinus in non infected cases.⁴ However, this investigation was not carried out in the current case due to infected swelling. The treatment of non infected cysts is complete surgical excision, and ligation of the sinus tract as high as possible when

present. However, patients presenting with infected cysts should receive a course of antibiotics followed by surgical excision.⁴ Meticulous dissection of the neck should be undertaken to visualize the recurrent, and superior laryngeal nerves, and excision of the fibrous tissue, and adjacent thyroid tissue, as well as the tract en bloc has been recommended.⁶ Intraoperative pharyngoscopy, injection of methylene blue or insertion of a catheter have all been reported in identifying the sinus opening in the pyriform fossa.⁴ However, other authors found these techniques less optimal, and advocated the direct laryngoscopic transillumination of the tract in dissection, and complete excision.¹

Although 3rd and 4th branchial cysts are rare, their existence has to be kept in mind when dealing with patients presenting with neck mass or deep recurrent neck abscess especially, on the left side. Multimodality investigations, and preoperative laryngoscopy are recommended to identify the sinus opening. The absence of communication with pyriform fossa does not exclude such diagnosis, and complete excision offers the optimal management.

Received 1st April 2005. Accepted for publication in final form 16th May 2005.

From the Department of Surgery (Al-Akeely), College of Medicine, University Unit, and the Department of Surgery (Al-Subaibani, Khalid), Riyadh Central Hospital, Riyadh, Kingdom of Saudi Arabia. Address correspondence and reprint requests to Dr. Mohammed H. Al-Akeely, Assistant Professor and Consultant Surgeon, Department of Surgery, 37 College of Medicine, PO Box 2925, Riyadh 11461, Kingdom of Saudi Arabia. Tel. +966 (1) 4671575. Fax. +966 (1) 4116772.

References

1. Edmonds JL, Girod DA, Woodroof JM, Bruegger DE. Third branchial anomalies. *Arch Otolaryngol Head Neck Surg* 1997; 123: 438-441.
2. Burge D, Middleton A. Persistent pharyngeal pouch derivatives in the neonate. *J Pediatr Surg* 1983; 18: 230-234.
3. Chin AC, Radhakrishnan J, Slatton D, Geisster G. Congenital cysts of the third and fourth pharyngeal pouches or pyriform sinus cysts. *J Pediatr Surg* 2000; 35: 1252-1255.
4. Liberman M, Kay S, Emil S, Flageole H, Nguyen LT, Tewfik TL, et al. Ten years of experience with third and fourth branchial remnants. *J Pediatr Surg* 2002; 37: 685-690.
5. Takimoto T, Itoh M, Furukawa M, Sakano K, Sakashita H, Iwawaki J, et al. Branchial cleft (pouch) anomalies: a review of 42 cases. *Auris Nasus Larynx* 1991; 18: 87-92.
6. Elahi MM, Dubé P, Manoukian JJ, Tewfik TL, Schloss MD. Partial thyroidectomy and selective neck dissection in the management of pyriform sinus fistulae. *J Otolaryngol* 1997; 26: 57-63.